

Dimensional ultrasonographic relationship of the right lobe of pancreas with associated anatomic landmarks in clinically normal dogs

Bandula Kumara WICKRAMASEKARA RAJAPAKSHAGE^{1)*},
Janaka Pradeep Kumara ELLEARAEWE GARUHAMILAGE¹⁾, Dona Daphney Niranjala DE SILVA¹⁾ and
Ashoka DANGOLLA¹⁾

¹⁾Department of Veterinary Clinical Sciences, Faculty of Veterinary Medicine and Animal Science, University of Peradeniya, Peradeniya, 20400, Sri Lanka

(Received 6 April 2015/Accepted 22 July 2015/Published online in J-STAGE 3 August 2015)

ABSTRACT. The purpose of this prospective study was to establish the ultrasonographic characteristics of the dimension of the right pancreatic lobe with that of the associated anatomic landmarks in healthy dogs. Ultrasonographic examinations were performed on 25 dogs. The thickness of the right pancreatic lobe was compared with that of mural thickness of duodenum, diameter of duodenum, pancreatic duct, abdominal aorta, portal vein, caudal vena cava, and length and width of the right kidney and right adrenal gland. The correlation between each pancreatic parameter and the dimensions of the anatomical landmarks were assessed using linear regression analysis and Pearson's correlation coefficient (*r*) test. Significant, but weak linear correlations were observed between thickness of right pancreatic lobe with that of duodenum mural thickness ($r=0.605$, $R^2=0.339$, $P=0.001$); duodenum diameter ($r=0.573$, $R^2=0.299$, $P=0.003$); and right adrenal gland length ($r=0.508$, $R^2=0.052$, $P=0.01$). There was no significant dimensional relationship with other selected anatomic landmarks. The ratio between the thickness of right pancreatic lobe and the mural thickness of duodenum, diameter of duodenum and length of right adrenal gland were 2.88 ± 0.53 , 1.27 ± 0.27 and 0.81 ± 0.15 , respectively. Calculating the ratio of thickness of the right pancreatic lobe with the dimension of significantly correlated anatomic landmarks is a useful and simple method for evaluating the size of the right pancreatic lobe in dogs in clinical practice.

KEY WORDS: anatomic landmark, canine, dimension, pancreas, ultrasonography

doi: 10.1292/jvms.15-0209; *J. Vet. Med. Sci.* 78(1): 1–5, 2016

The antemortem diagnosis of canine pancreatic disease poses a significant challenge to clinicians. Clinical presentation and clinical pathologic findings are often nonspecific in canine pancreatic diseases, such as pancreatitis, pancreatic abscesses and pancreatic tumors [14, 17–20]. The general process of diagnosis of pancreatic diseases in dogs consists of integrating patient history, physical examination results with the results of biochemical determinations of pancreatic enzymes and radiographic and ultrasonographic evaluation of the abdomen [17]. It is also shown that total amylase and lipase concentrations have significant limitations with regard to sensitivity and specificity in suspected pancreatic disease [17, 19–22]. Radiography is not sensitive in the diagnosis of pancreatitis [19]. While computed axial tomography is the most useful imaging modality for pancreatic evaluation in humans, the expense, need for general anesthesia and limited availability make it less useful in veterinary practice [1, 10, 14]. When traditional methods are combined with ultrasonography, the accuracy of diagnosis of pancreatic disorders can be increased both in human and animals [3, 17].

As a result, ultrasonography has become an increasingly valuable diagnostic aid in the evaluation of pancreatic diseases of dogs.

In dogs, the right pancreatic lobe is the easiest lobe to visualize ultrasonographically [8]. It lies dorsomedial to the descending duodenum, ventral to the right kidney and lateral to the portal vein which can be used as landmarks [5]. The gastroduodenal and cranial pancreaticoduodenal arteries supply the cranial half of the right pancreatic lobe, while the caudal part of the right lobe receives blood from the caudal pancreaticoduodenal artery which is a branch of the cranial mesenteric artery [11]. Identification of these anatomic landmarks and the blood vessels are helpful to ultrasonographically locate the right pancreatic lobe of dogs [3, 11].

In small animal clinical practice, several dimensional ultrasonographic associations have been proposed among various anatomical structures of the body [2, 7, 9, 16] that can be used as rapid and simple diagnostic techniques. Penninck *et al.* [18] have reported that the pancreatic thickness and diameter of the pancreatic duct of the dog significantly increase with the bodyweight. The ratio between kidney length and abdominal aortic diameter to estimate renal size in healthy dogs [16] and left atrium and aortic root ratio using M-mode echocardiography to identify cardiac enlargement of dogs [7] have been proposed.

Ultrasound is useful in the diagnosis of canine pancreatic diseases, such as pancreatitis, edema, necrosis and hemorrhage associated with pancreatitis result in an enlarged, irregular, diffusely hypoechoic pancreas [17]. On the other

*CORRESPONDENCE TO: WICKRAMASEKARA RAJAPAKSHAGE, B. K., Department of Veterinary Clinical Sciences, Faculty of Veterinary Medicine and Animal Science, University of Peradeniya, Peradeniya, 20400, Sri Lanka. e-mail: wrbkumara@pdn.ac.lk

©2016 The Japanese Society of Veterinary Science

This is an open-access article distributed under the terms of the Creative Commons Attribution Non-Commercial No Derivatives (by-nc-nd) License <<http://creativecommons.org/licenses/by-nc-nd/3.0/>>.

hand, chronic or resolving pancreatitis and pancreatic atrophy may result in decreased size of the pancreas [13]. Furthermore, the normal ultrasonographic appearance of the canine pancreas and the changes associated with experimentally induced acute pancreatitis have been reported [17]. However, evaluating the size of the pancreas is still challenging: largely because of the wide variations among breeds. To our knowledge, there is no information available for the dimensional correlation between the thickness of the pancreas and associated anatomic landmarks of clinically normal dogs. The purpose of our study was to establish the ultrasonographic characteristics of dimensions of the right lobe of pancreas of dogs with that of the associated anatomical landmarks.

MATERIALS AND METHODS

Animals: Ultrasonographic examinations were performed on 25 clinically normal dogs (7 males and 18 females) between 6 months and 10 years of age with bodyweights ranging from 3 to 28 kg. These dogs were presented to the Veterinary Teaching Hospital, University of Peradeniya for general checkups or elective surgical procedures, such as castration and ovariohysterectomy. Written consent from owners were obtained before each ultrasonographic examination. All the dogs were clinically healthy. None of the dogs had any evidence of gastrointestinal tract, adrenal or renal disease, based on history, physical examination, laboratory evaluations including complete blood count, serum biochemical analysis (blood urea nitrogen, serum creatinine, alanine aminotransferase, aspartate aminotransferase and alkaline phosphatase), urinalysis and ultrasonographic examinations. Dogs with anorexia, vomiting, diarrhea, constipation, nausea, weight loss, abdominal pain or abdominal effusion and dogs with urinary tract, hepatic or cardiac diseases were excluded from the study.

Ultrasonography procedure: Right lateral intercostal approach without sedation was used for ultrasonographic examinations. Sonography was performed using ultrasound scanner (MyLab30vet, Esaote, Genoa, Italy) with a linear-array transducer Esaote LA 522 with frequency of 5–7.5 MHz. All the necessary dimensions were obtained from the sonographic images using electronic calipers. In each examined organ, at least three measurements were taken in mm, and the means of all measurements were calculated as the final value. Real-time images were recorded on videotape, and static images were sent to a computer equipped with specialized software for storage and off-line evaluation.

Measuring the dimensions of right kidney and right adrenal gland: As Lim *et al.* described [15], the ultrasound transducer was placed on right lateral intercostal area, through the 10–12th intercostal space to image the transverse view of the right pancreatic lobe and proximal portion of the descending duodenum. The right lobe of pancreas was confirmed by observing the pancreaticoduodenal artery and vein, while cross sections of the duodenum, right kidney, transverse colon and liver served as anatomical landmarks. The maximum thickness of right pancreatic lobe was measured ventromedial to

the right kidney and lateral to the descending duodenum. The mural thickness of the descending duodenum was measured from the mucosal to the serosal surfaces. The diameter of the duodenum was also measured from the serosal to the serosal surfaces using the same image. The duct in the right pancreatic lobe was identified as a central anechoic tubular structure with a thick wall. It was confirmed by color-flow Doppler ultrasonography due to lack of vascular flow. The diameter of pancreatic duct was measured as described by Penninck *et al.* [18].

Measuring the dimensions of abdominal aorta, caudal vena cava and portal vein: The transducer was placed transversely on 10 or 11th intercostals space to image abdominal aorta, caudal vena cava and portal vein at the porta hepatis. The abdominal aorta was located at the most dorsal position of the scan plane with pulsatility and the thick hyperechoic vessel wall [4]. The luminal diameter of the aorta was measured from still images acquired when its diameter was largest in order to account for pulsation of the aorta (Fig. 1B). The caudal vena cava was distinguished between aorta and portal vein by visualizing the surrounded caudate and right lateral liver lobes as it passes through the liver [4]. Three values of luminal diameter of the caudal vena cava were obtained, and mean was calculated. The portal vein was visualized ventral and to the left of the caudal vena cava. The cross sectional image of the portal vein was obtained, and its diameter was measured excluding the vessel walls.

Measuring of the dimensions of right kidney and right adrenal gland: The right kidney was scanned by moving caudally from the porta hepatis. For each kidney, as described by Barella *et al.* [2], the maximum length and the maximum width were measured (Fig. 1C). As described by Brinkman *et al.* [4], the cranial pole of the right kidney was located, and then, the transducer was angled slightly medially to identify the sagittal view of right adrenal gland. The celiac and cranial mesenteric arteries, cranial pole of the right kidney and the caudal vena cava were used as landmarks for locating the right adrenal gland [1]. Color-flow Doppler ultrasonography was used to clearly distinguish the margin of right adrenal gland from the adjacent caudal vena cava. The maximum length and width (cranial pole) of the right adrenal gland were measured.

Statistical analysis: All measurements were recorded on a Microsoft Excel spreadsheet. Statistical analysis was done using softwares; Minitab[®], R-studio and R-commander[®]. Descriptive statistics, such as mean, range (minimum to maximum) and standard deviations of the mean, were calculated for all the measurements obtained. The correlation between each parameter of the pancreas and the dimensions of the anatomical landmarks were assessed using linear regression analysis and Pearson's coefficient after ensuring residual normality and constant residual variance using Shapiro Wilk test. The ratios for right pancreatic lobe thickness were calculated with that of the dimensions of the duodenum, abdominal aorta, caudal vena cava, portal vein and length and width of both the right kidney and right adrenal gland. For all the analyses, values of $P < 0.05$ were considered as statistically significant.

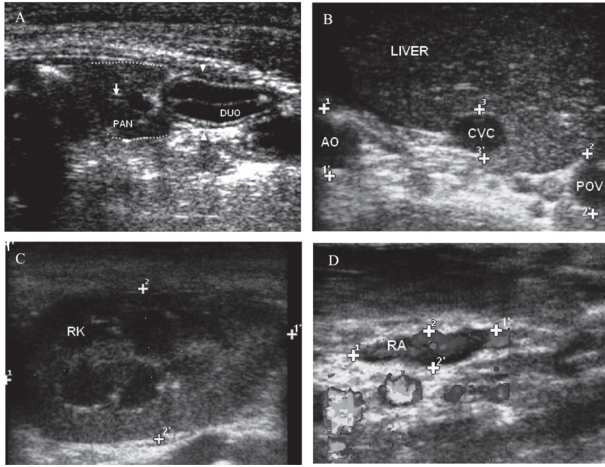


Fig. 1. Right intercostal approach sonograms of a 6 years old mixed breed female dog. (A) The transverse view of the normal right pancreatic limb (margined by dashed lines) which is located adjacent to the proximal descending duodenum (DUO). Pancreatic duct is indicated by the arrow. (B) The transverse view of normal canine porta hepatis. Three major vessels in a dorsoventral direction are abdominal aorta (AO), the most dorsal structure, caudal vena cava (CVC) view at margin of the liver and the portal vein (POV) located ventrally (dorsal is to the left, ventral is to the right, and medial is to the bottom). (C) Sagittal view of the right kidney (RK). Cursors represent the length (11') and the width (22') of RK. (D) Sagittal view of the right adrenal gland (RA), color-flow Doppler used to differentiate from blood vessels. Cursors represent the length (11') and the width (22') of RA.

RESULTS

A total of 25 dogs were scanned (7 males and 18 females), and the required scan images were obtained. The dogs were Dalmatian (1), Pomeranian (2), Labrador Retriever (3) and mixed breed dogs (19). For each variable measured, the mean, standard deviation, and minimum and maximum values were obtained. Figure 1A represents the sonograph of the right lobe of pancreas of a 6 years old mixed breed dog. The mean thickness of right pancreatic lobe was 14.2 ± 3.3 mm (range, 9.4 to 20.8 mm). The thickest dimension of 20.8 mm was recorded in a 28 kg, 8 months old Labrador Retriever. Figure 1A shows the proximal descending duodenum, which was located adjacent to the right pancreatic lobe. The mean mural thickness of descending duodenum was 4.9 ± 0.8 mm (range, 3.8 to 7.0 mm). The mean duodenum diameter was 11.3 ± 2.2 mm (range, 7.7 to 17 mm). Figure 1A shows the right pancreatic duct by its anechoic, tubular appearance with surrounding, thin, hyperechoic wall and its central location of the right pancreatic parenchyma. The pancreatic duct had a narrow lumen with a mean diameter of 1.5 ± 0.3 mm (range, 1 to 2.1 mm).

The diameter of the abdominal aorta, caudal vena cava, portal vein and length and width of right kidney and right adrenal gland reported are depicted in Fig. 1. The mean diameters of abdominal aorta, caudal vena cava and portal vein were 12.1 ± 1.8 mm (range, 8.5 to 16.2 mm), 9.0 ± 1.7 mm (range, 5.4 to 11.9 mm) and 9.5 ± 1.5 mm (range, 7.1 to 12.5

mm), respectively. The mean length of right kidney was 46.8 ± 3.2 mm (range, 40.1 to 54.5 mm), while the mean width was 29.0 ± 4.9 mm (range, 19.5 to 38.4 mm). The mean length and width of right adrenal gland were 17.8 ± 3.0 mm (range, 12.4 to 23.6 mm) and 5.0 ± 1.0 mm (range, 3.2 to 7.1 mm), respectively.

As shown in Fig. 2, the significant linear correlations ($P < 0.05$) were observed for the thickness of the right pancreatic lobe with that of mural thickness of duodenum ($P = 0.001$, Pearson's correlation coefficient = 0.605), diameter of duodenum ($P = 0.003$, Pearson's correlation coefficient = 0.573) and length of right adrenal gland ($P = 0.01$, Pearson's correlation coefficient = 0.508). The coefficient of determinations (R^2 value) for thickness of right pancreatic lobe to mural thickness of duodenum, diameter of duodenum and length of right adrenal gland were 0.339, 0.299 and 0.052, respectively. There was no significant linear correlation observed between thickness of right pancreatic lobe with that of the diameter of pancreatic duct, abdominal aorta, caudal vena cava, portal vein, length and width of the right kidney, and width of the right adrenal gland.

The ratio between the thickness of right pancreatic lobe to the dimension of significantly correlated anatomic landmarks of clinically normal dogs is presented in Table 1. The ratio between the right pancreatic lobe and the mural thickness of duodenum was 2.88 ± 0.53 (range, 1.92 to 4.04). Meanwhile, the ratio between the right pancreatic lobe and the mean diameter of duodenum was 1.27 ± 0.27 (range, 0.93 to 1.88). The ratio between the right pancreatic lobe and the mean length of right adrenal gland was 0.81 ± 0.15 (range, 0.41 to 1.06).

DISCUSSION

In this study, the dimensional relationship of right lobe of pancreas with associated anatomic landmarks of clinically healthy dogs was investigated, and 3 significant linear relationships were observed. Those were between thickness of right pancreatic lobe with that of mural thickness of duodenum, the diameter of duodenum and the length of right adrenal gland. However, the coefficient of determinations of those three associations indicated that the strengths of the association were weak ($R^2 < 0.5$). The regression equations were determined to predict the functional correlation between the right pancreatic lobe thickness and the dimensions of associated anatomic landmarks. The duodenum is a useful anatomic landmark that can be simultaneously imaged ultrasonographically with the right pancreatic lobe through the right intercostal approach [5]. Thus, the dimensional relationship between the right pancreatic lobe and the adjacent duodenum can be useful in assessing pancreatic size in dogs. In the present study, it was found that the thickness of the right pancreas showed a significant linear correlation both with the mural thickness and the diameter of the duodenum. Thus, it can be suggested that the thickness of the pancreas could be assessed by comparison with the adjacent descending duodenum. In addition, our study also revealed that the thickness of right pancreatic lobe showed significant linear correlation with the length of right

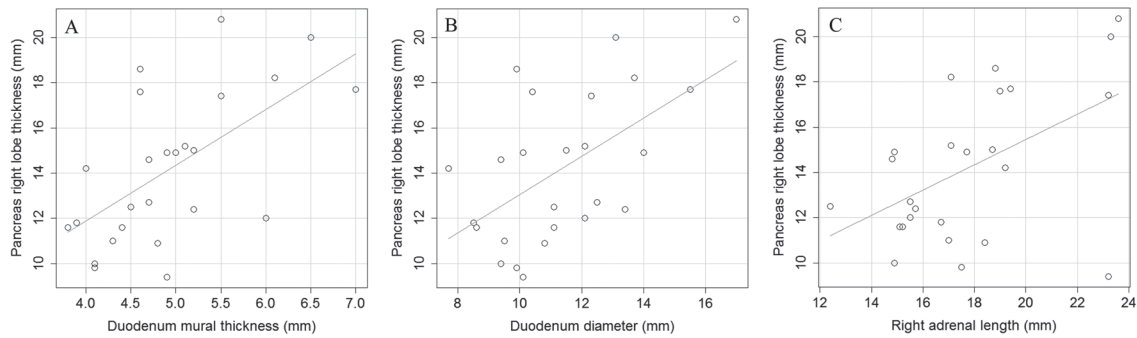


Fig. 2. Plot (A) pancreatic right lobe thickness as a function of mural thickness of duodenum, with the regression line. The regression equation is $y=0.148x + 2.82$. The Pearson's correlation coefficient is 0.605 with a P -value of 0.001, (B) pancreatic right lobe thickness as a function of duodenum diameter, with the regression line. The regression equation is $y=0.388x + 5.84$. The Pearson's correlation coefficient is 0.573 with a P -value of 0.003, (C) pancreatic right lobe thickness as a function of right adrenal gland length, with the regression line. The regression equation is $y=0.461x + 11.2$. The Pearson's correlation coefficient is 0.508 with a P -value of 0.01.

Table 1. Summary of ratio of right pancreatic lobe thickness with the dimension of significantly correlated anatomical landmarks of clinically normal dogs ($n=25$)

Ratio	Range		mean	standard deviation
	minimum	maximum		
Pancreas: Duodenum mural thickness	1.92	4.04	2.88	0.53
Pancreas: Duodenum diameter	0.93	1.88	1.27	0.27
Pancreas: Right adrenal gland length	0.41	1.06	0.81	0.15

adrenal gland. Thus, these findings can be used as markers for changes in pancreatic sizes in real-time ultrasonography. Penninck *et al.* have reported that pancreatic thickness and diameter of the pancreatic duct of dogs significantly increase with body weight, although age is not a correlated factor [18]. Dilation of the pancreatic duct has also been described as an ultrasonographic feature of pancreatitis in dogs [12]. Although pancreatic duct was visible in the right pancreatic lobe in all dogs used in this study, a significant dimensional association between the diameter of the pancreatic duct with that of the thickness of the right pancreas was not observed.

When comparing thickness of pancreas to mural thickness of duodenum, ratios between 1.92 and 4.04 were indicative of a normal-sized right lobe pancreas. Additionally, the ratios of the right pancreatic lobe to duodenum diameter and to right adrenal gland were between 0.93 to 1.88 and 0.41 to 1.06, respectively (Table 1). Thus, it can be suggested that these ratios can be utilized as a quick diagnostic tool to determine the changes in size of the right pancreatic lobe in clinical practice. However, it should be mentioned that as the variability in the normal ratio is fairly broad, these reference intervals may not allow the identification of small changes in the size of the pancreas.

In the present study, dogs were selected randomly without standardizing fasting period. If food was withheld for 12 hr prior to ultrasonographic examination to limit the ultrasound wave propagation interference with gas within the stomach and adjacent bowel could be avoided [20], this relationship would become more accurate. However, in our experience, the presence of intestinal gas was never substantial enough

to prevent measurements in this study. Accordingly, it can be suggested that the right lobe of pancreas could be visualized through right intercostal approach to get necessary information even in dogs not properly fasted. In addition, poor patient cooperation and excessive breathing motion also are significant factors contributing to the quality of the ultrasonographic examination. As Etue *et al.* suggested the use of sedation or analgesics during the examination may be useful to improve the tolerance of the procedure and reduce animal movements [6]. To mimic the normal status, the dogs were restrained manually in the present study.

The term thickness was used to represent the height or width of the pancreas in the present study. As described by Penninck *et al.* considering that the pancreas has a variably amorphous to triangular shape and its position can shift on the basis of position of dog, the term thickness was considered an acceptable compromise to describe the measurement obtained perpendicular to the long axis of the pancreas [18].

In our study, all dogs were clinically classified as free from pancreatic diseases. However, there are few limitations that should be reported in relation to our method. For example; increased duodenal wall thickness has been reported to be associated with pancreatitis [6, 15]. Thus, further investigation is needed to determine whether the reference values we identified were also valid for various disease conditions. Second drawback in our study was, that serum biochemical analysis; sensitive diagnostic test including canine pancreas-specific lipase could not be performed due to lack of test facilities. Histopathology using pancreatic biopsy, the gold standard [9], could not be performed in this study, as there is

no strong clinical justification to recommend a more invasive procedure in these clinically healthy dogs. The possibility of subclinical pancreatic disorder therefore cannot be ruled out. It was considered that the absence of a clinical history or clinical signs compatible with pancreatic diseases in these dogs supports their inclusion in the study. Moreover, it would have been better, if we could compare the body and the left lobe of the pancreas with associated anatomic landmarks as well. In the present study, the measurement of the body and the left lobe of pancreas was not possible due to the presence of gas in stomach and colon which obscured the visualization of these two areas in most cases. On the other hand, the range of body weights of 25 dogs is broad (range, 3 to 28 kg) in this study. Thus, it would have been better, if the sample number could increase including various breeds of dogs.

In conclusion, there were weak but significant linear correlations between thickness of right lobe of pancreas with that of the duodenum mural thickness, the duodenal diameter and the right adrenal gland length, respectively. The measurements used to calculate the ratio are sufficiently easy to obtain without complex reference tables. On the basis of the data obtained in this study, calculating the ratio of thickness of the right pancreatic lobe to dimension of significantly linear correlated anatomic landmarks is a useful and simple method for evaluating the size of the right lobe of canine pancreas in clinical practice.

ACKNOWLEDGMENTS. We thank Professor I. D. Silva, Drs. K. A. N. Wijayawardhane, E. Rajapaksha, E. R. K. V. Edirimanne, M. G. C., M. Jayasinghe, H. M. H. S. Ariyaratna and junior clinicians at the Veterinary Teaching Hospital, Department of Veterinary Clinical Sciences, University of Peradeniya, Sri Lanka, Professor M. Takiguchi at the Laboratory of Veterinary Internal Medicine, Graduate School of Veterinary Medicine, Hokkaido University, Japan and Professor M. Yamasaki at the Department of Veterinary Medicine, Faculty of Agriculture, Iwate University, Japan for their valuable advice in carrying out this study.

REFERENCES

1. Barberet, V. and Saunders, J. H. 2010. Ultrasonographic examination of selected small structures in dogs and cats: thyroid glands, lymph nodes and adrenal glands. *Vlaams Diergen. Tijds.* **79**: 147–155.
2. Barella, G., Lodi, M., Sabbadin, L. A. and Faverezani, S. 2012. A new method for ultrasonographic measurement of kidney size in healthy dogs. *J. Ultrasound* **15**: 186–191. [Medline] [CrossRef]
3. Bertolotto, M., Onforio, M. D., Martone, E., Malago, R. and Pozzi Mucelli, R. 2007. Ultrasonography of the pancreas. Doppler Imaging. *Abdom. Imaging* **32**: 161–170. [Medline] [CrossRef]
4. Brinkman-Ferguson, E. L., Biller, D. S., Armbrust, L. J. and O'Brien, R. T. 2007. The clinical utility of the right lateral intercostal ultrasound scan technique in dogs. *J. Am. Anim. Hosp. Assoc.* **43**: 179–186. [Medline] [CrossRef]
5. Brinkman-Ferguson, E. L. and Biller, D. S. 2009. Ultrasound of the right lateral intercostal space. *Vet. Clin. North Am. Small Anim. Pract.* **39**: 761–781. [Medline] [CrossRef]
6. Etue, S. M., Penninck, D. G., Labato, M. A., Pearson, S. and Tidwell, A. 2001. Ultrasonography of the normal feline pancreas and associated anatomic landmarks: a prospective study of 20 cats. *Vet. Radiol. Ultrasound* **42**: 330–336. [Medline] [CrossRef]
7. Hansson, K., Haggstrom, J., Kvarn, C. and Lord, P. 2002. Left atrial to aortic root indices using two-dimensional and M-mode echocardiography in Cavalier King Charles spaniels with and without left atrial enlargement. *Vet. Radiol. Ultrasound* **43**: 568–575. [Medline] [CrossRef]
8. Hecht, S. and Henry, G. 2007. Sonographic evaluation of the normal and abnormal pancreas. *Clin. Tech. Small Anim. Pract.* **22**: 115–121. [Medline]
9. Hecht, S., Penninck, D. G., Mahony, O. M., King, R. and Rand, W. M. 2006. Relationship of pancreatic duct dilation to age and clinical findings in cats. *Vet. Radiol. Ultrasound* **47**: 287–294. [Medline] [CrossRef]
10. Jaeger, J. Q., Mattoon, J. S., Bateman, S. W. and Morandi, F. 2003. Combined use of ultrasonography and contrast enhanced computed tomography to evaluate acute necrotizing pancreatitis in two dogs. *Vet. Radiol. Ultrasound* **44**: 72–79. [Medline] [CrossRef]
11. Knol, J. A., Strodel, W. E. and Eckhauser, F. E. 1987. Blood flow and distribution in the canine pancreas. *J. Surg. Res.* **43**: 278–285. [Medline] [CrossRef]
12. Lamb, C. R. and Simpson, K. W. 1995. Ultrasonographic findings in cholecystokinin-induced pancreatitis in dog. *Vet. Radiol. Ultrasound* **36**: 139–145. [CrossRef]
13. Larson, M. M., Panciera, D. L., Ward, D. L., Steiner, J. M. and Williams, D. A. 2005. Age-related changes in the ultrasound appearance of the normal feline pancreas. *Vet. Radiol. Ultrasound* **46**: 238–242. [Medline] [CrossRef]
14. Lee, E. S. and Lee, J. M. 2014. Imaging diagnosis of pancreatic cancer: a state of the art review. *World J. Gastroenterol.* **20**: 7864–7877. [Medline] [CrossRef]
15. Lim, S. Y., Nakamura, K., Morishita, K., Sasaki, N., Murakami, M., Osuga, T., Ohta, H., Yamasaki, M. and Takiguchi, M. 2013. Qualitative and quantitative contrast enhanced ultrasonography of the pancreas using bolus injection and continuous infusion methods in normal dogs. *J. Vet. Med. Sci.* **75**: 1601–1607. [Medline] [CrossRef]
16. Mareschal, A., Anjou, M. A., Moreau, M., Alexander, K. and Beaugard, G. 2007. Ultrasonographic measurement of kidney-to-abdominal aorta ratio as a method of estimating renal size in dogs. *Vet. Radiol. Ultrasound* **48**: 434–438. [Medline] [CrossRef]
17. Murtaugh, R. J., Herring, D. S., Jacobs, R. M. and Dehoff, W. D. 1985. Pancreatic ultrasonography in dogs with experimentally induced acute pancreatitis. *J. Vet. Radiol.* **26**: 27–32. [CrossRef]
18. Penninck, D. G., Zeyen, U., Taeymans, O. N. and Webster, C. R. 2013. Ultrasonographic measurement of the pancreas and pancreatic duct in clinically normal dogs. *Am. J. Vet. Res.* **74**: 433–437. [Medline] [CrossRef]
19. Riaux, C. G. 2003. Diagnostic approaches to acute pancreatitis. *Clin. Tech. Small Anim. Pract.* **18**: 245–249. [Medline] [CrossRef]
20. Saunders, H. M. 1991. Ultrasonography of the pancreas. *Probl. Vet. Med.* **3**: 583–603. [Medline]
21. Simpson, K. W., Simpson, J. W., Lake, S., Morton, D. B. and Batt, R. M. 1991. Effect of pancreatectomy on plasma activities of amylase, isoamylase, lipase, and trypsin-like immunoreactivity in dogs. *Res. Vet. Sci.* **51**: 78–82. [Medline] [CrossRef]
22. Trivedi, S., Marks, S. L., Kass, P. H., Luff, J. A., Keller, S. M., Johnson, E. G. and Murphy, B. 2011. Sensitivity and specificity of canine pancreas-specific lipase (cPL) and other markers for pancreatitis in 70 dogs with and without histopathologic evidence of pancreatitis. *J. Vet. Intern. Med.* **25**: 1241–1247. [Medline] [CrossRef]