

# Primary Hepatic Melanoma in a Child

Min Wang<sup>1</sup>, Hai-Feng Liu<sup>2</sup>, Yu-Lan Li<sup>1</sup>

<sup>1</sup>Department of Anesthesiology, First Hospital of Lanzhou University, Lanzhou, Gansu 730000, China

<sup>2</sup>Department of Radiology, First Hospital of Lanzhou University, Lanzhou, Gansu 730000, China

Min Wang and Hai-Feng Liu contributed equally to this work.

To the Editor: A 12-year-old male patient was admitted to First Hospital of Lanzhou University with the complaint of right upper abdominal pain lasting for 2 years. He had no history of hepatitis, vomiting, and weight loss during the past 2 years. Physical examination revealed that heart and lungs were normal and without superficial lymph node enlargement or yellowish discoloration of the skin and mucous membrane. Liver percussion pain was positive though abdomen was soft with no tenderness and no palpable liver or spleen. Laboratory examination showed globulin 18.7 g/L,  $\alpha$ -fetoprotein (AFP), and carcinoembryonic antigen (CEA) were normal. Ultrasound (US) showed a 6.2 cm  $\times$  4.2 cm well-defined and high-echo lesion with irregular low-echo area at its center in the right posterior lobe of enlarged liver [Figure 1a]. Computed tomography (CT) displayed a 5.9 cm  $\times$  4.2 cm low-density lesion with central high-density area in the right posterior lobe [Figure 1b]. On hepatic arterial phase scan [Figure 1c], the lesion was heterogeneously enhanced with clear margin and the density was superior to surrounded parenchyma. On portal venous and delayed phase scan [Figure 1d], lesion's enhancement was reduced with ambiguous margin. In addition, there was no evidence for the spread to the neighboring lymph nodes and other abdominal organs. The patient refused to receive magnetic resonance imaging (MRI) examination because of high expense.

The patient underwent right partial hepatectomy under general anesthesia. A 6.0 cm  $\times$  4.5 cm  $\times$  3.2 cm well-defined, dark-red space-occupying nodule was seen in the right lobe of liver and protruded on the enlarged liver surface [Figure 1e]. Pathologic examinations revealed that tumor cells were multiplemorphic and tumorous growth was invasive along with necrosis and hemorrhage at its center [Figure 1f]. Immunohistochemical stain demonstrated that tumor cells were positive for HMB45 and LCA while negative for S-100 and CD34, and Ki 67 proliferation index was <10%. The results of pathological and immunohistochemical examinations support the diagnosis of melanoma, and detailed medical history was inquired postoperatively. Exhaustive examinations of other body parts, especially the skin, eye, parotid gland, upper and lower gastrointestinal tracts, and genital tract, were performed. However, no other possible primary site of malignant melanoma was detected. Based on these examination results, the patient was diagnosed with primary hepatic melanoma (PHM).

Melanoma might occur in any organ and tissue of the body, but mostly occur in skin, and can spread to other organs, such as liver and bones.<sup>[1]</sup> The liver is a frequent site of metastases from melanoma; however, PHM is rare, only a few cases have been reported so far. PHM is most prevalent in the age group of 45–60 years, without a case of child in worldwide literature. Commonly, the patients with PHM often seek medical help because of right upper abdominal pain. AFP and CEA were normal in our case, which are consistent with reported literature;<sup>[2]</sup> therefore, AFP and CEA can provide an important clue in diagnosing PHM.

In our study, US expressed space-occupying lesion of high echo with central low echo within the enlarged liver, and these low echoes are possibly connected with lesion's internal necrosis and hemorrhage. PHM displays low-density lesion with central high-density area within enlarged liver on CT manifestation, and the lesion was of heterogeneous enhancement on arterial phase. Enhancement effect decreases on portal venous and delayed phase scan; however, the contrast medium continues filling the lesion, which causes equal enhancement compared to normal liver parenchyma. Therefore, we assume that the CT manifestation of PHM shows low density, and the enhancement rises greatly and reduces slowly. Hu<sup>[3]</sup> proposed that melanoma can create a paramagnetic material that can shorten T1 and T2 relaxation time, which leading MRI manifestation of PHM is characteristic with increased signal intensity on T1-weighted image (T1WI) and decreased signal intensity on T2WI.

There is no ideal treatment for PHM, and hepatic resection is considered safe and potentially curative treatment, which may decrease mortality in patients with resectable PHM.<sup>[4]</sup> However, the survival time is highly variable in patients. The reason for this variation is more likely due to delayed diagnosis. Multiple studies have reported the effectiveness of surgical treatment over systemic treatment. According to Hodi *et al.*,<sup>[5]</sup> total metastasectomy is a vital procedure for some appropriately selected PHM patients.

**Address for correspondence:** Dr. Yu-Lan Li,

Department of Anesthesiology, First Hospital of Lanzhou University,  
Lanzhou, Gansu 730000, China  
E-Mail: jasm@sina.com

## Access this article online

### Quick Response Code:



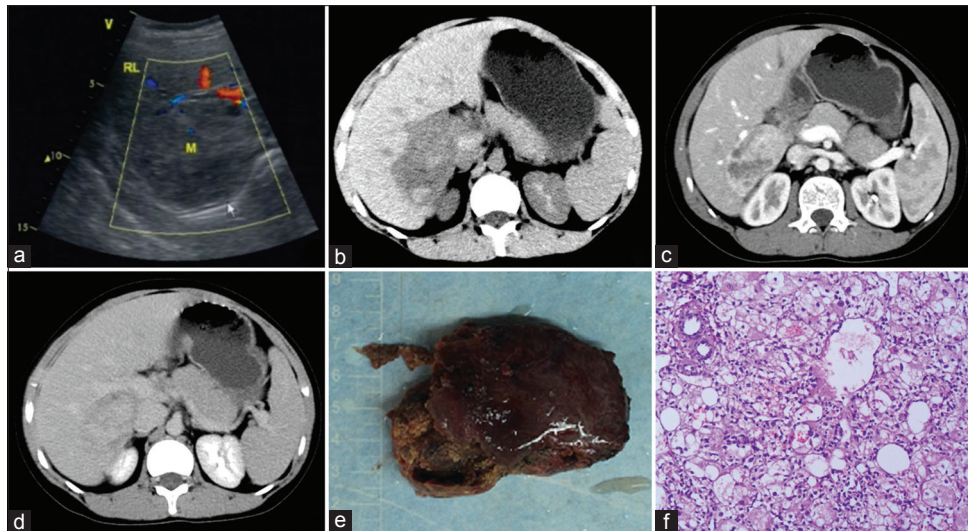
**Website:**  
www.cmj.org

**DOI:**  
10.4103/0366-6999.239318

This is an open access journal, and articles are distributed under the terms of the Creative Commons Attribution-NonCommercial-ShareAlike 4.0 License, which allows others to remix, tweak, and build upon the work non-commercially, as long as appropriate credit is given and the new creations are licensed under the identical terms.

© 2018 Chinese Medical Journal | Produced by Wolters Kluwer - Medknow

**Received:** 11-05-2018 **Edited by:** Li-Shao Guo  
**How to cite this article:** Wang M, Liu HF, Li YL. Primary Hepatic Melanoma in a Child. *Chin Med J* 2018;131:2135-6.



**Figure 1:** (a) Ultrasound showing a high-echo lesion with low-echo area at its center within the enlarged liver. (b) Computed tomography displaying low-density lesion with central high-density area within the enlarged liver. (c) On arterial phase, the lesion showed heterogeneous enhancement with clear margin. (d) On delayed phase, the lesion's density was similar to surrounded liver parenchyma. (e) Grossly, the resected irregular mass with white-red color measured 7.5 cm × 5.4 cm × 3.5 cm. (f) Microscopically, the tumor cells were round or oval with clear boundary and abundant cytoplasm; nuclear fission and melanin deposition can also be easily seen (H & E staining, original magnification ×100).

In conclusion, PHM may also occur in children. Characteristics of clinical and medical imaging can provide important clues for diagnosing PHM and distinguishing it from common liver tumors. Hepatic resection is considered safe which may improve survival in patients with PHM.

### Declaration of patient consent

The authors certify that they have obtained all appropriate patient consent forms. In the form, the patient/patient's guardians has given their consent for their images and other clinical information to be reported in the journal. The patient/patient's guardians understand that their names and initials will not be published and due efforts will be made to conceal their identity, but anonymity cannot be guaranteed.

### Financial support and sponsorship

Nil.

### Conflicts of interest

There are no conflicts of interest.

### REFERENCES

1. Agarwala SS, Eggermont AM, O'Day S, Zager JS. Metastatic melanoma to the liver: A contemporary and comprehensive review of surgical, systemic, and regional therapeutic options. *Cancer* 2014;120:781-9. doi: 10.1002/cncr.28480.
2. Farolfi A, Ridolfi L, Guidoboni M, Milandri C, Calzolari F, Scarpi E, *et al.* Liver metastases from melanoma: Hepatic intra-arterial chemotherapy. A retrospective study. *J Chemother* 2011;23:300-5. doi: 10.1179/joc.2011.23.5.300.
3. Hu XR. Primary malignant melanoma of liver: A case report. *Chin J Radiol* 2006;40:1115. doi: 10.3760/j.issn:1005-1201.2006.10.037.
4. Zhang Y, Hu Z, Wu W, Liu J, Hong D, Zhang C. Partial hepatectomy for primary hepatic melanoma: A report of two cases and review of the literature. *World J Surg Oncol* 2014;12:362. doi: 10.1186/1477-7819-12-362.
5. Hodi FS, O'Day SJ, McDermott DF, Weber RW, Sosman JA, Haanen JB, *et al.* Improved survival with ipilimumab in patients with metastatic melanoma. *N Engl J Med* 2010;363:711-23. doi: 10.1056/NEJMoa1003466.