

Available online at www.sciencedirect.com

ScienceDirect

journal homepage: www.elsevier.com/locate/radcr

Case Report

Adult extracardiac rhabdomyomas presenting as a slowly growing neck mass[☆]

Omar Elmandouh, MD, Elena Greco, MD, Amit Agarwal, MD*

Mayo Clinic, 4500 San Pablo Road, Jacksonville, FL 32224, USA

ARTICLE INFO

Article history:

Received 7 May 2022

Revised 25 May 2022

Accepted 28 May 2022

Keywords:

Extracardiac

Rhabdomyoma

CT

ABSTRACT

Rhabdomyomas are rare benign tumors arising from skeletal muscle cells, most common cardiac in origin and usually seen in pediatric age group, often associated with neurophakomatosis like tuberous sclerosis. Extracardiac tumors are rare and are classified based on histology into adult, fetal and genital forms. The adult form of extracardiac rhabdomyoma are seen in the head and neck region in vast majority of cases. These can occur within the pharyngeal or laryngeal compartments along with other neck spaces and the orbits. In this case report, we describe the findings of adult extracardiac rhabdomyoma and discuss the striking similarity with lymphomas on imaging.

© 2022 The Authors. Published by Elsevier Inc. on behalf of University of Washington.

This is an open access article under the CC BY-NC-ND license

(<http://creativecommons.org/licenses/by-nc-nd/4.0/>)

Introduction

Adult rhabdomyomas are rare benign tumors of skeletal muscle origin. Although histologic features of rhabdomyomas based on tissue sections have been well described, there are very few reports of the far less common extracardiac type of these tumors [1]. Based on the organ of origin these tumors can be broadly classified into cardiac and extracardiac types. Cardiac rhabdomyoma is often associated with tuberous sclerosis and is more probably a developmental anomaly [2]. Histologically, the extracardiac rhabdomyomas are further classified into fetal, genital, and adult types. The head and neck area harbors 90% of adult extracardiac rhabdomyomas (AER). Therefore, these tumors are to be kept in mind as a differential diagnosis of tumors in this region [2–4]. Although rare in children, these tumors have been described in patients of

all ages from 5 weeks to 61 years of age. The tumors are more common in men than in women (up to 6:1) [3,5]. Recurrence may be as high as 42% [4] and in one case; three recurrences have been reported within a period of 35 years after primary resection [6]

Adult extracardiac rhabdomyomas have a predilection for the head and neck, especially the sublingual and submandibular regions, palate, pharynx, larynx, and soft tissues of the neck. Usually, adult rhabdomyomas occur as a solitary mass, although they can at times occur as multiple nodules in the same anatomic location [7–9]. However, as these tumors are rare in day-to-day practice, the imaging features are not well defined. These imaging modalities are however very useful in determining the tumor's features, its extent, and the likelihood of multifocality [10,11].

In this paper we reviewed a case report of a 66-year-old female that presents to the hospital with a mass in the neck

[☆] Competing Interests: All authors declare no conflict of interest.

* Corresponding author.

E-mail address: agarwal.amit@mayo.edu (A. Agarwal).

<https://doi.org/10.1016/j.radcr.2022.05.077>

1930-0433/© 2022 The Authors. Published by Elsevier Inc. on behalf of University of Washington. This is an open access article under the CC BY-NC-ND license (<http://creativecommons.org/licenses/by-nc-nd/4.0/>)

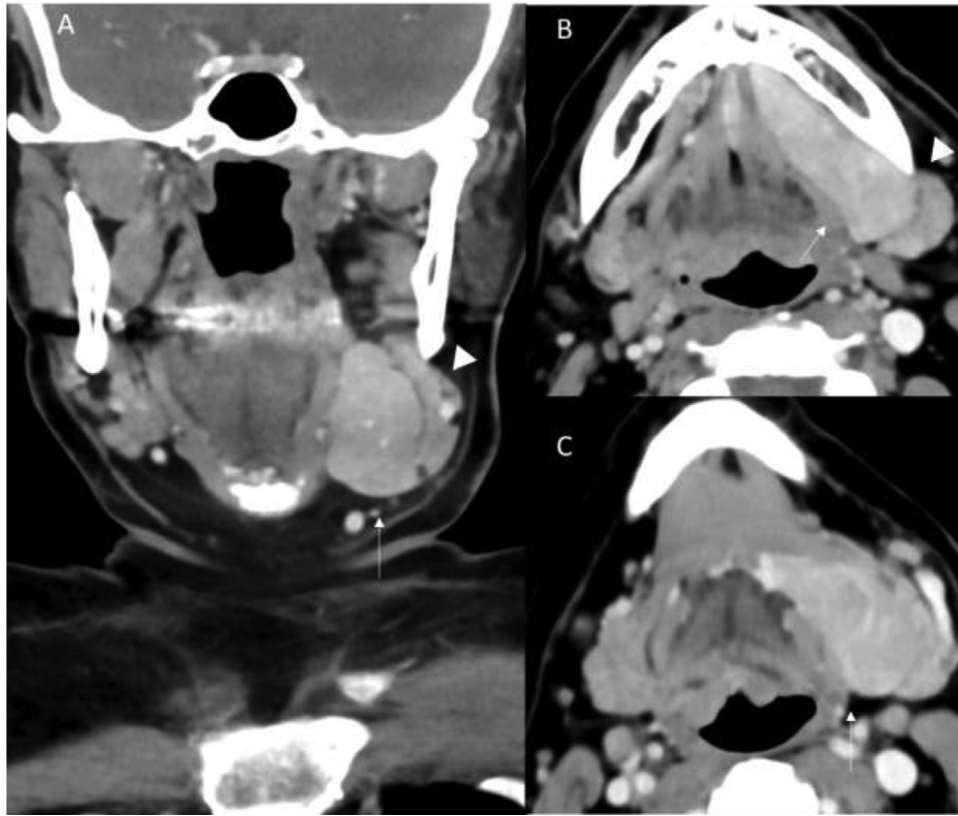


Fig. 1 – Coronal (A) and axial (B, C) contrast-enhanced CT neck images depicts the well-circumscribed homogenous mass (arrows) along the left floor of mouth extending into submandibular region. The lesion can be seen separately from the submandibular gland (arrowhead).

initially suspected as a submandibular tumor. We aim from our review to highlight that extra-cardiac rhabdomyoma can mimic other tumors in this anatomical site. We also aim to highlight that extra-cardiac rhabdomyoma should be taken into consideration as a differential diagnosis for the masses in these anatomical sites.

Case report

A 66-year-old woman presents to the Otolaryngology outpatient clinic with a left neck mass. According to the patient, the lesion has been there for about a year and was slowly growing. She underwent a facelift few years back and presumed the bulge in her left neck to be fatty tissue. On clinical examination, a nontender soft mass was palpable along the left floor of mouth and submandibular region. The neck was otherwise unremarkable on clinical examination and flexible laryngoscopy was also normal. CT of the neck with contrast was subsequently performed. The study revealed homogeneously enhancing mass involving the left sublingual gland, conforming to the glandular morphology, extending across the posterior mylohyoid sling into the submandibular space (Fig. 1A-C). Similar density mass was also noted in the right thyroid bed with infrasternal extension, along the median raphe of the tongue and the left parapharyngeal fat space (Fig. 2A, B). The thyroid region mass extended into the superior medi-

astinum. All these lesions were exactly similar in morphology and enhancement pattern and were highly suggestive of a common etiology. Given the multifocality and homogenous enhancement the primary imaging differentials included lymphoproliferative conditions and inflammatory conditions like IgG4 disease. Ultrasound-guided biopsy (fine-needle aspiration) of the dominant lesion in the left neck revealed adult-type rhabdomyoma and was negative for malignancy. Excisional biopsy of the dominant submandibular lesion was subsequently performed. The final path confirmed the finding on FNA and revealed uniform polygonal cells resembling mature skeletal muscle fibers with abundant, vacuolated eosinophilic cytoplasm and uniform nuclei consistent with AER (Fig. 3). The clinical team decided to follow-up the other lesions through routine CT scans.

Discussion

Rhabdomyomas are rare benign tumors originating from skeletal muscles and are broadly divided into cardiac and extracardiac types [1]. The cardiac type is far more common than the extracardiac types, and is usually seen in the pediatric age group, classically with tuberous sclerosis. These usually regress spontaneously and are believed to be hamartomas rather than true neoplasm. Extracardiac rhabdomyoma are further divided into three subtypes based on the histo-

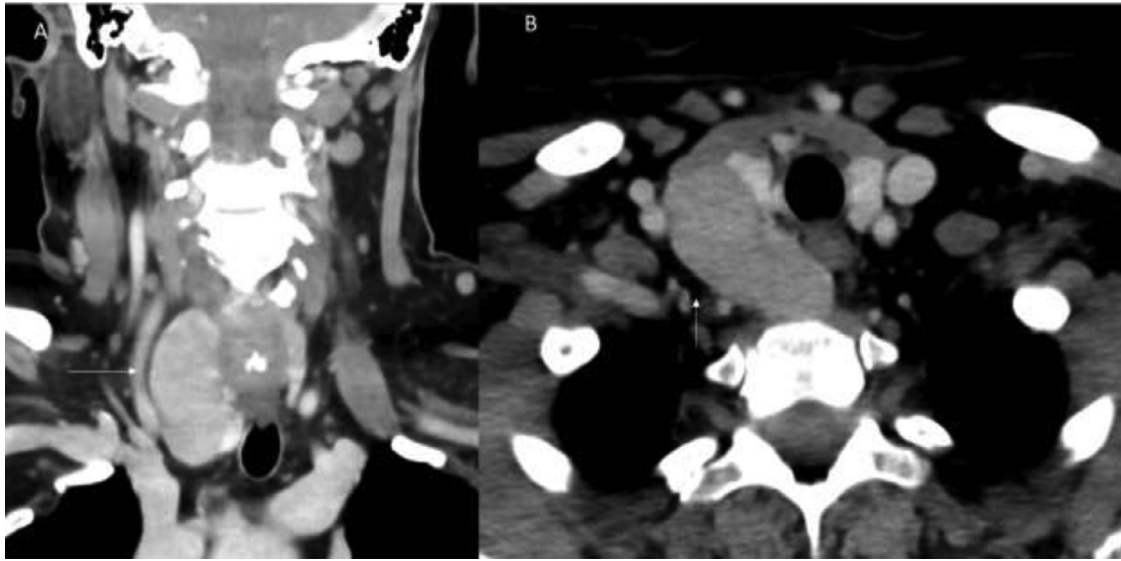


Fig. 2 – Coronal (A) and axial (B) contrast-enhanced CT neck images depicts the well-circumscribed homogenous mass (arrows) in the right thyroid region displacing the gland medially, extending into the mediastinum.

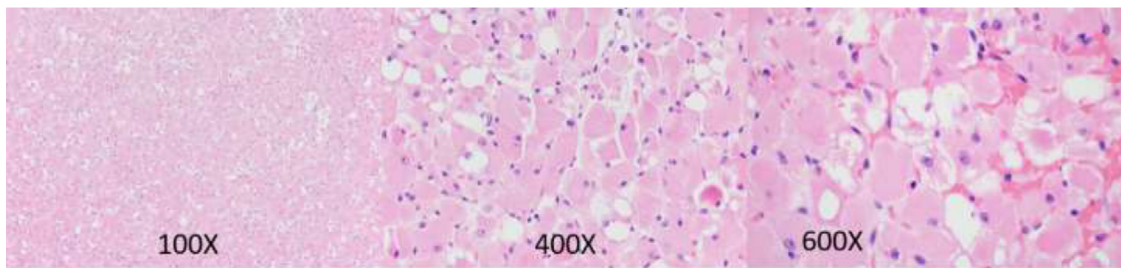


Fig. 3 – Adult rhabdomyoma showing uniform polygonal cells (100X) resembling mature skeletal muscle fibers with abundant, vacuolated eosinophilic cytoplasm and uniform nuclei. Higher (400X) magnification showing cross striations (center field) and nuclei with conspicuous nucleoli. High magnification (600X) view showing characteristic “spider cell” of rhabdomyoma with wispy cytoplasmic processes radiating from central nucleus.

logical findings and age, into adult rhabdomyomas (AER), fetal, and genital rhabdomyomas. The immunohistochemical findings of these lesions include positivity for muscle specific actin and desmin. Although the histological features are well-defined, many authors believe them to represent hamartomas rather than true neoplasm [5–7]. Recent literature on the cytogenetics of these tumors, however, are more suggestive of neoplastic etiology. The AER subtype of tumors is mainly detected in the head and neck region (more than 90% of case). As these lesions arises from the muscle of the third and fourth branchial arches, it has a strong preference for the head and neck region [10]. This tumour is more common in men aged 55–61 and are multifocal in around 15% of patients. The tumour usually appears as a painless, slow-growing lump. Some authors, however, believe that the manifestations of rhabdomyoma are dependent on the tumor’s location. Compressive manifestations such as globus, hoarseness, or dysphagia may be present in parapharyngeal rhabdomyomas [11]. The tumor can develop in the oral cavity, submandibular region, tongue, pharynx, larynx, soft palate, thyroid, cheek, tonsillar region, and parapharyngeal space, among other

places in the head and neck. It might also appear as a single lesion, or as multinodular or multifocal lesions [12,13]. Imaging work-up of these tumors is best done with MRI which has far superior soft-tissue demarcation as compared to CT scan. MR findings include enhancing well-circumscribed lesions which are isointense to muscle on T1-weighted images and iso- to hyperintense on T2. CT findings are much better described in literature given the widespread availability of the imaging modality and include homogenous enhancing pattern with the absence of any infiltrative features [13,14]. Given the multifocal nature of these tumors which conform to the neck spaces and the absence of invasive features, these tumors strongly mimic lymphoma and differentiation is not possible on imaging alone. Inflammatory condition like IgG4 can also have similar findings, however they tend to involve and enlarge the normal structures like the salivary gland rather than presenting as de-novo masses. As these tumors are well-circumscribed, surgical resection is the easiest and the most common treatment approach. Variable rates of recurrence are described ranging from 16% to 42%, however these never undergo malignant transformation. Given the

slow-growing nature and absence of malignant potential, these can be followed up on imaging if there are found incidentally with no significant symptoms [15].

Conclusion

Adult extracardiac rhabdomyomas are rare benign tumors classically seen in the head and neck region. Although rare, these tumors have a striking similarity on imaging with the much more common lymphoproliferative conditions like lymphoma. Although demarcation is limited on imaging alone, the slow rate of growth of AER can be a useful factor, especially if these are incidental finding on imaging with stable course. The final diagnosis is easily made through biopsy with characteristic findings on histology and immunohistochemistry. Treatment of these lesions is variable ranging from imaging follow-up to complete excision.

Financial disclosures

None.

Patient consent

We acknowledge that our institution does not require IRB approval for case reports or image submissions. Written patient consent has been obtained as per Institutional policy. All the images included are non-identifiable images consistent with Elsevier policies.

REFERENCES

- [1] Black M, Wei XJ, Sun W, et al. Adult rhabdomyoma presenting as thyroid nodule on fine-needle aspiration in patient with Birt-Hogg-Dubé syndrome: case report and literature review. *Diagnostic Cytopathol* 2020;48(6):576–80.
- [2] Andrade N, Gandhewar T, Aggarwal N, Mathai P. Adult rhabdomyoma of the tongue in a child: report of a case and a literature appraisal. *Contempor Clin Dentistry* 2018;9(1):2.
- [3] Cai Z, Thomas J, Alava I, et al. Fetal type rhabdomyoma of the soft palate in an adult patient: report of one case and review of the literature. *Head Neck Pathol* 2019;13(2):182–7.
- [4] Cameron B, Hannabass K, Kanungo A, Chhetri D. Adult-type rhabdomyoma of the omohyoid muscle. *Case Rep Otolaryngol* 2019;2019:4706582.
- [5] Svobodov A, Glushko L, Ergashov A. Surgical treatment of primary cardiac tumors in children systematic review and meta-analysis. *Pediatric Cardiology* 2022;3:1–6.
- [6] Marletta S, Caliò A, Fioravanzo A, et al. Recurrent primary endobronchial fetal rhabdomyoma: a case report and literature review. *Pathologica* 2021;113(6):436.
- [7] Walker WP, Laszewski MJ. Recurrent multifocal adult rhabdomyoma diagnosed by fine-needle aspiration cytology: report of a case and review of the literature. *Diagn Cytopathol* 1990;6:354–8.
- [8] McGregor DK, Krishnan B, Green L. Fine-needle aspiration of adult rhabdomyoma: a case report with review of the literature. *Diagnostic Cytopathol* 2003;28(2):92–5.
- [9] Di Sant'Agnes PA, Knowles DM. Extracardiac rhabdomyoma: a clinicopathologic study and review of the literature. *Cancer* 1980;46:780–9.
- [10] Bellis D, Torre V, Nunziata R, et al. Submandibular rhabdomyoma: a case report. *Acta Cytol* 2006;50:557–9.
- [11] Hakim I, Yunus MRM. Extracardiac rhabdomyoma mimicking plunging ranula. *Medeni Med J* 2020;35(3):271–5.
- [12] Helmberger R, Stringer S, Mancuso A. Rhabdomyoma of the pharyngeal musculature extending into the prestyloid parapharyngeal space. *AJNR Am J Neuroradiol* 1996;17(6):1115–18.
- [13] Khalaf MG, Haddad R, Akiki M, Khazen J, Melkane AE. Multifocal adult rhabdomyoma of the head and neck: case report and systematic review of the literature. *Int J Oral Maxillofacial Surg* 2021;50(3):327–34.
- [14] de Trey LA, Schmid S, Huber GF. Multifocal adult rhabdomyoma of the head and neck manifestation in 7 locations and review of the literature. *Case Rep Otolaryngol* 2013;2013:758416.
- [15] Willis J, Abdul-Karim FW, di Sant'Agnes PA. Extracardiac rhabdomyomas. *Semin Diagn Pathol* 1994;11(1):15–25.

[1] Black M, Wei XJ, Sun W, et al. Adult rhabdomyoma presenting as thyroid nodule on fine-needle aspiration in