

# Nasolacrimal Duct Mucocele: Case Report and Literature Review

Fernanda Carneiro Corujeira de Britto<sup>1</sup> Vitor Veloso Rosier<sup>1</sup> Tovar Vicente Luz<sup>2</sup>  
Raquel Crisóstomo Lima Verde<sup>2</sup> Clara Mônica Figueiredo de Lima<sup>3</sup> Marcus Miranda Lessa<sup>4</sup>

<sup>1</sup>Department of Otolaryngology, Hospital Universitário Professor Edgard Santos–Universidade Federal da Bahia (HUPES-UFBA), Salvador, BA, Brazil

<sup>2</sup>Department of Otolaryngology, Endoscopic Sinus Surgery, HUPES-UFBA, Salvador, BA, Brazil

<sup>3</sup>Department of Otolaryngology, Health Sciences, HUPES-UFBA, Salvador, BA, Brazil

<sup>4</sup>Department of Otolaryngology, Universidade de São Paulo, São Paulo, SP, Brazil; HUPES-UFBA, Salvador, BA, Brazil

Address for correspondence Fernanda Carneiro Corujeira de Britto, MD, Hospital Universitário Professor Edgard Santos–Universidade Federal da Bahia, Ambulatório Magalhães Neto Rua Padre Feijó, 240, 2° andar (Amb. de Otorrino), Canela, Salvador, BA CEP: 40.110-170 (e-mail: nancarneiro@gmail.com).

Int Arch Otorhinolaryngol 2015;19:96–98.

## Abstract

**Introduction** Mucoceles are benign expansive cystic formations, composed of a mucus-secreting epithelium (respiratory or pseudostratified epithelium). Nasolacrimal mucocele occurs in a small proportion of children with nasolacrimal duct obstruction and is characterized by a cystic mass in the medial canthus with dilation of the nasolacrimal duct; although dacryocystoceles are rare in adults, they have been reported in patients with trachoma.

**Objective** Discuss clinical aspects, diagnosis, and therapeutic management of mucocele of nasolacrimal duct based on literature review.

**Resumed Report** The authors report a case of bilateral congenital nasolacrimal duct cysts in a 30-year-old man, identified as a tumor in the topography of both lacrimal sacs since birth without associated symptoms. The patient underwent successive surgical treatments, leading to recurrence of the tumor at the right side and recurrent local infections.

**Conclusion** Endoscopic dacryocystorhinostomy has been increasingly used with good results and success rates similar to the external access.

## Keywords

- ▶ mucocele
- ▶ nasolacrimal duct
- ▶ dacryocystorhinostomy

## Introduction

Nasolacrimal duct obstruction (NLDO) is a common congenital abnormality that occurs in ~30% of neonates (range 6 to 84%).<sup>1</sup> Only 2 to 4% of these children become symptomatic, and most cases of NLDO resolve spontaneously in the first year of life.<sup>1–4</sup>

Dacryocystocele or congenital mucocele of nasolacrimal duct is a relatively rare variant of NLDO, representing ~0.1% of children with congenital obstruction, and results from the coexistence of a distal and a proximal obstruction.<sup>1,5</sup>

Nasolacrimal duct mucocele typically presents as a bulging in the lower medial canthus of the eye, associated with

epiphora. The cyst may extend inferiorly, herniating into the nasal cavity.

In this article, we report a case of congenital nasolacrimal duct mucocele, which recurred after surgery and was treated with endoscopic approach, followed by a literature review.

## Case Report

The patient was a 30-year-old man with a history of bilateral congenital cyst of nasolacrimal duct diagnosed by the presence of a bulge in both lacrimal sac topographies since birth, without associated symptoms. He underwent surgery on the left side at 9 years of age and on the right side at 21 years of

received  
June 25, 2013  
accepted  
November 18, 2013  
published online  
February 13, 2014

DOI <http://dx.doi.org/10.1055/s-0034-1366978>.  
ISSN 1809-9777.

Copyright © 2015 by Thieme Publicações Ltda, Rio de Janeiro, Brazil

License terms



age, but the tumor recurred on the right side, without tearing, pain, discharge, or other symptoms. In subsequent evaluation with an ophthalmologist, a lack of upper and lower right lacrimal ducts was identified and indicated reconstruction surgery lacrimal spot, which was done in December 2007. However, he developed ipsilateral epiphora later, requiring another two procedures—dacryocystectomy in July 2011 and August 2011—but without success, leading to recurrent local infections. He denied loss of visual acuity or nasal symptoms during the whole period. After the last procedure, computed tomography (CT) showed a cystic expansion in the right lacrimal sac topography and dilatation of the bony canal of the nasolacrimal duct (—Figs. 1 and 2).

The patient was then referred for evaluation by the rhinology group of Hospital Universitário Professor Edgard Santos (Salvador, Brazil); nasal endoscopy showed no alterations. He had endoscopic dacryocystorhinostomy in December 2011, with confection of mucosal flap and osteotomy of nasolacrimal bone, noting that the lacrimal sac was already opened with drainage of thick purulent secretion. The patient remains asymptomatic and without clinical signs 1 year and 8 months after surgery.

## Discussion

The nasolacrimal duct is formed by canalization of the caudal extremity of an epithelial cord derived from the ectoderm in the naso-optic fissure, which is often not completed at birth. NLDO at birth is common and usually asymptomatic or presents with epiphora in neonates and infants, which resolves spontaneously in most cases.<sup>2</sup> Generally, it results

in blockage in the distal end of the nasolacrimal system, at the Hasner valve level, although the blockage can also occur at the lacrimal spot.<sup>2,3,5</sup>

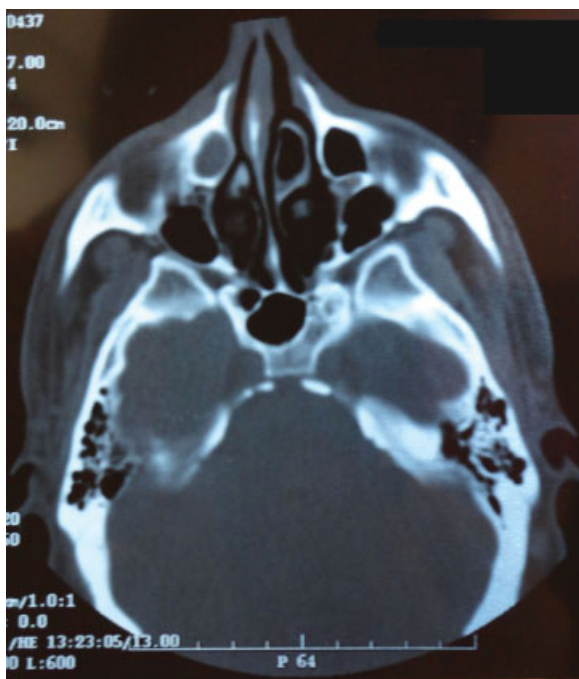
Nasolacrimal mucocele, on the other hand, occurs in a small proportion of children with NLDO, when there is a distal obstruction (distal membrane perforation failure) associated with a proximal obstruction, which can be functional or mechanical.<sup>2,3,5</sup> It is characterized by a cystic mass at the medial canthus with dilation of the nasolacrimal duct that can, rarely, extend into nasal cavity.<sup>2,3,6</sup> Patients with dacryocystoceles may present with local infection or difficult breathing or breast-feeding in the breast ipsilateral to the mucocele.<sup>5</sup>

Although dacryocystoceles are rare in adults, recurrent chronic keratitis of bacterial etiology (*Chlamydia trachomatis*) has been reported in patients with trachoma, which, due to repeated infections, can lead scarring of the conjunctiva and even to lacrimal obstruction.<sup>7</sup>

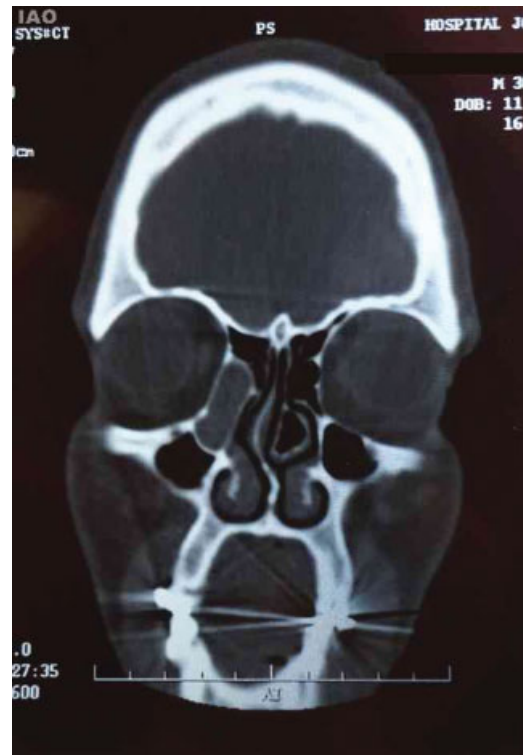It is believed that a mixture of mesodermal cells, mucus, amniotic fluid, tears, and colonizing bacteria compose the contents of the lacrimal sac, causing distention of the lacrimal system seen in dacryocystocele.<sup>7</sup>

Encephalocele, hemangioma, dermoid cysts, and nasal gliomas may present similarly and must be considered in the differential diagnosis.<sup>5</sup>

Dacryoceles appear as rounded, well-circumscribed lesions centered in the region of lacrimal sac in CT and magnetic resonance imaging (MRI). In CT, the density of



**Fig. 1** Computed tomography of the paranasal sinuses, axial section, in bone window, showing hypodense cystic lesion in the right nasolacrimal duct topography.



**Fig. 2** Computed tomography of the paranasal sinuses, coronal section, in bone window, showing hypodense cystic lesion in the right nasolacrimal duct topography.

the lesion is not homogeneous when infected. In MRI, the dacryoceles appear hypointense on T1 images and hyperintense on T2 images. If infected, it may show a peripheral contrast uptake.<sup>8</sup>

Conservative treatment of dacryocystocele is based on a short course of topical antibiotics, warm compresses, and local massage three times a day, with a reported resolution rate of 76%. Dacryocystitis may occur within a few days or weeks and requires intravenous antibiotics to prevent sepsis. Most ophthalmologists recommend early surgical intervention in cases of respiratory compromise, dacryocystitis, cellulitis, large dacryocystoceles inducing astigmatism, or recurrent dacryocystoceles and in cases of failed conservative strategies.<sup>1,9,10</sup> In cases of infection or respiratory compromise, drainage is required 24 to 48 hours after the start of antibiotic therapy.<sup>6</sup>

Dacryocystorhinostomy is a surgery commonly performed, in which a fistula is created between the lacrimal sac and the nasal cavity to relieve the epiphora caused by NLDO. External access is still noted as the most effective procedure by many ophthalmologists. The success rates vary from 75 to 95% in external access and 60 to 90% in endoscopic approach. The most common cause of failure in endoscopic surgery is obstruction of the new ostium by granulation or scar tissue.<sup>11–13</sup>

However, recent studies have shown better results with endoscopic dacryocystorhinostomy with confection mucosal flap in front of the middle turbinate and subsequent lateral wall osteotomy, with similar rates compared with the external access. The endoscopic technique has advantages such as no scars, less surgical trauma, less bleeding, a quicker return to work, and preservation of the medial canthus structure, providing sustainability of lacrimal pump mechanism.<sup>11,14</sup>

The success of surgery depends on creating a large bony ostium and preventing closure of this stoma. Many techniques have been described to avoid or prevent obstruction. Use of mucosal flaps after wide resection of bone surrounding the sac is one technique used to prevent granulation tissue and narrowing of the canal, with good results according to the literature.<sup>11,14,15</sup>

The main advantage of external dacryocystorhinostomy (DCR) is visualization of the anatomy that facilitates the precise removal of bone in the lacrimal fossa and enables the exact anastomosis of the nasal mucosa and lacrimal sac. Nevertheless, an intranasal component that is not recognized prior to the external access increases the chance of treatment failure if the catheter does not pass over the wall of the cyst.<sup>5,11</sup>

## Conclusion

Nasolacrimal duct mucocele is a rare occurrence; however, it carries a risk of major complications (local infection, cellulitis, respiratory distress, etc.). Surgery (dacryocystorhinostomy) is considered as the definitive treatment, and external access is still the most widespread and commonly used approach by ophthalmologists. However, the interest in an endoscopic nasal approach has increasingly grown as recent studies have shown good results with this technique, with similar success rates between the two types of procedures.

## References

- Leonard DS, O'Keefe M, Rowley H, Hughes JP. Neonatal respiratory distress secondary to bilateral intranasal dacryocystoceles. *Int J Pediatr Otorhinolaryngol* 2008;72(12):1873–1877
- Gujar SK, Gandhi D. Congenital malformations of the orbit. *Neuroimaging Clin N Am* 2011;21(3):585–602, viii
- Hulka GF, Kulwin DR, Weeks SM, Cotton RT. Congenital lacrimal sac mucoceles with intranasal extension. *Otolaryngol Head Neck Surg* 1995;113(5):651–655
- Yee SW, Seibert RW, Bower CM, Glasier CM. Congenital nasolacrimal duct mucocele: a cause of respiratory distress. *Int J Pediatr Otorhinolaryngol* 1994;29(2):151–158
- Wong RK, VanderVeen DK. Presentation and management of congenital dacryocystocele. *Pediatrics* 2008;122(5):e1108–e1112
- Koch BL. Case 73: Nasolacrimal duct mucocele. *Radiology* 2004;232(2):370–372
- Bhaya M, Meehan R, Har-El G. Dacryocystocele in an adult: endoscopic management. *Am J Otolaryngol* 1997;18(2):131–134
- Castillo BV Jr, Kaufman L. Pediatric tumors of the eye and orbit. *Pediatr Clin North Am* 2003;50(1):149–172
- Edmond JC, Keech RV. Congenital nasolacrimal sac mucocele associated with respiratory distress. *J Pediatr Ophthalmol Strabismus* 1991;28(5):287–289
- Paysse EA, Coats DK, Bernstein JM, Go C, de Jong AL. Management and complications of congenital dacryoceles with concurrent intranasal mucocele. *J AAPOS* 2000;4(1):46–53
- Kansu L, Aydin E, Avci S, Kal A, Gedik S. Comparison of surgical outcomes of endonasal dacryocystorhinostomy with or without mucosal flaps. *Auris Nasus Larynx* 2009;36(5):555–559
- Lueder GT. Endoscopic treatment of intranasal abnormalities associated with nasolacrimal duct obstruction. *J AAPOS* 2004;8(2):128–132
- Fayet B, Racy E, Assouline M. Complications of standardized endonasal dacryocystorhinostomy with unciformectomy. *Ophthalmology* 2004;111(4):837–845
- Tsirbas A, Wormald PJ. Endonasal dacryocystorhinostomy with mucosal flaps. *Am J Ophthalmol* 2003;135(1):76–83
- Çukurova I, Caner Mercan G, Çetinkaya E, et al. Endoscopic dacryocystorhinostomy: outcomes using mucosal flap preserving technique. *Eur Arch Otorhinolaryngol* 2013;270(5):1661–1666