



Contents lists available at ScienceDirect

AACE Clinical Case Reports

journal homepage: www.aaceclinicalcasereports.com

Case Report

Hypercalcemia of Malignancy Attributed to Cosecretion of PTH and PTHrP in Lung Adenocarcinoma

Jeffrey M. Kroopnick, MD^{1,*}, Ubaldo Martinez-Outschoorn, MD²,
Madalina Tuluc, MD, PhD³, Caroline S. Kim, MD⁴¹ Division of Endocrinology, Diabetes and Nutrition, University of Maryland School of Medicine, Baltimore, Maryland² Department of Medical Oncology, Jefferson University Hospital, Thomas Jefferson University, Philadelphia, Pennsylvania³ Department of Pathology, Anatomy, and Cell Biology, Jefferson University Hospital, Thomas Jefferson University, Philadelphia, Pennsylvania⁴ Division of Endocrinology, Diabetes and Metabolism, Perelman School of Medicine at the University of Pennsylvania, Philadelphia, Pennsylvania

ARTICLE INFO

Article history:

Received 15 October 2020

Received in revised form

29 December 2020

Accepted 2 January 2021

Available online 19 January 2021

Key words:

cosecretion of PTH and PTHrP

hypercalcemia of malignancy

ectopic PTH

Hypercalcemia of malignancy

ABSTRACT

Introduction: Hypercalcemia of malignancy (HCM) portends a very poor prognosis, and no established guidelines exist regarding its management. Most instances of HCM are due to local osteolysis or secretion of parathyroid hormone related-peptide, while less than 1% of all cases are due to ectopic secretion of parathyroid hormone.

Case Report: We present an unusual case of HCM due to proposed cosecretion of both parathyroid hormone and parathyroid hormone-related protein in a 36-year-old man with a poorly differentiated lung adenocarcinoma. The patient's hypercalcemia was refractory to conventional measures, including intravenous bisphosphonate therapy (zoledronic acid), and was improved with administration of denosumab.

Conclusion: This is the youngest and first case of hypercalcemia of malignancy attributed to cosecretion of PTH and PTHrP from an adenocarcinoma. In refractory cases of HCM, denosumab is a potential option when other conventional measures are unsuccessful.

Published by Elsevier Inc. on behalf of the AACE. This is an open access article under the CC BY-NC-ND license (<http://creativecommons.org/licenses/by-nc-nd/4.0/>).

Introduction

We describe an interesting case of severe refractory hypercalcemia attributed to ectopic production of parathyroid hormone (PTH) and humoral hypercalcemia of malignancy in a young patient with poorly differentiated lung adenocarcinoma. Differential diagnoses of concurrent elevated PTH and parathyroid hormone-related peptide (PTHrP) are also discussed.

Case Report

Case Presentation

A 36-year-old man with stage IV poorly differentiated lung adenocarcinoma with known brain metastases presented to our

Abbreviations: 1,25 vitamin D, 1,25-dihydroxy vitamin D; HCM, hypercalcemia of malignancy; HD, hospital day; PTH, parathyroid hormone; PTHrP, parathyroid hormone-related peptide; ZA, zoledronic acid.

* Address correspondence and reprint requests to Dr. Jeffrey M. Kroopnick, Division of Endocrinology, Diabetes and Nutrition, University of Maryland School of Medicine, 827 Linden Avenue, Baltimore, MD 21201.

E-mail address: jkroopnick@som.umaryland.edu (J.M. Kroopnick).

hospital with lethargy and a fall. On admission he had a severely elevated serum calcium of 21.3 mg/dL (ref 8.9–10.3) and an ionized calcium of 2.72 mmol/L (ref 1.0–1.25). His serum phosphorus was low at 1.3 mg/dL (ref 2.4–4.7), serum creatinine was 1.30 mg/dL (ref 0.64–1.27), and his electrocardiogram showed a shortened corrected QT interval. Three weeks prior to admission, his calcium was normal, ranging from 8.7 to 9.5 mg/dL, and approximately 10 days prior to admission his renal function was normal (creatinine 0.79), and he received his first round of chemotherapy. He initially received aggressive intravenous fluid hydration, calcitonin, and doses of zoledronic acid (ZA) on hospital day (HD) #1 and #9 (4 mg IV). After his first dose of ZA, his nadir calcium was 11.0 mg/dL on HD#7 but then rose to 12.8 mg/dL before receiving a second dose on HD#9. Further workup revealed elevated PTH levels of 33.2, 55.4, and 133.0 pmol/L (ref 1.3–6.8) on HD#2, 6, and 9, respectively. He had a reduced 25-hydroxyvitamin D of 7 ng/mL (ref 25–80) and 1,25-dihydroxy vitamin D (1,25 vitamin D) of 14 pg/mL (ref 15–75), both measured on HD#4. Interestingly, his PTHrP was elevated at 8.2 pmol/mL (ref 0–2.3) on HD#4. No parathyroid adenoma was detected on magnetic resonance imaging neck, 99mTc-sestamibi scan, or parathyroid ultrasound. Imaging revealed widespread

<https://doi.org/10.1016/j.aace.2021.01.003>

2376-0605/Published by Elsevier Inc. on behalf of the AACE. This is an open access article under the CC BY-NC-ND license (<http://creativecommons.org/licenses/by-nc-nd/4.0/>).

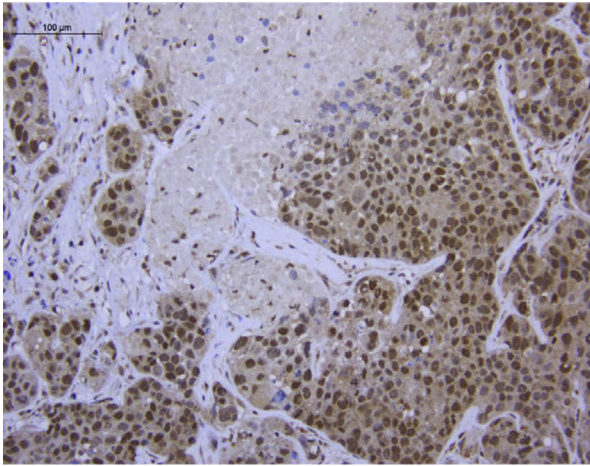


Fig. 1. Tissue from a brain metastasis resected a month prior to admission, showing positive nuclear staining for PTHrP (dark brown). Paraffin sections were dewaxed, rehydrated, and antigen retrieval was performed in 10 mM sodium citrate, pH 6.0, for 10 minutes using an electric pressure cooker. Sections were cooled, blocked with 3% hydrogen peroxide, then for endogenous biotin (Biocare Medical Kit #AB972), and incubated with 10% goat serum. Rabbit polyclonal antibody to PTHrP (sc-20728; Santa Cruz Biotechnology, Santa Cruz, CA) was used at 1:200 with overnight incubation at 4°C. PTHrP antibody binding was detected using the Vectastain Elite ABC HRP Kit (Vector Labs, Burlingame, CA) and developed with Dako Liquid DAB substrate (Dako Corp, Carpinteria, CA). PTHrP = parathyroid hormone-related peptide.

abdominal metastases and small lytic lesions. Pathology from his craniotomy stained negative for PTH but positive for PTHrP (Fig. 1). He also received one dose of denosumab, 120 mg on HD#12, after which his serum calcium normalized. However the patient elected for hospice care and expired. Figure 2 illustrates the patient's calcium trend and the various interventions he received during his hospitalization.

Discussion

Hypercalcemia of malignancy (HCM) portends a very poor prognosis and is an oncologic emergency that can occur in 10% to 20% of adult patients with cancer.¹

The Table summarizes the multiple mechanisms of HCM, including local osteolysis, humoral hypercalcemia of malignancy (ie, PTHrP), calcitriol, and ectopic PTH secretion.² More specifically, tumor cells in bone secrete cytokines and growth factors that stimulate release of receptor activator of nuclear factor kappa-B ligand from osteoblasts, which activates osteoclasts. Secondly, bone resorption itself may promote release of growth factors that lead to tumor growth and enhanced survival. PTHrP secreted by tumor cells mimic PTH by binding the common PTH/PTHrP receptor to increase bone resorption and renal calcium retention.^{1,3}

To our knowledge, only 3 case reports exist of patients with cosecretion of PTH and PTHrP. These patients were all at least 70 years of age and had either gastric, squamous cell, or transitional cell carcinomas.^{4–6} Imaging and/or autopsy revealed no abnormal or ectopic parathyroid tissue.^{4–6} Our patient's acute onset and severe degree of hypercalcemia in the setting of a lack of abnormal parathyroid tissue on imaging is most consistent with a paraneoplastic process. The degree of PTH elevation could not be solely related to known causes of secondary hyperparathyroidism, including vitamin D deficiency, administration of antiresorptive agents, or his minimally reduced glomerular filtration rate. While ZA has been purported to cause a mild secondary hyperparathyroidism, as mentioned in a case report from Sayn and Yazici,⁷ in which the PTH was approximately 4 times the upper limit of

normal after multiple doses of ZA in a patient with metastatic intermediate-grade lymphoma, it is thought that this is related to the hypocalcemia induced by osteoclast inhibition. In our case, ZA was administered less than 24 hours prior to our patient's first PTH measurement, and his degree of hyperparathyroidism, approximately 20 times the upper limit of normal, is thus not consistent with that following antiresorptive therapy, especially given our patient was persistently hypercalcemic following only 1 dose of ZA. Therefore, his HCM could be attributed to 3 likely mechanisms: local osteolysis, PTHrP, and ectopic PTH cosecretion.

PTHrP resembles the N-terminal sequence of PTH and thus can bind to the type 1 PTH receptor. Given this, PTHrP can increase renal tubular reabsorption of calcium, increase renal urinary excretion of phosphorus, and also increase expression of receptor activator of nuclear factor kappa-B ligand on osteoblasts. However, unlike PTH, PTHrP does not increase 1,25 vitamin D levels, so enhanced reabsorption of intestinal calcium and phosphorus does not occur.⁸ This, in conjunction with his vitamin D deficiency, likely explains our patient's low 1,25 vitamin D. Only 1 of the reported cases of cosecretion of PTH and PTHrP measured the 1,25 vitamin D level,⁵ which was low, and our case also documents the predominant effect of PTHrP on 1,25 vitamin D regulation. While the pathology available from his craniotomy did not stain positive for PTH, it is unclear if all tumor cells gain the ability to cosecrete both hormones or if clonal heterogeneity exists. Our patient had widespread metastatic disease, which was not evaluated pathologically and could account for the ectopic PTH production.

No consensus guidelines exist for the management of HCM, but a standard approach involves cessation of any medications that may promote hypercalcemia, ambulation to prevent immobility, intravenous fluids, and antiresorptive therapy. Pharmacologic options include subcutaneous or intravenous calcitonin and intravenous bisphosphonates to inhibit osteoclast resorption.^{9,10} Calcitonin lowers serum calcium levels within hours, but its use is limited to 48 to 72 hours due to tachyphylaxis.^{10,11} The intravenous bisphosphonate ZA can take up to 2 days to exert its effects.¹¹ These are temporizing measures to allow time for management of the underlying malignancy with systemic therapy, radiation, and/or surgery. Glucocorticoids are first-line treatment in calcitriol-mediated hypercalcemia; our patient received dexamethasone prior to admission and development of hypercalcemia. Given the patient's known brain metastases, he remained on dexamethasone throughout his hospital course. Despite the patient having received all of the aforementioned measures, his calcium failed to remain normal.

Retreatment with ZA in HCM may be as frequent as every 3 to 4 weeks. However, in our case, there was rebound hypercalcemia 8 days following the first administration of ZA, and the patient's calcium did not normalize following the second dose, all in the setting of deteriorating mental status (Fig. 1). Resistance to bisphosphonates may occur in humoral HCM because bisphosphonates are unable to inhibit PTHrP-induced calcium reabsorption in the kidneys.³

Studies suggest that denosumab, a monoclonal antibody that inhibits the signaling of receptor activator of nuclear factor kappa-B ligand, a key factor for osteoclast differentiation and activation, provides benefit in cases of bisphosphonate-refractory hypercalcemia.^{12,13} The calcimimetic agent, cinacalcet, is approved for treatment of both benign parathyroid disorders and parathyroid carcinoma. There are 2 reports in the literature on the use of cinacalcet for a tumor producing ectopic PTH.^{2,14} Asonitis et al³ described a patient with HCM due to metastatic estrogen receptor positive mammary carcinoma, with peak serum calcium of 14 mg/dL and poorly responsive to aggressive fluid hydration, furosemide, calcitonin, ZA, and denosumab. Cinacalcet was added in

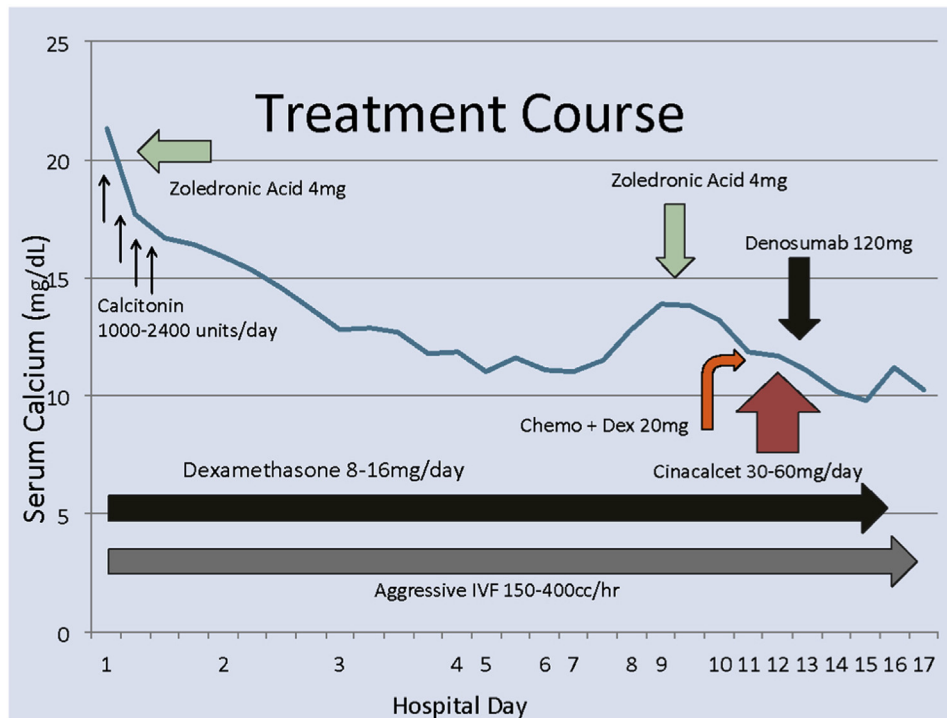


Fig. 2. Time course of serum calcium levels prior to and in response to different treatments during hospitalization. The serum calcium trend is illustrated graphically with the various treatment measures the patient received throughout. Please note that the patient received doses of calcitonin on HD#10, 11, 12, 14, and 15, which are not represented in this figure. HD = hospital day.

Table
Overview of the Mechanisms and Frequency of Hypercalcemia of Malignancy

| Causes | Local osteolysis | Calcitriol (1,25-[OH] ₂ vitamin D) | PTHrP | Ectopic PTH |
|-------------------------------|---|---|--|--|
| Types of malignancy | Breast, lung, myeloma, renal | Lymphoid tumors | Breast, bladder, ovarian, renal, squamous cell, non-Hodgkin lymphoma | Lung, ovarian, pancreatic, thyroid, transitional cell |
| Frequency mechanism of action | 20% Cytokines and/or chemokines leading to calcium release from bone | <1% Acts on bowel and kidneys to absorb and reabsorb calcium, respectively | 80% Renal reabsorption of calcium, osteoclast stimulation | <1% Acts on 1- α hydroxylase in kidney, stimulates osteoclasts (calcium release) |
| Expected laboratory data | PTH low PTHrP normal 1,25-(OH) ₂ vitamin D variable | PTH low Phosphorus high PTHrP normal 1,25-(OH) ₂ vitamin D high | PTH low PTHrP high 1,25-(OH) ₂ vitamin D low | PTH high PTHrP normal 1,25-(OH) ₂ vitamin D high |
| Pharmacologic options | Bisphosphonate denosumab | Glucocorticoids | Bisphosphonate denosumab | Bisphosphonate denosumab |

Abbreviations: PTH = parathyroid hormone; PTHrP = parathyroid hormone-related peptide.
Note: Adapted from reference 2.

addition to monthly denosumab, and her serum calcium normalized to 9.6 mg/dL approximately 4 weeks after initiation of the calcimimetic. A dose of denosumab, 120 mg, which has a median time to response of 9 days,¹⁰ was administered to our patient on HD#12 with improvement of his serum calcium.

Rare cases of primary hyperparathyroidism due to an adenoma with hypercalcemia of malignancy have been reported, but while the PTH is not suppressed, this degree of elevation is atypical unless there is parathyroid cancer; further, these patients had imaging confirmation of a parathyroid adenoma.^{15–17} Moreover, >90% of patients with primary hyperparathyroidism have undetectable levels of PTHrP and, even further, the specific detection of PTH has been significantly enhanced due to the 2-site radioimmunoassay, so cross-reactivity with PTHrP is minimized, if not absent.^{15,16,18,19} Outside of parathyroid carcinoma in multiple endocrine neoplasia 1 or in tertiary hyperparathyroidism, both of which were not

applicable in our case, PTH values in the setting of humoral hypercalcemia of malignancy are normal or high-normal.^{20,21}

While we realize that the cosecretion of PTH and PTHrP leading to hypercalcemia is an unusual and rare event, our patient’s PTH would not be explained by primary or secondary hyperparathyroidism. Clonal heterogeneity may be a limiting factor for pathologic confirmation of ectopic PTH secretion. The acuity and degree of hypercalcemia and hyperparathyroidism without imaging confirmation of a parathyroid lesion, together with an elevated PTHrP value, make primary hyperparathyroidism very unlikely. Further, the magnitude of his hyperparathyroidism is not consistent with that seen secondary to vitamin D deficiency, prolonged renal impairment, or administration of therapy to inhibit osteoclast function. This case underscores the importance of measuring a PTH value even in patients with acute-onset hypercalcemia in the setting of known malignancy. Doing so may yield increased

detection of ectopic PTH production. That being said, management is challenging and it remains unclear if these patients may be more resistant to traditional therapeutic measures. Early recognition of the causes of HCM and its various treatment options are important to optimize patient management.

Conclusion

This is the youngest and first case of hypercalcemia of malignancy due to cosecretion of PTH and PTHrP from an adenocarcinoma. Denosumab is a potential option to treat refractory hypercalcemia of malignancy when other conventional measures are unsuccessful.

Acknowledgment

Author Contributions

J.K. and C.K. each contributed to the writing of this manuscript.

Disclosure

The authors have no multiplicity of interest to disclose.

References

- Adhikaree J, Newby Y, Sundar S. Denosumab may be the treatment of choice for bisphosphonate refractory hypercalcemia of malignancy. *BMJ Case Rep.* 2014;2014:bcr2013202861.
- Doyle MA, Malcolm JC. An unusual case of malignancy-related hypercalcemia. *Int J Gen Med.* 2013;7:21–27.
- Asonitis N, Kassi E, Kokkinos M, Giovanopoulos I, Petychaki F, Gogas H. Hypercalcemia of malignancy treated with cinacalcet. *Endocrinol Diabetes Metab Case Rep.* 2017:17–0118.
- Nakajima N, Ueda M, Nagayama H, Yamazaki M, Katayama Y. Humoral hypercalcemia associated with gastric carcinoma secreting parathyroid hormone: a case report and review of the literature. *Endocr J.* 2013;60(5):557–562.
- Uchimura K, Mokuno T, Nagasaka A, et al. Lung cancer associated with hypercalcemia induced by concurrently elevated parathyroid hormone and parathyroid hormone-related protein levels. *Metabolism.* 2002;51(7):871–875.
- Eid W, Wheeler TM, Sharma MD. Recurrent hypercalcemia due to ectopic production of parathyroid hormone-related protein and intact parathyroid hormone in a single patient with multiple malignancies. *Endocr Pract.* 2004;10(2):125–128.
- Sayn M, Yazici G. Hyperparathyroidism secondary to zoledronic acid infusion: case report. *Support Care Cancer.* 2009;17:469–470.
- Goldner W. Cancer-related hypercalcemia. *J Oncol Pract.* 2016;12(5):426–432.
- Stewart AF. Hypercalcemia associated with cancer. *N Engl J Med.* 2005;352(4):373–379.
- Reagan P, Pani A, Rosner MH. Approach to the diagnosis and treatment of hypercalcemia in a patient with malignancy. *Am J Kidney Dis.* 2014;63(1):141–147.
- Thosani S, Hu MI. Denosumab: a new agent in the management of hypercalcemia of malignancy. *Future Oncol.* 2015;11(21):2865–2871.
- Hu MI, Glezerman IG, Lebouleux S, et al. Denosumab for the treatment of hypercalcemia of malignancy. *J Clin Endocrinol Metab.* 2014;99(9):3144–3152.
- Salahudeen AA, Gupta A, Jones JC, et al. PTHrP-induced refractory malignant hypercalcemia in a patient with chronic lymphocytic leukemia responding to denosumab. *Clin Lymphoma Myeloma Leuk.* 2015;15(9):e137–e140.
- Gabriel FGC, Picar RE. A rare case of hypercalcemic encephalopathy from ectopic secretion of parathyroid hormone. *Clin Case Rep.* 2020;8(3):423–425.
- Richey DS, Welch BJ. Concurrent primary hyperparathyroidism and humoral hypercalcemia of malignancy in a patient with clear cell endometrial cancer. *South Med J.* 2008;101(12):1266–1268.
- Gomes LDA, Kulak CA, Costa TM, Vasconcelos EC, Carvalho Md, Borba VZ. Association of primary hyperparathyroidism and humoral hypercalcemia of malignancy in a patient with clear cell renal carcinoma. *Arch Endocrinol Metab.* 2015;59(1):84–88.
- Pellicciotti F, Giusti A, Gelli MC, Foderaro S, Ferrari A, Pioli G. Challenges in the differential diagnosis of hypercalcemia: a case of hypercalcemia with normal PTH level. *World J Clin Oncol.* 2012;3(1):7–11.
- Ratcliffe WA, Hutchesson AC, Bundred NJ, Ratcliffe JG. Role of assays of parathyroid-hormone-related protein in investigation of hypercalcemia. *Lancet.* 1992;339:164–167.
- Logue FC, Perry B, Chapman RS, Milne I, James K, Beastall GH. A two-site immunoradiometric assay for PTH (1-84) using N and C terminal specific monoclonal antibodies. *Ann Clin Biochem.* 1991;28(pt 2):160–166.
- Dionisi S, Minisola S, Pepe J, et al. Concurrent parathyroid adenomas and carcinoma in the setting of multiple endocrine neoplasia type 1: presentation as hypercalcemic crisis. *Mayo Clin Proc.* 2002;77:866–869.
- Messa P, Sindici C, Cannella G, et al. Persistent secondary hyperparathyroidism after renal transplantation. *Kidney Int.* 1998;54:1704–1713.