

Hemi-Intravascular Stenting for Supermicrosurgical Anastomosis

Kensuke Tashiro, MD*†
 Shuji Yamashita, MD†
 Mitsunaga Narushima, MD†
 Isao Koshima, MD†
 Shimpei Miyamoto, MD*

Background: Although supermicrosurgical anastomosis is a widely known reconstructive microsurgical technique, it is difficult to perform. To expand the clinical use of supermicrosurgery, we used hemi-intravascular stenting (hemi-IVaS), which is performed by inserting an intravascular stent into one side of the vessel. We conducted lymphaticovenular anastomosis, free perforator flap transfer, and fingertip replantation with supermicrosurgical anastomosis using hemi-IVaS technique and examined its usefulness.

Methods: Between January 2013 and February 2015, 11 anastomoses in 11 cases of lymphaticovenular anastomosis for lymphedema patients, 14 anastomoses in 7 cases of free perforator flap transfer with supermicrosurgical perforator-to-perforator anastomosis, and 9 anastomoses in 5 cases of fingertip replantation were performed using hemi-IVaS. Time required for anastomosis and complications were examined. Flap survival rate was also examined in free perforator flap transfer cases and fingertip replantation cases.

Results: In all cases, anastomoses were performed without complications such as inadvertent catching of the back wall of the vessel during the procedure or the need for re-anastomoses. The average time required to complete the anastomosis was 16.4 ± 3.20 minutes using the hemi IVaS technique. All flaps survived in the supermicrosurgical perforator-to-perforator anastomosis as well as fingertip replantation cases.

Conclusions: Hemi-IVaS could be a useful alternative to conventional intravascular stenting techniques and is also effective for supermicrosurgical perforator-to-perforator anastomosis. Further studies are needed to improve the success rate and to explore its other possible utilizations in supermicrosurgery. (*Plast Reconstr Surg Glob Open* 2017;5:e1533; doi: 10.1097/GOX.0000000000001533; Published online 27 November 2017.)

INTRODUCTION

Since the first clinical success of microsurgical composite tissue transfer, the microsurgery field has advanced greatly.¹⁻³ Reconstructive methods have evolved from the use of conventional muscle flaps to perforator flaps, which have improved donor and recipient site results and patient satisfaction.

Supermicrosurgery involves the anastomosis of vessels with a diameter < 0.8 mm and has many advantages including less donor- and recipient-site morbidity, shortened sur-

gical time, protection of the main trunk vessel, and the possibility of avoiding deep-layer anastomosis and postoperative hematoma due to muscle dissection.^{4,5}

However, this technique is difficult to master and has a long learning curve. Furthermore, supermicrosurgical anastomosis is stressful for microsurgeons who have not been trained to perform the procedure, and in fact, not all microsurgeons can master this technique.⁶

The use of several methods employing simpler techniques was recently reported to result in successful supermicrosurgical anastomosis.^{6,7} Intravascular stenting (IVaS) was reportedly used for lymphaticovenular anastomosis (LVA) or fingertip replantation, both of which are difficult

From the *Department of Plastic and Reconstructive Surgery, National Cancer Center Hospital, Tokyo, Japan; and †Department of Plastic and Reconstructive Surgery, Graduate School of Medicine, University of Tokyo, Tokyo, Japan.

Received for publication February 19, 2017; accepted August 23, 2017.

Copyright © 2017 The Authors. Published by Wolters Kluwer Health, Inc. on behalf of The American Society of Plastic Surgeons. This is an open-access article distributed under the terms of the Creative Commons Attribution-Non Commercial-No Derivatives License 4.0 (CCBY-NC-ND), where it is permissible to download and share the work provided it is properly cited. The work cannot be changed in any way or used commercially without permission from the journal.

DOI: 10.1097/GOX.0000000000001533

Disclosure: Supported, in part, by Research Grant of the Daiwa Securities Health Foundation Research Fund (to K.T.). The other authors have no financial interest to declare in relation to the content of this article. The Article Processing Charge was paid for by the authors.

Supplemental digital content is available for this article. Clickable URL citations appear in the text.

Table 1. Patient Characteristics

Characteristics	Value
Total	23
Average age (y)	56
Sex	
Male	6
Female	17
Anastomosis type	
LVA	11
Perforator-to-perforator (artery or vein)	7
Fingertip replantation	5

to perform using conventional anastomosis techniques.^{8–10} Various types of IVaS methods were reported previously.^{11–14} There have been no published reports on the use of intravascular stents for supermicrosurgical perforator-to-perforator anastomosis for free perforator flap transfer.

In this article, we report on the use of hemi-IVaS for supermicrosurgical anastomosis. We revised the previously reported IVaS technique to develop the hemi-IVaS technique, in which an intravascular stent is inserted into only 1 side of the adjacent vessels.

PATIENTS AND METHODS

Between April 2013 and February 2015, 11 anastomoses in 11 cases of LVA in lymphedema patients, 14 anastomoses in 7 cases of supermicrosurgical perforator-to-perforator anastomosis, and 9 anastomoses in 5 cases of fingertip replantation were performed utilizing hemi-IVaS. The patients' characteristics are listed in Tables 1–4. The study protocol was approved by the ethics committee of the affiliated hospital.

Supermicrosurgical anastomosis using hemi-IVaS was performed as follows (see video, Supplemental Digital Content 1, which demonstrates a super-microsurgical anastomosis between a lymphatic channel and a sub-dermal vein using the hemi-intravascular stenting method. This video is available in the “Related Videos” section of PRSGO-GlobalOpen.com or at <http://links.lww.com/PRSGO/A587>). First, the intravascular stent was prepared as reported previously.^{8–10} A 4-0, 5-0, or 6-0 black monofilament nylon suture measuring 5–15 mm in length was used in the procedure. Stent size was selected according to vessel size; if vessel size was around 0.3 mm, a 6-0 size was used; if vessel size was around 0.5 mm, a 5-0 size was used; and if vessel size was around 0.8 mm, a 4-0 size was used. The stent length was decided in accordance with vessel mobility and

anastomotic field. As the end of the nylon suture must be smooth to prevent vessel lumen damage, we used a razor or surgical knife to produce a clean cut instead of using scissors. The stent was inserted in 1 side of the adjacent vessels and into the damaged, smaller-sized, or thin-walled vessel. After the insertion, we performed the anastomosis using a 12-0, 11-0, or 10-0 nylon suture (the needle sizes were 50, 65, and 100 μ m, respectively) in the conventional 0–180 suture or back wall first suture manner depending on vessel mobility. Vessel diameter was measured before the dilation procedure. Both arteries and veins were used in the technique. To keep the stent inside the vessels, vascular clips were occasionally used to hold the vessels and stent together. The damaged, smaller-sized, or thin-walled vessel is difficult to anastomose safely, but handling the stent inside the vessel makes the lumen visible and prevents the needle from catching the back wall (Fig. 1A, B). The last 2 stitches remained untied but were then tied after stent removal (Fig. 1C). Six to 8 stitches were routinely used for the anastomosis. End-to-end anastomosis was performed in all cases in the present study. The microsurgeons who performed supermicrosurgical anastomosis in the present study completed at least 6 months of intensive supermicrosurgical anastomosis experience.

LVA was performed under local anesthesia in 11 lymphedema patients (1 case of upper extremity lymphedema and 10 cases of lower extremity lymphedema; Table 2) according to previously reported conventional LVA procedures.¹⁰ An approximately 2–3-cm-long skin incision was made based on indocyanine green lymphography. After identification of the lymphatic channels and venules appropriate for anastomoses, the vessels were transected. An intravascular stent was subsequently inserted into either the venule or lymphatic channel, depending on the vessel condition. After stent insertion, anastomosis was carried out.

In the supermicrosurgical perforator-to-perforator anastomosis group, either the lateral thoracic artery perforator flap or superficial circumflex iliac artery perforator flap was used and anastomosed to the recipient perforator above the deep fascial layer. The diameter of at least 1 of the recipient or flap vessels was less than 0.8 mm. Seven arterial and venous anastomoses were performed in 7 patients. The recipient vessels included perforators of the descending branch of lateral circumflex femoral artery (anterolateral thigh perforator) in 1, descending genicular artery in 3, perforator of posterior tibial artery in 2, and the ulnar artery in 1 (Table 3).

Table 2. Patient Characteristics in the LVA Group

ID	Age	Sex	Etiology	Edema Period	Diameter of Lymphatics	Diameter of Vein	Anastomosis Problem
1	77	M	Primary	15	0.5	0.5	None
2	3	M	Primary	0	0.3	0.4	None
3	36	F	Primary	3	0.5	0.6	None
4	45	F	Secondary	20	0.3	0.5	None
5	65	F	Secondary	4	0.3	0.6	None
6	76	F	Secondary	8	0.4	0.4	None
7	59	F	Secondary	7	0.6	0.5	None
8	46	F	Secondary	2	0.3	0.3	None
9	60	F	Secondary	16	0.7	0.8	None
10	72	F	Secondary	2	0.5	0.6	None
11	66	F	Secondary	1	0.6	0.5	None

Table 3. Characteristics of Patients in the Supermicrosurgical Perforator-to-Perforator Group

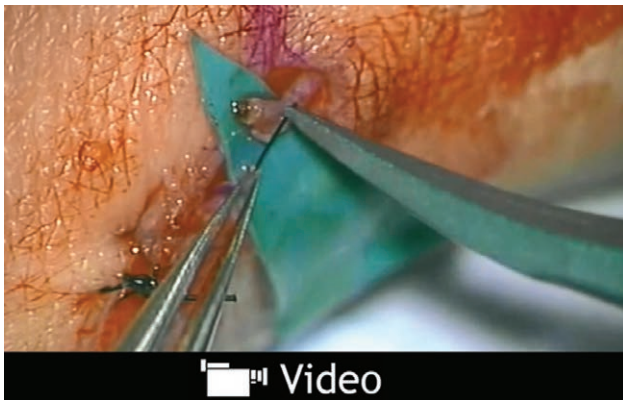
ID	Age	Sex	Type of Flap Vessels	Diameter of Flap Vessels (mm)	Type of Recipient Vessels	Diameter of Recipient Vessels (mm)	Anastomosis Problem
1	64	F	SCIP	1.2	UAP	0.8	None
2	41	F	Comitant vein	0.5	Comitant vein	0.5	None
3	74	F	LTAP	0.7	PTAP	0.8	None
4	65	F	Comitant vein	0.5	Comitant vein	0.5	None
5	62	F	LTAP	0.6	DGAP	0.5	None
6	75	F	LTAP	0.7	PTAP	0.8	None
7	46	F	Comitant vein	0.4	Cutaneous vein	1.0	None
			Comitant vein	0.6	Cutaneous vein	1.1	None
			LTAP	0.8	DGAP	0.6	None
			Comitant vein	1.0	Comitant vein	0.6	None
			Comitant vein	1.0	Cutaneous vein	0.8	None
			LTAP	1.3	DGAP	0.7	None
			LTAP	0.4	ALTP	0.5	None
			Comitant vein	0.7	Cutaneous vein	1.0	None

SCIP, superior circumflex iliac artery perforator; UAP, ulnar artery perforator; LTAP, lateral thoracic artery perforator; PTAP, posterior tibial artery perforator; DGAP, descending genicular artery perforator; ALTP, anterolateral thigh perforator.

Table 4. Characteristics of Patients in the Fingertip Replantation Group

ID	Age	Sex	Type of Amputation	Subzone	Amputated Finger	Type of Vessels	Diameter	Anastomosis Problem
1	45	M	Incomplete	3	Thumb	Artery	0.8	None
2	41	M	Complete	1	Little finger	Artery	0.5	None
3	76	F	Complete	3	Middle finger	Vein	0.4	None
4	59	M	Complete	2	Ring finger	Artery	0.8	None
5	43	M	Incomplete	2	Middle finger	Vein	0.3	None
						Vein	0.5	None
						Artery	0.6	None
						Vein	0.5	None
						Artery	0.5	None

Fingertip replantation was performed in 5 cases, with 5 arterial and 4 venous anastomoses. All cases involved a crushing injury in 4 men and 1 woman, with ages ranging



Video Graphic 1. See video, Supplemental Digital Content 1, which demonstrates a super-microsurgical anastomosis between a lymphatic channel and a sub-dermal vein using the hemi-IVaS method. First, a nylon stent is inserted into the lymphatic channel on the left. The lymphatic channel has a small diameter of less than 0.4 mm and a thin wall compared with the thicker wall and more visible lumen of the vein seen on the right. The blue intravascular stent allows easy visualization of the mouth of the thin-walled lymphatic lumen. The intravascular stent allows identification of the luminal wall, and thus, prevents the incorrect placement of sutures, and also damage to the thin lymphatic channel. The stent and vessels can be manipulated to facilitate the correct placement of sutures and thus ensure a good anastomosis. This video is available in the “Related Videos” section of PRSGlobalOpen.com or at <http://links.lww.com/PRSGO/A587>.

from 41 to 76 years (mean age, 53 years). Three patients underwent complete amputations, and the remaining 2 underwent incomplete amputations. The amputations comprised 1 thumb, 2 middle fingers, 1 ring finger, and 1 little finger. Based on the Ishikawa fingertip injury classification,¹¹ 1 case was a subzone 1 injury, 2 were subzone 2 injuries, and 2 were subzone 3 injuries (Table 4).

Time required for anastomosis and complications were examined. Flap survival rate was also examined in free perforator flap transfer cases and fingertip replantation cases.

RESULTS

In the LVA cases, supermicrosurgical anastomosis was established without any complications or damage to the vessels (Fig. 2). The common problems associated with anastomosis such as catching on the back wall, leakage of lymphatic fluid or blood, or thrombosis were not observed. Patency of anastomosis was confirmed by visualization of lymphatic fluid flow from the lymphatics to the veins and a patency test using forceps. Images of the anastomoses were taken, and several microsurgeons visually checked for patency.

In all cases of perforator-to-perforator anastomoses, flaps survived without complications (Fig. 3). Five cases involved 1 arterial and 1 venous anastomosis, whereas 2 cases involved 1 arterial and 2 venous anastomoses. The common complications associated with anastomosis such as catching on the back wall, leakage of blood, and thrombosis were not observed (Table 3).

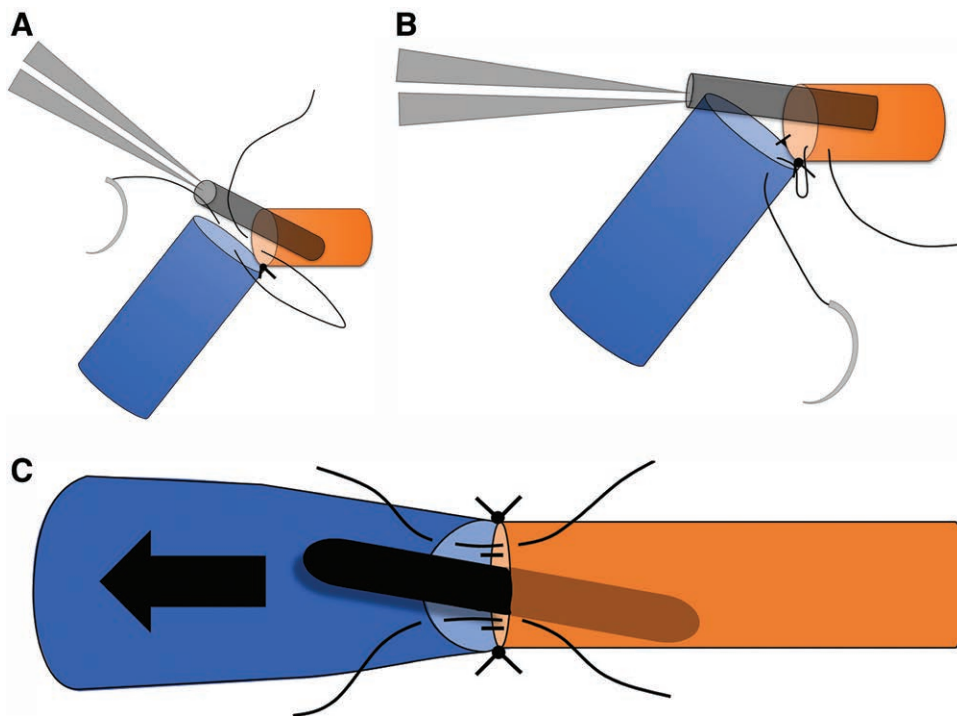


Fig. 1. A, Hemi-IVaS, in which the stent is inserted into 1 side of the vessel. The stent should be inserted into a vessel that has a small diameter or thin or damaged wall. B, Handling the stent in the lumen facilitates stitching to the vessel wall. Controlling the stent and vessels to position the needling point in upper side facilitates anastomosis and prevents the stent from removing the vessels. C, The last 2 stitches are untied, the stent is pulled out, and the stitches are then tied.

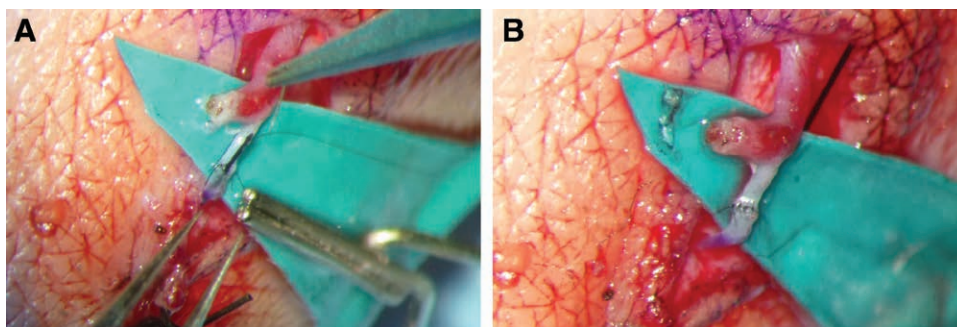


Fig. 2. A, In LVA, the intravascular stent was usually inserted into the lymphatic channel with the thinner vessel wall. B, Completion of LVA.

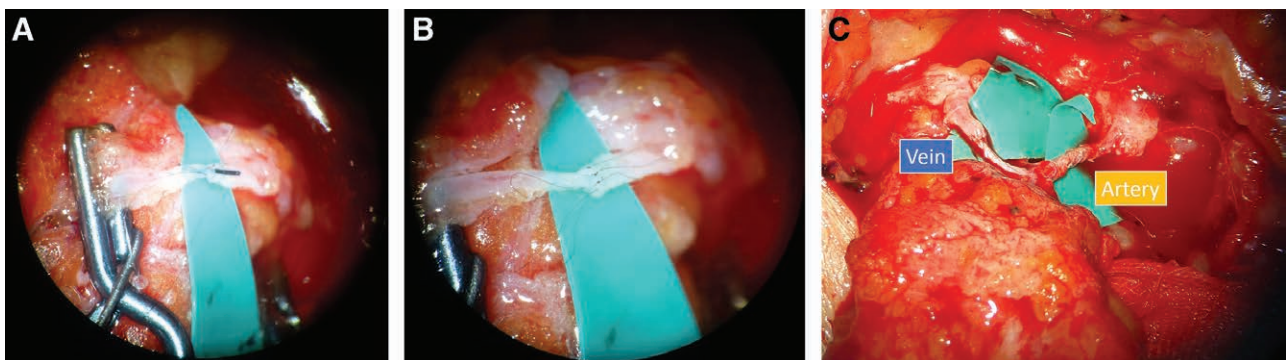


Fig. 3. A, In supermicrosurgical perforator-to-perforator anastomosis, the intravascular stent is inserted into the vessel with the thinner wall, smaller caliber, or damage. B, Completion of supermicrosurgical perforator-to-perforator anastomosis. C, Completion of a 1-artery, 1-vein anastomosis.

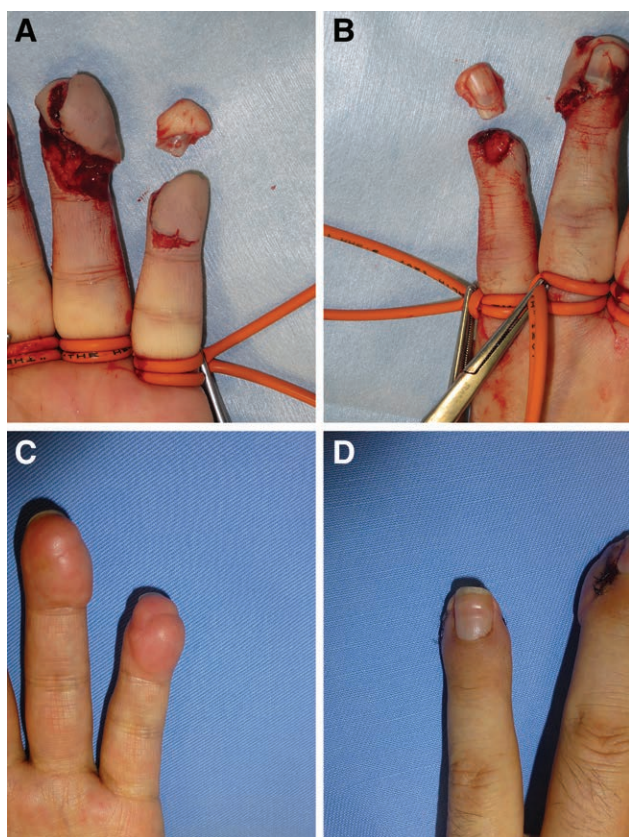


Fig. 4. A, Fingertip amputation (pulp side). B, Fingertip amputation (nail side). C, After replantation of fingertip (pulp side). D, After replantation of fingertip (nail side).

Among the fingertip replantation cases, the overall survival rate was 100% (5/5 replants) without associated postoperative complications or nail deformity (Fig. 4).

The mean time required to complete the anastomosis in the present study was 16.4 ± 3.56 minutes using the hemi-IVaS technique.

DISCUSSION

Supermicrosurgical anastomosis is defined as the microsurgical anastomosis of vessels with a diameter < 0.8 mm, although controversy persists regarding border size. The difficulty of the anastomosis of vessels with a diameter of 0.8 mm is dependent on vessel mobility, obstacles of the surrounding tissue, and vessel wall condition. In the present study, we defined microsurgical and supermicrosurgical anastomosis borders as 0.8 mm in diameter.⁵

Supermicrosurgical anastomosis is difficult due to small vessel size, thin vessel walls, vessel size discrepancy, and vessel damage. These conditions are frequently encountered in clinical practice because small vessels tend to have thin walls and a high vessel size to diameter ratio. For example, it would be more difficult to anastomose vessels with a diameter of 0.3–0.4 mm than those with a diameter of 1.3–1.4 mm because the diameter ratios are $0.4/0.3 = 1.33$ and $1.4/1.3 = 1.08$, respectively. To overcome these

challenges in performing supermicrosurgical anastomosis, we decided to insert an intravascular stent into 1 side of the vessel.

The advantages of the hemi-IVaS technique are as follows:

- 1) Stent insertion into only 1 side is easy and can be performed quickly;
- 2) It can make the lumen of the thin and damaged vessels visible;
- 3) It can reduce the risk of inadvertent catching of the back wall of the vessel and save time;
- 4) There is greater mobility of vessels while the stent is in place in hemi-IVaS than in the conventional IVaS technique; and
- 5) It is a reasonable method, especially when only 1 side of the vessel has a thin or damaged wall.

On the other hand, the disadvantages of the hemi-IVaS technique are as follows:

- 1) Making the last 2–3 stitches at equal intervals is difficult for beginners in the present method; and
- 2) Careful control of the stent is needed because it is easily removed from the lumen and must be reinserted.

Although IVaS is useful for supermicrosurgical anastomosis, it has some disadvantages including the difficulty and stress involved in inserting the stent in both sides of the vessels as well as time needed to perform the procedure. Additionally, it is difficult to maintain an acceptable stent position within the vessel. In some cases, the surgeon may even fail to remove the stent from the vessel.

The hemi-IVaS technique is helpful even for trained supermicrosurgeons because it can reduce stress during challenging anastomoses in cases such as different conditions in different vessel sides. Furthermore, the reliability of supermicrosurgical anastomosis has yet to be established, so improving supermicrosurgical anastomosis reliability is useful for supermicrosurgery beginners and masters alike. The possibility that stent insertion could damage fragile vessels was reportedly low in 1 electron microscopy observation, which indicated that the lumen will remain intact if this method is correctly applied.

The criteria for using this technique in supermicrosurgical anastomosis are a vessel discrepancy ≥ 1.5 times or 1 side of the vessel having a thin or damaged wall. In clinical supermicrosurgical anastomosis cases, the vessels are in different conditions (e.g., one may have a small diameter or a thin or damaged wall). In such situations, inserting the intravascular stent in only 1 side is especially effective for maintaining the integrity of the lumen of the affected side.

Although supermicrosurgery has been established worldwide, there have been no reports on techniques that have proved its success.¹⁵ To our knowledge, this is the first study to use an intravascular stent for supermicrosurgical perforator-to-perforator anastomosis for free flap transfer and examine the usefulness of hemi-IVaS, but future studies are needed to validate our findings.

CONCLUSIONS

Hemi-IVaS is a valuable technique to increase the reliability of supermicrosurgical anastomosis. However, further studies are needed to improve its success rate and identify all possible areas for its use.

Kensuke Tashiro, MD

Department of Plastic and Reconstructive Surgery
National Cancer Center
5-1-1 Tsukiji, Chuo-ku
Tokyo, Japan, 104-0045
E-mail: tashirop@pr@gmail.com

ACKNOWLEDGMENTS

The authors thank all members in their department for their kind support with data collection and article preparation.

REFERENCES

1. Harii K, Ohmori K, Ohmori S. Hair transplantation with free scalp flaps. *Plast Reconstr Surg.* 1974;53:410–413.
2. Daniel RK, Taylor GI. Distant transfer of an island flap by microvascular anastomoses. A clinical technique. *Plast Reconstr Surg.* 1973;52:111–117.
3. Rickard RF, Hudson DA. A history of vascular and microvascular surgery. *Ann Plast Surg.* 2014;73:465–472.
4. Koshima I, Inagawa K, Urushibara K, et al. Supermicrosurgical lymphaticovenular anastomosis for the treatment of lymphedema in the upper extremities. *J Reconstr Microsurg.* 2000;16:437–442.
5. Hong JP. The use of supermicrosurgery in lower extremity reconstruction: the next step in evolution. *Plast Reconstr Surg.* 2009;123:230–235.
6. Chen WF, Eid A, Yamamoto T, et al. A novel supermicrosurgery training model: the chicken thigh. *J Plast Reconstr Aesthet Surg.* 2014;67:973–978.
7. Miyamoto S, Sakuraba M, Asano T, et al. Optimal technique for microvascular anastomosis of very small vessels: comparative study of three techniques in a rat superficial inferior epigastric arterial flap model. *J Plast Reconstr Aesthet Surg.* 2010;63:1196–1201.
8. Narushima M, Koshima I, Mihara M, et al. Intravascular stenting (IVaS) for safe and precise supermicrosurgery. *Ann Plast Surg.* 2008;60:41–44.
9. Narushima M, Mihara M, Koshima I, et al. Intravascular stenting (IVaS) method for fingertip replantation. *Ann Plast Surg.* 2009;62:38–41.
10. Narushima M, Mihara M, Yamamoto Y, et al. The intravascular stenting method for treatment of extremity lymphedema with multiconfiguration lymphaticovenous anastomoses. *Plast Reconstr Surg.* 2010;125:935–943.
11. Maegawa J, Yabuki Y, Tomoeda H, et al. Outcomes of lymphaticovenous side-to-end anastomosis in peripheral lymphedema. *J Vasc Surg.* 2012;55:753–760.
12. Yamamoto T, Narushima M, Kikuchi K, et al. Lambda-shaped anastomosis with intravascular stenting method for safe and effective lymphaticovenular anastomosis. *Plast Reconstr Surg.* 2011;127:1987–1992.
13. Nuri T, Ueda K, Yamada A, et al. Preparatory intravascular stenting technique: an easier method of supermicrosurgical lymphaticovenular anastomosis. *Ann Plast Surg.* 2013;71:541–543.
14. Yamamoto T, Yoshimatsu H, Narushima M, et al. Split intravascular stents for side-to-end lymphaticovenular anastomosis. *Ann Plast Surg.* 2013;71:538–540.
15. Tashiro K, Harima M, Yamamoto T, et al. Locating recipient perforators for perforator-to-perforator anastomosis using color Doppler ultrasonography. *J Plast Reconstr Aesthet Surg.* 2014;67:1680–1683.