

Long-Term Tumor Control despite Late Pseudoprogression on ¹⁸F-FDG-PET following Extremely Hypofractionated Stereotactic Radiotherapy for Retropharyngeal Lymph Node Metastasis from Esthesioneuroblastoma

Kazuhiro Ohtakara^a Hiroaki Hoshi^b

^aDepartment of Radiation Oncology, Murakami Memorial Hospital, Asahi University, and

^bDepartment of Radiology, Gifu University Graduate School of Medicine, Gifu, Japan

Key Words

Esthesioneuroblastoma · Stereotactic body radiotherapy · Retropharyngeal lymph node metastasis · ¹⁸F-FDG-PET · Pseudoprogression

Abstract

¹⁸F-FDG-PET is a valuable adjunct to conventional imaging for evaluating treatment response following stereotactic body radiotherapy (SBRT) for head and neck malignancies (HNM). The effect of treatment-related inflammation is generally deemed negligible after 12 weeks following conventionally fractionated radiotherapy. Herein, we describe an unusual case showing pseudoprogression on ¹⁸F-FDG-PET 2 years after SBRT for retropharyngeal lymph node metastasis (RPLNm) from esthesioneuroblastoma. A 36-year-old man presented with right RPLNm 32 months after the diagnosis of esthesioneuroblastoma associated with ectopic adrenocorticotrophic hormone production. The RPLNm was treated with SBRT in 2 fractions over 8 days using dynamic conformal arcs with concomitant chemotherapy with cisplatin and etoposide. Although follow-up MRI showed sustained lesion regression, the early/delayed maximum standardized uptake (SUVmax) values on dual-time-point ¹⁸F-FDG-PET obtained 1 and 2 years after SBRT were 7.7/8.3 and 8.5/10.1, respectively, suggesting local progression. Despite no subsequent focal or systemic treatment, the SUVmax values gradually decreased thereafter over a period of 4 years (3.3/3.4 at 76 months). MRI obtained

Kazuhiro Ohtakara, MD, PhD
Department of Radiation Oncology
Murakami Memorial Hospital, Asahi University
3-23 Hashimoto-cho, Gifu 500-8523 (Japan)
E-Mail ohtakara@murakami.asahi-u.ac.jp

7 years after SBRT revealed sustained tumor regression. No obvious relevant toxicities have occurred. Thus, caution should be exercised in the interpretation of the SUVmax change following ablative irradiation for HNM.

© 2014 S. Karger AG, Basel

Introduction

Stereotactic body radiotherapy (SBRT), also referred to as stereotactic ablative radiotherapy, has emerged as a valuable treatment option, either alone or in conjunction with other radiotherapeutic approaches and/or pharmacotherapy, for oral as well as head and neck malignancies (HNM) [1]. Several issues have been under active investigation, including the optimal dose-fractionation scheme according to a wide variety of clinical scenarios, and long-term outcomes with respect to safety and durability of efficacy [1].

Integrated PET/CT with 2-[¹⁸F]FDG, referred to hereafter as ¹⁸F-FDG-PET/CT, is considered a useful adjunct to conventional imaging for disease staging, target definition, evaluation of treatment response, and detection of disease relapse outside the treated site for patients undergoing SBRT for HNM [2, 3]. Although ¹⁸F-FDG-PET is well known to give false-positive results in the early period after (chemo-)radiotherapy because of treatment-induced inflammation, the effect on image interpretation can be eliminated more than 12 weeks after treatment [3].

Herein, we describe an unusual case presenting with late ‘pseudoprogression’ on ¹⁸F-FDG-PET, despite the observation of sustained tumor regression on MRI, following extremely hypofractionated SBRT for metachronous retropharyngeal lymph node metastasis (RPLNm) from esthesioneuroblastoma associated with ectopic adrenocorticotrophic hormone (ACTH) production.

Case Presentation

A 33-year-old man first experienced bilateral leg edema and bradycardia. He was diagnosed with esthesioneuroblastoma that extended into the brain parenchyma and the orbit. Bilateral submandibular lymph node involvement (modified Kadish stage D) was also diagnosed. His general symptoms were proven to be attributable to Cushing’s syndrome due to the ectopic secretion of ACTH by esthesioneuroblastoma. Following induction chemoradiotherapy with cisplatin (CDDP) and 5-fluorouracil and 40 Gy in 20 fractions using a single anterior port, he underwent gross resection of the primary tumor as well as bilateral selective neck dissection. He subsequently received 2 courses of adjuvant chemotherapy including CDDP and etoposide (VP-16), although he refused postoperative radiotherapy to either the primary site or the neck. Cushing’s syndrome as well as pathological secretion of ACTH subsequently resolved.

Right submandibular lymph node metastasis developed 19 months after the initial surgery. A lesionectomy was therefore performed. Ten months later, the patient experienced right RPLNm and contralateral multiple neck lymph node metastases (level Ib–III). After neck dissection surgery on the left side, he was referred to our institution for treatment of the right RPLNm.

SBRT was performed 33 months after the initial treatment. We used the dynamic conformal arcs technique with the m3® (BrainLAB AG, Feldkirchen, Germany) micro-multileaf collimator as an add-on device on the Clinac 21EX linear accelerator (Varian Medical Systems, Palo Alto, Calif., USA) with a 6-MV X-ray output to deliver SBRT. The patient’s

immobilization was achieved using the BrainLAB thermoplastic mask [1]. BrainSCAN v5.3 (BrainLAB AG) was used to generate the dynamic conformal arcs plan. Planning CT scans were acquired in contiguous 2-mm slices and fused to gadolinium-enhanced T1-weighted MRI, also in 2-mm slices. The clinical target volume (9.7 cm³) was delineated, principally by referring to the MRI. It was then expanded by 3 mm isotropically to form the planning target volume (PTV, 20.0 cm³) after accounting for the setup uncertainty arising from the lack of a dedicated image-guidance system. The prescribed dose to the PTV isocenter was 30 Gy in 2 fractions with an interval of 7 days, and the dose calculation algorithm was based on a pencil beam with the radiological path length to correct for tissue heterogeneity. The dose encompassing 95% of the PTV (D95) was 26.6 Gy (88.7%) on the dose-volume histogram (fig. 1). One course of systemic chemotherapy consisting of 70 mg/m² CDDP (day 1) and 85 mg/m² VP-16 (days 1–3) was also started the day after SBRT initiation. The patient completed the planned treatment but experienced a generalized convulsive seizure 2 months after the completion of SBRT, necessitating the administration of an anticonvulsant.

In addition to MRI, ¹⁸F-FDG-PET/CT evaluation was included in imaging surveillance after SBRT. Dual-time-point ¹⁸F-FDG-PET/CT imaging (whole body) was acquired 1 h (early) and 3 h (delayed) after the ¹⁸F-FDG injection. Follow-up MRI 10 months after SBRT revealed a recurrent nodule in the right basal frontal lobe (marginal recurrence at the primary site), which was treated by single-session stereotactic radiosurgery using the aforementioned system [4]. The maximum standardized uptake (SUVmax) values (early/delayed) in the right RPLNm on ¹⁸F-FDG-PET/CT increased from 7.7/8.3 to 8.5/10.1 1 and 2 years after SBRT, respectively (fig. 2). Nuclear medicine radiologists suggested a progression of the right RPLNm. Since MRI showed sustained regression of the RPLNm thereafter (fig. 3), we chose to keep the patient under clinical observation. He required craniotomy for the decompression of symptomatic delayed cyst formation in the right frontal lobe that developed 38 months after stereotactic radiosurgery [4]. He also developed marginal recurrence in the right posterior ethmoid sinus that extended into the orbital apex 55 months after SBRT which was treated with endoscopic resection followed by postoperative radiotherapy via image-guided SBRT and using the Novalis Tx (BrainLAB AG) with 35 Gy in 10 fractions to 85% isodose surface for PTV (8.7 cm³) coverage [5]. The early/delayed SUVmax values then gradually decreased over a period of 4 years to 3.3/3.4 76 months after SBRT (fig. 2b). Whole-body ¹⁸F-FDG-PET/CT, obtained 76 months after SBRT and MRI obtained 84 months after SBRT, revealed no obvious recurrent or metastatic disease as well as sustained regression of the RPLNm (fig. 3). The patient was alive at the last follow-up visit (10 and 7 years after the initial presentation and SBRT, respectively) with a Karnofsky performance score of 90 and with no clinical or radiological findings suggesting SBRT-related toxicities.

Discussion

At the time when we were considering SBRT for RPLNm in this case, the use of the micro-multileaf collimator as an add-on device for a non-dedicated linear accelerator and the machine capacity at our institution required us to use a very limited number of fractions, only 1 or 2 per week [1]. In this case, we used 2 fractions over 8 days. Despite no additional systemic treatment, the RPLNm gradually shrank over 3 years, and sustained regression was achieved for a further 4 years as observed on MRI, suggesting a continued, gradual response (fig. 3), whilst ¹⁸F-FDG-PET/CT revealed profoundly different findings during the same period. The SUVmax increased between the first and second year after SBRT, but then spontaneously and gradually decreased and has continued to do so for a period of more than

4 years (fig. 2b). Given the ablative nature of the SBRT dose used, the effect of radiation on the metastatic lymph node and surrounding normal tissue would be quite distinct from that of conventional (chemo-)radiotherapy. Specifically, in addition to tumor cell death, SBRT may result in coagulation necrosis of both tumor and normal tissues as well as a wide variety of chronic inflammatory processes. The transient increase in the SUVmax values at 2 years might reflect some of these consequences. In addition, these imaging findings suggest that the effect of SBRT gradually increased over several years, and that SBRT can therefore provide long-term control of lymph node metastasis from esthesioneuroblastoma. This case provides further evidence that SBRT can offer a valuable and less invasive alternative to the surgical treatment of RPLNm. Since the installation of the Novalis Tx platform, we now use ≥ 5 –10 fractions for SBRT of HNM [5], although it is not known whether this confers similar local control as oligofractionation.

The patient in this case experienced a generalized convulsive seizure 2 months after SBRT, presumably as a result of the earlier brain surgery. However, given the location of RPLNm, radiation effects such as edema might stimulate a syncope attack as a result of a tumor-induced cardiovascular reflex associated with tumor involvement of the glossopharyngeal nerve adjacent to the internal carotid artery [6]. No other obvious radiation-related toxicities have so far been observed, although potential late toxicities germane to SBRT included injuries involving the internal carotid artery, other cranial nerves, the pharyngeal mucosa, the surrounding soft tissue, and the adjacent vertebrae. Nonetheless, further long-term vigilant observation is necessary, and caution should be exercised when interpreting the SUVmax values on ^{18}F -FDG-PET/CT following ablative SBRT. It is recommended that treatment response is comprehensively evaluated using a combination of imaging modalities.

Esthesioneuroblastoma is an uncommon neuroectodermal tumor that arises from the olfactory mucosa of the upper nasal cavity in the region of the cribriform plate [7]. It generally has an insidious nature but often presents with locoregionally advanced disease. Furthermore, it has a propensity for local recurrence and late distant metastases [7]. It is very rarely associated with ectopic secretion of ACTH causing Cushing's syndrome [8], which was well controlled after initial treatment in this case. The histological grade (low or high) or Hyams classification is closely associated with initial disease extension, tendency for recurrence, and prognosis [7]. In this case, there were concerns regarding the detailed histopathological analysis of the primary tumor and a possible discordance in histological features between the primary tumor and metachronously developed recurrent/metastatic disease. Unfortunately, these analyses, including the histological verification of the RPLNm, were unavailable. The prognosis of patients with recurrent HNM, who are treated using a SBRT-based strategy, is largely determined by the presence of any disease outside the irradiated site [1]. In this case, a couple of locoregional recurrences, including RPLNm, occurred metachronously and reiteratively after the initial treatment, for which SBRT offered a less invasive and efficacious treatment as an integral part of salvage therapy, allowing the maintenance of a good quality of life. Thus, SBRT still has an important role in the treatment of recurrent or metastatic esthesioneuroblastoma.

In addition to the lack of histological analyses, several other study limitations need to be considered. First, ^{18}F -FDG-PET was not performed before SBRT, and the interpretation of the SUVmax change in its entirety is therefore compromised by the absence of a pretreatment value. According to a report on the largest cohort to date, the mean SUVmax values \pm standard deviation are 8.68 ± 4.75 for the primary tumor and 8.57 ± 6.46 for the metastatic site [9]. Certainly, these values are similar to those of the RPLNm 1 and 2 years after SBRT, suggesting viable tissue in this case, albeit one subsequently proven to be pseudoprogress-

sion. Second, the SBRT dose calculation in this case was based on a pencil beam in conjunction with a one-dimensional equivalent path length in order to correct tissue heterogeneity. However, the accuracy of the one-dimensional equivalent path length algorithm is limited for lesions close to an air cavity [10]. Dose calculation in this case should thus have been performed using a more accurate algorithm such as the Monte Carlo code.

In conclusion, we describe the long-term clinical and radiological outcomes of a case of RPLNm from esthesioneuroblastoma, which was treated using SBRT in 2 fractions with concurrent chemotherapy, resulting in long-term tumor control without any relevant toxicities. However, pseudoprogression was observed on ¹⁸F-FDG-PET/CT 2 years after SBRT, with a subsequent gradual decrease over 4 years. Nuclear medicine radiologists and practitioners should be aware that ¹⁸F-FDG-PET can yield false-positive findings more than a year after SBRT for HNM.

Acknowledgements

The authors thank Dr. Yoichi Yokota for his valuable support and his suggestions.

References

- 1 Ohtakara K, Hayashi S, Mizuta K, Aoki M, Ando K, Okada S, Ito Y, Hoshi H: Clinical outcomes of single or oligo-fractionated stereotactic radiotherapy for head and neck tumors using micromultileaf collimator-based dynamic conformal arcs. *J Cancer Res Clin Oncol* 2012;138:1511–1522.
- 2 Rajagopalan MS, Heron DE: Role of PET/CT imaging in stereotactic body radiotherapy. *Future Oncol* 2010;6:305–317.
- 3 Kawabe J, Higashiyama S, Yoshida A, Kotani K, Shiomi S: The role of FDG PET-CT in the therapeutic evaluation for HNSCC patients. *Jpn J Radiol* 2012;30:463–470.
- 4 Ohtakara K, Hoshi H: Cerebral cyst formation following stereotactic ablative irradiation for non-nasopharyngeal head and neck malignancies: imaging findings and relevant dosimetric parameters. *Br J Radiol* 2014;87:20140071.
- 5 Ohtakara K, Hayashi S, Tanaka H, Hoshi H, Matsuyama K, Kitahara M, Okada H: Clinical comparison of positional accuracy and stability between dedicated versus conventional masks for immobilization in cranial stereotactic radiotherapy using 6-degree-of-freedom image guidance system-integrated platform. *Radiother Oncol* 2012;102:198–205.
- 6 Nakahira M, Nakatani H, Takeda T: Syncope as a sign of occult malignant recurrence in the retropharyngeal and parapharyngeal space: CT and MR imaging findings in four cases. *AJNR Am J Neuroradiol* 2002;23:1257–1260.
- 7 Malouf GG, Casiraghi O, Deutsch E, Guigay J, Temam S, Bourhis J: Low- and high-grade esthesioneuroblastomas display a distinct natural history and outcome. *Eur J Cancer* 2013;49:1324–1334.
- 8 Mayur N, Bordonni RE, Locandro D, McLaughlin M: Cushing's syndrome due to ectopic adrenocorticotrophic hormone production by olfactory neuroblastoma. *Endocr Pract* 2014;20:e47–e52.
- 9 Broski SM, Hunt CH, Johnson GB, Subramaniam RM, Peller PJ: The added value of 18F-FDG PET/CT for evaluation of patients with esthesioneuroblastoma. *J Nucl Med* 2012;53:1200–1206.
- 10 Linthout N, Verellen D, Van Acker S, Voordeckers M, Bretz A, Storme G: Evaluation of dose calculation algorithms for dynamic arc treatments of head and neck tumors. *Radiother Oncol* 2002;64:85–95.

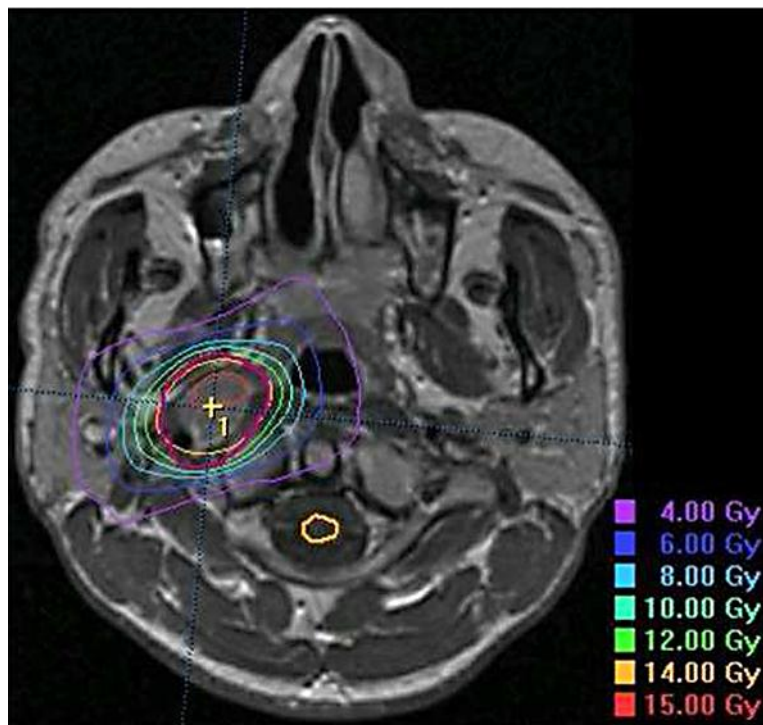


Fig. 1. Representative dose distribution of SBRT plan. Absolute doses for each isodose surface are represented as dose per fraction.

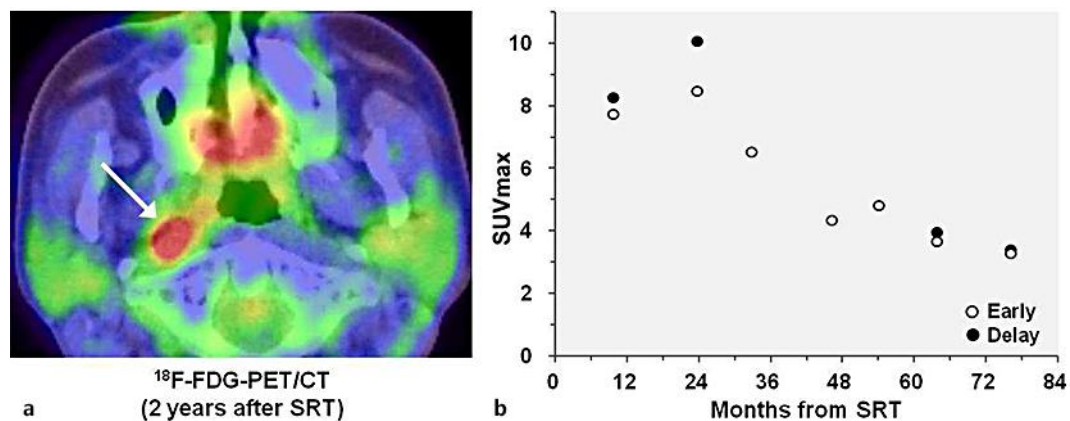


Fig. 2. a ^{18}F -FDG-PET/CT obtained 2 years after SBRT revealing an avid lesion in the right retropharyngeal space. **b** Serial change in the SUVmax values of the right RPLNm on dual-time-point ^{18}F -FDG-PET/CT after SBRT, although the delayed SUVmax values at 33, 46, and 54 months are unavailable.

Ohtakara and Hoshi: Pseudoprogression on FDG-PET following SBRT for Lymph Node Metastasis

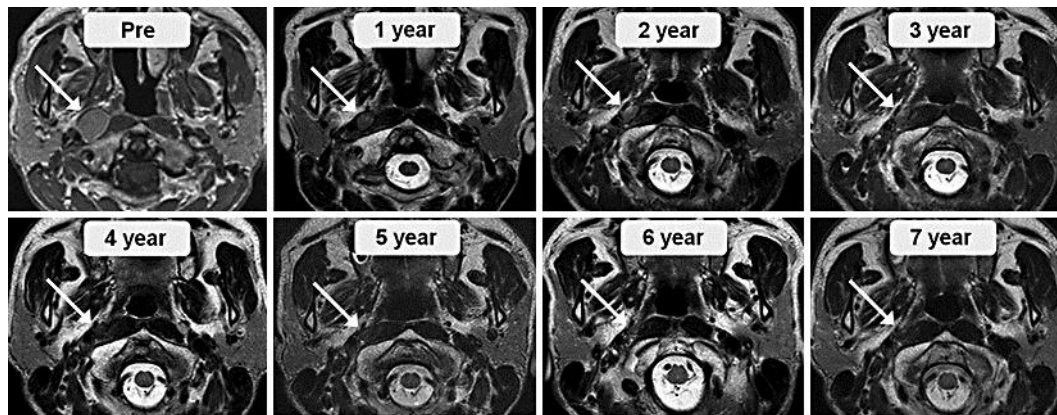


Fig. 3. MRI with gadolinium-enhanced T1-weighted image before (Pre) and with T2-weighted images after SBRT. Arrows indicate the right RPLNm.