

Contents lists available at [ScienceDirect](https://www.sciencedirect.com)

International Journal of Surgery Case Reports

journal homepage: www.casereports.com

Case report of a successful non-operative management of postoperative bleeding from pseudoaneurysm of the gastroduodenal artery, following gastric surgery

Georgios Stravodimos*, Vasileios Komporozos, Antonia Papazoglou

4th Surgical Department, Evangelismos General Hospital, Athens, Greece

ARTICLE INFO

Article history:

Received 22 November 2020

Received in revised form

29 November 2020

Accepted 30 November 2020

Available online 2 December 2020

Keywords:

Pseudoaneurysm

Gastroduodenal artery

Bleeding

Computed Angiography (CTA)

Digital subtraction angiography (DSA)

Case report

ABSTRACT

INTRODUCTION: Post operative pseudoaneurysm of the gastroduodenal artery is a very rare entity. Rupture of the pseudoaneurysm can be treated by embolism of the artery.

PRESENTATION OF CASE: A 71 years old male with a perforated pyloric ulcer was treated with controlled external duodenal fistula. Due to postoperative bleeding a subtotal gastrectomy was performed. A second episode of bleeding occurred and rupture of a pseudoaneurysm of the gastroduodenal artery was diagnosed by computed angiography and treated by embolism of the artery. Three days later the duodenal stump was ruptured and a new controlled external duodenal fistula was surgically created. The patient died 6 weeks later due to multiple organ failure.

DISCUSSION: Pseudoaneurysm is the result of self-contained ruptures of one or more layers of the vascular wall. Computed angiography is the golden standard to identify pseudoaneurysms (100% sensitivity). Early suspicion for the presence of a pseudoaneurysm is crucial, as when the rupture actually occurs, the mortality rate is remarkably high. Endovascular approach is a minimally invasive procedure with high success rates (70–100%) and significantly lower morbidity and mortality rates. Surgical is reserved in case of bleeding recurrence. The fact that is particularly interesting in this patient is the timing of the formation of the pseudoaneurysm, considering the fact that 48 h earlier the gastroduodenal artery appeared normal.

CONCLUSION: There are no guidelines regarding the treatment of the pseudoaneurysm of the gastroduodenal artery. It seems reasonable to treat them immediately after diagnosis because a possible rupture of the aneurysm has an extremely high mortality.

© 2020 The Authors. Published by Elsevier Ltd on behalf of IJS Publishing Group Ltd. This is an open access article under the CC BY-NC-ND license (<http://creativecommons.org/licenses/by-nc-nd/4.0/>).

1. Introduction

Pseudoaneurysm of the gastroduodenal artery is very rare, representing 1.5% of the visceral arteries' pseudoaneurysms [1]. Only a very small number of cases of hemorrhage following upper gastrointestinal (GI) surgical procedures have been reported [2].

We present a patient with postoperative gastric bleeding due to pseudoaneurysm of the gastroduodenal artery. The original procedure was antrectomy to treat a neglected perforated ulcer at the duodenal ampulla. This case is of particular interest, because the original pathology is also rare (kissing ulcers).

The work has been reported in line with the SCARE criteria [9].

Abbreviations: GI, gastrointestinal; OR, operation room; CRBC, concentrated red blood cells; FFP, plasma; CTA, Computed Angiography; DSA, digital subtraction angiography; ICU, intensive care unit; MRI, magnetic resonance imaging; IVC, intravenous contrast.

* Corresponding author at: Ypsilantou 45-47, Athens 10676, Greece.

E-mail address: georgeksgr@hotmail.com (G. Stravodimos).

<https://doi.org/10.1016/j.ijscr.2020.11.157>

2210-2612/© 2020 The Authors. Published by Elsevier Ltd on behalf of IJS Publishing Group Ltd. This is an open access article under the CC BY-NC-ND license (<http://creativecommons.org/licenses/by-nc-nd/4.0/>).

2. Presentation of case

A 71 years old male was admitted at the emergency department due to acute abdominal pain. He reported a medical history of Arterial Hypertension, Diabetes Melitus and Trigeminal Neuralgia treated with irivesartan, metformine and pregabalin respectively. No smoking or alcohol abuse was reported and his family history was clear.

He underwent an abdominal ultrasound and thorax/abdominal x-ray and the diagnosis of GI perforation was confirmed.

The patient was urgently transferred to the operation room (OR) where a surgical exploration of the abdomen was performed. We discovered a large amount of fluid with food mixture and a 3 cm perforated ulcer at the anterior wall of pylorus. It seemed that the perforation had occurred several hours ago.

The extensive severe inflammation affected the gallbladder and therefore cholecystectomy was conducted. Furthermore, due to the extent of the rupture, the perforation was not sutured. We preferred to create a controlled external duodenal fistula instead, using a Pezzer catheter.

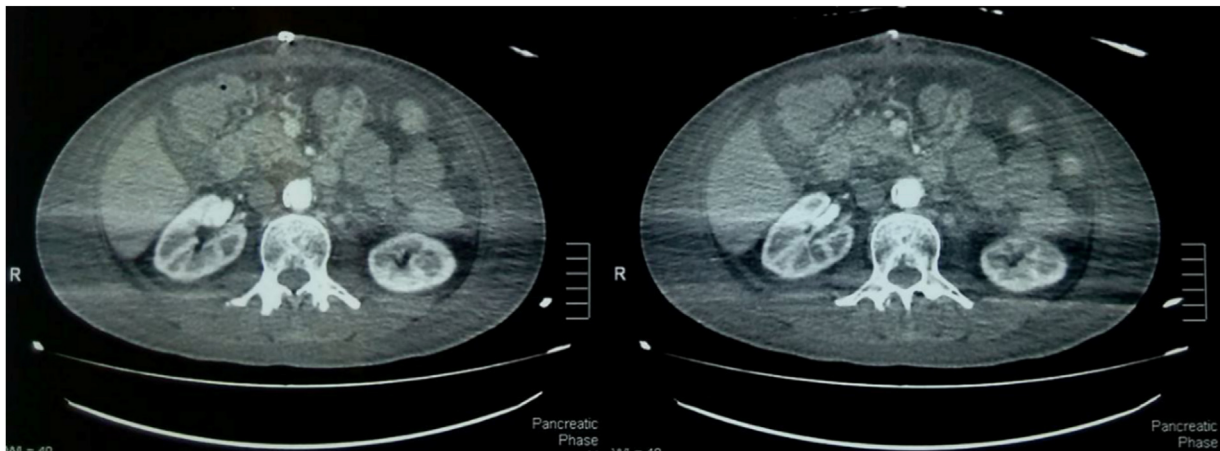


Image 1. CTA where no pseudoaneurysm is identified.

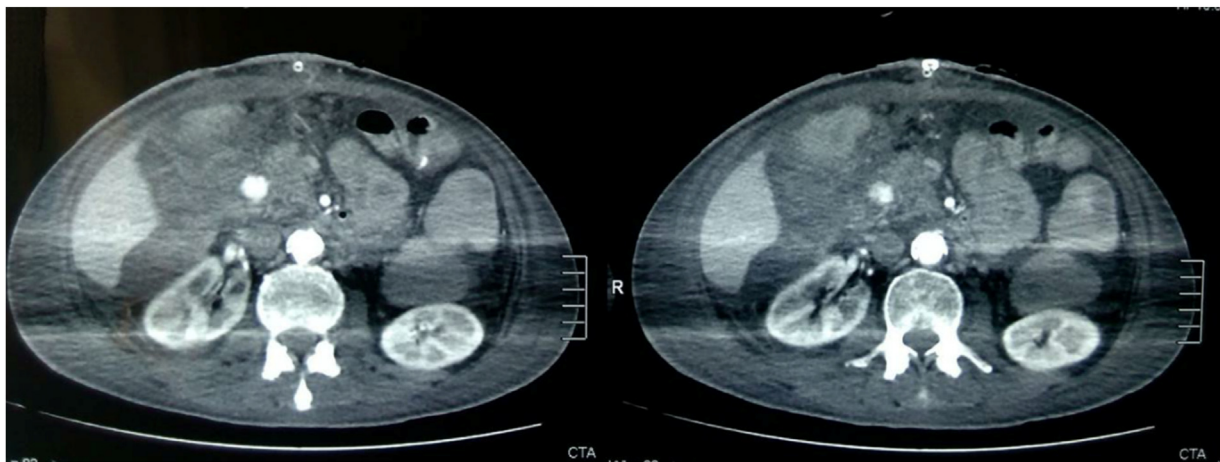


Image 2. CTA 48 h later, where the pseudoaneurysm is obvious.

On the sixth (6th) postoperative day the patient had another emergency laparotomy due to upper GI hemorrhage. The location of the bleeding was a second deep ulcer at the posterior duodenal wall perforating to the pancreas with a visible thrombosed artery in it (kissing ulcers). We performed subtotal gastrectomy (Billroth II) stapling the duodenal stump and creating gastrojejunostomy.

On the twelfth (12th) postoperative day a new episode of upper GI and intraabdominal bleeding occurred, that required transfusion of 6 Units of concentrated red blood cells (CRBC) and 8 Units of fresh frozen plasma (FFP). The next day Computed Angiography (CTA) was performed in order to specifically identify the bleeding vessel. Rupture of a pseudoaneurysm of the gastroduodenal artery in the duodenal wall was diagnosed [Image 2]. A digital subtraction angiography (DSA) was immediately performed and the bleeding was successfully treated by embolism [Images 3 and 4]. It is worth mentioning that 48 h earlier a Computed Angiography was performed because of high transaminase values, in which the gastroduodenal artery appeared normal [Image 1].

On the fifteenth (15th) postoperative day a leakage of biliary fluid was detected through the abdominal incision, therefore the patient underwent urgent laparotomy for the third time. A leak of the duodenal stump was detected, along with ischaemia of a small area of the liver. After thorough lavage of the peritoneal cavity a Pezzer tube was inserted in the duodenal stump creating a controlled external duodenal fistula. All surgical procedures mentioned above were performed by the same surgeon, director of the surgical department, fully experienced regarding upper GI procedures.

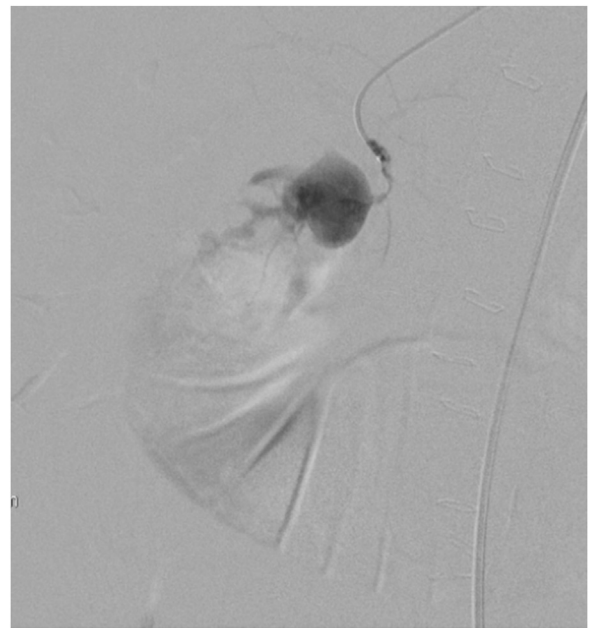


Image 3. DSA, before the embolism of the gastroduodenal artery.

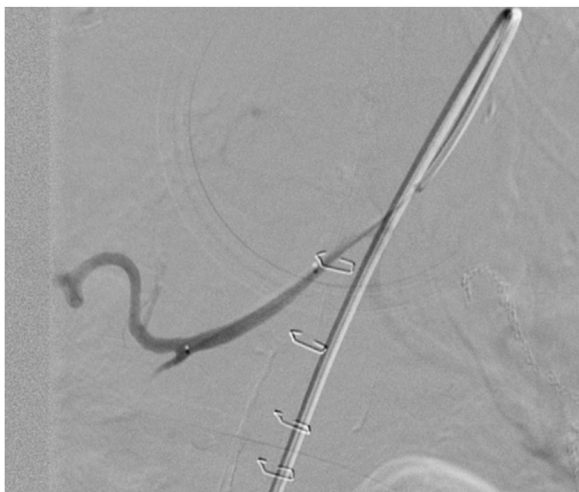

Image 4. DSA, after the embolism of the gastroduodenal artery.

The patient returned to the intensive care unit (ICU) under hemodynamic support, where he died six weeks later, due to multiple organ failure.

3. Discussion

Pseudoaneurysm of the gastroduodenal artery is mainly diagnosed in middle aged (50–58 y.o.a) male patients (4.5:1) [3]. The pathophysiology of the pseudoaneurysm's formation includes inflammation and trauma that lead to lesions of the artery and blood extravasation in the nearby tissues. The next step is the formation of fibrous pocket that gradually increases because of the arterial pressure. The median diameter is 3.6 cm [3]. Pseudoaneurysm is actually the result of self-contained ruptures of one or more layers of the vascular wall. Other factors that may play a role in the formation of a pseudoaneurysm of the gastroduodenal artery are connective tissue diseases (Marfan syndrome, Ehlers-Danlos syndrome, polyarteritis nodosa, fibromuscular dysplasia), alcohol abuse (25%), liver cirrhosis and gastric ulcer (17%). Arterial hypertension and septic emboli are considered to be predisposing factors. Postoperative pseudoaneurysms occur after upper GI operations [4–6]. Almost half (52%) of the pseudoaneurysms are diagnosed when a rupture occurs. The bleeding could be either endoluminal (haematemesis/melaena) or retroperitoneal and rarely in the common bile duct (haemobilia) [7]. Forty percent of these patients die. Computed angiography is the golden standard in order to identify pseudoaneurysms (100% sensitivity). Less sensitive examination is the ultrasound scan (US) (50% sensitivity). Three dimensional magnetic resonance imaging (MRI) with intravenous contrast (IVC) infusion and Doppler US have been recently introduced [8]. Early suspicion for the presence of a pseudoaneurysm is crucial, as when the rupture actually occurs, the mortality rate is remarkably high.

The treatment of a bleeding pseudoaneurysm could be either surgical (artery ligation), or endovascular (x-ray guided embolism with coils, stenting of the vessel, synthetic graft insertion). Conservative management of such a bleeding leads to a mortality over 90% [7]. Considering all the above, it is obvious that all the pseudoaneurysms of the gastroduodenal artery must be treated right after the diagnosis, no matter what their size is.

Comparing the two options, the endovascular approach is a minimally invasive procedure with high success rates (70–100%) and significantly lower morbidity and mortality rates. The surgical approach is reserved for case of bleeding recurrence.

The fact that is particularly interesting in this case is the timing of the formation of the pseudoaneurysm, considering the fact that 48 h earlier the gastroduodenal artery appeared normal in the CTA image.

Multiple possible causative factors can be identified. The patient had two upper GI ulcers located in the pylorus and the first part of the duodenum and one of them was complicated with perforation several hours before admission. The prolonged peritoneal presence of gastric fluid and bile caused severe local inflammation. Moreover the patient subjected to cholecystectomy and subtotal gastrectomy which are known to be predisposing factors for the formation of pseudoaneurysms of the gastroduodenal artery. During these procedures the vascular wall may be injured. A small amount of pancreatic secretions may also be locally released due to manipulation of the pancreas. Finally we can assume that a certain degree of angiopathy was present as consequence of Diabetes Mellitus. Our assumption is that the combination of all the factors mentioned above led to the formation of the gastroduodenal pseudoaneurysm.

Learning points: What is remarkable about this case is the fact that the pseudoaneurysm of the gastroduodenal artery rapidly formed between tenth and twelfth postoperative day according to the CTA images. Therefore prompt intervention is of high importance and should take place at the moment of diagnosis and not when the rupture has already occurred. Minimally invasive techniques are preferable as they are associated with lower morbidity and mortality rates.

4. Conclusion

Because of the rarity of the pseudoaneurysms of the gastroduodenal artery, there is lack of guidelines regarding both the screening and follow up of these patients. The only solid conclusion is that all pseudoaneurysms of the gastroduodenal artery must be treated immediately after diagnosis, regardless their size or the absence of symptoms. If a rupture occurs the mortality is almost 100%. Endovascular treatment is the method of choice as it is a minimally invasive procedure.

Conflicts of interest

None.

Sources of funding

None.

Ethical approval

Not applicable (not an experimental technique).

Consent

The patient passed away and during the final days of his hospitalization he was intubated. Furthermore, he had declared no existing relatives. Therefore, having the patient's consent for this publication is not an option.

However, the Head of our medical team has taken responsibility that exhaustive attempts have been made to contact the family and that the paper has been sufficiently anonymised not to cause harm to the patient or their family.

Author contribution

Georgios Stravodimos: Methodology, investigation, Writing - Original Draft.

Vasileios Komporozos: Supervision, validation.

Antonia Papazoglou: Conceptualization, methodology, validation, Writing - Review & Editing.

Riad Nafas: contributor.

Dimitrios Tomais: contributor.

Registration of research studies

Not applicable.

Guarantor

Antonia Papazoglou.

Provenance and peer review

Not commissioned, externally peer-reviewed.

Acknowledgments

Riad Nafas MD¹.

Dimitrios Tomais MD².

1. 4th Surgical Department, Evangelismos General Hospital, Athens, Greece.

2. Department of Radiology, Interventional Radiology Unit, Evangelismos General Hospital of Athens, Athens, Greece.

References

- [1] O. Røkke, K. Søndena, S. Amundsen, T. Bjerke-Larssen, D. Jensen, The diagnosis and management of splanchnic artery aneurysms, *Scand. J. Gastroenterol.* 31 (8) (1996) 737–743, <http://dx.doi.org/10.3109/00365529609010344>.
- [2] Z. Li, Z. Jie, Y. Liu, X. Xie, Management of delayed hemorrhage following radical gastrectomy for gastric carcinoma patients, *Hepatogastroenterology* 59 (September (118)) (2012) 2016–2019, <http://dx.doi.org/10.5754/hge11825>, PMID: 22282039.
- [3] Y. Matsuzaki, T. Inoue, K. Kuwajima, Y. Ito, Y. Okauchi, H. Kondo, N. Horiuchi, K. Nakao, K. Hasegawa, M. Iwata, M. Yoden, Aneurysm of the gastroduodenal artery, *Intern. Med.* 37 (November (11)) (1998) 930–933, <http://dx.doi.org/10.2169/internalmedicine.37.930>, PMID: 9868954.
- [4] Y. Matsuno, Y. Mori, Y. Umeda, M. Imaizumi, H. Takiya, Surgical repair of true gastroduodenal artery aneurysm: a case report, *Vasc. Endovasc. Surg.* 42 (October–November (5)) (2008) 497–499, <http://dx.doi.org/10.1177/1538574408316916>, PMID: 19000986.
- [5] N. Tulsyan, V.S. Kashyap, R.K. Greenberg, T.P. Sarac, D.G. Clair, G. Pierce, K. Ouriel, The endovascular management of visceral artery aneurysms and pseudoaneurysms, *J. Vasc. Surg.* 45 (February (2)) (2007) 276–283, <http://dx.doi.org/10.1016/j.jvs.2006.10.049>, discussion 283. PMID: 17264002.
- [6] D.P. Coll, R. Ierardi, M.D. Kerstein, S. Yost, A. Wilson, T. Matsumoto, Aneurysms of the pancreaticoduodenal arteries: a change in management, *Ann. Vasc. Surg.* 12 (May (3)) (1998) 286–291, <http://dx.doi.org/10.1007/s100169900155>, PMID: 9588518.
- [7] N. Habib, S. Hassan, R. Abdou, et al., Gastroduodenal artery aneurysm, diagnosis, clinical presentation and management: a concise review, *Ann. Surg. Innov. Res.* 7 (1) (2013) 4–9, <http://dx.doi.org/10.1186/1750-1164-7-4>.
- [8] K. Harris, Gastroduodenal artery aneurysm rupture in hospitalized patients: an overlooked diagnosis, *World J. Gastrointest. Surg.* 2 (9) (2010) 291, <http://dx.doi.org/10.4240/wjgs.v2.i9.291>.
- [9] R.A. Agha, M.R. Borrelli, R. Farwana, K. Koshy, A. Fowler, D.P. Orgill, For the SCARE Group, The SCARE 2018 statement: updating consensus Surgical Case Report (SCARE) guidelines, *Int. J. Surg.* 60 (2018) 132–136.

Open Access

This article is published Open Access at [sciencedirect.com](https://www.sciencedirect.com). It is distributed under the [IJSCR Supplemental terms and conditions](#), which permits unrestricted non commercial use, distribution, and reproduction in any medium, provided the original authors and source are credited.