

Limbic encephalitis with relapsing polychondritis: persistent white matter lesions and brain atrophy

Journal of International Medical Research

2018, Vol. 46(12) 5297–5302

© The Author(s) 2018

Article reuse guidelines:

sagepub.com/journals-permissions

DOI: 10.1177/0300060518805593

journals.sagepub.com/home/imr



Zilong Zhu^{1,#}, Decai Tian^{2,#}, Ning Ren¹,
Zhihong Zhao¹, Xin Wang¹ and Lei Chen¹

Abstract

Relapsing polychondritis (RP) is a rare autoimmune disorder affecting cartilage. Limbic encephalitis is a rare central nervous system manifestation of RP. This current case report describes a 66-year-old Chinese male patient who complained of developing myoclonus in the left leg, ataxia and speech difficulties 3 weeks prior to hospital admission. The patient presented with cognitive impairment, sleep disorder and extrapyramidal symptoms. The patient was diagnosed with RP that affected auricular cartilage, which also manifested as limbic encephalitis. Magnetic resonance imaging showed bilateral temporal lobe lesions involving the hippocampi and basal ganglia. Signal abnormalities in the white matter persisted during the 15-month follow-up period after treatment with corticosteroids and intravenous immunoglobulin. Over the same period, the bilateral hippocampi showed significant atrophy.

Keywords

Relapsing polychondritis, dementia, encephalitis, magnetic resonance imaging

Date received: 18 May 2018; accepted: 17 September 2018

Introduction

Relapsing polychondritis (RP) is a rare and potentially lethal autoimmune disorder of unknown aetiology manifesting as progressive inflammation of cartilaginous and other proteoglycan-rich structures throughout the body, including the ears, joints,

¹Department of Neurology, Tianjin HuanHu Hospital, Tianjin, China

²Centre for Neuroinflammation, Beijing Tiantan Hospital, Capital Medical University, Beijing, China

[#]These authors contributed equally to this work.

Corresponding author:

Lei Chen, Department of Neurology, Tianjin HuanHu Hospital, 6 Ji Zhao Road, Jinnan District, Tianjin 300350, China.

Email: halo1881@163.com



nose, eyes, respiratory tract, cardiovascular system and skin.¹ The aetiology and pathogenesis of RP are unknown, but autoantibodies to cartilage and to type II collagen have been demonstrated by immunofluorescence techniques.² The clinical manifestations of neurological involvement include headache, palsies of the cranial nerves, ataxia, polyneuritis, meningoencephalitis, general or focal seizure, dementia and cerebral infarction.³ Autopsy findings have implicated vasculitis as the underlying pathogenesis.⁴ This current report describes the case of a 66-year-old Chinese male patient whose first symptoms were auricular inflammation and limbic encephalitis. The clinical manifestations, electroencephalogram (EEG), 15-month follow-up magnetic resonance imaging (MRI) and therapy considerations of RP-related limbic encephalitis are summarized by reviewing this case and the published literature.

Case report

A previously healthy 66-year-old Chinese male patient complained of developing myoclonus in the left leg, ataxia and speech difficulties 3 weeks prior to admission to the Department of Neurology, Tianjin HuanHu Hospital, Tianjin, China on 20 December 2016. He could understand long sentences but had difficulty expressing what he wanted to say. These symptoms deteriorated gradually. He was in delirium and completely incapable of communicating with others. There was no familial history of immune-related disease. The neurological examination revealed cognitive impairment including memory, calculation and orientation; extrapyramidal symptoms with high muscle tension of extremities; and a bilateral positive Babinski sign. Laboratory blood tests showed a mild inflammatory reaction (C-reactive protein, 39.4 mg/l; normal range, 0–3 mg/l), while serum biochemistry, including renal and liver function, revealed

no abnormalities. Paraneoplastic antibodies (i.e. anti-Hu, anti-Yo anti-Ma, anti-amphiphysin) were negative and the tumour marker levels (carcinoembryonic antigen, alpha-fetoprotein, cancer antigen (CA) 242, CA199, CA724, Cyfra21-1, squamous cell carcinoma antigen, neuron-specific enolase) were in the normal range. Serum markers for Sjogren's disease, systemic lupus erythematosus and Wegener's (i.e. anti-ssDNA, anti-dsDNA, antiextractable nuclear antigens, anti-Sjögren's-syndrome-related antigen A and B antibodies) were negative. Cerebrospinal fluid (CSF) analysis showed a pleocytosis of eight white cells and normal levels of glucose and chlorine. The total protein level was 79 mg/dl (normal range, 15–45 mg/dl) with elevated immunoglobulin (200 mg/l; normal range, 0.1–34 mg/l). However, the encephalitis-related antibodies including anti-N-methyl-D-aspartate receptor, anti- α -amino-3-hydroxy-5-methyl-4-isoxazolepropionic acid receptor and anti-gamma-aminobutyric acid type B receptors were negative. Brain MRI revealed high T2 signals in the bilateral basal ganglia and temporal lobe involving the hippocampus (Figure 1). The 'sphenoid electrodes' EEG showed high irregular slow waves in the temporal lobe. Brainstem auditory evoked potentials showed bilateral damage in the auditory pathway of the central segment; and blink reflex showed a lesion in the central nervous system (Figure 2).

A clinical diagnosis of limbic encephalitis was made according to acute cognitive impairment and limbic area involvement. The patient was treated as follows: 500 mg methylprednisolone was administered intravenously daily for 3 days followed by 20 g (0.4 mg/kg per day) immunoglobulin administered intravenously daily for 5 days; followed by an initial dose of 60 mg/day prednisolone administered orally from day 9 and then gradually decreased over 2 months. One notable detail was that the

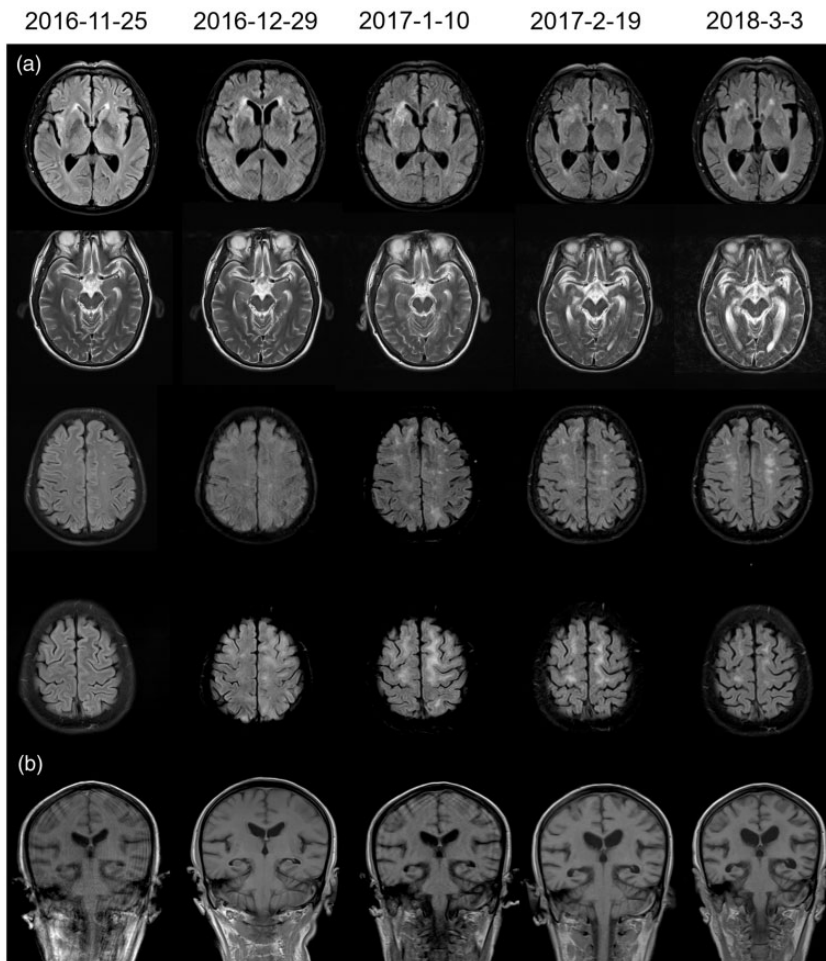


Figure 1. Magnetic resonance imaging (MRI) scans of a 66-year-old Chinese male patient who complained of developing myoclonus in the left leg, ataxia and speech difficulties 3 weeks prior to hospital admission on 20 December 2016. The MRI images show the dynamic changes of the lesions and brain atrophy during the follow-up period. (A) Axial head T2-weighted and fluid-attenuated inversion recovery (flair) MRI undertaken in an outpatient clinic on 25 November 2016 prior to hospital admission showed high signals in the bilateral temporal lobe, which had expanded to the basal ganglia, lateral ventricle and white matter by 29 December 2016. After high-dose methylprednisolone and immunoglobulin treatment, the lesions in the basal ganglia and subcortical white matter had gradually disappeared by the MRI scan on 19 February 2017, but bilateral periventricular white matter lesions persisted at the MRI scan on 3 March 2018. (B) The dynamic Coronal T1-weighted MRI from 25 November 2016 to 3 March 2018 demonstrated the enlargement of the lateral ventricle and atrophy of the hippocampus (white arrows) that occurred 3 months after onset of the symptoms and continued to deteriorate during the 1-year MRI follow-up.

slight redness of the ears was not obvious on the first day, so this clinical feature was missed by both the patient's caregivers and doctors during the initial physical

examination. The patient's mental abilities and verbal communication improved considerably and the redness of the ears was resolved. The patient was able

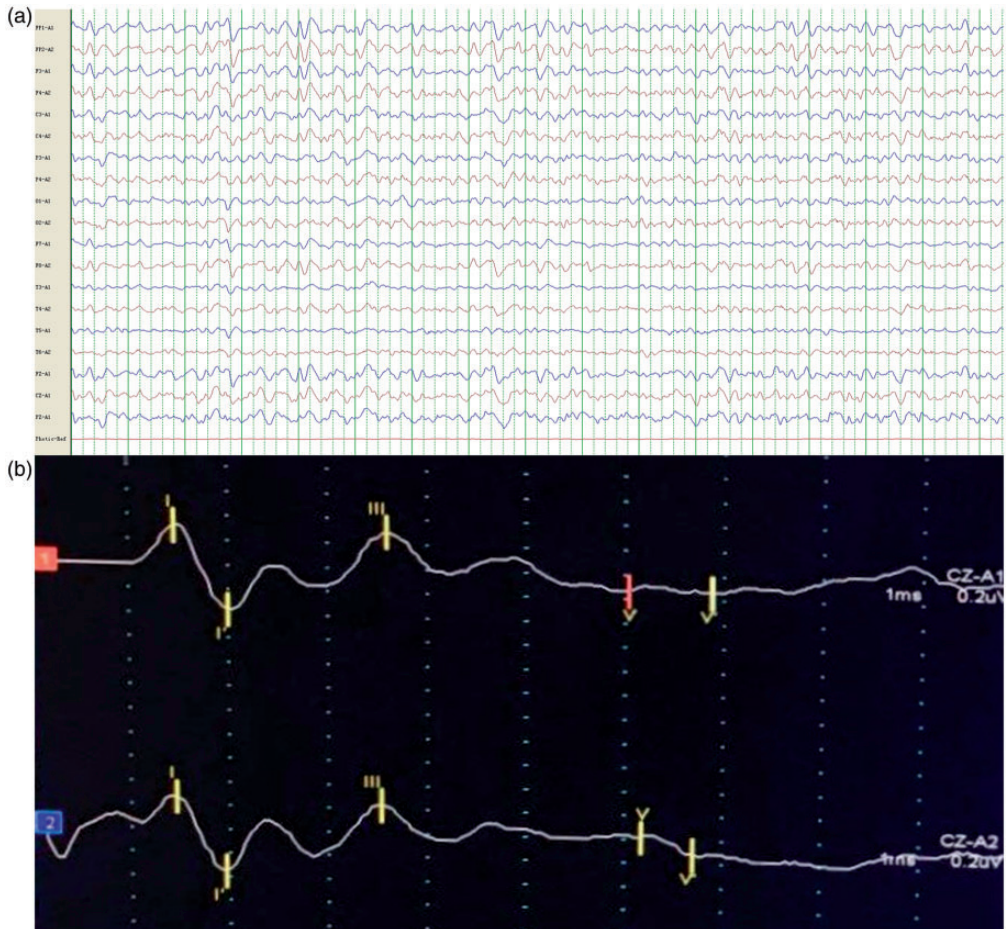


Figure 2. An electroencephalogram undertaken on 21 December 2016 showed a diffuse slow wave of 7–8 hertz in the whole brain, especially in the bilateral temporal lobe (A). Brainstem auditory evoked potentials showed both left (1) and right (2) damage in the auditory pathway of the central segment, of which the left dominated (B).

independently carry out the functions of his normal daily life and he could hold a full conversation. Five months later, the patient was admitted to the Department of Rheumatology, Tianjin First Central Hospital, Tianjin, China because of tender bilateral swollen and stumpy earlobes. The patient was examined and ultimately the diagnosis of RP was established. Bronchial three-dimensional imaging showed a slight collapse of the bronchi, but the patient had no respiratory problems. Since then, the

patient has received immunosuppressive treatment with 20 mg/day prednisolone administered orally. The follow-up head MRI showed the original anomalous signals had faded away at 1, 2 and 12 months after initial onset, although these reversible changes took a long time to diminish. Both sides of the hippocampus showed significant atrophy and were accompanied by new bilateral symmetric white matter lesions that appeared after 15 months of follow-up (Figure 1).

Discussion

Relapsing polychondritis is a rare autoimmune disease of unknown aetiology, characterized by inflammation and destruction of cartilaginous structures all over the body, including the ear, nose, larynx, trachea, bronchi, peripheral joints, eye, heart and skin.¹ Neurological involvement in RP is even rarer, only occurring in 3% of patients with RP.³ The pathophysiology of central nervous system (CNS) involvement in RP is not well understood.⁵ At present, pathological changes are generally consistent with vasculitis.⁶ Diagnosis and treatment are not well established. RP is difficult to diagnose due to its rarity and the variable presentation of the disease. Among the heterogeneous manifestations of RP such as headache, seizures, hemiplegia and unconsciousness, the main two characteristics of RP with CNS involvement are meningoencephalitis and dementia.^{7,8} Diagnosis may be delayed when patients mainly present with CNS symptoms. In this current case, dystonia and cognitive impairment were the main complaints, while redness of the bilateral ear was easily overlooked. Bilateral auricular chondritis and polyarthritis are the most common symptoms that occur in over 80% of patients with RP.⁹ In addition, this unusual case serves to remind clinicians that ear examinations are essential when encephalitis or meningitis are suspected. MRI plays an important role in diagnosing and monitoring RP with CNS involvement. MRI investigations demonstrated that nine of 14 patients had bilateral temporal lobe, especially hippocampal, involvement; and six of 14 patients had lesions in the deep brain white matter.^{5,10–14} In this current case, the lesions of the periventricle and temporal lobe decreased, but new bilateral symmetric white matter lesions appeared at the 15-month follow-up. These dynamic changes in white matter lesions may suggest that

inflammatory damage persists although the clinical symptoms have improved. Consistent with other patients with brain atrophy during MRI follow-up,^{8,10} this current patient showed a pronounced atrophy of the hippocampus, which could explain the cause of the onset of dementia during RP.¹⁵ As an autoimmune disease, the pathophysiology is thought to be related to an immune-mediated attack on particular proteins that are abundant in cartilage. In fact, anti-cartilage antibodies can be detected in at least 33% of RP patients and their titres appear to correlate with disease severity.¹⁶ Autoantibodies to glutamate receptor GluR ϵ 2 and neutral glycosphingolipids are detectable in the CSF and sera obtained from patients with encephalitis.¹⁷ Because of the suspicion of autoimmune encephalitis, autoimmune antibody testing was undertaken in the current case, but there were no positive findings. Given the rarity of RP, there have been no controlled treatment trials. Corticosteroids remain the mainstay of the medical treatment of RP. Infliximab has demonstrated primary effectiveness in two cases,^{18,19} but the first-line treatment is glucocorticoids, typically prednisolone or methylprednisolone.

In conclusion, this care report described a rare case of autoimmune encephalitis with RP. After 15 months of follow-up, persistent brain white matter damage and hippocampal atrophy were the main characteristics of the disease. This may be the cause of RP-related encephalitis associated with dementia.

Declaration of conflicting interests

The authors declare that there are no conflicts of interest.

Funding

This research received no specific grant from any funding agency in the public, commercial, or not-for-profit sectors.

References

1. Cantarini L, Vitale A, Brizi MG, et al. Diagnosis and classification of relapsing polycondritis. *J Autoimmun* 2014; 48–49: 53–59.
2. Arnaud L, Mathian A, Haroche J, et al. Pathogenesis of relapsing polycondritis: a 2013 update. *Autoimmun Rev* 2014; 13: 90–95.
3. Hatti K and Giuliano V. Central nervous system involvement in relapsing polycondritis. *J Clin Rheumatol* 2014; 20: 396–367.
4. Lin DF, Yang WQ, Zhang PP, et al. Clinical and prognostic characteristics of 158 cases of relapsing polycondritis in China and review of the literature. *Rheumatol Int* 2016; 36: 1003–1009.
5. Yan M, Cooper W, Harper C and Schwartz R. Dementia in a patient with non-paraneoplastic limbic encephalitis associated with relapsing polycondritis. *Pathology* 2006; 38: 596–599.
6. Niwa A, Okamoto Y, Kondo T, et al. Perivascularitic panencephalitis with relapsing polycondritis: an autopsy case report and review of previous cases. *Intern Med* 2014; 53: 1191–1195.
7. Erten-Lyons D, Oken B, Woltjer RL, et al. Relapsing polycondritis: an uncommon cause of dementia. *J Neurol Neurosurg Psychiatry* 2008; 79: 609–610.
8. Ahn SW, Park MS, Jeong HB, et al. Relapsing polycondritis presented with encephalitis followed by brain atrophy. *Exp Neurobiol* 2017; 26: 66–69.
9. Jeon CH. Relapsing polycondritis with central nervous system involvement: experience of three different cases in a single center. *J Korean Med Sci* 2016; 31: 1846–1850.
10. Ellis RJ, Mbizvo GK, Jacob A, et al. Relapsing polycondritis complicated by cognitive dysfunction: two distinct clinical phenotypes? *Int J Neurosci* 2017; 127: 124–134.
11. Nara M, Komatsuda A, Togashi M, et al. Relapsing polycondritis with encephalitis: a case report and literature review. *Intern Med* 2015; 54: 231–234.
12. Fujiwara S, Zenke K, Iwata S, et al. Relapsing polycondritis presenting as encephalitis. *No Shinkei Geka* 2012; 40: 247–253 [Article in Japanese, English abstract].
13. Yang SM and Chou CT. Relapsing polycondritis with encephalitis. *J Clin Rheumatol* 2004; 10: 83–85.
14. Fujiki F, Tsuboi Y, Hashimoto K, et al. Non-herpetic limbic encephalitis associated with relapsing polycondritis. *J Neurol Neurosurg Psychiatry* 2004; 75: 1646–1647.
15. Simabukuro MM, Lucato LT, Shinjo SK, et al. Teaching NeuroImages: Limbic encephalitis associated with relapsing polycondritis. *Neurology* 2016; 86: e215–e216.
16. Borgia F, Giuffrida R, Guarneri F, et al. Relapsing Polycondritis: An Updated Review. *Biomedicines* 2018; 6: pii: E84.
17. Kashihara K, Kawada S and Takahashi Y. Autoantibodies to glutamate receptor GluRepsilon2 in a patient with limbic encephalitis associated with relapsing polycondritis. *J Neurol Sci* 2009; 287: 275–257.
18. Kondo T, Fukuta M, Takemoto A, et al. Limbic encephalitis associated with relapsing polycondritis responded to infliximab and maintained its condition without recurrence after discontinuation: a case report and review of the literature. *Nagoya J Med Sci* 2014; 76: 361–368.
19. Garcia-Egido A, Gutierrez C, De la Fuente C, et al. Relapsing polycondritis-associated meningitis and encephalitis: response to infliximab. *Rheumatology (Oxford)* 2011; 50: 1721–1723.