








# Preoperative Shoulder MRI Findings to Predict Subscapularis Tendon Tear Requiring Surgical Repair

수술이 필요한 견갑하건 파열을 예측하기 위한 수술 전 어깨 MRI 소견

Ji-hoon Jung, MD<sup>1</sup> , Young-Hoon Jo, MD<sup>2</sup> , Yeo Ju Kim, MD<sup>3</sup> ,  
Seunghun Lee, MD<sup>3</sup> , JeongAh Ryu, MD<sup>1\*</sup> 


Departments of <sup>1</sup>Radiology and <sup>2</sup>Orthopedic Surgery, Hanyang University Guri Hospital, Hanyang University College of Medicine, Guri, Korea

<sup>3</sup>Department of Radiology, Hanyang University Hospital, Hanyang University College of Medicine, Seoul, Korea

## ORCID iDs

Ji-hoon Jung  <https://orcid.org/0000-0002-1173-3942>

Young-Hoon Jo  <https://orcid.org/0000-0002-4299-2496>

Yeo Ju Kim  <https://orcid.org/0000-0002-1783-8876>

Seunghun Lee  <https://orcid.org/0000-0002-4348-7993>

JeongAh Ryu  <https://orcid.org/0000-0002-4474-180X>

**Purpose** This study aimed to investigate which indirect parameters on preoperative MRI were the principal predictors of subscapularis tendon tears (STTs) requiring surgical repair.

**Materials and Methods** Preoperative MRI scans of 86 patients were retrospectively reviewed for visual assessment of the STT, pathology of the long head of the biceps tendon (LHBT), posterior decentering (PD) of the humeral head, humeral rotation, fatty degeneration, and subscapularis muscle atrophy. To evaluate atrophy, visual grading using the anatomical line connecting the coracoid tip to the glenoid base, designated as the base-to-tip line (BTL), and thickness measurements were performed in the en-face view.

**Results** Arthroscopically, 31 patients (36%) exhibited Lafosse type III or IV STT and underwent surgical repair. LHBT pathology ( $p = 0.002$ ), PD of the humeral head ( $p = 0.012$ ), fatty degeneration ( $p < 0.001$ ), and BTL grade ( $p = 0.003$ ) significantly correlated with STT. In the multivariate analysis, PD of the humeral head ( $p = 0.011$ , odds ratio [OR] = 5.14) and fatty degeneration ( $p = 0.046$ , OR = 2.81) were independent predictors of STT.

**Conclusion** PD of the humeral head and fatty degeneration of the subscapularis can help to diagnose clinically significant STT. Interpretation of these findings may contribute to the planning of an optimal surgical strategy.

**Index terms** Subscapularis; Rotator Cuff Tear; Magnetic Resonance Imaging; Posterior Decentering; Fatty Degeneration

Received May 2, 2023  
Revised July 23, 2023  
Accepted August 26, 2023

## \*Corresponding author

JeongAh Ryu, MD  
Department of Radiology,  
Hanyang University Guri Hospital,  
Hanyang University  
College of Medicine,  
153 Gyeongchun-ro, Guri 11923,  
Korea.

Tel 82-31-560-2449  
Fax 82-31-560-2458  
E-mail ryuja@hanyang.ac.kr

This is an Open Access article distributed under the terms of the Creative Commons Attribution Non-Commercial License (<https://creativecommons.org/licenses/by-nc/4.0>) which permits unrestricted non-commercial use, distribution, and reproduction in any medium, provided the original work is properly cited.

## INTRODUCTION

The subscapularis muscle is important in shoulder biomechanics such as glenohumeral coaptation, anterior stability, and internal rotation (1). The prevalence of rotator cuff tears combined with subscapularis tendon tears (STT) is 30% to 69% (2-4). Because STT has been recognized as a risk factor for retear after rotator cuff repair, accurate diagnosis is essential (5). Surgical repair is preferred in tears that involve 50% or more of the tendon thickness. Therefore, preoperative evaluation to detect STT can affect surgical strategy (6). Undetected STTs can lead to shoulder dysfunction and persistent pain with the progression of muscle atrophy, fatty infiltration, and tear worsening (7).

MRI is the most effective diagnostic method for rotator cuff diseases, including STT (3). This noninvasive imaging modality can provide excellent multiplanar delineation without contrast or radiation exposure. MRI has the advantage of providing further information on cuff issues and surrounding structures, such as muscle atrophy, edema, and fatty degeneration (FD), which represent the physiological conditions of the rotator cuffs (3, 7). MRI shows greater than 90% accuracy in diagnosing rotator cuff tears by focusing on the supraspinatus and infraspinatus muscles. However, the use of MRI as an effective diagnostic tool for rotator cuff tears focusing on the subscapularis has been challenging (7, 8). A recent systematic review and meta-analysis demonstrated unclear sensitivity of MRI for detecting STT, ranging from 25% to 94% with an overall sensitivity of 68% (9). However, this overall sensitivity was overestimated because more than half of the studies included in this review used MR arthrography (10). Although the recognition of STT during arthroscopy has improved, and surgical outcomes are good, the current diagnostic performance of preoperative MRI is not ideal (11).

Previous studies suggest that tears and malpositioning of the long head of the biceps tendon (LHBT) may indicate the presence of STT (12). Posterior decentering (PD) of the humeral head, severe muscle atrophy, and high-grade FD are associated with a large tear size (3, 13). These findings suggest that investigating reliable parameters that are highly associated with STTs may improve the diagnostic ability of MRIs. However, these studies did not analyze other significant MRI parameters. Because these parameters correlated with each other, it was necessary to conduct a multivariate analysis. Therefore, the current study aimed to determine which preoperative MRI parameters were the principal predictors of STT requiring surgical repair.

## MATERIALS AND METHODS

The study protocol was approved by the Institutional Review Board of Hanyang University Guri Hospital (IRB No. GURI 2022-08-012). The requirement for patient consent was waived by the review board due to the retrospective design of the study.

## PATIENTS

Between July 2018 and June 2020, 214 patients were diagnosed with rotator cuff tears using shoulder MRI. The inclusion criteria were: 1) patients who underwent preoperative MRI

at our institutes using a standardized protocol, 2) those who had arthroscopic rotator cuff repairs within 3 months after MRI acquisition, and 3) those with available operation records describing the condition of the rotator cuff tendons. The exclusion criteria were as follows: 1) individuals with a fracture or infection around the shoulder, 2) those who had undergone prior shoulder surgery on the same side, and 3) those who underwent total shoulder replacement arthroplasty. A total of 86 patients were enrolled in this study.

## ARTHROSCOPY

The orthopedic surgeon determined whether surgical repair of the subscapularis tendon was required based on arthroscopic findings. Patients with intact tendon or tears in less than the superior 1/3 tear of the tendon (Lafosse type I or II) were classified into the non-surgical group. Patients with injuries larger than a superior 1/3 tear (Lafosse type III) or an entire full-thickness tendon tear of the tendon (Lafosse type IV) were classified into the surgical repair group (14). Before the arthroscopic procedure, the surgeon was aware of the preoperative MR findings. Arthroscopic reports were retrospectively reviewed to assess the location, size, and repair methods of rotator cuff tear with STT.

## MRI ACQUISITION

MRI was performed using 3T scanners (Achieva or Ingenia; Philips Medical System, Best, the Netherlands) with dedicated shoulder coils. None of the patients were administered intravenous or intra-articular contrast agents. All MRI examinations consisted of T2-weighted modified Dixon (mDixon) images in the axial, oblique coronal (parallel to the long axis of the supraspinatus tendon), and oblique sagittal planes (parallel to the glenohumeral joint); proton density-weighted mDixon images in the oblique coronal plane; and T1-weighted images in the oblique sagittal plane. The mDixon sequences included water-only images and in-phase images. All axial and oblique coronal planes were obtained with a 160 × 160 mm field of view (FOV), 3.0 mm-section thickness, and no intersection gap. All oblique sagittal planes were obtained with a 160 × 160 mm FOV, 4.5-mm section thickness, and 0.45 mm-intersection gap.

## IMAGE ANALYSIS

All parameters were retrospectively reviewed using preoperative MRI. Two readers (a dedicated musculoskeletal radiologist with 24 years of experience and a third-year radiology resident) independently interpreted or measured the MR parameters and resolved all disagreements by consensus. Candidate parameters included MRI diagnoses based on visual assessments using all suspicious direct signs such as alterations in signal intensity, thickness changes, and musculotendinous retraction (10, 12). If an STT was present, it was evaluated for surgical repair.

Indirect MRI parameters included LHBT pathology, PD of the humeral head, humeral rotation, FD, and atrophy of the subscapularis muscle. LHBT tear and malposition were collectively defined as “LHBT pathology.” Findings suggestive of LHBT tears include alterations in signal intensity, contour irregularity, and thickness change. A partial tear was also a positive LHBT tear. Various types of malpositioning were included in this study. The LHBTs located outside the bicipital groove deviate medially within the bicipital groove and move over the

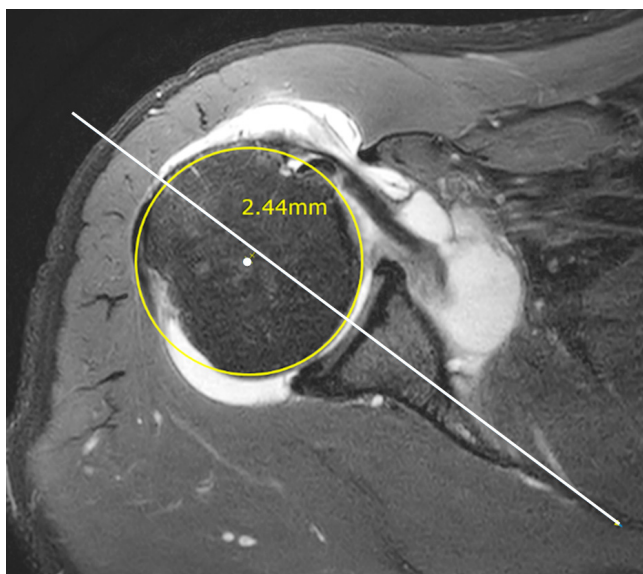
inner rim of the bicipital groove while maintaining partial contact with the groove (12). When the LHBT was completely torn, the positioning of the tendon could not be evaluated.

The PD of the humeral head was assessed in the axial plane at the mid-glenoid level, as confirmed in the sagittal plane. First, a circle was drawn, assuming a circular articular surface of the humeral head. On the circle, two points should overlap the articular surface and one point should overlap the greater tuberosity area. After obtaining the circle with the best fit to the humeral head, the center was determined. Next, a line was drawn from the medial end of the scapula to the midpoint of the glenoid fossa to indicate the transverse axis of the scapula. Next, the distance between the center of the circle and the transverse axis of the scapula was measured. PD was defined as the center of the circle located greater than 2 mm posterior to the scapula (Fig. 1) (13).

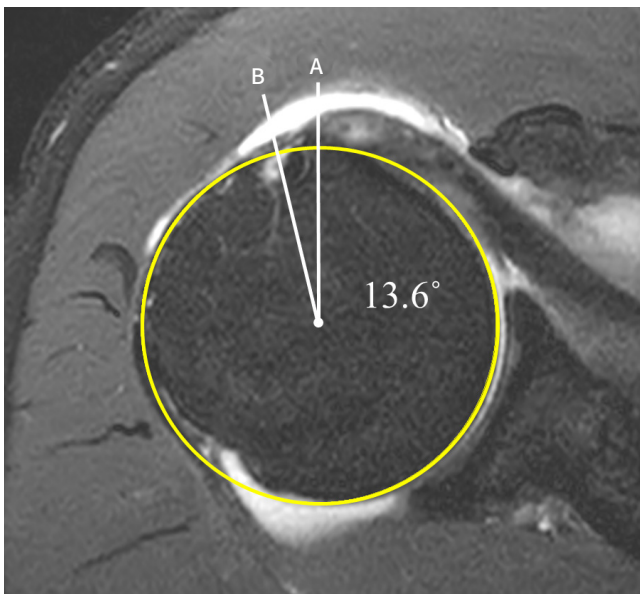
Humeral rotation can cause thickness changes in the subscapularis muscles and tendons. Furthermore, humeral rotation can cause PD of the humeral head (13). This rotation was measured in the most cranial slice that showed a definitive outline of the bicipital groove on the axial plane. First, the circle created when evaluating the PD was drawn. Second, two linear lines were drawn through the center of the circle: one parallel to the sagittal plane and one through the bicipital groove. The angle between the two lines was defined as the humeral rotation (Fig. 2) (13, 15).

FD of the subscapularis muscle was assessed using the Goutallier classification on the Y-view of the T1-weighted oblique sagittal plane, where the scapular spine is in contact with the scapular body (16).

Visual grading and thickness measurements were used to estimate atrophy in the en-face view in the T2 weighted oblique sagittal plane (3). The en-face view was defined as the image in which the glenoid was largest and the base of the coracoid process was adjacent to the glenoid. For visual grading, a base-to-tip line (BTL) was drawn to connect the coracoid tip to the glenoid base. Based on whether the position of the muscle and tendon exceeded the BTL, they were classified into three grades: Grade I, both muscles and tendons above the BTL;



**Fig. 1.** Determining the posterior decentering of the humeral head. White dot: center of the humeral head, white line: transverse axis of the scapula. This patient had posterior decentering of the humeral head because the white dot was located more than 2 mm posterior to the white line.



**Fig. 2.** Estimating the humeral rotation. Two linear lines were drawn through the center of the circle (white dot): one parallel to the sagittal plane (A) and one through the bicipital groove (B). This patient showed 13.6° of humeral external rotation.

Grade II, tendon only above the BTL; and Grade III, no subscapular structures above the BTL. The thickness of the subscapularis was defined as the longest depth perpendicular to the anatomical line connecting the superior and inferior poles of the glenoid (Fig. 3) (3). Ultimately, we evaluated seven candidate imaging parameters consisting of a direct visual assessment and six indirect parameters.

## STATISTICAL ANALYSIS

Continuous variables are expressed as medians and ranges, and categorical variables are expressed as numbers and percentages. Statistical analysis of MR parameters was performed using the Mann-Whitney U test for continuous variables and the chi-square test or Fisher's exact test for categorical variables. Logistic regression analysis was used in multivariate analysis to predict STT requiring repair. In the logistic regression, the odds ratio (OR) with a 95% confidence interval (CI) was used to quantify the strength of the association between the two events and to represent the constant effect of a predictor based on the likelihood of one outcome. To concentrate our investigation on the clinical impact of indirect MR parameters, a subgroup analysis was performed for patients without a visible STT on preoperative MRI. All *p*-values < 0.05 were accepted as statistically significant. Interobserver agreement was evaluated using an intraclass correlation coefficient (ICC) for continuous variables and a Cohen's Kappa coefficient ( $\kappa$  value) for categorical variables. In addition, the 95% CI was calculated. All statistical analyses were performed using MedCalc version 20.218 (Ostend, Belgium).

## RESULTS

The detailed patient characteristics are shown in Table 1. The mean age of the enrolled 86 patients (46 male and 40 female) was  $64.2 \pm 7.6$  years. The mean interval between MRI and surgery was  $3.0 \pm 3.0$  weeks. Arthroscopic findings revealed that 36 (41.9%) patients had in-

Fig. 3. En-face view of the T2-weighted oblique sagittal plane.

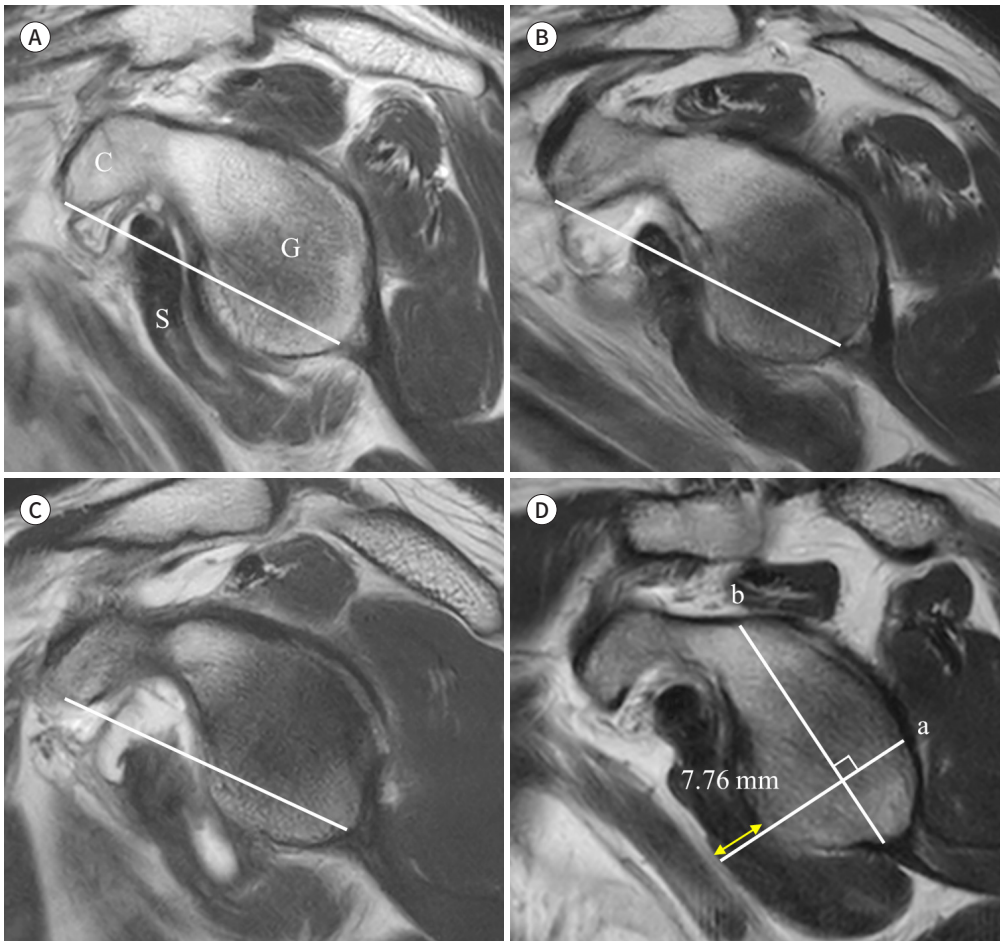
A. Example of grade I atrophy of subscapularis muscle. The subscapularis muscle and tendon exceed the BTL (white line).

B. Example of grade II atrophy shows tendon-only above the BTL.

C. Example of grade III atrophy shows no subscapularis structures above the BTL.

D. Thickness of the subscapularis muscle is measured within the extended anteroposterior glenoid pole line (a), which is drawn perpendicular to the anatomical line connecting the superior and inferior poles of the glenoid (b).

BTL = base-to-tip line, C = coracoid, G = glenoid, S = subscapularis muscle



tact subscapularis tendons, 19 (22.1%) had a less than the superior 1/3 tear, and 31 (36%) had a more than the superior 1/3 tear. Lafosse type III or IV patients underwent surgical repair using the single-row technique with one ( $n = 23$ , 74.2%) or two anchors ( $n = 8$ , 25.8%). There were 33 cases (38.4%) of supraspinatus and infraspinatus tears, 52 cases (60.5%) of supraspinatus tears, and one case (1.2%) of infraspinatus tears. No patients had small rotator cuff tears, 53 (61.6%) had medium-sized tears, and 33 (38.4%) had large-sized tears. All patients underwent arthroscopic rotator cuff repair using the suture bridge technique ( $n = 47$ , 54.7%), single-row repair ( $n = 34$ , 39.5%), or double-row repair ( $n = 5$ , 5.8%). Additional acromioplasty was performed in 78 patients (90.7%).

The sensitivity, specificity, and accuracy of MRIs for detecting STTs were 48.4%, 87.3%, and 73.3%, respectively. Direct diagnosis ( $p < 0.001$ ), LHBT pathology ( $p = 0.002$ ), PD of the hu-

**Table 1.** Patient Characteristics (*n* = 86)

Characteristic	
Age (years)	64.2 ± 7.6
Sex (male/female)	46/40
Affected shoulder (right/left)	55/31
Time from MRI to surgery (weeks)	3.0 ± 3.0
Subscapularis tear	
Intact	36 (41.9)
Less than 1/3	19 (22.1)
More than 1/3	31 (36.0)
Subscapularis repair	
Single row technique with one anchor	23 (74.2)
Single row technique with two anchors	8 (25.8)
Other RCT location	
SSP only	52 (60.5)
ISP only	1 (1.2)
SSP + ISP	33 (38.4)
Other RCT size	
Medium	53 (61.6)
Large	33 (38.4)
Other RCT repair	
Suture bridge technique	47 (54.7)
Single row	34 (39.5)
Double row	5 (5.8)

Values are presented as *n* (%) or mean ± standard deviation.

ISP = infraspinatus, RCT = rotator cuff tear, SSP = supraspinatus

meral head ( $p = 0.012$ ), FD ( $p < 0.001$ ), and BTL grade ( $p = 0.003$ ) were significantly correlated with subscapularis tendon repair. However, humeral rotation and thickness of the subscapularis did not differ between the two groups ( $p = 0.580$  and  $p = 0.461$ , respectively) (Table 2). Table 3 shows the multivariate logistic regression analysis with the enter method to identify the most related independent predictors of STTs requiring surgical repair. Direct diagnosis ( $p = 0.039$ , OR = 2.06), PD of the humeral head ( $p = 0.011$ , OR = 5.14), and FD ( $p = 0.046$ , OR = 2.81) were independent predictors of STT.

Among patients without visible STT on preoperative MRI ( $n = 64$ ), the PD of the humeral head ( $p = 0.002$ ) and LHBT pathology ( $p = 0.032$ ) were independent predictors of occult STT. The PD of the humeral head exhibited relatively high sensitivity and specificity for predicting occult STT (81.3% and 75.0%, respectively). When using the LHBT pathology, the sensitivity and specificity were 65.0% and 72.7%, respectively.

The  $\kappa$  values and ICCs for interobserver agreement in assessing and estimating the MR parameters are presented in Table 2. Interobserver agreement was almost perfect for direct diagnosis ( $\kappa = 0.83$ ), LHBT pathology ( $\kappa = 0.97$ ), PD of the humeral head ( $\kappa = 0.92$ ), and FD ( $\kappa = 0.82$ ). The ICCs for interobserver reliability for measurements of humeral rotation and thickness were 0.99 and 0.95, respectively. There was substantial agreement in the assessment of

**Table 2.** Image Analysis between the Two Groups and Interobserver Agreements

Parameters	Subscapularis Repair (+) (n = 31)	Subscapularis Repair (-) (n = 55)	p-Value	Interobserver Agreement (95% CI)
Direct diagnosis	15 (48.4)	7 (12.7)	< 0.001	$\kappa = 0.83$ (0.70–0.96)
LHBT pathology	13 (41.9)	7 (12.7)	0.002	$\kappa = 0.97$ (0.91–1.00)
Posterior decentering of the humeral head	17 (54.8)	15 (27.3)	0.012	$\kappa = 0.92$ (0.84–1.00)
Humeral rotation (°)	-4 (-41–24)	-7 (-46–30)	0.580	ICC = 0.99 (0.98–0.99)
Fatty degeneration			< 0.001	$\kappa = 0.82$ (0.72–0.93)
Grade 0	10 (32.3)	31 (56.4)		
Grade I	12 (38.7)	24 (43.6)		
Grade II	9 (29.0)	0 (0)		
Atrophic change				
BTL grade			0.003	$\kappa = 0.72$ (0.57–0.86)
Grade I	3 (9.7)	25 (45.5)		
Grade II	25 (80.6)	27 (49.1)		
Grade III	3 (9.7)	3 (5.5)		
Thickness (mm)	7.9 (2.7–20.7)	9.0 (4.1–20.0)	0.461	ICC = 0.95 (0.93–0.97)

Values are presented as n (%) or mean (range).

BTL = base-to-tip line, CI = confidence interval, ICC = intraclass correlation coefficient, LHBT = long head of the biceps tendon

**Table 3.** Multivariate Logistic Regression Analysis to Predict Subscapularis Tendon Tears

Parameters	Estimate	Standard Error	Wald $\chi^2$	p-Value	OR	95% CI
Direct diagnosis	0.724	0.351	4.250	0.039*	2.06	1.04–4.11
LHBT pathology	0.966	0.707	1.867	0.172	2.63	0.66–10.51
Posterior decentering of the humeral head	1.638	0.644	6.467	0.011*	5.14	1.46–18.16
Humeral rotation	-0.002	0.019	0.009	0.924	1.00	0.96–1.04
Fatty degeneration	1.035	0.519	3.977	0.046*	2.81	1.02–7.78
Atrophic change						
BTL grade	1.134	0.640	3.136	0.077	3.11	0.89–10.91
Thickness	0.074	0.082	0.832	0.362	1.08	0.92–1.26

\*Statistically significant.

BTL = base-to-tip line, CI = confidence interval, LHBT = long head of the biceps tendon, OR = odds ratio

atrophic changes using the BTL grade ( $\kappa = 0.72$ ).

## DISCUSSION

Surgical repair of STT was not an uncommon procedure during arthroscopy for rotator cuff tears, accounting for 36.0% (31/86) of the patients. Detecting these clinically significant STT using MRI is challenging because of the low sensitivity of 48.4%, similar to the results of previous studies (7, 10, 17).

Among the several previously proposed MR parameters, the PD of the humeral head was the most influential predictor. It was also the best predictor of occult STT with high sensitivity and specificity. Kim and Seo (13) were the first to report a significant relationship between the



PD and STT. The results of the current study indicate that PD occurred more frequently in patients with high-grade STT, which is consistent with the findings of previous studies. The subscapularis is more closely involved in resisting posterior glenohumeral subluxation than the supraspinatus and infraspinatus-teres minor complexes (18). A previous biomechanical study that showed that the upper half of the subscapularis significantly altered the biomechanics of the shoulder and increased glenohumeral subluxation supports our findings (19).

Several previous studies have suggested that LHBT pathology on MRI may indicate the presence of a STT requiring repair (12, 20, 21). This close relationship between the LHBT pathology and STT could be explained by the anatomy of the biceps pulley. The biceps pulley is formed by the union of the superior fibers of the subscapularis tendon, the coracohumeral ligament, and the superior glenohumeral ligament (21). The current study demonstrated that LHBT pathology was significantly associated with STT requiring repair in the univariate analysis ( $p = 0.002$ ), but not in the multivariate analysis ( $p = 0.172$ ). In the subgroup analysis of patients without a visible STT on preoperative MRI, this was a significant independent predictor ( $p = 0.032$ ). This may be due to the small sample size of the current study. Further studies with larger sample sizes are required to clarify the usefulness of LHBT pathology in predicting STTs.

In the current study, the median value of subscapularis thickness was smaller in patients with clinically significant tears, but the difference was not statistically significant in the current study (7.9 mm vs. 9.0 mm,  $p = 0.461$ ). Scheibel et al. (22) reported no significant difference in the thickness of the lower portion of the subscapularis, and the thickness measured in the en-face view seemed to have limitations in representing atrophic changes. It could be explained that STTs begin in the upper portion along with atrophic changes (14, 23, 24).

Grading using the BTL is suitable for evaluating the volume of the upper portion of the subscapularis. Therefore, the BTL grade appears to reflect the degree of STT in previous studies (3, 10). The current study demonstrated that BTL grade was significantly associated with STT requiring repair in the univariate analysis ( $p = 0.003$ ), but not in the multivariate analysis ( $p = 0.077$ ). This grading system is critical because friction of the subscapularis muscle can be controlled by fluid collection in the subscapularis recess and subcoracoid bursa (25). This fluid collection is associated not only with STT but also with other rotator cuff tears and rotator interval tears (11, 26). In a previous study considering this fluid collection, BTL grade was not a significant independent predictor of STTs (10).

When the rotator cuff tendon, including the subscapularis tendon, is ruptured, retraction of the musculotendinous unit occurs, followed by atrophic changes and FD in the muscles (3, 16). Atrophic change and FD have been recognized as the same process, with a previous study using 'composite muscle atrophy and fatty infiltration grade' as prognostic factor (27-29). In addition, a previous three-dimensional measurement study demonstrated that an increase in the proportion of fat, that is, high-grade FD, was likely driven by muscle atrophy rather than an increase in fat mass (30). Therefore, the Goutallier classification is a grading system that complexly reflects atrophy as well as FD. For this reason, FD using the Goutallier classification better reflected the subscapularis muscle pathology associated with tendon tears than atrophic changes using BTL in the current study.

Many studies have been conducted on indirect parameters to help diagnose STT using pre-

operative MRI. As these parameters were correlated, it was necessary to conduct a multivariate analysis. To the best of our knowledge, this is the first study to investigate independent MR findings for predicting STT requiring repair. The current study suggests that evaluating the PD of the humeral head and FD while investigating the STT on MRI will contribute to an accurate diagnosis.

The current study had several limitations. First, there may be errors in drawing the line, despite well-defined anatomical landmarks. However, in the current study, BTL grades exhibited almost perfect to substantial agreement between the two readers. Although one of the readers was a resident, the interobserver reliability was excellent. Further studies using software with precise measurements are required to prevent measurement errors. Second, the current study focused only on radiologic findings and did not analyze clinical features. Although clinical tests are routinely performed, information on these tests is not available because of the retrospective study design. It may be meaningful to conduct further evaluations, including a correlation analysis between the clinical and MR parameters. Third, this study used a small sample from a single institution. In addition, all inherent biases associated with the retrospective design were possible. Representatively, selection bias occurred by including only a subset of patients who underwent arthroscopic repair of rotator cuff tears. In selecting surgical candidates, surgeons considered the results of previously published studies describing poor prognostic factors for surgical repair (16, 27, 28, 31). This selection bias was likely the reason why patients with massive rotator cuff tears, severe FD, or muscle atrophy were not included in the current study. A large-scale multicenter study with a prospective design is necessary to enhance the reliability and objectivity of the current results.

In conclusion, among various shoulder MRI parameters, PD of the humeral head and FD could predict STT requiring surgical repair. In particular, PD of the humeral head was a significant predictor of occult tears that were not detected on MRI. Interpretation of these findings may contribute to the planning of optimal surgical strategies.

### Author Contributions

Conceptualization, J.J.; data curation, J.Y.; formal analysis, J.J.; investigation, J.J., J.Y., R.J.; methodology, J.J.; resources, J.Y.; supervision, R.J.; validation, K.Y.J.; visualization, R.J.; writing—original draft, J.J.; and writing—review & editing, K.Y.J., L.S.

### Conflicts of Interest

The authors have no potential conflicts of interest to disclose.

### Funding

None

### Acknowledgments

These results were previously presented in presentation form by Ji-hoon Jung, Preoperative MRI Shoulder Findings to Predict Subscapularis Tendon Tear Requiring Repair, the Radiological Society of North America, Nov 2022 (S4-SSMK02).

## REFERENCES

1. Lee H, Ahn JM, Kang Y, Oh JH, Lee E, Lee JW, et al. Evaluation of the subscapularis tendon tears on 3T mag-

- netic resonance arthrography: comparison of diagnostic performance of T1-weighted spectral presaturation with inversion-recovery and T2-weighted turbo spin-echo sequences. *Korean J Radiol* 2018;19:320-327
2. Kappe T, Sgroi M, Reichel H, Daexle M. Diagnostic performance of clinical tests for subscapularis tendon tears. *Knee Surg Sports Traumatol Arthrosc* 2018;26:176-181
  3. Shim JW, Pang CH, Min SK, Jeong JY, Yoo JC. A novel diagnostic method to predict subscapularis tendon tear with sagittal oblique view magnetic resonance imaging. *Knee Surg Sports Traumatol Arthrosc* 2019; 27:277-288
  4. Furukawa R, Morihara T, Arai Y, Ito H, Kida Y, Sukenari T, et al. Diagnostic accuracy of magnetic resonance imaging for subscapularis tendon tears using radial-slice magnetic resonance images. *J Shoulder Elbow Surg* 2014;23:e283-e290
  5. Lee SH, Nam DJ, Kim SJ, Kim JW. Comparison of clinical and structural outcomes by subscapularis tendon status in massive rotator cuff tear. *Am J Sports Med* 2017;45:2555-2562
  6. Matthewson G, Beach CJ, Nelson AA, Woodmass JM, Ono Y, Boorman RS, et al. Partial thickness rotator cuff tears: current concepts. *Adv Orthop* 2015;2015:458786
  7. Ward JRN, Lotfi N, Dias RG, McBride TJ. Diagnostic difficulties in the radiological assessment of subscapularis tears. *J Orthop* 2018;15:99-101
  8. Lin L, Yan H, Xiao J, He Z, Luo H, Cheng X, et al. The diagnostic value of magnetic resonance imaging for different types of subscapularis lesions. *Knee Surg Sports Traumatol Arthrosc* 2016;24:2252-2258
  9. Malavolta EA, Assunção JH, Gracitelli MEC, Yen TK, Bordalo-Rodrigues M, Ferreira Neto AA. Accuracy of magnetic resonance imaging (MRI) for subscapularis tear: a systematic review and meta-analysis of diagnostic studies. *Arch Orthop Trauma Surg* 2019;139:659-667
  10. Xu W, Wang F, Xue Q. Identifying key factors associated with subscapularis tendon tears and developing a risk prediction model to assist diagnosis. *BMC Musculoskelet Disord* 2022;23:393
  11. Sankaya B, Bahadır B, Kaya İ, Oklaz B, Bekin Sankaya PZ, Kanatlı U. Can subcoracoid effusion be a more specific finding for subscapularis tear among rotator cuff pathologies on magnetic resonance imaging? *J Shoulder Elbow Surg* 2023;32:17-23
  12. Kim BR, Lee J, Ahn JM, Kang Y, Lee E, Lee JW, et al. Predicting the clinically significant subscapularis tendon tear: malposition and tear of the long head of the biceps tendon on shoulder magnetic resonance imaging. *Acta Radiol* 2021;62:1648-1656
  13. Kim JH, Seo HW. Relationship of posterior decentering of the humeral head with tear size and fatty degeneration in rotator cuff tear. *Clin Shoulder Elb* 2019;22:121-127
  14. Lafosse L, Jost B, Reiland Y, Audebert S, Toussaint B, Gobezie R. Structural integrity and clinical outcomes after arthroscopic repair of isolated subscapularis tears. *J Bone Joint Surg Am* 2007;89:1184-1193
  15. Updegrave GF, Armstrong AD, Mosher TJ, Kim HM. Posterior displacement of supraspinatus central tendon observed on magnetic resonance imaging: a useful preoperative indicator of rotator cuff tear characteristics. *Arthroscopy* 2015;31:2089-2098
  16. Tsuchiya S, Bois AJ, Matthewson G, Oiwa S, More KD, Lo IKY. The relationship between preoperative Goutallier stage and retear rates following posterosuperior rotator cuff repair: a systematic review. *J Shoulder Elbow Surg* 2023;32:435-443
  17. Foad A, Wijdicks CA. The accuracy of magnetic resonance imaging and magnetic resonance arthrogram versus arthroscopy in the diagnosis of subscapularis tendon injury. *Arthroscopy* 2012;28:636-641
  18. Blasler RB, Soslowsky LJ, Malicky DM, Palmer ML. Posterior glenohumeral subluxation: active and passive stabilization in a biomechanical model. *J Bone Joint Surg Am* 1997;79:433-440
  19. Su WR, Budoff JE, Luo ZP. The effect of posterosuperior rotator cuff tears and biceps loading on glenohumeral translation. *Arthroscopy* 2010;26:578-586
  20. Yoon JS, Kim SJ, Choi YR, Lee W, Kim SH, Chun YM. Medial subluxation or dislocation of the biceps on magnetic resonance arthrography is reliably correlated with concurrent subscapularis full-thickness tears confirmed arthroscopically. *Biomed Res Int* 2018;2018:2674061
  21. Shi LL, Mullen MG, Freehill MT, Lin A, Warner JJ, Higgins LD. Accuracy of long head of the biceps subluxation as a predictor for subscapularis tears. *Arthroscopy* 2015;31:615-619
  22. Scheibel M, Tsynman A, Magosch P, Schroeder RJ, Habermeyer P. Postoperative subscapularis muscle in-

- sufficiency after primary and revision open shoulder stabilization. *Am J Sports Med* 2006;34:1586-1593
23. Bartl C, Salzmann GM, Seppel G, Eichhorn S, Holzapfel K, Wörtler K, et al. Subscapularis function and structural integrity after arthroscopic repair of isolated subscapularis tears. *Am J Sports Med* 2011;39:1255-1262
  24. Yoo JC, Rhee YG, Shin SJ, Park YB, McGarry MH, Jun BJ, et al. Subscapularis tendon tear classification based on 3-dimensional anatomic footprint: a cadaveric and prospective clinical observational study. *Arthroscopy* 2015;31:19-28
  25. Colas F, Nevoux J, Gagey O. The subscapular and subcoracoid bursae: descriptive and functional anatomy. *J Shoulder Elbow Surg* 2004;13:454-458
  26. Grainger AJ, Tirman PF, Elliott JM, Kingzett-Taylor A, Steinbach LS, Genant HK. MR anatomy of the subcoracoid bursa and the association of subcoracoid effusion with tears of the anterior rotator cuff and the rotator interval. *AJR Am J Roentgenol* 2000;174:1377-1380
  27. Kijowski R, Thurlow P, Blankenbaker D, Liu F, McGuine T, Li G, et al. Preoperative MRI shoulder findings associated with clinical outcome 1 year after rotator cuff repair. *Radiology* 2019;291:722-729
  28. Melis B, Nemoz C, Walch G. Muscle fatty infiltration in rotator cuff tears: descriptive analysis of 1688 cases. *Orthop Traumatol Surg Res* 2009;95:319-324
  29. Shin SM, Chai JW, Kim SJ, Park J, You JY. Fatty degeneration and atrophy of rotator cuffs: comparison of immediate postoperative MRI with preoperative MRI. *Investig Magn Reson Imaging* 2016;20:224-230
  30. Vidt ME, Santago AC 2nd, Tuohy CJ, Poehling GG, Freehill MT, Kraft RA, et al. Assessments of fatty infiltration and muscle atrophy from a single magnetic resonance image slice are not predictive of 3-dimensional measurements. *Arthroscopy* 2016;32:128-139
  31. Nakamura H, Gotoh M, Honda H, Mitsui Y, Ohzono H, Shiba N, et al. Posterior decentering of the humeral head in patients with arthroscopic rotator cuff repair. *Clin Shoulder Elb* 2022;25:22-27

## 수술이 필요한 견갑하건 파열을 예측하기 위한 수술 전 어깨 MRI 소견

정지훈<sup>1</sup> · 조영훈<sup>2</sup> · 김여주<sup>3</sup> · 이승훈<sup>3</sup> · 류정아<sup>1\*</sup>

**목적** 본 연구의 목적은 수술 전 MRI의 다양한 간접 소견 중 어떤 소견이 외과적 치료가 필요한 견갑하건 파열을 예측하는 데 가장 주요한 것인지 조사하는 것이다.

**대상과 방법** 총 86명의 환자를 대상으로 수술 전 MRI 영상을 후향적으로 분석하였다. 견갑하건 파열의 직접평가, 이두박근 장두의 병리, 상완골두의 후방위, 상완골 회전, 견갑하근의 지방변성과 위축을 평가하였다. En-face 보기에서 부리돌기의 끝과 관절오목의 기저를 연결한 base-to-tip line (이하 BTL)을 이용한 육안 등급 및 두께 측정을 통해서 위축을 평가하였다.

**결과** 관절경 시술에서 31명(36%)의 환자가 Lafosse type III 또는 IV의 견갑하건 파열을 보여, 재건수술을 받았다. 이두박근 장두의 병리( $p = 0.002$ ), 상완골두의 후방위( $p = 0.012$ ), 견갑하근의 지방 변성( $p < 0.001$ ), BTL 등급( $p = 0.003$ )은 견갑하건 파열과 유의한 상관관계가 있었다. 다변량 분석에서 상완골두의 후방위( $p = 0.011$ , odds ratio [이하 OR] = 5.14)와 견갑하근의 지방변성( $p = 0.046$ , OR = 2.81)은 견갑하건 파열의 독립적인 예측인자였다.

**결론** 상완골두의 후방위와 지방변성은 견갑하건 파열 진단에 도움이 될 수 있다. 이러한 결과를 판독하는 것은 최적의 수술 전략을 계획하는 데 기여할 수 있다.

한양대학교 의과대학 한양대학교 구리병원 <sup>1</sup>영상의학과, <sup>2</sup>정형외과,  
<sup>3</sup>한양대학교 의과대학 한양대학교 서울병원 영상의학과