

# Intestinal Anisakiasis Treated Successfully with Prednisolone and Olopatadine Hydrochloride

Hideki Toyoda<sup>a</sup> Kyosuke Tanaka<sup>b</sup>

<sup>a</sup>Happy GI Clinic, Kameyama, Japan; <sup>b</sup>Department of Endoscopic Medicine, Mie University Hospital, Tsu, Japan

## Keywords

*Anisakis* · Small intestine · Prednisolone · Histamine antagonists · Ambulatory care

## Abstract

The clinical characteristic of gastrointestinal anisakiasis is severe abdominal pain after eating raw fish. Intestinal anisakiasis is more uncommon than gastric anisakiasis. Most patients with intestinal anisakiasis need hospitalization because anisakiasis can cause intestinal obstruction, ileus, peritonitis or intestinal perforation. We report a case of intestinal anisakiasis. A 43-year-old woman presented with symptoms of intermittent abdominal pain 2 days after eating raw fish. Her brother had eaten the same food and had been suffering from gastric anisakiasis. Abdominal ultrasonography in this patient showed localized jejunal wall thickening with dilated lumen of proximal jejunum and ascites. According to the clinical course and examinations, she was diagnosed with intestinal anisakiasis. Administration of prednisolone 5 mg/day and olopatadine hydrochloride 10 mg/day improved her symptoms quickly without hospitalization. Prednisolone was administered for 10 days, and olopatadine hydrochloride was administered for a total of 6 weeks according to ultrasonographic findings. Six months after the treatment, the abdominal ultrasonography demonstrated normal findings. This case demonstrates that ultrasonography was quite useful for the diagnosis and surveillance of intestinal anisakiasis. Furthermore, treatment with corticosteroid and an antiallergic agent could be an option for patients with intestinal anisakiasis.

© 2016 The Author(s)  
Published by S. Karger AG, Basel

## Introduction

Anisakiasis is a human disease caused by the larval nematodes of *Anisakis* species and *Pseudoterranova decipiens* [1]. Larvae are ingested when people consume contaminated raw fish. Dolphins or other marine mammals are hosts to adult *Anisakis* worms, and their presence in coastal waters leads to increased larval contamination causing heavy infections in fish such as mackerel [2]. Human anisakiasis is peculiar because this parasite is not adapted to live in humans and infection is transitory. *Anisakis* larvae will die within 14 days in a human body; however, persistent inflammation and granuloma can remain [3]. Since *Anisakis* larvae die in the course of time, enteric anisakiasis is generally alleviated by conservative treatment; however, there have been reports of a worm body penetrating the intestinal wall into the abdominal cavity [4].

Anisakiasis commonly involves the stomach, but rarely the intestine. A large study conducted in Japan revealed that only 567 (4.5%) of 12,586 anisakiasis cases involved the intestine [5]. Intestinal anisakiasis usually presents with lower abdominal pain, which settles conservatively [6]. However, most patients with intestinal anisakiasis have needed hospitalization because it can cause intestinal obstruction, ileus, peritonitis or intestinal perforation [7–10]. The most effective treatment for intestinal anisakiasis has not yet been established.

Here, we present a case of intestinal anisakiasis that was diagnosed by abdominal ultrasound and was treated successfully with oral administration of prednisolone and olopatadine hydrochloride without hospitalization.

## Case Report

A 43-year-old woman with a history of allergic rhinitis complained of intermittent severe abdominal pain and came to the clinic within 5 h after onset of this symptom. She and her brother had eaten the same food of pickled mackerel (raw fish) together 2 days before the onset, and her brother suffered from gastric anisakiasis (fig. 1), diagnosed the day before her onset. Her blood pressure was 112/70 mmHg, pulse was 62 bpm, and body temperature was 36.4°C. On physical examination, spontaneous pain and tenderness was noted on palpation over the periumbilical region; however, muscle defense and rebound tenderness were not present. Laboratory data showed slight increases in IgE-RIST level (236 IU/ml; normal range <170 IU/ml) and the serum titer of anti-*Anisakis* IgG/A antibody (1.75; normal range <1.50). Abdominal ultrasonography revealed marked local edema in a part of the jejunal wall (12 cm long, 9 mm thick), dilatation of the oral sided lumen with fluid accumulation, and ascites (fig. 2). In the edematous jejunal wall, mucosa and submucosal layers were thickened with a normal structure of layers. An *Anisakis* body was not detected by ultrasonography.

According to the clinical course and examinations, she was diagnosed with intestinal anisakiasis. We advised her to seek hospital admission, but she rejected hospitalization and chose conservative ambulatory treatment as an outpatient. She was treated with oral administration of prednisolone 5 mg and olopatadine hydrochloride 10 mg daily. After starting the medication, the patient's symptoms improved immediately. Three days after the onset, ultrasound showed that the jejunal wall thickening was diminished, the luminal dilatation disappeared and ascites was reduced. Prednisolone was administered for a total of 10 days and olopatadine hydrochloride for 14 days because *Anisakis* can live for maximally 2 weeks, and its body could remain in the intestinal wall for several days even if it had died. Two weeks later, the patient did not have any abdominal symptoms; however, ultrasound

showed a remaining unilateral wall thickening in the jejunum, approximately 3 cm long (fig. 3). Therefore, olopatadine sulfate was administered for 28 additional days (total, 42 days). Six months after the treatment, the patient had no abdominal symptom, and the abdominal ultrasonography was normal.

## Discussion

The clinical characteristic of gastrointestinal anisakiasis is severe abdominal pain after eating raw fish. Nausea, ascites and peritonitis are often observed, and intestinal obstruction and ileus have been seen in patients with intestinal anisakiasis [10]. The annual incidence of intestinal anisakiasis in Japan is estimated to be about 3.0 per 1 million people per year [10]. Patients with intestinal anisakiasis should be treated initially with conservative therapy. In several reports, patients have undergone fasting, fluid infusion, nasogastric tube or long tube insertion and received administration of antibiotics as conservative therapy [7–9]. However, in a previous report, the prevalence of ileus, perforation, bleeding and intussusception were 50, 8, 2 and 0.5%, respectively. Seven percent of the patients needed surgical treatment. The average lengths of stay were 9.6 and 13.2 days in non-surgical and surgical cases, respectively [10].

Human anisakiasis comprises mostly allergic and digestive symptoms, although extradiigestive manifestations have also been observed occasionally. In the previous report, 5 patients with acute, established intestinal obstruction by *Anisakis simplex* were treated with intravenous corticosteroids (6-methylprednisolone 1 mg/kg/24 h, 5 days), which resulted in a dramatic clinical and radiologic improvement in all 5 patients [11]. In a case report, it was demonstrated that an antiallergic drug and oral administration of 5 mg prednisolone were useful as a conservative treatment in patients with gastric anisakiasis [12].

The small intestine has a very thin wall and narrow lumen compared with the stomach, and thus, intestinal anisakiasis can cause severe complications. Matsuo et al. reported two patients with intestinal anisakiasis who needed surgical operation on the 23rd and 35th in the hospital [13]. Therefore, we decided that this patient needed strong and long-term (over 5 weeks) antiallergic therapy. Subsequently, oral administration of prednisolone and olopatadine hydrochloride provided a dramatic improvement of her abdominal symptoms. In the outpatient clinic, a lower dose of prednisolone was easier to administer firstly and we administered antihistamine agent additionally. Although there are some reports that show the effect of corticosteroid for anisakiasis, there has been no report of antihistamine for anisakiasis. A prospective study or reports of a larger number of patients is required to confirm the effect of antihistamine for anisakiasis. For this type of infection it has been reported that ultrasonography [14, 15] and CT [16] were useful for establishing a diagnosis. In this case, ultrasonography was quite useful for the diagnosis and surveillance during the conservative treatment.

This case suggests that prompt administration of corticosteroid and an antiallergic agent for intestinal anisakiasis can improve abdominal symptoms immediately and help to avoid complications, such as ileus, peritonitis and perforation. However, the appropriate medication cannot be predetermined because it might depend on patients' individual condition. Furthermore, ambulatory treatment should be limited to young or middle-aged patients without severe concomitant diseases, because complications could cause a critical situation in elderly patients.

In conclusion, we reported that a case of intestinal anisakiasis was diagnosed by abdominal ultrasound and was successfully treated with administration of prednisolone and olopatadine hydrochloride without hospitalization. Surveillance with ultrasonography was quite useful to establish disease condition. Treatment with corticosteroid and an antiallergic agent could be an option for patients with intestinal anisakiasis.

### Statement of Ethics

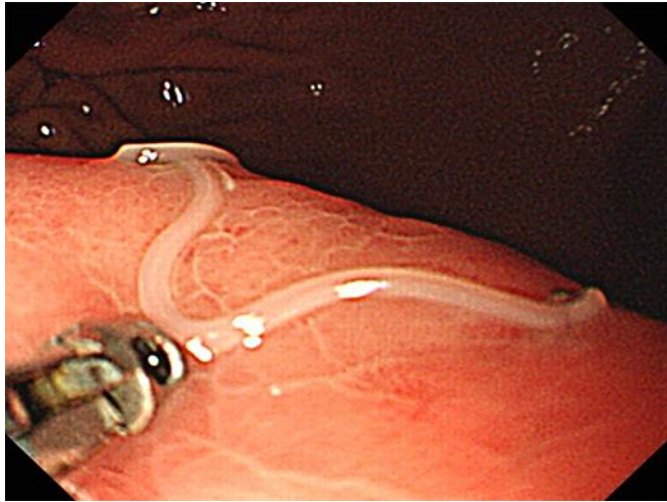
The authors have no ethical conflicts to disclose.

### Disclosure Statement

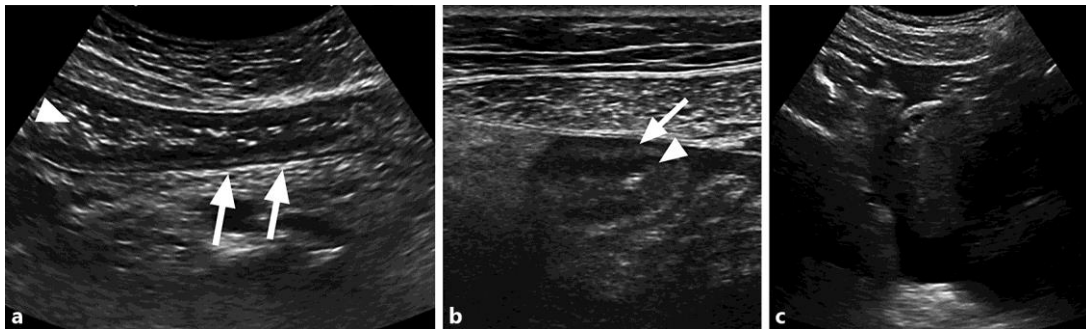
The authors declare that they have no competing interests.

### References

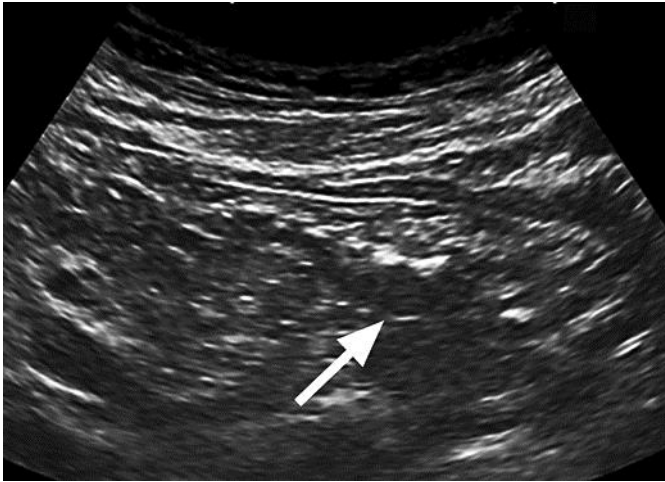- 1 Sakanari JA, McKerrow JH: Anisakiasis. *Clin Microbiol Rev* 1989;2:278–284.
- 2 Moore DA, Girdwood RW, Chiodini PL: Treatment of anisakiasis with albendazole. *Lancet* 2002;360:54.
- 3 Audicana MT, Kennedy MW: Anisakis simplex: from obscure infectious worm to inducer of immune hypersensitivity. *Clin Microbiol Rev* 2008;21:360–379.
- 4 Sasaki T, Fukumori D, Matsumoto H, Ohmori H, Yamamoto F: Small bowel obstruction caused by anisakiasis of the small intestine: report of a case. *Surg Today* 2003;33:123–125.
- 5 Ishikura H: Epidemiological aspects of intestinal anisakiasis and its pathogenesis; in Ishihara H, Kikuchi K (eds): *Intestinal Anisakiasis in Japan*. Tokyo, Springer, 1990, pp 3–21.
- 6 Akbar A, Ghosh S: Anisakiasis – a neglected diagnosis in the West. *Dig Liver Dis* 2005;37:7–9.
- 7 Ishida M, Harada A, Egawa S, Watabe S, Ebina N, Unno M: Three successive cases of intestinal anisakiasis. *Dig Surg* 2007;24:228–231.
- 8 Takano Y, Gomi K, Endo T, Suzuki R, Hayashi M, Nakanishi T, Tateno A, Yamamura E, Asonuma K, Ino S, Kuroki Y, Nagahama M, Inoue K, Takahashi H: Small intestinal obstruction caused by anisakiasis. *Case Rep Infect Dis* 2013;2013:401937.
- 9 Shrestha S, Kisino A, Watanabe M, Itsukaichi H, Hamasuna K, Ohno G, Tsugu A: Intestinal anisakiasis treated successfully with conservative therapy: importance of clinical diagnosis. *World J Gastroenterol* 2014;20:598–602.
- 10 Yasunaga H, Horiguchi H, Kuwabara K, Hashimoto H, Matsuda S: Clinical features of bowel anisakiasis in Japan. *Am J Trop Med Hyg* 2010;83:104–105.
- 11 Ramos L, Alonso C, Guilarte M, Vilaseca J, Santos J, Malagelada JR: Anisakis simplex-induced small bowel obstruction after fish ingestion: preliminary evidence for response to parenteral corticosteroids. *Clin Gastroenterol Hepatol* 2005;3:667–671.
- 12 Yamamoto K, Kurihara T, Fukuo Y: A unique and simple treatment method for anisakiasis (in Japanese). *Nihon Ika Daigaku Igakkai Zasshi* 2012;8:179–180.
- 13 Matsuo S, Azuma T, Susumu S, Yamaguchi S, Obata S, Hayashi T: Small bowel anisakiasis: a report of two cases. *World J Gastroenterol* 2006;12:4106–4108.
- 14 Ido K, Yuasa H, Ide M, Kimura K, Toshimitsu K, Suzuki T: Sonographic diagnosis of small intestinal anisakiasis. *J Clin Ultrasound* 1998;26:125–130.
- 15 Shirahama M, Koga T, Ishibashi H, Uchida S, Ohta Y, Shimoda Y: Intestinal anisakiasis: US in diagnosis. *Radiology* 1992;185:789–793.
- 16 Shibata E, Ueda T, Akaike G, Saida Y: CT findings of gastric and intestinal anisakiasis. *Abdom Imaging* 2014;39:257–261.



**Fig. 1.** Endoscopic image of the patient's brother. An *Anisakis* larva was seen in the stomach, and the adjacent mucosa was swollen.



**Fig. 2.** Images of abdominal ultrasonography of the patient. **a** Longitudinal image. In a part of the jejunum, a markedly edematous wall (arrows) and dilatation of the oral sided lumen (arrowhead) were seen. **b** Cross-sectional image. In the edematous jejunal wall, mucosa (arrowhead) and submucosal (arrow) layers were thickened. **c** Ascites was seen in Douglas' pouch.



**Fig. 3.** Abdominal ultrasound image 15 days after onset. Unilateral wall thickening was seen in the jejunum (arrows).