

Postoperative pulmonary embolism in a three year old with Klippel–Trenaunay syndrome

Jana Hudcova¹
 Monica Kleinman²
 Daniel Talmor¹

¹Department of Anesthesia, Critical Care and Pain Medicine, Beth Israel Deaconess Medical Center and Harvard Medical School, Boston, MA, USA; ²Department of Anesthesia, Division of Critical Care Medicine, Children's Hospital Boston and Harvard Medical School, Boston, MA, USA

Abstract: Massive pulmonary embolism (PE) in a small child is a rare event and unified guidelines for its treatment are missing. Timely diagnosis and management of massive pulmonary embolism is of crucial importance for a good outcome. We describe a unique management of PE causing oxygenation failure using a combination of catheter extraction technique, and regional thrombolysis on top of systemic heparin administration and inferior vena cava filter placement. Pulmonary hypertension was treated with inhaled nitric oxide. We believe that catheter extraction technique and regional thrombolysis is an option to consider provided that resources and expertise are available. Preoperative placement of an inferior vena cava filter should be contemplated in such high risk situations.

Keywords: embolectomy, regional thrombolysis, inferior vena cava filter, inhaled nitric oxide

Introduction

Klippel–Trenaunay syndrome (KTS) is a rare congenital anomaly characterized by venous and lymphatic abnormalities, cutaneous capillary malformations, and hypertrophy of soft tissue and bone. KTS is usually isolated to one extremity; however any part of the body may be affected. Deep venous thrombosis (DVT) with a pulmonary embolism (PE) has been described in these patients,¹ though children have a lower rate of thromboembolic episodes. We report a life-threatening PE and its management in a child after radical resection of a KTS vascular malformation involving the right calf and adjacent tissues.

Case report

A 3-year-old boy (weight 22 kg), with KTS involving the right lower extremity, pelvis and genitalia was admitted to the medical-surgical intensive care unit (MSICU) after resection of his right lower extremity malformation. Except of his malformation he was a healthy child with normal kidney and liver function tests and no underlying pathology in hemostasis. The operation lasted 8.5 hours and was complicated by major blood loss (estimated blood loss 3400 mL). The patient remained intubated because of extensive volume resuscitation with blood products (2265 mL packed red blood cells, 436 mL fresh frozen plasma, and 6 units of platelets) and crystalloid (8900 mL). Patient was anticoagulated with low molecular weight heparin (LMWH), enoxaparin, for a few weeks prior to surgery. The drug was discontinued the day before the operation, and restarted on postoperative day (POD) 1 at a dose of 10 mg subcutaneously twice per day. On POD 2 a peripherally inserted central catheter was placed, active diuresis was initiated, and he began to wean from mechanical ventilation. On POD 3 the patient experienced a sudden episode of agitation, oxygen desaturation to 55%, and drop of end tidal partial pressure of carbon dioxide ($p_{ET}CO_2$) from 40 s to 24 mmHg. Oxygenation slowly improved to 90% after administration of 100% oxygen and an increase in positive end-expiratory pressure (PEEP) from

Correspondence: Jana Hudcova
 Department of Surgical Critical Care,
 Lahey Clinic, 41 Mall Road, Burlington,
 MA 01805, USA
 Tel +1 617 650 4012
 Fax +1 781 744 2273
 Email jana.hudcova@lahey.org

5 mmHg to 16 mmHg. An arterial blood gas revealed a partial pressure of carbon dioxide ($p_a\text{CO}_2$) of 75 mmHg and partial pressure of oxygen ($p_a\text{O}_2$) of 62 mmHg on a FiO_2 of 1.0. PE was suspected and immediate systemic anticoagulation with unfractionated heparin (UFH) was initiated using a bolus dose of 80 units/kg followed by an infusion at a rate of 18 units/kg/hour. Urgent pulmonary CT angiography showed a large filling defect in the right main pulmonary artery (PA) (Figure 1) and a number of smaller defects in the peripheral PA branches. In light of respiratory instability the patient was transferred to the interventional radiology suite. Pulmonary arteriogram via the right internal jugular vein confirmed a large thrombus in the right PA. A successful transcatheter pulmonary embolectomy was followed by thrombolysis with 2 mg of recombinant tissue plasminogen activator (tPA), alteplase, injected through the PA catheter. The same dose of alteplase was repeated once and an inferior vena cava (IVC) filter was placed. Post-procedure angiogram revealed recanalized right PA with persistent smaller defects in upper and lower lobe branches. Systemic heparinization with UFH continued during thrombolysis as well as after arrival to MSICU. Heparinization was monitored by measuring

heparin levels with a goal of 0.3–0.5 units/mL. Trans-thoracic echocardiogram (TTE) confirmed a dilated right ventricle (RV) with elevated PA pressure (mean PA pressure equaled $\frac{1}{3}$ – $\frac{1}{2}$ of mean systemic pressure) and dopamine 5 $\mu\text{g}/\text{kg}/\text{min}$ was initiated to support RV function. Treatment with inhaled nitric oxide (iNO) started for pulmonary hypertension as well as for ventilation perfusion (VQ) mismatch. Within 24 hours, the patient experienced an episode of hypotension and deterioration of gas exchange (Table 1); however, follow-up pulmonary angiography showed no new emboli, unchanged angiogram, and a still elevated PA pressure of 32/22 mmHg. Patient was resuscitated with intravenous crystalloids and dopamine and epinephrine was added for a short period of time. Three days after the embolectomy, the patient bled extensively and required multiple blood transfusions. Heparin was discontinued and pressure dressings were applied. No coagulation factors were transfused and protamine was not administered. UFH levels drifted to a value less than 0.05 units/min. After resolution of bleeding UFH drip was resumed. A follow-up TTE confirmed good biventricular function with normal PA pressures. Patient was weaned off dopamine, iNO, and extubated within the

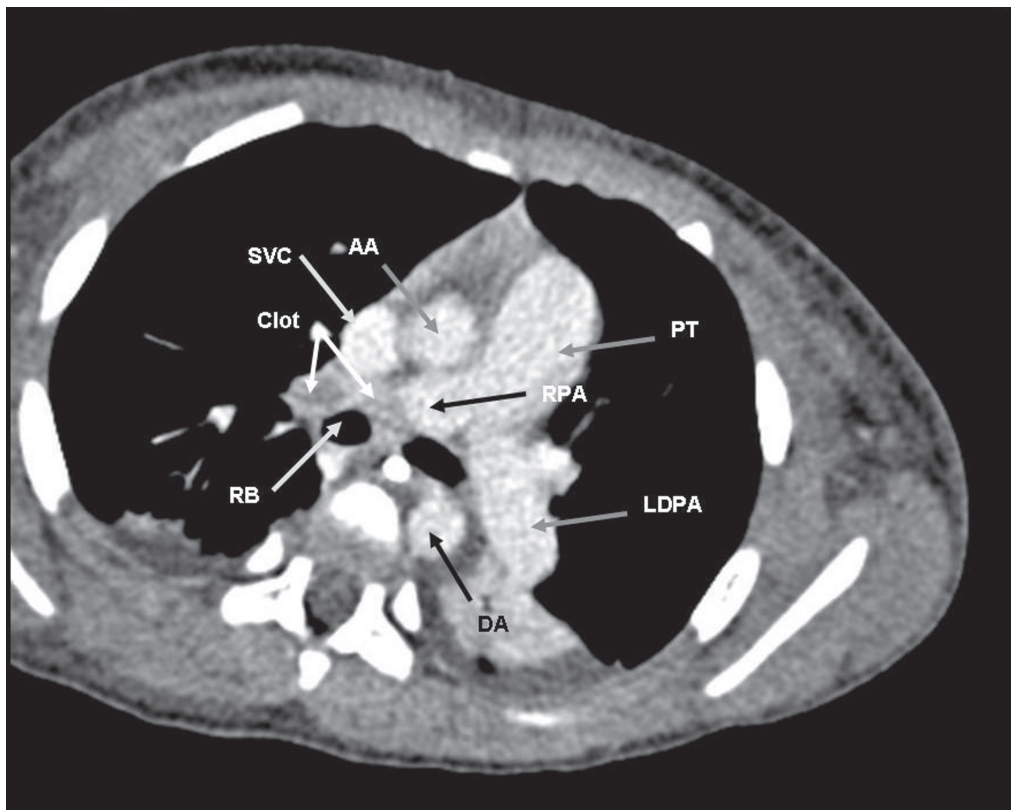


Figure 1 Filling defect in the right main pulmonary artery.

Abbreviations: AA, ascending aorta; DA, descending aorta; LDPA, left descending pulmonary artery; PT, pulmonary trunk; RB, right bronchus; RPA, right pulmonary artery; SVC, superior vena cava.

next few days. Subsequent lung perfusion scan showed good perfusion of all lung units (Figure 2). UFH drip was switched to LMWH subcutaneously. The patient's IVC filter was removed in the interventional radiology suite prior to discharge from hospital one month after its insertion.

Discussion

All patients with KTS are at high risk of DVT and PE and may require long term thromboprophylaxis.^{1,2} Anticoagulation is of vital importance in the perioperative setting or in trauma victims with this condition. Our patient developed massive PE despite the use of prophylactic anticoagulation with LMWH, which was interrupted only for 24 hours in the immediate peri-operative period.

PE in children is rare event and has not been extensively studied. The fibrinolytic system in the pediatric population differs from the one in adults;³ however controlled studies are unavailable and treatment regimens of PE are usually extrapolated from the adult guidelines,⁴ which are outlined here.

The mainstay of PE therapy is anticoagulation with either UFH or LMWH.

In massive PE or where subcutaneous absorption is a concern, an intravenous UFH is a preferred antithrombotic agent. The recommended initial dose is an intravenous bolus of 80 units/kg followed by intravenous infusion 18 units/kg/h. Therapeutic effect is monitored by measuring either activated partial thromboplastin time or heparin levels. Subcutaneously administered LMWH is an effective alternative of UFH for treatment of PE in patients without hemodynamic compromise.

While antithrombotic agents or anticoagulants prevent further thrombus formation; clot dissolution is achieved by thrombolysis. Thrombolytic agents, also known as plasminogen activators, initiate fibrinolysis by conversion of plasminogen to plasmin, the main fibrinolytic enzyme. Since plasmin breaks fibrin in occlusive as well as hemostatic plug, bleeding may result.

Because of risk of hemorrhage and no mortality benefit when compared to treatment with anticoagulants alone,⁴ thrombolysis is recommended only in hemodynamically unstable PE with high risk of death and low risk of bleeding and in patients with poor prognosis due to right ventricular failure or severely compromised oxygenation.⁴ Agents with a short half-life, like tPA ($T_{1/2} = 5$ min), are usually administered by infusion, while derivatives of tPA with longer half-life such as reteplase or TNK-t-PA ($T_{1/2} = 15$ and 20 minutes, respectively) may be given as a bolus.⁵ Management of PE by means of interventional catheterization techniques as well as surgical embolectomy should be restricted only to highly compromised patients who cannot receive thrombolytics.⁴

There are few case reports and case series depicting treatment of acute PE in children with thrombolytic agents^{6,7} and surgical embolectomy.⁸ Cannizzaro and colleagues described an administration of tPA by catheter into two branches of PA in a 10-year-old girl with a massive PE and echocardiographic evidence of reduced right ventricular function.⁶ They used two boluses of tPA followed by a continuous infusion. Intravenous UFH was co-administered as an anticoagulant. Treatment with tPA was complicated by large hematoma in the groin area. Maeda and colleagues

Table 1 Key hemodynamic parameters, gas exchange indicators, doses of inotropic agents as well as inhaled nitric oxide dose during and after an episode of PE

	Event (PE)	IR suite	12 h post event	24 h post event	48 h post event	96 h post event	5 days post event
MAP (mmHg)	50–60	65–68	60–65	60 s	60 s	65	68
HR (bpm)	106–132	90	117	110–120	100–125	100–120	100 s
PAP _{mean} (mmHg)	NA	30–32	NA	28	NA	NA	NA
p _a O ₂ (mmHg)	62	349	173	72.4	92	130	107
p _{ET} CO ₂ (mmHg)	24–28	NA	NA	NA	NA	NA	NA
p _a CO ₂ (mmHg)	75	66–70	53	77.8	53	64	63
pH	7.23	7.25	7.35	7.18	7.40	7.31	7.33
Lactate (mmol/L)	NA	0.6–0.8	NA	NA	NA	NA	NA
Dopamine (µg/kg/min)	0	0	5–10	5–10	5–16	0–5	0
Epinephrine (µg/kg/min)	0	0	0	0	0.05–0.1	0	0
iNO (ppm)	0	0	5–20	20–30	20	4–5	2

Abbreviations: HR, heart rate; iNO, inhaled nitric oxide; IR, interventional radiology; MAP, mean arterial pressure; PAP_{mean}, mean pulmonary artery pressure; p_aO₂, partial pressure of arterial oxygen; p_{ET}CO₂, partial pressure of end-tidal carbon dioxide; p_aCO₂, partial pressure of carbon dioxide; PE, pulmonary embolism.

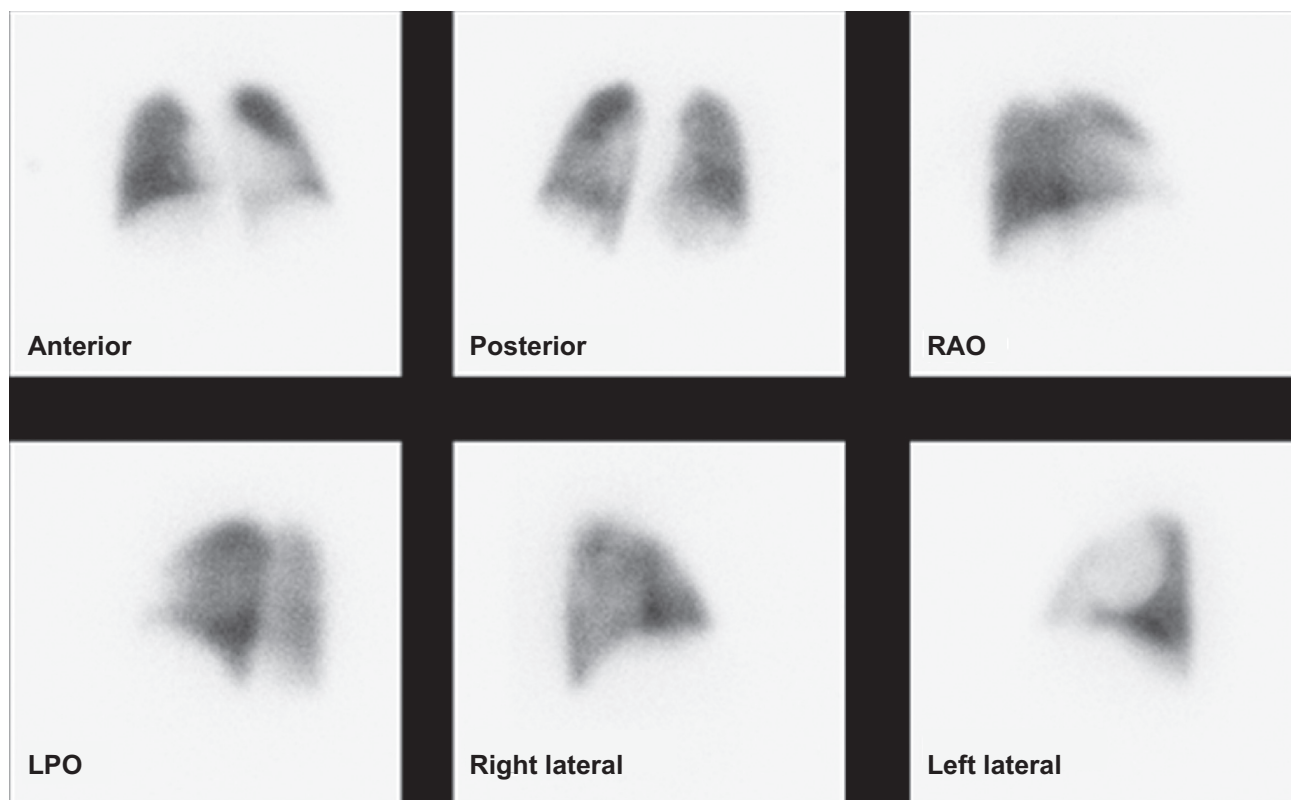


Figure 2 Lung perfusion scan.

Abbreviations: RAO, right anterior oblique; LPO, left posterior oblique.

administered thrombolytics successfully through the central venous catheter in a hemodynamically stable 4-year-old boy with poor oxygenation shortly after total cavopulmonary shunt.⁷ Combination of tPA (bolus) and urokinase (infusion) were used together with an infusion of UFH. Poor oxygenation persisted and required treatment with iNO. Follow-up angiography revealed clot resolution.

We present a successful treatment of massive PE in a 3-year-old patient with oxygenation failure employing combination of interventional catheterization technique and regional thrombolysis. As we mentioned above, any embolectomy should be reserved only for highly unstable patients where thrombolytics are being contraindicated or has already failed. Our patient had significantly compromised oxygenation, however thrombolytics were contraindicated because of recent major vascular resection and high risk of bleeding. Catheter extraction technique was chosen over an open approach since expertise was available, PA catheter was *in situ* (for selective pulmonary angiography) and the possibility of combining two techniques emerged. Risk of hemorrhage was weighed against the risk of significant damage and/or death from progressive hypoxemia and it was

decided to proceed with thrombolysis. Availability of tPA, a thrombolytic agent that preferentially activates fibrin-bound plasminogen and not circulating plasminogen supported our treatment alternative. Streptokinase, urokinase, and reteplase do not have this discriminative property and resulting systemic plasminemia causes degradation of fibrinogen and other clotting factors, and more bleeding. Nonetheless, the use of a fibrin-specific agent does not eliminate the risk of bleeding and an intervention should be undertaken only if all means for resuscitation including blood products and antifibrinolytics are immediately available. Procedure in this patient was performed by skilled interventional radiologist in fully equipped radiological suite with on-site critical care specialist and stand-by blood products.

In vivo experiments show that flow in pulmonary circulation with embolus in its branches is almost instantly diverted into nonoccluded vessels.⁹ However fragmentation of the thrombus enables flow into previously occluded PA.⁹ We believe that repeated administration of tPA contributed to sustained patency of PA based on the evidence that supports prolonged fibrinolysis after tPA administration despite its short half-life¹⁰ as well as the fact that the

agent was injected into recently opened PA after catheter instrumentation.

To prevent recurrent PE, an IVC filter was inserted immediately after thrombolysis. Study of patients from the International Cooperative Pulmonary Embolism Registry (ICOPER) evaluated the effect of adjunctive therapies, such as thrombolysis and IVC filter placement on the clinical outcome of patients with massive PE.⁵ While thrombolytic therapy did not reduce mortality or recurrent PE, none of the patients with IVC filter developed recurrent PE and 90-day mortality was reduced. It is unknown whether pre-operative placement of the IVC filter in our patient would have prevented the thromboembolic episode and subsequent complications of therapy that we observed. In small children, IVC filter placement is technically challenging and carries the risk of IVC injury and thrombosis.^{11,12} As with adults, this technique does not provide complete protection against life-threatening PE.

Our patient developed RV dysfunction with elevated PA pressures as per TTE. Dopamine was started to support failing RV and iNO was initiated to unload the RV as well as improve VQ matching. Dose of iNO was titrated up to 30 ppm to improve oxygenation. Weaning off iNO was a lengthy process lasting few days because of frequent episodes of desaturation initially.

Forty-eight hours after the embolectomy/thrombolysis, the patient experienced hypotension, hypoxemia, required higher doses of dopamine, and, for a short period of time, epinephrine. The exact nature of hypotension was not clear because the repeat angiography revealed patent right PA and TTE showed decreasing PA pressure, and improvement of right ventricular function. Some hypovolemia secondary to third space losses in this sick and very edematous patients might have been contributing factors.

Bleeding, which occurred three days after thrombolysis, was almost certainly related to use of anticoagulants, considering the short half life of thrombolytic agents. Discontinuation of UFH, pressure dressing, and blood transfusions were the only measures to treat hemorrhage.

Conclusion

We present a unique management of PE in a child with oxygenation failure and recent major vascular surgery using a catheter extraction technique combined with regional thrombolysis followed by IVC filter placement. We believe that prompt diagnosis and expertise of hospital staff as well as availability of resources contributed to a good patient outcome in our case.

Disclosure

The authors report no conflicts of interest in this work.

References

- Huiras EE, Baner CJ, Eichenfield LF, Pelech AN, Drolet BA. Pulmonary thromboembolism associated with Klippel-Trenaunay Syndrome. *Pediatrics*. 2005;116(4):e596–e600.
- Karalezli A, Sevgili S, Ernam Turgut D, Hasanoglu A, Hasanoglu HC. Pulmonary embolism in a patient with Klippel-Trenaunay-Weber syndrome. *Tuberk Toraks*. 2006;54:281–287.
- Albisetti M. The fibrinolytic system in children. *Semin Thromb Hemost*. 2003;29(4):339–347.
- Kearon C, Kahn SR, Agnelli G, Goldhaber S, Raskob GE, Comerota AJ. Antithrombotic therapy for venous thromboembolic disease. American College of Chest Physicians Evidence-Based Clinical Practice Guidelines (8th Edition). *Chest*. 2008;133:454S–545S.
- Weitz JI, Stewart RJ, Fredenburgh JC. Mechanism of action of plasminogen activators. *Thromb Haemost*. 1999;82(2):974–982.
- Cannizzaro V, Berger F, Kretschmar O, Saurenmann R, Knirsch W, Albisetti M. Thrombolysis of venous and arterial thrombosis by catheter-directed low-dose infusion of tissue plasminogen activator in children. *J Pediatr Hematol Oncol*. 2005;27:688–691.
- Maeda K, Murakami A, Hishi T, Takamoto S. Successful thrombolytic therapy for acute massive pulmonary thrombosis after cavo-pulmonary shunt. *Jpn J Thorac Cardiovasc Surg*. 2002;50:451–454.
- Ngaage DL, Ahmed I, Chandrasekaran V. Pulmonary embolectomy in a child. *Ann Thorac Surg*. 2000;69:1248–1249.
- Schmitz-Rode T, Kilbinger M, Günther RW. Simulated flow pattern in massive pulmonary embolism: significance for selective pulmonary thrombolysis. *Cardiovasc Intervent Radiol*. 1998;21(3):199–204.
- Eisenberg PR, Sherman LA, Tiefenbrunn AJ, Ludbrook PA, Sobel BE, Jaffe AS. Sustained fibrinolysis after administration of t-PA despite its short half-life in the circulation. *Thromb Haemost*. 1987;57(1):35–40.
- Cahn MD, Rohrer MJ, Martella MB, Cutler BS. Long-term follow-up of Greenfield inferior vena cava filter placement in children. *J Vasc Surg*. 2001;34(5):820–825.
- Haider EA, Rosen JC, Torres C, Valenti DA. Serial repositioning of a Gunther tulip retrievable inferior vena cava filter in a pediatric patient. *Pediatr Radiol*. 2005;35:1135–1138.

