

## Open Access

## Efficacy of the Over-the-Scope Clip System for Treatment of Gastrointestinal Fistulas, Leaks, and Perforations: A Korean Multi-Center Study

Hang Lak Lee<sup>1</sup>, Joo Young Cho<sup>2</sup>, Jun-Hyung Cho<sup>3</sup>, Jong Jae Park<sup>4</sup>, Chan Gyoo Kim<sup>5</sup>, Seong Hwan Kim<sup>6</sup> and Joung-Ho Han<sup>7</sup>

<sup>1</sup>Department of Internal Medicine, Hanyang University College of Medicine, Seoul, <sup>2</sup>Digestive Disease Center, CHA Bundang Medical Center, CHA University, Seongnam, <sup>3</sup>Digestive Disease Center, Soonchunhyang University Hospital, Seoul, <sup>4</sup>Department of Internal Medicine, Korea University College of Medicine, Seoul, <sup>5</sup>Center for Gastric Cancer, Research Institute and Hospital, National Cancer Center, Goyang, <sup>6</sup>Department of Gastroenterology, Eulji University School of Medicine, Eulji Hospital, Seoul, <sup>7</sup>Department of Internal Medicine, Chungbuk National University Hospital, Chungbuk National University College of Medicine, Cheongju, Korea

**Background/Aims:** Currently, a new over-the-scope clip (OTSC) system has been introduced. This system has been used for gastrointestinal perforations and fistulas in other countries. The aim of our study is to examine the therapeutic success rate of endoscopic treatment using the OTSC system in Korea.

**Methods:** This was a multicenter prospective study. A total of seven endoscopists at seven centers performed this procedure.

**Results:** A total of 19 patients were included, with gastrointestinal leakages from anastomosis sites, fistulas, or esophageal perforations due to Boerhaave's syndrome. Among these, there were three gastrojejunostomy sites, three esophagojejunostomy sites, four esophagogastrostomy sites, one esophagocolonostomy site, one jejunum-jejunal site, two endoscopic full thickness resection site closures, one Boerhaave's syndrome, two esophago-bronchial fistulas, one gastrocolonic fistula, and one colonopseudocyst fistula. The size of the leakage ranged from 5 to 30 mm. The median procedure time was 16 min. All cases were technically successful. Complete closure of the leak was achieved in 14 of 19 patients using OTSC alone.

**Conclusions:** The OTSC system is a safe and effective method for the management of gastrointestinal leakage, especially in cases of anastomotic leakage after surgery. **Clin Endosc 2018;51:61-65**

**Key Words:** Over the scope clip; Gastrointestinal leak; Fistula; Perforation

## INTRODUCTION

Until now, surgical management has been the mainstay of therapy for gastrointestinal perforation, fistulas, and anastomotic leakages.<sup>1</sup> Endoscopic treatment has also been used with various devices, such as through the scope clips (TTS clips), histoacryl glue, endoloops, and covered metal stents.<sup>2-5</sup>

However, the success rate of such procedures was highly variable, and additional surgical management is sometimes required. Currently, an over-the-scope clip called OTSC (Ovesco Endoscopy, Tuebingen, Germany) has been developed. Thus far, clinical data have supported the effectiveness of OTSC in the management of gastrointestinal bleeding and perforation.<sup>5</sup>

The purpose of our study was to report our multicenter experience with OTSCs for the management of gastrointestinal perforations, fistulas, and anastomotic leakages, and to examine the overall success rate and complication rate in Korean patients.

Received: February 1, 2017 Revised: June 15, 2017

Accepted: June 15, 2017

Correspondence: Joo Young Cho

Department of Internal Medicine, Digestive Disease Center, Cha Bundang Medical Center, CHA University, 59 Yatop-ro, Bundang-gu, Seongnam 13496, Korea  
 Tel: +82-31-780-5005, Fax: +82-31-780-5219, E-mail: cjoy6695@cha.ac.kr

© This is an Open Access article distributed under the terms of the Creative Commons Attribution Non-Commercial License (<http://creativecommons.org/licenses/by-nc/3.0>) which permits unrestricted non-commercial use, distribution, and reproduction in any medium, provided the original work is properly cited.

## MATERIALS AND METHODS

This study was approved by the institutional review board

**Table 1.** Characteristics of Patients and Outcome

Case No.	Age /Sex	Location	Indication	Reason for operation	Duration of GI defect (day)	Size	Procedure time (min)	F/U (day)	Complications	Technical success	Final success	Use of tissue anchor
1	64/M	Gastrojejunostomy site	Anastomotic leakage	Stomach cancer	3	10	13	425	None	Yes	Yes	Suction
2	77/F	Gastrojejunostomy site	Anastomotic leakage	Stomach cancer	4	12	14	418	None	Yes	Yes	Suction
3	69/M	Esophagojejunostomy site	Anastomotic leakage	Stomach cancer	3	3	15	478	None	Yes	Yes	Suction
4	70/M	Upper esophagus	Esophago-bronchial fistula	Esophageal cancer	15	8	10		None	Yes	No	Suction
5	60/M	Esophagojejunostomy site	Anastomotic leakage	Stomach cancer	5	3	12	598	None	Yes	Yes	Suction
6	49/F	Esophago-gastrostomy site	Anastomotic leakage	Bariatric surgery	4	5	15		None	Yes	No	Twin grasper
7	52/M	Lower esophagus	Boerhaave syndrome	Boerhaave syndrome	8	8	18	380	None	Yes	Yes	Twin grasper
8	49/F	Mid esophagus	Esophago-bronchial fistula	Pulmonary tuberculosis	30	5	15		None	Yes	No	Aligator
9	68/M	Gastrojejunostomy site	Anastomotic leakage	Stomach cancer	2	8	14	420	None	Yes	Yes	Suction
10	75/F	Esophagojejunostomy site	Anastomotic leakage	Stomach cancer	2	7	16	440	None	Yes	Yes	Suction
11	47/M	Esophago-gastrostomy site	Anastomotic leakage	Bariatric surgery	4	10	15	840	None	Yes	Yes	Twin grasper
12	32/F	Esophago-gastrostomy site	Anastomotic leakage	Bariatric surgery	3	10	20	750	None	Yes	Yes	Twin grasper
13	56/M	Transverse colon	Colonopseudocyst fistula	Acute pancreatitis	35	12	30	600	None	Yes	Yes	Twin grasper
14	50/M	Stomach angle	Endoscopic full thickness resection	Stomach cancer	3	30	20	570	None	Yes	Yes	Twin grasper
15	57/M	Stomach cardia	Endoscopic full thickness resection	GIST	3	10	10	700	None	Yes	Yes	Twin grasper
16	48/M	Jejunostomy site	Anastomotic leakage	Small bowel necrosis	53	10	10	330	None	Yes	Yes	Suction
17	41/M	Gastrojejunostomy site	Gastrocolonic fistula	Gastric ulcer	20	20	30		None	Yes	No	Twin grasper
18	25/M	Esophago-colonostomy site	Anastomotic leakage	Necrotizing esophagitis	63	6	10		None	Yes	No	Suction
19	71/M	Esophago-gastrostomy site	Anastomotic leakage	Esophageal cancer	5	5	15	90	None	Yes	Yes	Suction

GI, gastrointestinal; F/U, follow up; GIST, gastrointestinal stromal tumor.

for human research at each hospital. This was a multicenter prospective study in Korea. A total of seven endoscopy experts at seven academic centers performed the OTSC procedure. All patients were given intravenous midazolam and pethidine before the procedure. All procedures were performed as follows: after attachment of the system to the tip of the endoscope, close contact was made with the target lesion, the area was fully sucked, and the OTSC clip was deployed. The OTSC system was installed onto the tip of an upper gastroscop.

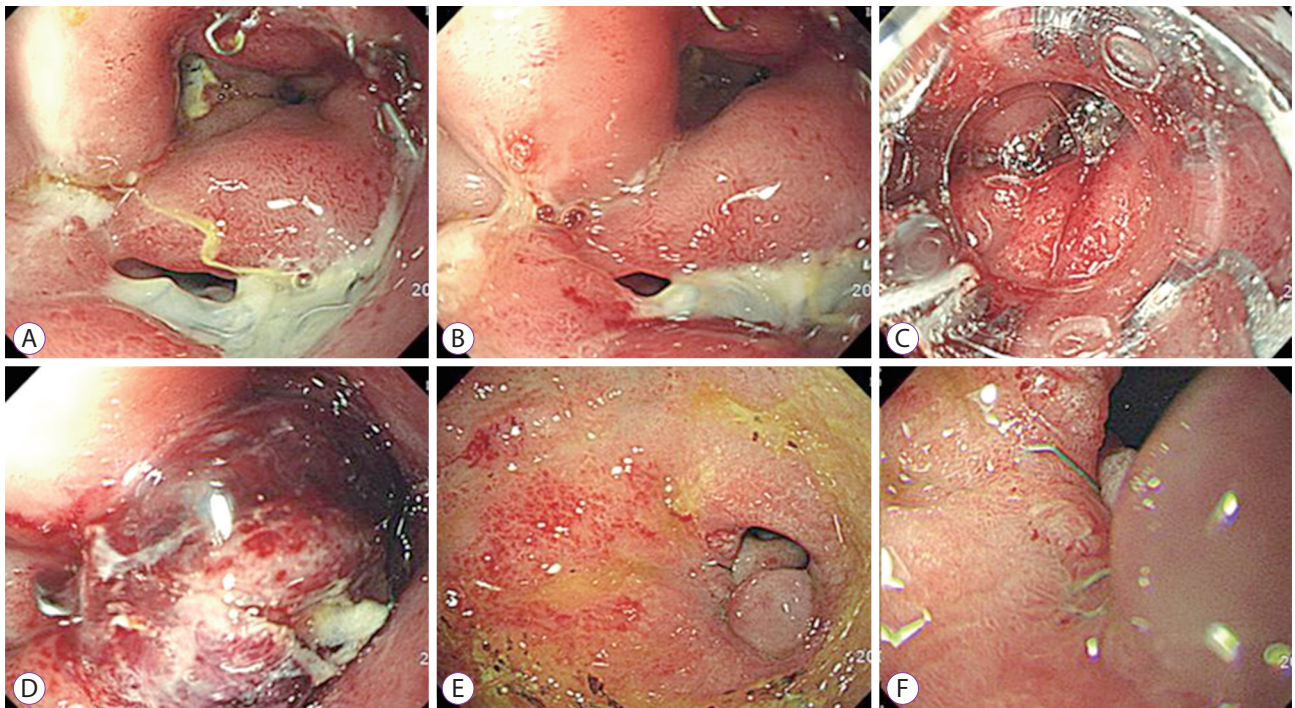
The OTSC consists of a shape-memory nitinol alloy, which returns to its initial shape when it is released from the applicator, allowing for closure of the clip. The clip is deployed by stretching a wire with a hand wheel fixed on the working channel. To facilitate targeting of the lesion, we used endoscopic suction, a twin grasper, and alligator, based on individual case requirement.

The gastrointestinal defects studied included anastomosis leakage, fistulas, and perforations. An anastomosis leakage was defined as tissue breakdown at the anastomotic site resulting in a fluid collection with or without evidence of extravasation of contrast on radiologic study.<sup>6</sup> A fistula was defined as abnormal communication between two epithelialized surfaces.<sup>7</sup> Perforation was defined as a full-thickness defect in the gastrointestinal tract. Technical success was defined as successful deployment of an OTSC at the intended site as determined endoscopically and/or radiographically. Clinical success was

defined as the resolution of the gastrointestinal defect attributed to OTSC at the time of follow up as evidenced by clinical, endoscopic, and/or abdominal imaging, with a minimum of 2 weeks of follow-up.

## RESULTS

This study included a total of 19 patients (median age 56 years, range 25–77 years, 14 men) with gastrointestinal leaks from anastomosis sites, fistulas, or esophageal perforations due to Boerhaave's syndrome. Among these, there were three cases involving gastrojejunostomy sites, three esophagojejunostomy sites, four esophagogastrostomy sites, one esophagocolonostomy site, one jejun-jejunal site, two endoscopic full thickness resection site closure, one Boerhaave's syndrome, two esophago-bronchial fistulas, one gastrocolonic fistula, and one colonopseudocyst fistula. The size of the leakage ranged from 5 to 30 mm (median diameter 10 mm). The median procedure time was 16 min. All patients were nil per os (NPO) after midnight prior to the procedure. All cases were technically successful. Complete healing of the leakage was achieved in 14 of 19 patients (74%) using OTSC alone. In one patient in which OTSC failed, closure was achieved by placing an additional covered metal stent. Three fistula cases required surgical intervention. One anastomotic leakage case required surgical



**Fig. 1.** One case of over-the-scope clip (OTSC) procedure. (A, B) About 1 cm sized anastomotic leakage was noted. (C, D) One OTSC placed at the leakage site. (E, F) Endoscopic finding after six months. Only scar lesion was noted.

repair (Table 1). When we divided patients into two categories (perforations and leakages versus fistulas), overall, the rate of successful closure in perforations and leakages was significantly higher than that of fistulas (87% vs. 25%,  $p=0.025$ ). There were no complications associated with the OTSC procedures. Mean follow-up period after OTSC was 502 days. Fig. 1 showed a successful OTSC procedure in case of anastomotic leakage after subtotal gastrectomy due to stomach cancer.

## DISCUSSION

With improvements in various therapeutic endoscopy techniques and more technically difficult surgical procedures, both endoscopists and surgeons are more frequently encountering serious complications such as gastrointestinal perforation, fistulas, and anastomotic leakages. Non-surgical management of gastrointestinal perforations and post-operative fistulas has been attempted endoscopically using various devices such as endoclip, histoacryl glue, endoloop, and covered metal stents. These procedures have proven utility in some clinical cases. However, the success rate of such procedures is highly variable, and additional surgical management is sometimes required.<sup>8-12</sup>

Recently, a new system, OTSC, was developed, which was designed to create full-thickness closure by using an OTSC made of a super-elastic, shape-memory alloy (nitinol), which takes its former unbent shape after the clip is released. The OTSC clip has been successfully used for the primary non-surgical closure of gastrointestinal tract perforations and fistulas.<sup>5,6,13</sup> This system is easy to handle, and no meaningful complications have been reported to date. In our study, there was no meaningful complication related to the OTSC procedure. However, complete jejunal closure cases secondary to clip misplacement have been reported.<sup>13</sup>

Until now, there have been no large studies that examined the effectiveness of OTSC clips in Asia. We experienced a total of 19 cases that were treated with OTSC. The technical success rate of the OTSC procedure was 100%. Overall long term clinical success was achieved in 74% of patients in our study. The present study shows that the OTSC system can be more effective in cases of perforation or leakage than in cases of chronic fistula. In cases of chronic fistula, the closure rate by OTSC was approximately 40%. The reason for low clinical success in the treatment of fistula is possibly due to the lesions' fibrotic edges, according to many previous studies.<sup>14,15</sup>

We suggest that, in case of OTSC failure, an additional covered metal stent can be used as salvage therapy. A previous report suggests that the duration of the defect is important in predicting clinical success of OTSC.<sup>5</sup> The chance of spon-

taneous closure of perforations or leakages is very low, and surgical management of such complications is often difficult; morbidity and mortality may be as high as 5%–30% in emergency situations. Therefore, it is important to perform OTSC without hesitation.

Gastric cancer is one of the most common cancers in Korea, and every year approximately 20,000 gastric surgeries are performed. As a result, postoperative leakage is not uncommon. OTSC was effective for use in cases of anastomotic leakage after gastrectomy in our study. In case of anastomotic dehiscence with abscess, abscess drainage may be needed before the OTSC procedure.

The major limitation of our study is the small study population. In addition, all procedures were performed by experienced endoscopists at seven sites, which may have introduced heterogeneity. However, this study has several notable strengths, as it is to our knowledge the first multicenter study of its kind in Asia. In addition, the results of our study are similar to those reported in previous Western studies. In Korea, the OTSC system is not covered by national insurance as a new medical technology; therefore, there are many limitations to its use. In the future, the OTSC system should be included in the Korea medical insurance program.

In conclusion, OTSC is effective therapy for closure of gastrointestinal defects in Korean patients and appears to be a relatively safe procedure. In the future, the indications for OTSC may include natural orifice transluminal endoscopic surgery (NOTES) entry closure, resection of small subepithelial lesions, and prevention of perforation following endoscopic resection involving the muscularis propria.

### Conflicts of Interest

The authors have no financial conflicts of interest.

### Acknowledgments

This study was supported by a 2014 DONG-A ST grant from the Korean Gastrointestinal Endoscopy Research Foundation.

## REFERENCES

1. Parodi A, Repici A, Pedroni A, Bianchi S, Conio M. Endoscopic management of GI perforations with a new over-the-scope clip device (with videos). *Gastrointest Endosc* 2010;72:881-886.
2. Yoon JH, Lee HL, Lee OY, et al. Endoscopic treatment of recurrent congenital tracheoesophageal fistula with histoacryl glue via the esophagus. *Gastrointest Endosc* 2009;69:1394-1396.
3. Lopes MF, Cattré D, Reis A, Leitão LM. Endoscopic treatment of recurrent tracheoesophageal fistula with histoacryl glue. *Gastrointest Endosc* 2010;72:1324-1325; author reply 1325.
4. Park SW, Lee HL, Ahn SE, et al. A case of successful endoscopic management of afferent loop leakages by using hemoclips and a detachable snare. *Korean J Gastrointest Endosc* 2008;37:30-34.
5. Haito-Chavez Y, Law JK, Kratt T, et al. International multicenter expe-

- rience with an over-the-scope clipping device for endoscopic management of GI defects (with video). *Gastrointest Endosc* 2014;80:610-622.
6. Caulfield H, Hyman NH. Anastomotic leak after low anterior resection: a spectrum of clinical entities. *JAMA Surg* 2013;148:177-182.
  7. Metcalf C. Enterocutaneous fistulae. *J Wound Care* 1999;8:141-142.
  8. van Boeckel PG, Dua KS, Weusten BL, et al. Fully covered self-expandable metal stents (SEMS), partially covered SEMS and self-expandable plastic stents for the treatment of benign esophageal ruptures and anastomotic leaks. *BMC Gastroenterol* 2012;12:19.
  9. Kim JS, Kim BW, Kim JI, et al. Endoscopic clip closure versus surgery for the treatment of iatrogenic colon perforations developed during diagnostic colonoscopy: a review of 115,285 patients. *Surg Endosc* 2013;27:501-504.
  10. Haider S, Kahaleh M. The use of endoscopic clipping devices in the treatment of iatrogenic duodenal perforation. *Gastroenterol Hepatol (N Y)* 2010;6:660-661.
  11. Carrott PW Jr, Low DE. Advances in the management of esophageal perforation. *Thorac Surg Clin* 2011;21:541-555.
  12. Blackmon SH, Santora R, Schwarz P, Barroso A, Dunkin BJ. Utility of removable esophageal covered self-expanding metal stents for leak and fistula management. *Ann Thorac Surg* 2010;89:931-936; discussion 936-937.
  13. Baron TH, Song LM, Ross A, Tokar JL, Irani S, Kozarek RA. Use of an over-the-scope clipping device: multicenter retrospective results of the first U.S. experience (with videos). *Gastrointest Endosc* 2012;76:202-208.
  14. Arezzo A, Verra M, Reddavid R, Cravero F, Bonino MA, Morino M. Efficacy of the over-the-scope clip (OTSC) for treatment of colorectal postsurgical leaks and fistulas. *Surg Endosc* 2012;26:3330-3333.
  15. Manta R, Manno M, Bertani H, et al. Endoscopic treatment of gastrointestinal fistulas using an over-the-scope clip (OTSC) device: case series from a tertiary referral center. *Endoscopy* 2011;43:545-548.