


## CLINICAL ARTICLE

# Decreasing Thickness of Partial Lateral Trochlear Cartilage in Patients with Patellar Instability

Chongyi Fan, MD, Ming Li, MD, Guangmin Yang, MD, Xunkai Feng, MD, Fei Wang, DC 

*Department of Joint Surgery, The Third Hospital of Hebei Medical University, Shijiazhuang, China*

**Objective:** To explore morphological characteristics of patellofemoral joint surface of patients with patellar instability by adopting the MRI-based method.

**Methods:** A retrospective analysis was performed from March 2016 to January 2020 to assess morphological characteristics of the patellofemoral joint surface by Magnetic Resonance Imaging (MRI) scanning knees of 30 patients (24 females, six males) with patellar instability and trochlear dysplasia and knees of 30 subjects from a randomly selected control group (25 females, five males). The control group was matched as per age and sex. All participants had undergone MRI scans in the supine position and keep knees in or near full extension. Six parts were measured in total, including thickness of trochlear cartilage, thickness of patella cartilage, cartilaginous sulcus angle, cartilaginous Wiberg angle, contact range and frequency and distributions of the mean difference measurement of the femoral trochlea, to evaluate the difference of trochlear and patellar morphology between the patient group and the control group. The threshold for statistical significance was set at  $P < 0.05$ .

**Results:** There were significant differences in four values between the two groups ( $P < 0.05$ ). The cartilage thickness two-third along the lateral condyle in the patient group was significantly lower than that in the control group (LCT2,  $1.80 \pm 0.37$  vs  $2.06 \pm 0.52$ ,  $1.92 \pm 0.36$  vs  $2.17 \pm 0.50$ ), but there was no significant difference in other sites. There was no significant difference in patella thickness between the patient group and the control group. The cartilaginous sulcus angle in the patient group was larger than that in the control group ( $157.90 \pm 6.64$  vs  $142.23 \pm 3.95$ ,  $P < 0.001$ ), but there was no significant difference in cartilaginous Wiberg angle. The patient group had a larger initial contact ratio ( $59.47 \pm 6.13$  vs  $46.50 \pm 3.67$ ,  $P < 0.001$ ), and a smaller contact range ( $16.55 \pm 4.14$  vs  $27.55 \pm 4.09$ ,  $P < 0.001$ ). The deepest part of the intercondylar sulcus appears more often in the lateral of the deepest part of the osseous concavity of the femoral trochlea. Among the patient group, 18 cases (60%) were found with the deepest part of the intercondylar sulcus lateral to the deepest point of the osseous concavity of the femoral trochlea while among the control group only 4 cases (13.33%) were found. The distribution of trochlear dysplasia of Dejour grades was type B ( $n = 22$ ), type C ( $n = 5$ ), and type D ( $n = 3$ ).

**Conclusion:** Thickness of partial lateral trochlear cartilage decreases in patients with patellar instability and the trochlear cartilage develops abnormal morphological characteristics. Moreover, it also suggests that MRI can be used to further present the morphology of cartilage for the convenience of surgical planning.

**Key words:** Cartilage thickness; MRI; Patellar instability; Patellar dislocation; Trochlear dysplasia

## Introduction

Recurrent patellar dislocation is a repeated dislocation that follows from an initial episode of minor trauma dislocation<sup>1</sup>. It generally occurs to patients who have been found with various predisposing factors and causes, such as trochlear

dysplasia and the Medial patellofemoral ligament injury and so forth<sup>2</sup>. Trochlear dysplasia is one of the major predisposing factors related to patella instability, especially in children and adolescents<sup>3</sup>. Chronic abnormal patellofemoral joint stress is most likely to lead to patellar softening and accelerate the

**Address for correspondence** Fei Wang, Department of Joint Surgery, The Third Hospital of Hebei Medical University, Shijiazhuang, Hebei, China 050051 Tel: +86-13315460225; Fax: +86-311-88602613; Email: doctorwf@yeah.net

Received 10 June 2020; accepted 20 January 2021

development of patellofemoral arthritis<sup>4</sup>. Non-surgical treatment is not effective in preventing the patellar dislocation, and may lead to further injuries of the patellofemoral articular cartilage<sup>5</sup>. In clinical practices, X-ray examination and computed tomography (CT) are widely used to diagnose the morphology of the trochlear, which is limited when studying morphological changes of early patellofemoral arthritis cartilage caused by patella instability. Furthermore, associated studies show patients with patellar dislocation or subluxation are more likely to cause bony dysplasia of the trochlear joint. What is more, early relocation could reduce the incidence of trochlear dysplasia<sup>6</sup>. Meanwhile, peers must be aware that radiographic indices for measuring the osseous anatomy of the patella and femoral trochlea may not represent the surface morphology of the patellofemoral joint<sup>7</sup>. Therefore, further studies on the morphology of articular cartilage are necessary. Previous studies have evaluated cartilage-bone mismatch in the dysplastic trochlea. Yamada *et al.* also used 3D MRI in discovering that the lateral distribution of cartilage in patients with recurrent patellar dislocation was more obvious than that in the control group<sup>8</sup>. It is well known that patients with patellar instability are often accompanied by damage to articular cartilage, which may also cause edema of articular cartilage<sup>9, 10</sup>. In recent years, researches have shown that the WNT/  $\beta$ -catenin pathway can inhibit the formation of cartilage, stimulate hypertrophy of cartilage cells and regulate the formation and damage of articular cartilage<sup>11</sup>. Besides, other authors have also mentioned that mechanical stress can promote inflammation of cartilage repair<sup>9</sup>. In addition, Wang *et al.* reported that early relocation of the patella can prevent femoral trochlear dysplasia in growing rabbits<sup>12</sup>. Furthermore, previous studies have described that early patellar reduction can also improve the morphology of the femoral groove<sup>13, 14</sup>. The lateralized patella concentrated excessive mechanical stress on the lateral condyle, whether it will cause hyperplasia or wear on the lateral surface is unknown. Meanwhile, whether the insufficient stress on the center and medial trochlear facet could lead to degeneration or proliferation of the trochlear cartilage remains unknown. Therefore, it needs further studies how thickness of patellofemoral articular cartilage will change under the long-term abnormal stress.

The main purposes of this research are: (i) to compare the thickness, distribution and contact range of trochlear cartilage and patella cartilage between normal subjects and patients with patellar instability by analyzing the MRI-based measurements of patients with patellar instabilities; (ii) explore morphological characteristics of the patellofemoral joint surface; and (iii) and hypothesize that there would be a decrease in the thickness of the patellofemoral articular cartilage due to chronic abnormal stress.

## Materials and Methods

### Inclusion and Exclusion Criteria

Patient selection was based on the following inclusion criteria: (i) clinically diagnosed patients had a history of

recurrent patellar dislocation ( $\geq 3$  times); (ii) physical findings, like a lateral position of the patella, passive subluxation of the patella, a positive apprehension sign in response to a lateral thrust to the patella etc, were objective; (iii) there were radiologic evidences that confirm the dislocation or subluxation by MRI. The exclusion criteria were: (i) body mass index (BMI)  $> 30$  kg/m<sup>2</sup>; (ii) patellar chondromalacia or patellofemoral arthritis; and (iii) there was history of knee surgery and trauma.

### Patients' Information

We retrospectively analyzed some patients with patellar instability in Third Hospital of Hebei Medical University from March 2016 to January 2020. Thirty patients (patient group) were selected according to the above criteria, containing six males and 24 females, whose ages range from 13 to 23 years old.

The control group consisted of patients without any radiological signs of trochlear dysplasia, or clinical signs of objective and subjective patellofemoral instability. The control group was matched as per age and sex (30 cases, five males and 25 females ranging from 13 to 23 years old).

### MRI Measurement

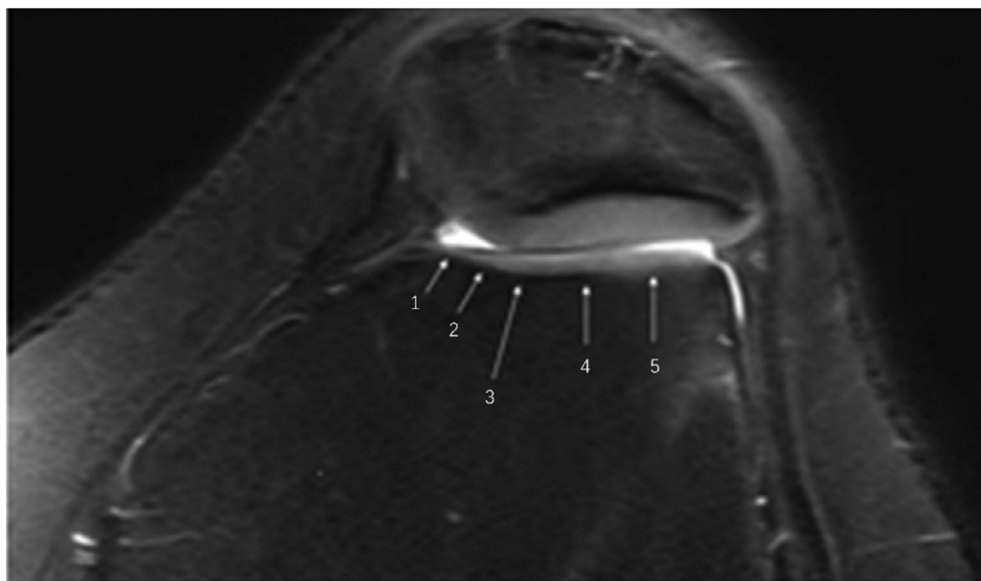
The MRI used for this study were obtained with a 1.5T MRI (Sonata Magnetom, Siemens Medical Solutions, Erlangen, Germany) with the knee in or near full extension. All measurements were performed on the PACS (Picture Archiving and Communications System; General Electrics, Chicago, IL, US) using a mouse cursor with automated distance or angle calculation. Six parts were measured in total, including thickness of trochlear cartilage, thickness of patella cartilage, cartilaginous sulcus angle, cartilaginous Wiberg angle and contact range and frequency and distributions of the mean difference measurement of the femoral trochlea.

### Outcome Measures

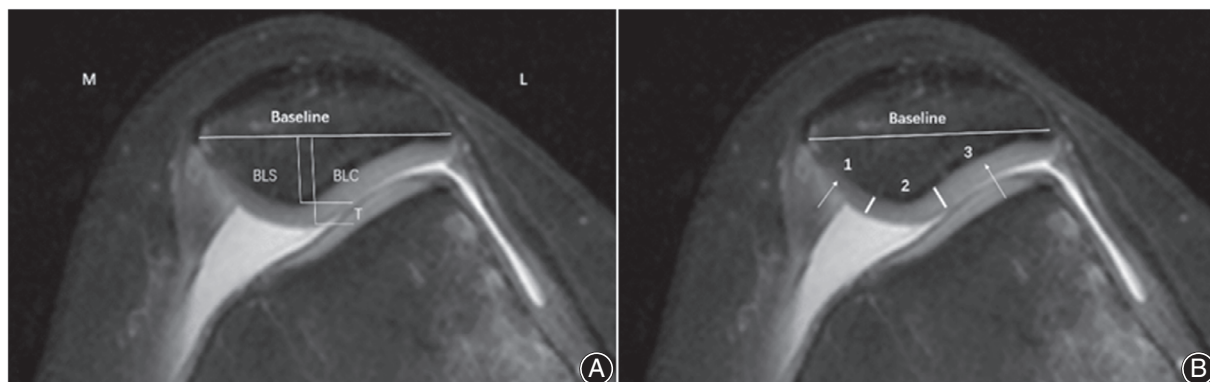#### Evaluation of the Thickness of the Articular Cartilage

The trochlear cartilage to be measured was selected in the next plane, near the proximal femur, after the trans-epicondylar axis. This level shows the boundary between bone and cartilage was seen more clearly on MRI. Moreover, many previous studies have shown that the proximal trochlear cartilage is dysplastic<sup>15, 16</sup>, so this level can better reflect the changes of the trochlear cartilage. We used the method of van Huyssteen *et al.* to measure the cartilage's thickness at five positions of the trochlea<sup>10</sup>. (the thickness of the cartilage in the sulcus at one-third and two-thirds along each condyle, Fig. 1).

The thickness of the patella was measured at three positions. The cartilage of the patella was divided into three subregions, as previously described<sup>9</sup>. The transverse diameter was measured in 'mm' between the most medial and the most lateral edge of the patella and was defined as the baseline. Two perpendicular lines to (BL) through the cartilaginous and the



**Fig. 1** MRI scans showing trochlea cartilage thickness. LCT2, MCT2, the mean cartilage thickness two-third along the lateral and medial condyles (white arrow 1,5); LCT1, MCT1, the mean cartilage thickness one-third along the lateral and medial condyles (white arrow 2,4); TGCT, trochlear groove cartilage thickness (white arrow 3).



**Fig. 2** MRI scans showing patellar cartilage thickness. (A) The thickness of the retropatellar cartilage (T) was calculated out of the difference between (BLC) and (BLS). PCCT, patellar crest cartilage thickness (T); (B) Select the midpoint of the facies lateral and the medial surface of patella respectively to measure the difference between the osseous structure and cartilage structure as the thickness of the medial cartilage and the lateral cartilage. MPCT, medial patellar cartilage thickness (white arrow 1), LPCT, lateral patellar cartilage thickness (white arrow 3).

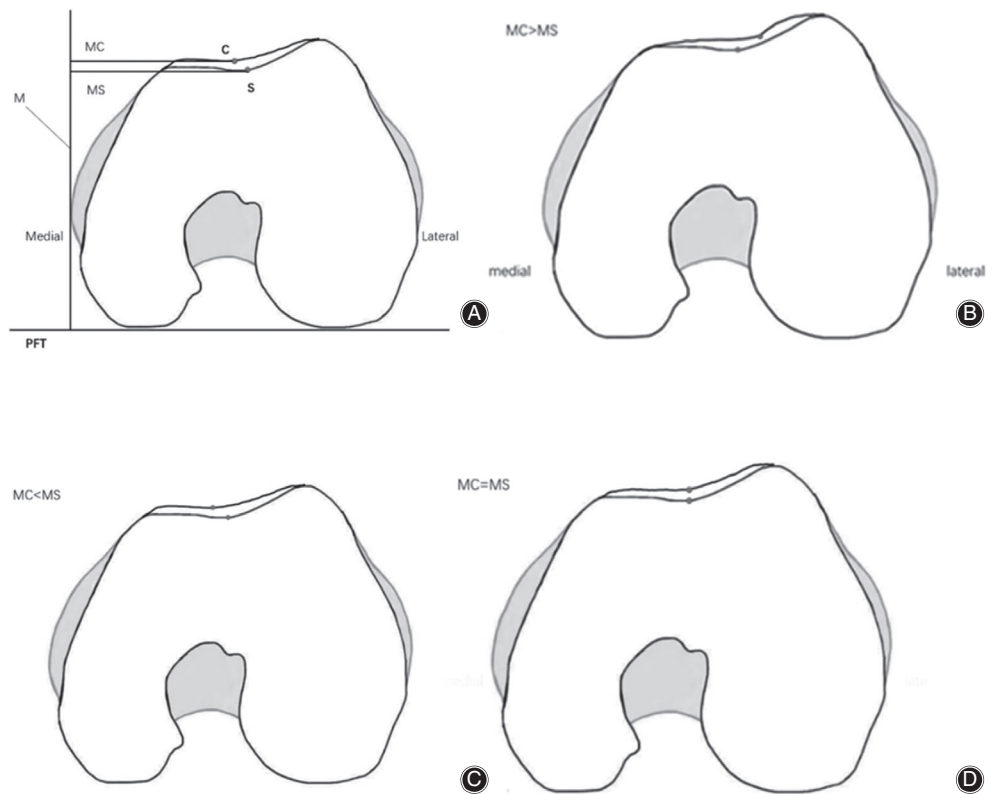
subchondral posterior patellar edge were drawn to measure the vertical cartilaginous (BLC) and subchondral (BLS) patella size of the articular part of the patella (in mm). The thickness of the retropatellar cartilage (T) was calculated out of the difference between (BLC) and (BLS) in mm, according to Staubli *et al.* (Fig. 2A). Select the midpoint of the facies lateral and the medial surface of patella respectively to measure the difference between the osseous structure and cartilage structure as the thickness of the medial cartilage and the lateral cartilage (Fig. 2B).

We measure five values of the trochlea, including trochlear groove cartilage thickness (TGCT), the mean cartilage thickness one-third along the lateral (LCT1) and medial condyles (MCT1) and the mean cartilage thickness two-third along the lateral (LCT2) and medial condyles (MCT2). We measure three values of the patella, including medial patellar

cartilage thickness (MPCT), lateral patellar cartilage thickness (LPCT) and patellar crest cartilage thickness (PCCT).

#### *Frequencies and Distributions of the Mean Differences Measurement for the Femoral Trochlea*

The measurement refers to the mean distance differences for the locations of the deepest part for the surface concavities of the intercondylar sulcus (C) and the corresponding deepest part of the osseous contour of the femoral trochlea (S). Construct a medial tangent (M) that is perpendicular to posterior femoral tangent (PFT)<sup>7</sup>; assess the matching relation between the deepest part for the surface concavities of the intercondylar sulcus and the corresponding deepest part of the osseous contour of the femoral trochlea by comparing MS with MC (Fig. 3A).



**Fig. 3** (A) The relationship between the deepest part of the intercondylar sulcus and the corresponding deepest part of the osseous contour of the femoral trochlea. (B) lateral (MC > MS). (C) medial (MS < MC) (D) match (MS = MC). MC: The distance from the deepest part for the surface concavities of the intercondylar sulcus to a medial tangent that is perpendicular to posterior femoral tangent. MS: The distance from the corresponding deepest part of the osseous contour of the femoral trochlea to a medial tangent that is perpendicular to posterior femoral tangent.

Evaluation of the Contact Range of the Articular Cartilage Through MRI sagittal plane, observe, from medial to lateral, the contact (Fig. 4B,C) and separation (Fig. 4A,D) of patella and trochlear cartilage. Select the plane of transepicondylar axis, and adopt the posterior condyle line as the baseline, with the position of the medial epicondyle is defined as the origin of this coordinate system, and the position of the lateral epicondyle represents 100%. Calculate the proportions of the distance between the first contact and the last contact in the coordinate system. (Fig. 4E).

### Statistical Analysis

All of measurements were statistically analyzed by *t* test; If the data had been found not normally distributed, Mann-Whitney U non-parametric test would have been alternatively taken. A *P* value less than 0.05 was considered statistically significant. The thickness of cartilage was separately measured by two of the authors, who were then blinded to the results and interclass correlation coefficient (ICC) was then calculated. Zero indicated no agreement, 0 to 0.2 was a mild agreement, 0.2 to 0.4 was a fair agreement, 0.4 to 0.6 was a moderate agreement, 0.6 to 0.8 was a substantial agreement, and 0.8 to 1.0 was excellent agreement. The data were represented with mean  $\pm$  standard deviation (SD). All analyses were performed using SPSS software (Version 21.0, IL, USA).

## Results

### Demographic

From March 2016 to January 2020, MRI scanning was performed on 30 patients (24 females, six males) with patellar instability, and 30 cases of knees (25 females, five males) were randomly selected for a retrospective analysis. Patients averaged at  $17.30 \pm 3.13$  years old (13 to 23 years) while the average age of the control group was  $17.27 \pm 3.11$  years old (13 to 23 years). The average BMI of patients was  $23.23 \pm 2.71$  kg/m<sup>2</sup> and that of controls was  $22.50 \pm 1.68$  kg/m<sup>2</sup> (Table 1).

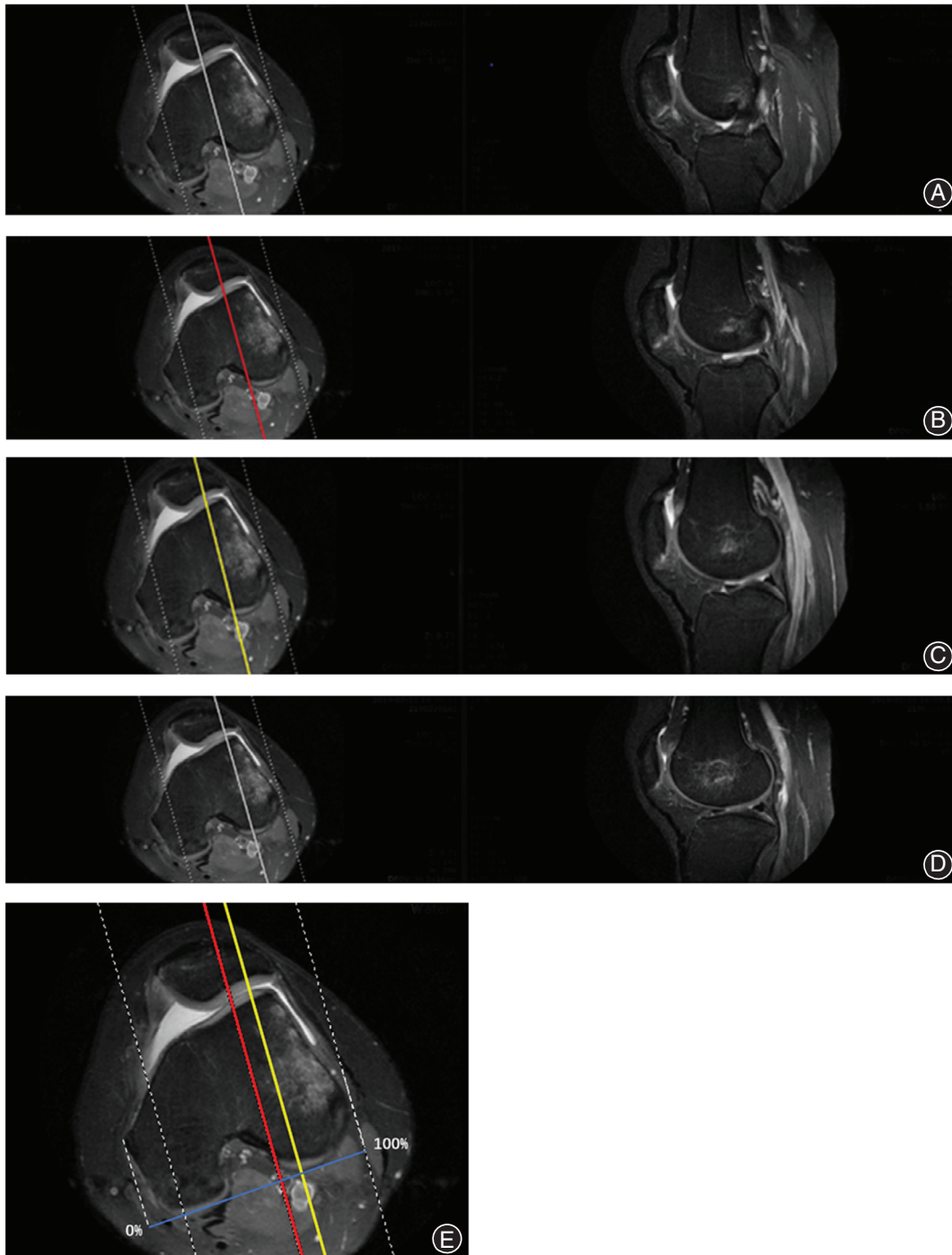
The patients with patellar instability were classified into Dejour type<sup>17</sup>, with 3 grade D, 5 grade C and 22 grade B in 30 knees.

### Cartilage Thickness

There was a significant difference in cartilage thickness two-third along the lateral condyle ( $1.80 \pm 0.37$  vs  $2.06 \pm 0.52$ , *P* = 0.031;  $1.92 \pm 0.36$  vs  $2.17 \pm 0.50$ , *P* = 0.029), but there were no significant differences in the thickness of other measured cartilage. The ICC results for the two observers ranged from 0.879 to 0.990. All measurement data are shown in Table 2.

### Cartilaginous Sulcus Angle and Wiberg Angle

The mean angle of cartilaginous sulcus angle was  $157.90^\circ \pm 6.64^\circ$  ( $143^\circ$  to  $173^\circ$ ) in patients and  $143.23^\circ \pm 3.95^\circ$



**Fig. 4** Assess the contact range of patellofemoral articular cartilage. A to D are four consecutive planes. (A) uncontacted plane: patellofemoral joint cartilage in the sagittal plane is not in contact. (B) contacted plane: patellofemoral joint cartilage in the sagittal plane is in contact, in the meantime, the coronal plane is regarded as the first plane of contact. (C) contacted plane: patellofemoral joint cartilage in the sagittal plane is in contact, in the meantime, the coronal plane is regarded as the last plane of contact. (D) separation plane: separation of the patella from the femoral trochlear in the sagittal plane. (E) contact range: the range from B to C (the range between the red line and the yellow line) The position of the medial epicondyle is defined as the origin of this coordinate system, and the position of the lateral epicondyle represents 100%. Calculate the proportion of the distance between the red line and the yellow line in the coordinate system.

(137° to 152°) in controls. There was significant differences in cartilaginous sulcus angle which was larger in patients ( $P < 0.001$ ). The mean angle of cartilaginous Wiberg angle was  $140.97^\circ \pm 3.57^\circ$  (131° to 148°) in patients and  $142.23^\circ \pm 5.87^\circ$  (137° to 156°) in controls. There were no significant differences in cartilaginous Wiberg-angle ( $P = 0.316$ ) (Table 3).

#### Frequencies and Distributions of the Mean Differences Measurement for the Femoral Trochlea

In the patient group 18 knees (60.00%), the deepest part of the intercondylar sulcus is lateral to the deepest part of the osseous concavity of the femoral trochlea (Fig. 3B), and in 4 knees (13.33%), the deepest part of the intercondylar sulcus is medial to the deepest part of the femoral trochlea (Fig. 3C). In 8 knees (26.67%), the contours of cartilage surface and subchondral bone match (Fig. 3D).

In the control group, four knees (13.33%), the deepest part of the intercondylar sulcus is lateral to the deepest part of the osseous concavity of the femoral trochlea, and in 16 knees (53.34%), the deepest part of the intercondylar sulcus is medial to the deepest part of the femoral trochlea. In 10 knees (33.33%), the contours of cartilage surface and subchondral bone match.

According to the frequencies and distributions of the mean differences measurement for the femoral trochlea, the

deepest part of the intercondylar sulcus appears more often in the lateral of the deepest part of the osseous concavity of the femoral trochlea (Table 4).

#### The Contact Range of the Articular Cartilage

The mean ratio of initial contact ratio was  $59.47\% \pm 6.13\%$  (45% to 70%) in patients and  $46.50\% \pm 3.67\%$  (41% to 59%) in controls. The mean ratio of contact range was  $17.33\% \pm 3.74\%$  (13% to 26%) in patients and  $27.56\% \pm 3.41\%$  (18% to 32%) in controls. There were significant differences in initial contact ratio ( $59.47\% \pm 6.13\%$  vs  $46.50\% \pm 3.67\%$ ,  $P < 0.001$ ) and contact range ( $17.33\% \pm 3.74\%$  vs  $27.56\% \pm 3.41\%$ ,  $P < 0.001$ ). Patellas of the patient group were found to be more lateralized obviously than that of the control group, and the contact range between the patella and the femoral trochlea was smaller. There were no significant differences in terminal contact ratio (Table 5).

## Discussion

### Trochlear Cartilage Thickness

Our study showed, compared with the control group, the patients have lower cartilage thickness at the LCT2 site, and the result was statistically different. Measurements suggested the cartilage thickness in the trochlear groove was the largest and that of the condyle was the smallest, consistent with results of van Huyssteen *et al.*<sup>10</sup>. Ficat *et al.* once put forward the concept of Excessive Lateral Pressure Syndrome, that excessive lateral pressure of the patella could cause the patient's pain on the outside of the knee joint, which might lead to wear on the lateral of the trochlea, resulting in thinner lateral cartilage of the trochlea, and loss of the lateral cartilage of the trochlea<sup>18</sup>. In the process of chronic patellar instability, the wear on the patellar cartilage may gradually lead to the development of patellofemoral arthritis due to excessive lateral pressure of the patella. This idea has been confirmed by our research results. Hence, early surgical reduction of the patella can change the mechanical

**TABLE 1** patients and controls' demographic characteristics

Characteristics	Patients (n = 30)	Controls (n = 30)
Gender		
Male	6	5
Female	24	25
Age, years (range)	$17.30 \pm 3.13$ (13–23)	$17.27 \pm 3.11$ (13–23)
BMI (kg/m <sup>2</sup> )	$23.23 \pm 2.71$	$22.50 \pm 1.68$
Side		
Right	10	8
Left	20	22

**TABLE 2** Patients and controls' cartilage thickness measurements

Thickness (mm)	Observer 1			Observer 2			ICC
	Patients	Controls	P	Patients	Controls	P	
MCT2	$1.97 \pm 0.52$	$2.04 \pm 0.44$	0.559	$2.06 \pm 0.49$	$2.11 \pm 0.43$	0.621	0.963
MCT1	$2.02 \pm 0.52$	$2.12 \pm 0.46$	0.433	$2.09 \pm 0.49$	$2.21 \pm 0.43$	0.293	0.938
TGCT	$2.33 \pm 0.66$	$2.62 \pm 0.78$	0.122	$2.41 \pm 0.62$	$2.69 \pm 0.74$	0.122	0.962
LCT1	$2.03 \pm 0.41$	$2.26 \pm 0.56$	0.091	$2.04 \pm 0.43$	$2.22 \pm 0.50$	0.139	0.918
LCT2	$1.80 \pm 0.37$	$2.06 \pm 0.52$	<b>0.031</b>	$1.92 \pm 0.36$	$2.17 \pm 0.50$	<b>0.029</b>	0.879
PCCT	$2.37 \pm 0.56$	$2.51 \pm 0.63$	0.372	$2.37 \pm 0.56$	$2.51 \pm 0.63$	0.520	0.988
MPCT	$2.37 \pm 0.63$	$2.48 \pm 0.80$	0.568	$2.40 \pm 0.62$	$2.52 \pm 0.77$	0.456	0.971
LPCT	$2.44 \pm 0.75$	$2.74 \pm 0.66$	0.104	$2.51 \pm 0.73$	$2.81 \pm 0.64$	0.095	0.990

LCT1, MCT1, the mean cartilage thickness one-third along the lateral and medial condyles; LCT2, MCT2, the mean cartilage thickness two-third along the lateral and medial condyles; LPCT, lateral patellar cartilage thickness; MPCT, medial patellar cartilage thickness; PCCT, patellar crest cartilage thickness; TGCT, trochlear groove cartilage thickness.; Bold letters in the table indicate that the item is statistically significant.

**TABLE 3 Cartilaginous sulcus angle and cartilaginous Wiberg angle**

Groups	Cartilaginous sulcus angle (°)	Cartilaginous Wiberg angle (°)
Patients	157.90 ± 6.64	140.97 ± 3.57
Controls	143.23 ± 3.95	142.23 ± 5.87
P value	<b>&lt;0.001</b>	0.316

Bold letters in the table indicate that the item is statistically significant.

**TABLE 4 Frequencies and distributions of the mean differences measurement for the femoral trochlea**

(case, %)	MC>MS	MC<MS	MC = MS
Patients	18,60.00%	4,13.33%	8,26.67%
Controls	4,13.33%	16,53.34%	10,33.33%

MC: The distance from the deepest part for the surface concavities of the intercondylar sulcus to a medial tangent that is perpendicular to posterior femoral tangent.; MS: The distance from the corresponding deepest part of the osseous contour of the femoral trochlea to a medial tangent that is perpendicular to posterior femoral tangent.

**TABLE 5 Contact range measurements**

Groups	Initial contact ratio (%)	Terminal contact ratio (%)	Contact range (%)
Patients	59.47 ± 6.13	76.13 ± 4.90	17.33 ± 3.74
Controls	46.50 ± 3.67	74.47 ± 2.49	27.56 ± 3.41
P value	<b>&lt;0.001</b>	0.102	<b>&lt;0.001</b>

Bold letters in the table indicate that the item is statistically significant.

environment of the patellofemoral joint, reduce the incidence of early patellofemoral arthritis and change the surface morphology of the patellofemoral joint, which is of great significance to the selection of the treatments for patients with patellar instability or dislocation.

To our knowledge, mechanical stress is one of the most significant factors influencing cartilage and bone development<sup>19</sup>. In addition, changes in microstructure and morphology of trochlear subchondral bone will affect its capacity to disperse the mechanical stress from the cartilage, thus causing abnormal mechanical stress on cartilage, and inducing cartilage damage such as defects and collagen breakdown. Studies showed that excessive mechanical stress could directly damage the cartilage extracellular matrix and shift the balance in chondrocytes to favor catabolic activity over anabolism<sup>20, 21</sup>, whereas reduced loading also created catabolic responses within articular cartilage<sup>22</sup>. In our study, a significant decrease in the thickness of the lateral cartilages of the trochlea

was observed, while this was not the case in the medial and central parts of the trochlea. We consider that this may be due to the inconspicuous degeneration of the patellofemoral cartilages despite the early reduction in the medial and central stresses. The abnormal stress environment caused by patellar instability may lead to degeneration of the trochlear cartilage, which may be one of the leading factors resulting in early patellofemoral arthritis in patients with patellar instability<sup>23</sup>.

### Cartilage Morphology

Our study showed that the sulcus angle of cartilage in the patient group was greater than that in the control group. Trochlear dysplasia is considered to be a key factor causing patellar instability<sup>1, 24</sup>. In patients with patellar instability, the dysplasia of the medial and lateral femoral condyle makes the depth of the trochlear groove become shallower and the trochlear sulcus angle become larger, which also leads to the poor movement trajectory of the patella in the trochlear groove. The classification of trochlear imaging has been widely recognized. Furthermore, Dejour, Locatelli *et al.* and Tavernier *et al.* have also classified and measured the trochlear morphology by CT<sup>17</sup>. In fact, the geometric shape of the patellofemoral joint surface is not just the morphology of the bone, and the morphology of the cartilage is much more reflective of the actual morphology. Compared with CT and X-ray studies, MRI has the advantage of showing the distribution characteristics of cartilage in patients with patellar instability<sup>8, 24, 25</sup>. According to 3D-MRI, Yamada *et al.* considered that the femoral trochlear cartilage formed “convex femoral trochlea” which made the convex cartilage at the proximal end of the trochlear and caused the patella to fail to properly enter the trochlear groove and lead to instability or dislocation of the patella<sup>8</sup>. Our results showed that the deepest part of the intercondylar sulcus appeared more often in the lateral of the deepest part of the osseous concavity of the femoral trochlea. This might shorten the length of the lateral trochlear surface and also bring the patella closer to the lateral condyle and enter the femoral trochlea. Meanwhile, if accompanied by a decrease in the depth of the trochlear groove, patellar dislocation became more possible. In addition, it is speculated that stimulation of patellar lateral subluxation may, in turn lead to the extraverted distribution of the trochlear cartilage.

### Contact Range of Cartilage

We measured the contact range between the patella and the femoral trochlea. In the condition of stretching the knees of 18 patients with patellar instability, we found that range of contact with the femoral trochlea was smaller and the starting part of the contact range was closer to the lateral boundary compared with the control group. The contact area of the patellofemoral joint also changes with the difference of knee flexion Angle. Hayes *et al.*<sup>26</sup> study present that the patellofemoral compressive stress between 30° and 60° of the knee is the fastest, and Mills *et al.*<sup>27</sup> found that patellofemoral softening occurred in the contact area between

40° and 80° of the knee. Our study found that the patellar contact was close to the outside in the patients with patellar instability when they stretched their knees, indicating that the patellar trajectory had already tilted outward when the patella entered the trochlear groove. In addition, it is currently believed that the distribution of compressive stress on patellofemoral joint surface should be relatively symmetrical, but patellar instability breaks this balance, making the compressive stress on the lateral contact surface higher, which is more prone to cartilage lesions. Although some scholars suggested that changes in the trochlear groove have a genetic origin<sup>28, 29</sup>, there was a lack of precise hypotheses about patella morphology and its genetics. In recent years, many scholars believe that the chronic patellar instability occurs in the early time, which may lead to the poor movement of the patella and cannot effectively stimulate the normal formation of the femoral trochlea, resulting in the dysplasia of the femoral trochlea. In addition, previous studies have suggested that early patellar reduction could improve the morphology of the femoral groove<sup>12-14</sup>. Although our study found that the patients with patellar instability had developed abnormal morphology of articular cartilage, whether it is congenital or acquired remains unclear. Since previous studies have focused on the bone morphology of the trochlea, it remains to be further explored whether early patellar reduction is likely to change the articular morphology.

### Patellar Cartilage Thickness

Fucentese *et al.* have described that the patella of patients with trochlear dysplasia is smaller than that of the control group in terms of both the transverse diameter and medial. Moreover, the medial of the patella may be shaped not by the reduction of pressure on it, but by the traction on the

medial<sup>30</sup>. We focused on measuring changes in patellar cartilage thickness. There was no significant difference in measured cartilage thickness and cartilaginous Wiberg-angle, which was consistent with what Fucentese *et al.* had discovered. The patellar dislocation is more likely caused by the factor of transformed patellar morphology. In other words, thickness of the patella cartilage changes under the influence of the factor, so it cannot be regarded as the cause.

There are several limitations to our MRI-based study. Firstly, patients with patellar dislocation are often found with knee swelling, so we need to choose the clearest image as far as possible. Sometimes our failure to distinguish the boundary between cartilage and the edge of the bony structure on the image would cause measuring errors. Secondly, most of the patients we included were Dejour type B trochlear dysplasia, subjective errors were prone to exist in the measurement data since the lowest point of the trochlea groove was not obvious in the type C or D trochlea. Finally, our sample size is small. In future research, we should use a larger sample size to measure the cartilage thickness in multiple layers so that changes in cartilage geometry and thickness can be reflected in a more accurate way.

### Conclusion

Our research shows that cartilage thickness of patients with patellar instability decreases at LCT2 trochlear part and the trochlear cartilage develops abnormal morphology, which might worsen the malformation of trochlear dysplasia. Moreover, it also suggests that MRI can be used to further present the morphology of cartilage for the convenience of surgical planning. For children and adolescent patients, early relocation should be advocated to reduce the occurrence of long-term patellofemoral arthritis.

### References

1. Arendt EA, Fithian DC, Cohen E. Current concepts of lateral patella dislocation. *Clin Sports Med*, 2002, 21: 499-519.
2. Johnson DS, Turner PG. Management of the first-time lateral patellar dislocation. *Knee*, 2019, 26: 1161-1165.
3. Dejour H, Walch G, Nove-Josserand L, Guier C. Factors of patellar instability: an anatomic radiographic study. *Knee Surg Sports Traumatol Arthrosc*, 1994, 2: 19-26.
4. Lubis AMT, Panjaitan T, Hoo C. Autologous mesenchymal stem cell application for cartilage defect in recurrent patellar dislocation: a case report. *Int J Surg Case Rep*, 2019, 55: 183-186.
5. Sillanpää PJ, Mattila VM, Visuri T, Mäenpää H, Pihlajamäki H. Patellofemoral osteoarthritis in patients with operative treatment for patellar dislocation: a magnetic resonance-based analysis. *Knee Surg Sports Traumatol Arthrosc*, 2011, 19: 230-235.
6. Fithian DC, Paxton EW, Stone ML, *et al.* Epidemiology and natural history of acute patellar dislocation. *Am J Sports Med*, 2004, 32: 1114-1121.
7. Stäubli HU, Bosshard C, Porcellini P, Rauschnig W. Magnetic resonance imaging for articular cartilage: cartilage-bone mismatch. *Clin Sports Med*, 2002, 21: 417-433.
8. Yamada Y, Toritsuka Y, Yoshikawa H, Sugamoto K, Horibe S, Shino K. Morphological analysis of the femoral trochlea in patients with recurrent dislocation of the patella using three-dimensional computer models. *J Bone Joint Surg Br*, 2007, 89: 746-751.
9. Salonen EE, Magga T, Sillanpää PJ, Kiekara T, Mäenpää H, Mattila VM. Traumatic patellar dislocation and cartilage injury: a follow-up study of long-term cartilage deterioration. *Am J Sports Med*, 2017, 45: 1376-1382.
10. van Huyssteen AL, Hendrix MR, Barnett AJ, Wakeley CJ, Eldridge JD. Cartilage-bone mismatch in the dysplastic trochlea. An MRI Study. *J Bone Joint Surg Br*, 2006, 88: 688-691.
11. Xia H, Cao D, Yang F, *et al.* Jiawei Yanghe decoction ameliorates cartilage degradation in vitro and vivo via Wnt/ $\beta$ -catenin signaling pathway. *Biomed Pharmacother*, 2020, 122: 109708.
12. Wang S, Ji G, Yang X, *et al.* Femoral trochlear groove development after patellar subluxation and early reduction in growing rabbits. *Knee Surg Sports Traumatol Arthrosc*, 2016, 24: 247-253.
13. Benoit B, Laflamme GY, Laflamme GH, Rouleau D, Delisle J, Morin B. Long-term outcome of surgically-treated habitual patellar dislocation in children with coexistent patella Alta. Minimum follow-up of 11 years. *J Bone Joint Surg Br*, 2007, 89: 1172-1177.
14. Fu K, Duan G, Liu C, Niu J, Wang F. Changes in femoral trochlear morphology following surgical correction of recurrent patellar dislocation associated with trochlear dysplasia in children. *Bone Joint J*, 2018, 100-B: 811-821.
15. Kujala UM, Osterman K, Kormanen M, Nelimarkka O, Hurme M, Taimela S. Patellofemoral relationships in recurrent patellar dislocation. *J Bone Joint Surg Br*, 1989, 71: 788-792.
16. Pfirrmann CW, Zanetti M, Romero J, Hodler J. Femoral trochlear dysplasia: MR findings. *Radiology*, 2000, 216: 858-864.
17. Nelitz M, Lippacher S, Reichel H, Dornacher D. Evaluation of trochlear dysplasia using MRI: correlation between the classification system of Dejour and objective parameters of trochlear dysplasia. *Knee Surg Sports Traumatol Arthrosc*, 2014, 22: 120-127.
18. Elias DA, White LM. Imaging of patellofemoral disorders. *Clin Radiol*, 2004, 59: 543-557.
19. Guevara JM, Moncayo MA, Vaca-González JJ, Gutiérrez ML, Barrera LA, Garzón-Alvarado DA. Growth plate stress distribution implications during bone development: a simple framework computational approach. *Comput Methods Programs Biomed*, 2015, 118: 59-68.



- 20.** Buckwalter JA, Martin JA. Osteoarthritis. *Adv Drug Deliv Rev*, 2006, 58: 150–167.
- 21.** Torzilli PA, Grigiene R, Borrelli J Jr, Helfet DL. Effect of impact load on articular cartilage: cell metabolism and viability, and matrix water content. *J Biomech Eng*, 1999, 121: 433–441.
- 22.** Sun HB. Mechanical loading, cartilage degradation, and arthritis. *Ann N Y Acad Sci*, 2010, 1211: 37–50.
- 23.** Mäenpää H, Lehto MU. Patellar dislocation. The long-term results of nonoperative management in 100 patients. *Am J Sports Med*, 1997, 25: 213–7.
- 24.** Biedert R, Sigg A, Gal I, Gerber H. 3D representation of the surface topography of normal and dysplastic trochlea using MRI. *Knee*, 2011, 18: 340–346.
- 25.** Song YF, Wang XY, Niu YZ, Dong ZY, Qi JC, Wang F. Magnetic resonance imaging-based pathogenic investigation of patellar instability. *Chin Med J*, 2019, 132: 1998–1999.
- 26.** Lewallen DG, Riegger CL, Myers ER, Hayes WC. Effects of retinacular release and tibial tubercle elevation in patellofemoral degenerative joint disease. *J Orthop Res*, 1990, 8: 856–862.
- 27.** Mills K, Hunter DJ. Patellofemoral joint osteoarthritis: an individualised pathomechanical approach to management. *Best Pract Res Clin Rheumatol*, 2014, 28: 73–91.
- 28.** Garron E, Jouve JL, Tardieu C, Panuel M, Dutour O, Bollini G. Anatomic study of the anterior patellar groove in the fetal period. *Rev Chir Orthop Reparatrice Appar Mot*, 2003, 89: 407–412.
- 29.** Tardieu C, Dupont JY. The origin of femoral trochlear dysplasia: comparative anatomy, evolution, and growth of the patellofemoral joint. *Rev Chir Orthop Reparatrice Appar Mot*, 2001, 87: 373–383.
- 30.** Fucentese SF, von Roll A, Koch PP, Epari DR, Fuchs B, Schottle PB. The patella morphology in trochlear dysplasia—a comparative MRI study. *Knee*, 2006, 13: 145–150.