

REVIEW

Comprehensive medical evaluation of pediatric bilateral sensorineural hearing loss

Suat Kılıç MD¹  | Malek H. Bouzaher MD¹ | Michael S. Cohen MD²  |
Judith E. C. Lieu MD, MSPH³  | Margaret Kenna MD, MPH⁴  |
Samantha Anne MD, MS¹ 

¹Head and Neck Institute, Cleveland Clinic, Cleveland, Ohio, USA

²Department of Otolaryngology, Head and Neck Surgery, Harvard Medical School, Boston, Massachusetts, USA

³Department of Otolaryngology-Head and Neck Surgery, Washington University in St. Louis, St. Louis, Missouri, USA

⁴Department of Otolaryngology and Communication Enhancement, Boston Children's Hospital, Boston, Massachusetts, USA

Correspondence

Samantha Anne, Head & Neck Institute, Cleveland Clinic, 9500 Euclid Ave A71, Cleveland, OH 44195, USA.
Email: annes@ccf.org

Abstract

Children with bilateral sensorineural hearing loss (SNHL) should undergo a comprehensive medical evaluation to determine the underlying etiology and help guide treatment and counseling. In this article, we review the indications and rationale for medical evaluation of pediatric bilateral SNHL, including history and physical examination, imaging, genetic testing, specialist referrals, cytomegalovirus (CMV) testing, and other laboratory tests. Workup begins with a history and physical examination, which can provide clues to the etiology of SNHL, particularly with syndromic causes. If SNHL is diagnosed within the first 3 weeks of life, CMV testing should be performed to identify patients that may benefit from antiviral treatment. If SNHL is diagnosed after 3 weeks, testing can be done using dried blood spots samples, if testing capability is available. Genetic testing is oftentimes successful in identifying causes of hearing loss as a result of recent technological advances in testing and an ever-increasing number of identified genes and genetic mutations. Therefore, where available, genetic testing should be performed, ideally with next generation sequencing techniques. Ophthalmological evaluation must be done on all children with SNHL. Imaging (high-resolution computed tomography and/or magnetic resonance imaging) should be performed to assess for anatomic causes of hearing loss and to determine candidacy for cochlear implantation when indicated. Laboratory testing is indicated for certain etiologies, but should not be ordered indiscriminately since the yield overall is low.

KEYWORDS

bilateral sensorineural hearing loss, EKG, genetic testing, imaging, medical evaluation, medical workup, pediatric sensorineural hearing loss, SNHL

1 | OVERVIEW

Sensorineural hearing loss (SNHL) occurs in 0.2% to 0.4% of live births, affects approximately 40 000 children annually in the United States (US), and affects both ears in nearly 2/3 of the

cases.^{1,2} Bilateral SNHL in children has been shown to cause poorer development of speech and language, even when the hearing loss is mild to moderate.³⁻⁵ Therefore, early identification, determination of etiology, and appropriate treatment are essential for optimal outcomes.

This is an open access article under the terms of the Creative Commons Attribution-NonCommercial-NoDerivs License, which permits use and distribution in any medium, provided the original work is properly cited, the use is non-commercial and no modifications or adaptations are made.

© 2021 The Authors. *Laryngoscope Investigative Otolaryngology* published by Wiley Periodicals LLC on behalf of The Triological Society.

The Early Hearing Detection and Intervention (EHDI) Guidelines for Pediatric Medical Home Providers, published by the Joint Committee on Infant Hearing (JCIH), have recommended a timeline for early identification and intervention for hearing loss in children.⁶ The 2019 edition recommends identification of a medical home at birth and completion of hearing screen or rescreening by 1 month of age. If a child fails the newborn hearing screening, a pediatric audiologist should perform a diagnostic valuation by 2 to 3 months of age. If diagnostic evaluation reveals hearing loss, the patient must be referred to a First Steps or Early Intervention program for each state (through the Individuals with Disabilities Education Act—Part C),⁷ and to an otolaryngologist by 3 to 6 months of age. Referral to an ophthalmologist and geneticist is also recommended, although a timeline is not specified for these evaluations. All children, regardless of hearing status, should receive the standard “ongoing care of all infants” (eg, vision screening, developmental screening, identification, and aggressive treatment of middle ear disease).

A comprehensive workup of bilateral SNHL, including these EHDI recommendations, is of paramount importance. Determining the underlying cause can have prognostic and management implications for both the hearing loss and potential co-occurring conditions. Medical workup has the highest diagnostic yield in younger children and children with profound bilateral SNHL, but the yield is still considerably high even in older children.⁸⁻¹⁰ A recent study of 300 children with bilateral SNHL found that in children older than 6 years of age, an etiology was identified 58% of the time.⁸

Bilateral SNHL is typically classified as genetic, non-genetic, or idiopathic. Notably, while most genetic cases are inherited, *de novo* mutations can also lead to genetic bilateral SNHL.^{11,12} Genetic causes are further divided into syndromic and non-syndromic causes. SNHL is also classified as congenital (present at birth and identified in the neonatal period), or delayed onset (is prenatal in etiology, but is identified after the neonatal period). Genetic and non-genetic causes can contribute to both of these categories. Common etiologies of bilateral SNHL are listed in Table 1, along with the approximate percentage of cases attributed to each category. The percentage that each etiology comprises is variable in the literature and differs to some degree with age of the patients and populations studied; the percentages shown in this table are based on findings in studies that evaluated large cohorts of children with bilateral SNHL.⁸ The purpose of the current review is to describe the medical evaluation of bilateral SNHL. A simplified diagram to help guide this process is provided in Figure 1.

TABLE 1 Common etiological categories of bilateral SNHL⁸

Etiology	Percentage
Genetic, non-syndromic	24.6%
Genetic, syndromic	20.7%
Congenital CMV	17.0%
Idiopathic	33.0%

Abbreviations: bilateral SNHL, bilateral sensorineural hearing loss; CMV, cytomegalovirus; NICU, neonatal intensive care unit.

1.1 | History and physical

The evaluation of bilateral SNHL begins with eliciting a thorough history. It is important to obtain a birth history, as prenatal, perinatal, and postnatal risk factors may suggest the underlying etiology. The clinician should inquire about important risk factors for hearing loss included in the JCIH position statement, including prenatal maternal vaccination status and testing, perinatal infections, premature birth, low birth weight, hyperbilirubinemia, prolonged stay in the neonatal intensive care unit, administration of ototoxic medications (eg, intravenous aminoglycosides), and family history.⁶ Given that a large percentage of bilateral SNHL is due to hereditary causes, a family history of at least three generations should be obtained when possible. Next, a thorough review of systems should be obtained, with particular emphasis on the neurologic, ophthalmologic, otologic, cardiac, and genitourinary components. This can guide testing for genetic causes as well as help identify features of infectious etiologies, such as syphilis, toxoplasmosis, cytomegalovirus (CMV), and rubella.

The physical exam should include a complete head and neck examination, otologic exam and inspection for dysmorphic facial features, as well as cardiac, ophthalmologic, neurologic, neck/thyroid, and extremity examinations. Although history and physical examination alone are usually insufficient to determine the underlying etiology of bilateral SNHL, it can help guide diagnostic testing and need for referral to specialists.

2 | DIAGNOSTIC EVALUATION

2.1 | Imaging

Imaging is a key component of the diagnostic evaluation for pediatric patients with SNHL. In addition to its role in determining a potential etiology, imaging can identify anomalies that can be associated with hearing loss progression and evaluate suitability for operative intervention.^{13,14} In particular, imaging allows for assessment of the anatomical structures of the cochlea, labyrinth, cranial nerves, and neural pathways responsible for processing of auditory information. Anatomic abnormalities can help prognosticate success with various methods of hearing rehabilitation and, in some cases, may preclude surgical intervention entirely.¹⁵ The imaging modalities of choice for the assessment of pediatric SNHL are high-resolution computed tomography (HRCT) and magnetic resonance imaging (MRI) of the temporal bone. HRCT provides better visualization of bony structures with the advantages of lower costs and quicker imaging times that are better tolerated by pediatric patients. However, HRCT exposes the patient to ionizing radiation, which has been shown in longitudinal studies to increase the lifetime risk of developing certain types of cancer.¹⁶ MRI provides superior quality images of soft tissues and neural structures, but is associated with increased cost and longer imaging times, which often necessitate sedation in children.^{17,18} However, recent studies utilizing modified MRI protocols, adapted in an effort to reduce the use of sedatives and improve tolerance in children, have shown considerable promise.^{19,20}

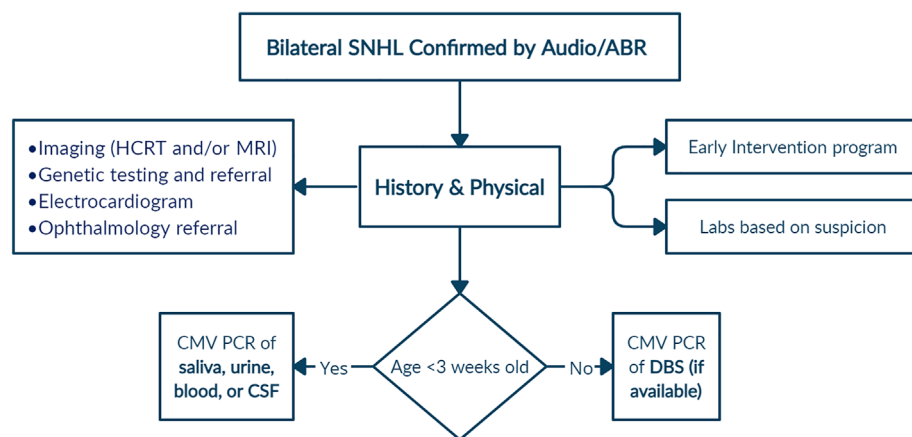


FIGURE 1 Simplified flowchart for medical evaluation of bilateral sensorineural hearing loss

Due to these various factors, there is considerable variation in practice and institutional protocols in the type and timing of imaging obtained.^{10,17,21,22} Consensus guidelines have been published to provide a standardized approach for evaluation of pediatric SNHL, but have not been uniformly adopted.^{23,24} Systematic review of the literature suggests that imaging should play a role in the diagnostic paradigm for pediatric bilateral SNHL, with the results significantly influenced by both the severity of hearing loss and the status of genetic testing.^{22,25-28} Several studies have demonstrated a positive correlation between diagnostic yield and severity of hearing loss, with a nearly 20% increase in diagnostic yield being demonstrated in severe-profound hearing loss groups as compared with mild-moderate hearing loss groups.^{22,26} Diagnostic yield from imaging is significantly diminished in patients who test positive for mutations in *GJB2*, which is the most common cause of inherited non-syndromic hearing loss.^{22,27,29,30}

It remains unclear which imaging modality should be used, with some studies revealing increased diagnostic yield with HRCT and others with MRI.^{22,31} Several institutions send patients for either HRCT or MRI, while others have all patients complete both tests as part of the evaluation. Two systematic reviews have found that HRCT appears to have greater diagnostic yield than MRI for diagnosing enlarged vestibular aqueduct and cochlear abnormalities, whereas MRI identified more brain abnormalities.^{32,33} The diagnostic yield of HRCT is estimated to be about 30% based upon aggregate data with a number needed to image of four.³² Tables 2-4 include the most commonly identified abnormalities stratified by imaging modality for studies that had a clearly identified pediatric bilateral SNHL population. In cases of auditory neuropathy, MRI has been shown to be highly effective in identifying cochlear nerve deficiency, which is a common finding in these cases.³⁴

2.2 | Genetic testing

Approximately 50% of pediatric SNHL overall is due to genetic causes, and the remaining 50% are due to non-genetic causes. Among the genetic causes, approximately 70% are non-syndromic and 30% are

due to syndromic causes.³⁵ However, genetic causes are 2.5 times as common in bilateral SNHL, as they are in unilateral SNHL.⁸ Therefore, genetic testing plays a greater role in the evaluation of bilateral SNHL. A comprehensive list of genetic non-syndromic causes of SNHL can be found on the Hereditary Hearing Loss Homepage (<https://hereditaryhearingloss.org>, accessed July 3, 2021). As of June 27, 2021, 123 non-syndromic genes have been identified. Among these, *GJB2* (Connexin-26) is by far the most common. Table 5 includes a list of the most common genetic causes of bilateral SNHL. *GJB2* (Connexin 26) and *GJB6* (Connexin 30), both at the *DFNB1* locus, are the most common genes associated with bilateral SNHL, accounting for 31% of confirmed genetic cases in a recent large study.⁸ Three of the most frequently reported syndromic causes include Pendred, Usher, and Waardenburg syndromes.^{8,36-38}

The widespread availability of genetic testing has changed the diagnostic landscape of SNHL, particularly in non-syndromic cases. Among the options for medical testing available, genetic testing has the highest yield. With modern testing methods, a genetic cause can be identified in approximately 44% of patients with bilateral SNHL.³⁸ In addition, the cost of genetic testing has decreased significantly, making it more feasible for use on a large scale. One study of 53 711 children with SNHL found that the likelihood of receiving genetic testing increased substantially between 2008 and 2018 (odds ratio: 1.22 per year; 95% CI, 1.20-1.24).³⁹

Single-gene testing (SGT), generally for *GJB2/6*, was commonly used in the early days of genetic testing for SNHL, and some clinicians still advocate for *GJB2/6* testing as the initial step. However, comprehensive genetic testing (CGT) has a much higher yield and has become the standard of care.^{24,40} The International Pediatric Otolaryngology Group (IPOG) is a group of pediatric otolaryngologists that provides expertise-based consensus recommendations for the management of pediatric otolaryngologic disorders with the goal of improving patient care. In the 2016 IPOG consensus recommendations, 84% of respondents were in agreement or in partial agreement that SGT for *GJB2/6* is of low diagnostic yield and should not be offered as part of an initial workup unless a known family history exists or CGT is not available.²⁴ CGT uses next generation sequencing (NGS) techniques, such as disease-targeted exon-capture, whole-exome sequencing (WES), or

TABLE 2 Studies utilizing CT for evaluation of pediatric bilateral SNHL

Study title	Author	Year	# with bilateral SNHL	Age group (mean)	Most common finding
Etiologic and audiologic characteristics of patients with pediatric-onset unilateral and asymmetric sensorineural hearing loss ⁶⁶	Lin et al	2017	41 (30 imaged)	0 to 46 years (9.1 years old)	CCC, cochlear aperture stenosis, semicircular canal dysplasia (one each)
Characteristics and application of inner ear CT in 20 cases of sensorineural hearing loss in children ⁶⁷	Huo et al	2012	65	1 to 14 years old (3.78 years old)	EVA
Imaging correlation of children with DFNB1 vs non-DFNB1 hearing loss ²⁹	Kochhar et al	2009	19	NR	Enlarged vestibule, widened lateral semicircular canal island (four each)
Audiologic and temporal bone imaging findings in patients with sensorineural hearing loss ²⁷	Lee et al	2009	369 (# imaged NR)	NR	EVA
Etiology of deafness in children cochlear implant candidates in Croatia ⁶⁸	Drvis et al	2008	270	5 months to 14 years old (3.9 years old)	EVA
Characteristics of sensorineural hearing loss in children with inner ear anomalies ⁶⁹	Coticchia et al	2006	18 (14 imaged)	NR	NR
Improved diagnostic effectiveness with a sequential diagnostic paradigm in idiopathic pediatric sensorineural hearing loss ⁷⁰	Preciado et al	2005	129	1 week to 18 years old (4.8 years old)	EVA
Major and minor temporal bone abnormalities in children with and without congenital sensorineural hearing loss ⁷¹	McClay et al	2002	72	2 months to 15 years old	Cochlear abnormalities (not specified)
Causes of pediatric sensorineural hearing loss ⁶⁵	Bilings et al	1999	241 (# imaged NR)	AOD 1 month to 13 years (3.54 years old)	EVA
Computed tomography evaluation of the inner ear as a diagnostic, counselling, and management strategy in patients with congenital sensorineural hearing impairment ⁷²	Cross et al	1999	176 (98 imaged)	13 to 20 years old	EVA
Clinical features of the prevalent form of childhood deafness, DFNB1, due to a connexin-26 gene defect: implications for genetic counselling ⁷³	Denoyelle et al	1999	140 (# imaged NR)	4 to 20 years old (7 years old)	EVA
Usefulness of computed tomographic scan in the evaluation of sensorineural hearing loss in children ⁷⁴	Shusterman et al	1992	32	1 to 20.9 years old (6.76 years old)	EVA, large ventricles (three each)

Abbreviations: AOD, age at diagnosis; CCC, common cochlear cavity; EVA, enlarged vestibular aqueduct; NR, not reported.

whole-genome sequencing (WGS) strategies. Disease targeted exon-capture techniques test for a large list of genes known to cause hearing loss.⁴¹ A registry of available genetic tests can be found at “<https://www.ncbi.nlm.nih.gov/gtr>.” Turnaround for testing varies between 3 to 12 weeks.⁴⁰

Unless insurance mandates *GJB2/6* testing as an initial study, the yield will be statistically higher if CGT strategies are considered,

starting with targeted NGS testing, which covers many common and less common genes. WES or WGS can be used as secondary studies if pathogenic variants were not identified on large targeted sequencing panels.^{42,43} The challenge with WGS or WES is that they may identify genes/mutations of unknown significance, or identify genes/mutations with implications for conditions unrelated to hearing.⁴¹ These stepwise genetic testing strategies may be more cost effective

TABLE 3 Studies utilizing MRI for evaluation of pediatric bilateral SNHL

Study title	Author	Year	# with bilateral SNHL	Age group (mean)	Most common finding
Cerebral volume and diffusion MRI changes in children with sensorineural hearing loss ⁷⁵	Moon et al	2020	50	(5.3 years old)	Enlarged vestibular aqueduct, multiple abnormalities (not specified); (five each)
Management and outcomes of cochlear implantation in patients with congenital cytomegalovirus (cCMV)-related deafness ⁷⁶	Hoey et al	2017	11 (case series)	.6 to 7.5 years old (2.1 years old)	Brain abnormalities
Hearing loss and enlarged internal auditory canal in children ⁷⁷	Santos et al	2014	four (case series)	NR	Incomplete partition type II
Sensorineural hearing loss in a pediatric population association of congenital cytomegalovirus infection with intracranial abnormalities ⁷⁸	Kimani et al	2010	95 (# imaged NR)	1 to 5 years old	Cochlear nerve deficiency
CT and MR imaging for pediatric cochlear implantation: emphasis on the relationship between the cochlear nerve canal and the cochlear nerve ⁷⁹	Miyasaka et al	2010	10	1 to 13 years old (7 years old)	Enlarged vestibular aqueduct
Evaluation of pediatric sensorineural hearing loss with magnetic resonance imaging ²⁶	McClay et al	2008	101	(5.3 years old)	Cochlear dysplasia
Central nervous system findings by magnetic resonance in children with profound sensorineural hearing loss ⁸⁰	LaPointe et al	2005	40	NR	Cochlear nerve hypoplasia

Abbreviations: NR, not reported.

and help avoid WGS and WES in circumstances where they are not necessary.⁴⁴⁻⁴⁷ Other alternatives include the use of targeted sequencing or microarray testing if a syndromic cause is suspected.⁴⁸ Targeted sequencing can test for a set of mutations or genes known to cause the suspected syndrome. In addition, microarrays may detect copy number variations, an increasingly recognized type of mutation related to hearing loss.^{34,49}

Referral to genetic counseling or medical genetics is highly recommended, because genetic specialists are especially adept at recognizing nuances to examination, testing, and counseling both before and after diagnosis. One study demonstrated that genetic testing ordered by a genetic specialist is more cost effective than testing ordered by otolaryngologists.⁵⁰ There are also ethical and social concerns with genetic testing, including the psychological impact on the patient and the family, medical implications for family members, and the potential for discrimination relating to employment and insurance.^{51,52} Genetic testing does not always identify the etiology, or it may identify variations of unknown significance (VUS), particularly when WGS or WES is used. Furthermore, follow-up is recommended when there are VUSs, because features related to certain mutations may become more apparent as the child grows, at which point additional testing may be indicated. In addition, ongoing reanalysis of VUSs may reclassify the VUS as either benign, or in some cases pathogenic, leading to a definite hearing loss etiology.

2.3 | CMV testing

Approximately half of non-genetic causes of SNHL are due to prenatal and perinatal infections, the TORCHES (toxoplasmosis, rubella, CMV, herpes, and syphilis) infections specifically.⁵³ Among these, congenital CMV (cCMV) is by far the most frequent cause of bilateral SNHL.⁵³ In one systematic review, 14% to 41% of children with symptomatic cCMV infection were reported to develop SNHL vs 7.4% to 11% children with asymptomatic infections.⁵⁴ In one study, 43% of infants with cCMV who passed their NBHS were diagnosed with SNHL on diagnostic testing completed at 3 to 8 weeks of age.^{54,55} Therefore, UNHS is not a reliable indicator of normal hearing in newborns with cCMV (they could have mild hearing loss and still pass UNHS). UNHS is also not a prognosticator of normal hearing, as cCMV is one of the more common causes of progressive SNHL in children.

Traditionally, viral culture techniques were used to diagnose congenital CMV, but polymerase chain reaction (PCR) testing of urine, saliva, blood, or cerebrospinal fluid is currently preferred. PCR testing is highly sensitive and specific; when saliva is used for testing, the sensitivity is 100%, and the specificity is 99%.⁵⁶ Since postnatal infection with CMV is common and not associated with SNHL, distinguishing cCMV from postnatally acquired CMV infection is important. The diagnosis is considered cCMV if made within the first 21 days. Given the high incidence of cCMV in children with bilateral SNHL and

TABLE 4 Studies utilizing both CT and MRI for evaluation of pediatric bilateral SNHL

Study title	Author	Year	# with bilateral SNHL	Age group (mean)	Most common finding
Medical referral patterns and etiologies for children with mild-to-severe hearing loss ⁸¹	Judge et al	2019	307 (146 imaged)	NR	CT: bilateral enlarged vestibular aqueduct; MRI: bilateral enlarged vestibular aqueduct
Evaluation of the outcome of CT and MR imaging in pediatric patients with bilateral SNHL ³⁶	van Beeck Calkoen et al	2018	207	AOD 1 month to 17 years old (0.8 years old)	Enlarged vestibular aqueduct
Utilization of diagnostic testing for pediatric sensorineural hearing loss ²⁵	Wentland et al	2018	462 (340 imaged)	AOD 0 to 18 years old (4.3 years old)	CT: cochlear or vestibular abnormality (not specified); MRI: cochlear nerve deficiency
Clinical outcomes following cochlear implantation in children with inner ear anomalies ⁸²	Isaiah et al	2017	496 (381 imaged)	1 to 18 years old	Cochlear dysplasia
Resolution of bilateral sensorineural hearing loss following ventriculoperitoneal shunt and literature review ⁸³	Jamshidi et al	2017	One (case study)	NA	Hydrocephalus
Imaging evaluation of pediatric sensorineural hearing loss in potential candidates for cochlear implantation ⁸⁴	Jallu et al	2015	40	1 to 16 years old	Enlarged vestibular aqueduct
Pediatric cochlear implantation of children with eighth nerve deficiency ⁸⁵	Young et al	2012	10	AOI 1.1 to 5.2 years old (2.6 years old)	Incomplete partition type ii, absent cochlear nerve division in distal IAC (seven each)
Integrated profile to assess auditory nerve-auditory pathway integrity ⁸⁶	Kong et al	2009	68	1 to 15 years old (5 years and 5 months old)	NR
Etiologic and audiologic evaluations after universal neonatal hearing screening: analysis of 170 referred neonates ⁸⁷	Declau et al	2008	68 (# imaged NR)	NR	NR
Evaluation of cochlear nerve imaging in severe congenital sensorineural hearing loss ⁸⁸	Komatsubara et al	2007	Five	NR	NR
Cochlear nerve size evaluation in children with sensorineural hearing loss by high-resolution magnetic resonance imaging ³⁰	Russo et al	2006	24	NR	Cochlear nerve hypoplasia
Computed tomography and magnetic resonance imaging in pediatric unilateral and asymmetric sensorineural hearing loss ²⁸	Simons et al	2006	49	AOD 0 to 13 years (3.7 years old)	Enlarged vestibular aqueduct
A diagnostic paradigm for childhood idiopathic sensorineural hearing loss ²²	Preciado et al	2004	496 (466 imaged)	1 week to 18 years old (5.8 years old)	Enlarged vestibular aqueduct
Use of laboratory evaluation and radiologic imaging in the diagnostic evaluation of children with sensorineural hearing loss ⁸⁹	Mafong et al	2002	95 (number imaged not reported)	1 to 18 years old (9 years old)	Enlarged vestibular aqueduct
Cochlear nerve aplasia: its importance in cochlear implantation ⁹⁰	Maxwell et al	1999	One (case study)	NA	Narrow IAC, atrophic CN VIII

Abbreviations: AOD, age at diagnosis; AOI, age at implantation; IAC, internal auditory canal; NR, not reported.

narrow diagnostic window, all neonates who refer on newborn hearing screening or diagnosed with SNHL should be tested for CMV within the first 3 weeks of life. Diagnosis of CMV as the cause of SNHL in the neonatal period is crucial, as early diagnosis is necessary

to allow for consideration of antiviral treatment with intravenous ganciclovir or oral valganciclovir.⁵⁷

An alternative method of diagnosing CMV involves the use of the dried blood spots (DBS) obtained from a heel stick for the newborn

TABLE 5 Common genetic causes of pediatric bilateral sensorineural hearing loss

	Genetic cause (inheritance pattern)	Associated genes	Predominant features	Other findings
Syndrome	Pendred (AR)	SLC26A4	Euthyroid (often) goiter, progressive, often asymmetric , mild to moderate sensorineural or mixed hearing loss	Intracochlear partition defect type II (Mondini) deformity in which the cochlea has less than the normal 2.5 turns and/or enlarged vestibular aqueduct on CT or MRI
	Usher (AR)	Type I Type II Type III <i>MYO7A; USH1C; CDH23; PCDH15; SANS/USH1G</i> <i>USH2A; ADGRV1; WHRN</i> <i>CLRN1; HARS1</i>	Type I: profound hearing loss at birth, vestibular dysfunction starting at birth, vision problems early in life Type II: moderate to severe hearing loss at birth, vision problems by adolescence with progression, no vestibular dysfunction Type III: progressive hearing loss, later onset vestibular dysfunction, and vision loss starting later in childhood or adolescence	Electroretinogram or dark adapted thresholds may show signs of RP earlier than routine ocular examination; there are also few variants that result in either nonsyndromic RP or nonsyndromic HL
	Waardenburg (AD)	<i>PAX3-WS1/3</i> <i>MITF-WS2</i> <i>SNAI2-WS2D</i> <i>SOX10-WS2E, 4C</i> <i>EDNRB-WS4A</i> <i>EDN3-WS4B</i>	Progressive hearing loss, hematuria, ocular abnormalities (anterior lenticonus, retinopathy)	Dystopia canthorum (WS1), synophrys, vitiligo, heterochromia iridis, white forelock; upper limb anomalies (WS3), Hirschsprung disease (WS4)
	Branchi-oto-renal (AD)	<i>EYA1; SIX1; SIX5</i>	HL is generally congenital, ear anomalies may involve external, middle, and inner ear	
	Stickler	<i>COL2A1, COL11A1, or COL11A2</i> (AD) <i>COL9A1, COL9A2, or COL9A3</i> (AR)	2/3 of hearing loss is sensorineural. Cleft palate, pierre robin sequence, ophthalmologic issues including severe myopia and/or retinal detachment	
	Alport	<i>COL4A5</i> (X-linked); <i>COL4A3</i> or <i>COL4A4</i> (AR)	Progressive hearing loss, hematuria, ocular abnormalities (anterior lenticonus, retinopathy)	Kidney biopsy may reveal glomerulonephritis
	Jervell and Lange-Nielsen (AR)	<i>KCNQ1; KCNE1</i>	Severe to profound bilateral congenital SNHL, syncope, sudden death	Prolongation of QT interval on electrocardiogram (ECG)
Non-syndromic	DFNB1	<i>GJB2</i>	Congenital mild-to-profound autosomal recessive nonsyndromic hearing loss	Usually normal temporal bone imaging. Rarer dominant forms are associated with skin disease. Uncommon digenic inheritance with both <i>GJB2</i> and <i>GJB6</i>
	DFNB16	<i>STRC</i> (<i>CATSPER2</i>)	Bilateral mild to moderate congenital SNHL; deletion of both <i>STRC</i> and <i>CATSPER2</i> is associated with SNHL and infertility in males	

TABLE 5 (Continued)

Genetic cause (inheritance pattern)	Associated genes	Predominant features	Other findings
DFNA8	TECTA	Often prelingual, often milder, and mid- or high-frequency SNHL	
DFNB3	MYO15A	Progressive bilateral SNHL	
Mitochondrial hearing loss	MT-RNR1 (12s rRNA)-1555A > G (most common one)	Maternally inherited nonsyndromic hearing loss, or hearing loss that occurs after brief exposure to aminoglycosides	

Note: Adapted with permission from Lieu et al.²

Abbreviations: AD, autosomal dominant; AR, autosomal recessive; CT, computed tomography; MRI, magnetic resonance imaging; SNHL, sensorineural hearing loss.

TABLE 6 Lab tests, indications, and diagnoses in the work up of pediatric bilateral SNHL

Lab test	Indications	Associated disease/syndrome
Complete blood count	Unilateral or bilateral HL with other manifestations of leukemia (fever, malaise, night sweats, lymphadenopathy, splenomegaly, etc.)	Leukemia ⁹¹
Platelet count	Bilateral SNHL with visual abnormalities, abnormal renal function, bleeding diathesis	Fechtner syndrome ⁹² (variant of Alport syndrome)
Urinalysis	Bilateral SNHL (usually develops in late childhood and is progressive in Alport Syndrome; may be asymmetric) with visual abnormalities (lenticonus, keratoconus, cataracts, and corneal erosion), abnormal renal function (gross or microscopic hematuria, proteinuria)	Alport syndrome, ⁸⁸ Fechtner syndrome ⁹²
Blood glucose	Bilateral SNHL with vision problems, obesity, signs of cardiovascular dysfunction (shortness of breath, fluid overload, etc.)	Alström syndrome, diabetes mellitus ⁹³
Lipid panel	Bilateral SNHL with vision problems, obesity, signs of cardiovascular dysfunction (shortness of breath, fluid overload, etc.)	Alström syndrome, hyperlipidemia-associated hearing loss ⁹³
Electrocardiogram	Bilateral SNHL loss with history of syncopal episodes (usually precipitated by exertion, stress, fright)	Jervell and Lange-Nielsen ⁶⁴
Thyroid function tests	Bilateral SNHL (may be asymmetric) with goiter, signs of hypothyroidism	Pendred syndrome ⁹⁴
Anti-nuclear antibody	SNHL that may be unilateral, bilateral, asymmetric, or sudden with other manifestations of autoimmune disease (fever, malaise, mood disturbance, joint pain, rashes, etc.)	Autoimmune diseases (lupus, GPA, RA, etc.) ⁹⁵
Rheumatoid factor	SNHL that may be unilateral, bilateral, asymmetric, or sudden with other manifestations of autoimmune disease (fever, malaise, mood disturbance, joint pain, rashes, etc.)	Autoimmune diseases (lupus, GPA, RA, etc.) ⁹⁵
ESR, CRP	SNHL that may be unilateral, bilateral, asymmetric, or sudden with other manifestations of autoimmune disease (fever, malaise, mood disorders, joint pain, rashes, etc.)	Autoimmune diseases (lupus, GPA, RA, etc.) ⁹⁵
Rapid plasma reagent	Bilateral SNHL (usually sudden, symmetric, and profound) with visual abnormalities, notched incisors, mulberry molars, saddle nose deformity	Syphilis ⁹⁶
Fluorescent anti-treponemal antibody	Bilateral SNHL (usually sudden, symmetric, and profound) with vision problems, notched incisors, mulberry molars, saddle nose deformity	Syphilis ⁹⁶

Abbreviations: CRP, c-reactive protein; ESR, erythrocyte sedimentation rate; GPA, granulomatosis with polyangiitis; RA, rheumatoid arthritis; SNHL, sensorineural hearing loss.

screening panel.⁵⁷⁻⁵⁹ PCR testing for CMV DNA can be carried out using a DBS sample, though sensitivity is significantly reduced compared with testing of urine or saliva specimens. Given that a considerable portion of CMV related hearing loss presents beyond the neonatal period, and the absence of routine universal CMV screening, DBS can be helpful in making a diagnosis of congenital CMV retrospectively. A 2015 systematic review and meta-analysis of CMV DBS testing reported a pooled sensitivity and specificity of 84.4% (95% CI = 81.2%-87.2%) and 99.99% (95% CI = 99.8%-99.9%), respectively.⁵⁹ To that end, respondents to the 2016 IPOG hearing loss consensus recommendation survey agreed that DBS can be used as an adjunct diagnostic test after the first 3 weeks of life where available.²⁴ Each state has its own regulations regarding storage of DBS cards (from no storage to 5 or more years), so each physician should be cognizant of local availability of DBS testing.

3 | SPECIALIST CONSULTATIONS AND LABORATORY TESTING

Consultation with medical genetics was discussed earlier in the context of genetic testing. All children with SNHL should also be referred to ophthalmology.¹ All respondents to the IPOG survey agreed or partially agreed that all children with SNHL should be referred for ophthalmologic evaluation.²⁴ Children with SNHL have a 2 to 3-fold increase in the incidence of ocular abnormalities, including correctible vision disorders such as astigmatism and refractive errors.⁶⁰ Studies have shown that ophthalmologic consultation has a high yield in identifying visual anomalies.⁶¹⁻⁶³ In contrast, cardiology consultation has relatively low yield and should be done if genetic testing or EKG identifies a cardiac anomaly that needs further evaluation. Long QT syndrome, also called Jervell and Lange Nielsen, can present in newborns with bilateral SNHL, and ECG in these babies is warranted, especially if genetic testing is not available.⁶⁴ Speech and language evaluation should be performed at time of diagnosis of SNHL given the increased likelihood of speech abnormalities secondary to hearing loss. Referral to a developmental pediatrician should be considered given that many children with SNHL may also have developmental delay.¹⁰

A list of lab tests with corresponding indications and diagnoses is provided in Table 6, which may assist in the evaluation of pediatric bilateral SNHL.²² However, laboratory tests should not be ordered indiscriminately, because the yield has been shown to be as low as 0% to 2%.^{22,65} These tests should be included as part of the comprehensive work up detailed above if the listed indications are met or if suggested by family history.

Finally, unilateral hearing loss can often progress into bilateral SNHL such as in cases of EVA or cCMV. In addition, auditory neuropathy can present as bilateral SNHL. Therefore, although not the focus of this review, the considerations of genetic testing, imaging, and CMV testing are still applicable in some of these cases.

4 | CONCLUSION

Children with bilateral SNHL should undergo a comprehensive medical evaluation to determine the underlying etiology and help guide treatment and counseling. History and physical examination can

provide clues, particularly with syndromic causes. If SNHL is diagnosed within the first 3 weeks of life, CMV testing should be performed to identify patients that may benefit from antiviral treatment. If SNHL is diagnosed after 3 weeks, testing can be done using DBS samples, if testing capability is available. Genetic testing is oftentimes successful in identifying causes of HL as a result of recent technological advances in testing and an ever-increasing number of identified genes and genetic mutations. Therefore, where available, genetic testing should be performed, ideally with NGS techniques. Ophthalmologic evaluation must be done on all children with SNHL. Imaging (HRCT and/or MRI) should be performed to assess for anatomic causes of hearing loss and to determine candidacy for cochlear implantation when indicated. Laboratory testing is indicated for certain etiologies, but should not be ordered indiscriminately since the yield overall is low.

CONFLICTS OF INTEREST

The authors declare no conflicts of interest.

ORCID

Suat Kılıç  <https://orcid.org/0000-0001-7903-2299>

Michael S. Cohen  <https://orcid.org/0000-0002-1877-8668>

Judith E. C. Lieu  <https://orcid.org/0000-0001-7933-5601>

Margaret Kenna  <https://orcid.org/0000-0003-0851-9272>

Samantha Anne  <https://orcid.org/0000-0002-5719-6206>

BIBLIOGRAPHY

1. Prosser JD, Cohen AP, Greinwald JH. Diagnostic evaluation of children with sensorineural hearing loss. *Otolaryngol Clin North Am.* 2015;48:975-982.
2. Lieu JEC, Kenna M, Anne S, Davidson L. Hearing loss in children: a review. *Jama.* 2020;324:2195-2205.
3. Halliday LF, Tuomainen O, Rosen S. Language development and impairment in children with mild to moderate sensorineural hearing loss. *J Speech Lang Hear Res.* 2017;60:1551-1567.
4. Moeller MP, Tomblin JB, Yoshinaga-Itano C, Connor CM, Jerger S. Current state of knowledge: language and literacy of children with hearing impairment. *Ear Hear.* 2007;28:740-753.
5. Tuller L, Delage H. Mild-to-moderate hearing loss and language impairment: how are they linked? *Lingua.* 2014;139:80-101.
6. Hearing TJColYear 2019 position statement: principles and guidelines for early hearing detection and intervention programs. *J Early Hear Detect Inter.* 2010;4:1-44.
7. United States. Individuals with Disabilities Education Improvement Act of 2004. [Bethesda, MD: ProQuest], 2011.
8. van Beeck Calkoen EA, Engel MSD, van de Kamp JM, et al. The etiological evaluation of sensorineural hearing loss in children. *Eur J Pediatr.* 2019;178:1195-1205.
9. Korver AM, Admiraal RJ, Kant SG, et al. Causes of permanent childhood hearing impairment. *Laryngoscope.* 2011;121:409-416.
10. Wiley S, Arjmand E, Jareenmeinzen D, Dixon M. Findings from multidisciplinary evaluation of children with permanent hearing loss. *Int J Pediatr Otorhinolaryngol.* 2011;75:1040-1044.
11. Cabanillas R, Diñeiro M, Cifuentes GA, et al. Comprehensive genomic diagnosis of non-syndromic and syndromic hereditary hearing loss in Spanish patients. *BMC Med Genomics.* 2018;11:58.
12. Janecke AR, Nekahm D, Löffler J, Hirst-Stadlmann A, Müller T, Utermann G. De novo mutation of the connexin 26 gene associated with dominant non-syndromic sensorineural hearing loss. *Hum Genet.* 2001;108:269-270.

13. Woolley AL, Oser AB, Lusk RP, Bahadori RS. Preoperative temporal bone computed tomography scan and its use in evaluating the pediatric cochlear implant candidate. *Laryngoscope*. 1997;107:1100-1106.
14. Jackson NM, Givens VB, Carpenter CC, et al. Cochlear trajectory in pediatric patients. *Laryngoscope*. 2015;125:961-965.
15. Walton J, Gibson WP, Sanli H, Prelog K. Predicting cochlear implant outcomes in children with auditory neuropathy. *Otol Neurotol*. 2008;29:302-309.
16. Pearce MS, Salotti JA, Little MP, et al. Radiation exposure from CT scans in childhood and subsequent risk of leukaemia and brain tumours: a retrospective cohort study. *Lancet*. 2012;380:499-505.
17. Young JY, Ryan ME, Young NM. Preoperative imaging of sensorineural hearing loss in pediatric candidates for cochlear implantation. *Radiographics*. 2014;34:E133-E149.
18. Anne S, Trosman S, Haffey T, Sindwani R, Geelan-Hansen K. Charges associated with imaging techniques in evaluation of pediatric hearing loss. *Int J Pediatr Otorhinolaryngol*. 2016;89:25-27.
19. Ronner E, Reid R, Basonbul RA, et al. Outcomes with non-sedated MRI for infants with sensorineural hearing loss. *Int J Pediatr Otorhinolaryngol*. 2019;127:109662.
20. Dean DC, Dirks H, O'Muirheartaigh J, et al. Pediatric neuroimaging using magnetic resonance imaging during non-sedated sleep. *Pediatr Radiol*. 2014;44:64-72.
21. Lim LH. A multidisciplinary approach to paediatric hearing loss: programme at the centre for hearing intervention and language development, National University Hospital, Singapore. *Ann Acad Med Singapore*. 2008;37:57-53.
22. Preciado DA, Lim LH, Cohen AP, et al. A diagnostic paradigm for childhood idiopathic sensorineural hearing loss. *Otolaryngol Head Neck Surg*. 2004;131:804-809.
23. Gürtler N, Gysin C, Schmid N, et al. Bilateral congenital deafness: what investigations should be performed? *Swiss Med Wkly*. 2017;147:w14416.
24. Liming BJ, Carter J, Cheng A, et al. International pediatric otolaryngology group (IPOG) consensus recommendations: hearing loss in the pediatric patient. *Int J Pediatr Otorhinolaryngol*. 2016;90:251-258.
25. Wentland CJ, Ronner EA, Basonbul RA, et al. Utilization of diagnostic testing for pediatric sensorineural hearing loss. *Int J Pediatr Otorhinolaryngol*. 2018;111:26-31.
26. McClay JE, Booth TN, Parry DA, Johnson R, Roland P. Evaluation of pediatric sensorineural hearing loss with magnetic resonance imaging. *Arch Otolaryngol Head Neck Surg*. 2008;134:945-952.
27. Lee KH, Larson DA, Shott G, et al. Audiologic and temporal bone imaging findings in patients with sensorineural hearing loss and GJB2 mutations. *Laryngoscope*. 2009;119:554-558.
28. Simons JP, Mandell DL, Arjmand EM. Computed tomography and magnetic resonance imaging in pediatric unilateral and asymmetric sensorineural hearing loss. *Arch Otolaryngol Head Neck Surg*. 2006;132:186-192.
29. Kochhar A, Angeli SI, Dave SP, Liu XZ. Imaging correlation of children with DFNB1 vs non-DFNB1 hearing loss. *Otolaryngol Head Neck Surg*. 2009;140:665-669.
30. Russo EE, Manolidis S, Morriss MC. Cochlear nerve size evaluation in children with sensorineural hearing loss by high-resolution magnetic resonance imaging. *Am J Otolaryngol*. 2006;27:166-172.
31. Lin JW, Chowdhury N, Mody A, et al. Comprehensive diagnostic battery for evaluating sensorineural hearing loss in children. *Otol Neurotol*. 2011;32:259-264.
32. Chen JX, Kachniarz B, Shin JJ. Diagnostic yield of computed tomography scan for pediatric hearing loss: a systematic review. *Otolaryngol Head Neck Surg*. 2014;151:718-739.
33. Kachniarz B, Chen JX, Gilani S, Shin JJ. Diagnostic yield of MRI for pediatric hearing loss: a systematic review. *Otolaryngol Head Neck Surg*. 2015;152:5-22.
34. Buchman CA, Roush PA, Teagle HF, Brown CJ, Zdanski CJ, Grose JH. Auditory neuropathy characteristics in children with cochlear nerve deficiency. *Ear Hear*. 2006;27:399-408.
35. Smith RJ, Bale JF Jr, White KR. Sensorineural hearing loss in children. *The Lancet*. 2005;365:879-890.
36. van Beeck Calkoen EA, Merkus P, Goverts ST, et al. Evaluation of the outcome of CT and MR imaging in pediatric patients with bilateral sensorineural hearing loss. *Int J Pediatr Otorhinolaryngol*. 2018;108:180-185.
37. Mehta D, Noon SE, Schwartz E, et al. Outcomes of evaluation and testing of 660 individuals with hearing loss in a pediatric genetics of hearing loss clinic. *Am J Med Genet A*. 2016;170:2523-2530.
38. Sloan-Heggen CM, Bierer AO, Shearer AE, et al. Comprehensive genetic testing in the clinical evaluation of 1119 patients with hearing loss. *Hum Genet*. 2016;135:441-450.
39. Qian ZJ, Chang KW, Ahmad IN, Tribble MS, Cheng AG. Use of diagnostic testing and intervention for sensorineural hearing loss in US children from 2008 to 2018. *JAMA Otolaryngol Head Neck Surg*. 2021;147:253-260.
40. Belcher R, Virgin F, Duis J, Wootten C. Genetic and non-genetic workup for pediatric congenital hearing loss. *Front Pediatr*. 2021;9:536730.
41. Alford RL, Arnos KS, Fox M, et al. American College of Medical Genetics and Genomics guideline for the clinical evaluation and etiologic diagnosis of hearing loss. *Genet Med*. 2014;16:347-355.
42. Diaz-Horta O, Duman D, Foster J II, et al. Whole-exome sequencing efficiently detects rare mutations in autosomal recessive non-syndromic hearing loss. *PLoS One*. 2012;7:e50628.
43. Likar T, Hasanhodžić M, Teran N, Maver A, Peterlin B, Writzl K. Diagnostic outcomes of exome sequencing in patients with syndromic or non-syndromic hearing loss. *PLoS One*. 2018;13:e0188578.
44. Wang J, Xiang J, Chen L, et al. Molecular diagnosis of non-syndromic hearing loss patients using a stepwise approach. *Sci Rep*. 2021;11:4036.
45. Li M, Mei L, He C, et al. Extrusion pump ABCC1 was first linked with nonsyndromic hearing loss in humans by stepwise genetic analysis. *Genet Med*. 2019;21:2744-2754.
46. Budde BS, Aly MA, Mohamed MR, et al. Comprehensive molecular analysis of 61 Egyptian families with hereditary nonsyndromic hearing loss. *Clin Genet*. 2020;98:32-42.
47. Guan Q, Balciuniene J, Cao K, et al. AUDIOME: a tiered exome sequencing-based comprehensive gene panel for the diagnosis of heterogeneous nonsyndromic sensorineural hearing loss. *Genet Med*. 2018;20:1600-1608.
48. D'Aguillo C, Bressler S, Yan D, et al. Genetic screening as an adjunct to universal newborn hearing screening: literature review and implications for non-congenital pre-lingual hearing loss. *Int J Audiol*. 2019;58:834-850.
49. Vona B, Hofrichter MAH, Schröder J, Shehata-Dieler W, Nanda I, Haaf T. Hereditary hearing loss SNP-microarray pilot study. *BMC Res Notes*. 2018;11:391.
50. Jayawardena ADL, Shearer AE, Smith RJH. Sensorineural hearing loss: a changing paradigm for its evaluation. *Otolaryngol Head Neck Surg*. 2015;153:843-850.
51. Oonk AMM, Ariens S, Kunst HPM, Admiraal RJC, Kremer H, Pennings RJE. Psychological impact of a genetic diagnosis on hearing impairment-an exploratory study. *Clin Otolaryngol*. 2018;43:47-54.
52. Liu CC, Anne S, Horn DL. Advances in Management of Pediatric Sensorineural Hearing Loss. *Otolaryngol Clin North Am*. 2019;52:847-861.
53. Chen MM, Oghalai JS. Diagnosis and management of congenital sensorineural hearing loss. *Curr Treat Options Pediatr*. 2016;2:256-265.
54. Grosse SD, Ross DS, Dollard SC. Congenital cytomegalovirus (CMV) infection as a cause of permanent bilateral hearing loss: a quantitative assessment. *J Clin Virol*. 2008;41:57-62.
55. Fowler KB, McCollister FP, Sabo DL, et al. A targeted approach for congenital cytomegalovirus screening within newborn hearing screening. *Pediatrics*. 2017;139.

56. Boppana SB, Ross SA, Shimamura M, et al. Saliva polymerase-chain-reaction assay for cytomegalovirus screening in newborns. *N Engl J Med*. 2011;364:2111-2118.
57. Dobbie AM. Evaluation and management of cytomegalovirus-associated congenital hearing loss. *Curr Opin Otolaryngol Head Neck Surg*. 2017;25:390-395.
58. Pellegrinelli L, Alberti L, Pariani E, Barbi M, Binda S. Diagnosing congenital cytomegalovirus infection: don't get rid of dried blood spots. *BMC Infect Dis*. 2020;20:217-217.
59. Wang L, Xu X, Zhang H, Qian J, Zhu J. Dried blood spots PCR assays to screen congenital cytomegalovirus infection: a meta-analysis. *Virology*. 2015;12:60-60.
60. Sharma A, Ruscetta MN, Chi DH. Ophthalmologic findings in children with sensorineural hearing loss. *Arch Otolaryngol Head Neck Surg*. 2009;135:119-123.
61. Batson S, Kelly K, Morrison D, Virgin F. Ophthalmologic abnormalities in children with congenital sensorineural hearing loss. *J Binocul Vis Ocul Motil*. 2019;69:126-130.
62. Johnston DR, Curry JM, Newborough B, et al. Ophthalmologic disorders in children with syndromic and nonsyndromic hearing loss. *Arch Otolaryngol Head Neck Surg*. 2010;136:277-280.
63. Falzon K, Guerin M, Fulcher T, Viani L. Ophthalmological screening of a paediatric cochlear implant population: a retrospective analysis and 12-year follow-up. *Eye (Lond)*. 2010;24:1031-1036.
64. Farzal Z, Walsh J, Ahmad FI, Roberts J, Ferns SJ, Zdanski CJ. Electrocardiogram screening in children with congenital sensorineural hearing loss: prevalence and follow-up of abnormalities. *Otolaryngol Head Neck Surg*. 2018;158:553-558.
65. Billings KR, Kenna MA. Causes of pediatric sensorineural hearing loss: yesterday and today. *Arch Otolaryngol Head Neck Surg*. 1999;125:517-521.
66. Lin PH, Hsu CJ, Lin YH, et al. Etiologic and audiologic characteristics of patients with pediatric-onset unilateral and asymmetric sensorineural hearing loss. *JAMA Otolaryngol Head Neck Surg*. 2017;143:912-919.
67. Huo L, Wang H. Characteristics and application of inner ear CT in 20 cases of sensorineural hearing loss in children. *Acta Otolaryngol*. 2012;132:1261-1265.
68. Drvis P, Ajduk J, Trotic R, Ries M, Kosovic V, Hat J. Etiology of deafness in children cochlear implant candidates in Croatia. *Coll Antropol*. 2008;32:1111-1113.
69. Coticchia JM, Gokhale A, Waltonen J, Sumer B. Characteristics of sensorineural hearing loss in children with inner ear anomalies. *Am J Otolaryngol*. 2006;27:33-38.
70. Preciado DA, Lawson L, Madden C, et al. Improved diagnostic effectiveness with a sequential diagnostic paradigm in idiopathic pediatric sensorineural hearing loss. *Otol Neurotol*. 2005;26:610-615.
71. McClay JE, Tandy R, Grundfast K, et al. Major and minor temporal bone abnormalities in children with and without congenital sensorineural hearing loss. *Arch Otolaryngol Head Neck Surg*. 2002;128:664-671.
72. Cross NC, Stephens SD, Francis M, Hourihan MD, Reardon W. Computed tomography evaluation of the inner ear as a diagnostic, counselling and management strategy in patients with congenital sensorineural hearing impairment. *Clin Otolaryngol Allied Sci*. 1999;24:235-238.
73. Denoyelle F, Marlin S, Weil D, et al. Clinical features of the prevalent form of childhood deafness, DFNB1, due to a connexin-26 gene defect: implications for genetic counselling. *The Lancet*. 1999;353:1298-1303.
74. Shusterman D, Handler SD, Marsh RR, Bilaniuk L, Tom LW. Usefulness of computed tomographic scan in the evaluation of sensorineural hearing loss in children. *Arch Otolaryngol Head Neck Surg*. 1992;118:501-503.
75. Moon PK, Qian JZ, McKenna E, et al. Cerebral Volume and Diffusion MRI Changes in Children with Sensorineural Hearing Loss. *NeuroImage Clin*. 2020;27:102328.
76. Hoey AW, Pai I, Driver S, Connor S, Wraige E, Jiang D. Management and outcomes of cochlear implantation in patients with congenital cytomegalovirus (cCMV)-related deafness. *Cochlear Implants Int*. 2017;18:216-225.
77. Santos S, Dominguez MJ, Cervera J, et al. Hearing loss and enlarged internal auditory canal in children. *Acta Otorrinolaringol Esp*. 2014;65:93-101.
78. Kimani JW, Buchman CA, Booker JK, et al. Sensorineural hearing loss in a pediatric population: association of congenital cytomegalovirus infection with intracranial abnormalities. *Arch Otolaryngol Head Neck Surg*. 2010;136:999-1004.
79. Miyasaka M, Nosaka S, Morimoto N, Taiji H, Masaki H. CT and MR imaging for pediatric cochlear implantation: emphasis on the relationship between the cochlear nerve canal and the cochlear nerve. *Pediatr Radiol*. 2010;40:1509-1516.
80. Lapointe A, Viamonte C, Morriss MC, Manolidis S. Central nervous system findings by magnetic resonance in children with profound sensorineural hearing loss. *Int J Pediatr Otorhinolaryngol*. 2006;70:863-868.
81. Judge PD, Jorgensen E, Lopez-Vazquez M, et al. Medical referral patterns and etiologies for children with mild-to-severe hearing loss. *Ear Hear*. 2019;40:1001-1008.
82. Isaiiah A, Lee D, Lenes-Voit F, et al. Clinical outcomes following cochlear implantation in children with inner ear anomalies. *Int J Pediatr Otorhinolaryngol*. 2017;93:1-6.
83. Jamshidi A, Glidewell C, Murnick J, Magge S, Reilly BK. Resolution of bilateral sensorineural hearing loss following ventriculoperitoneal shunt and literature review. *Int J Pediatr Otorhinolaryngol*. 2017;100:141-144.
84. Jallu AS, Jehangir M, Ul Hamid W, Pampori RA. Imaging evaluation of pediatric sensorineural hearing loss in potential candidates for Cochlear implantation. *Indian J Otolaryngol Head Neck Surg*. 2015;67:341-346.
85. Young NM, Kim FM, Ryan ME, Tournis E, Yaras S. Pediatric cochlear implantation of children with eighth nerve deficiency. *Int J Pediatr Otorhinolaryngol*. 2012;76:1442-1448.
86. Kong WJ, Cheng HM, Wang YJ, et al. Integrated profile to assess auditory nerve-auditory pathway integrity. *ORL J Otorhinolaryngol Relat Spec*. 2009;71:196-208.
87. Declau F, Boudewyns A, Van den Ende J, Peeters A, van den Heyning P. Etiologic and audiologic evaluations after universal neonatal hearing screening: analysis of 170 referred neonates. *Pediatrics*. 2008;121:1119-1126.
88. Komatsubara S, Haruta A, Nagano Y, Kodama T. Evaluation of cochlear nerve imaging in severe congenital sensorineural hearing loss. *ORL J Otorhinolaryngol Relat Spec*. 2007;69:198-202.
89. Mafong DD, Shin EJ, Lalwani AK. Use of laboratory evaluation and radiologic imaging in the diagnostic evaluation of children with sensorineural hearing loss. *Laryngoscope*. 2002;112:1-7.
90. Maxwell AP, Mason SM, O'Donoghue GM. Cochlear nerve aplasia: its importance in cochlear implantation. *Am J Otol*. 1999;20:335-337.
91. Naithani R, Chandra J, Mathur NN, Narayan S, Singh V. Hearing loss in chronic myeloid leukemia. *Pediatr Blood Cancer*. 2005;45:54-56.
92. Pecci A, Klersy C, Gresele P, et al. MYH9-related disease: a novel prognostic model to predict the clinical evolution of the disease based on genotype-phenotype correlations. *Hum Mutat*. 2014;35:236-247.
93. Hearn T. ALMS1 and Alström syndrome: a recessive form of metabolic, neurosensory and cardiac deficits. *J Mol Med (Berl)*. 2019;97:1-17.

94. Wémeau JL, Kopp P. Pendred syndrome. *Best Pract Res Clin Endocrinol Metab.* 2017;31:213-224.
95. Di Stadio A, Ralli M. Systemic lupus erythematosus and hearing disorders: literature review and meta-analysis of clinical and temporal bone findings. *J Int Med Res.* 2017;45:1470-1480.
96. Chau J, Atashband S, Chang E, Westerberg BD, Kozak FK. A systematic review of pediatric sensorineural hearing loss in congenital syphilis. *Int J Pediatr Otorhinolaryngol.* 2009;73:787-792.

How to cite this article: Kılıç S, Bouzaher MH, Cohen MS, Lieu JEC, Kenna M, Anne S. Comprehensive medical evaluation of pediatric bilateral sensorineural hearing loss. *Laryngoscope Investigative Otolaryngology.* 2021;6(5): 1196-1207. doi:10.1002/lio2.657