

Functional evaluation of the macular area in early glaucoma using microperimetry

Swati Phuljhele, Dewang Angmo, Lalit Aalok¹, Sandeep Parwal, Raj Vardhan Azad¹, Viney Gupta, Ramanjit Sihota

Purpose: To evaluate the central visual field by microperimetry (MP), in early glaucoma. **Methods:** Consecutive perimetrically experienced patients with a single nasal step or arcuate scotoma and 14 control eyes underwent MP. Retinal sensitivity on MP was mapped for frequency and depth of loss in the central 10° around fixation. **Results:** Twenty-one eyes had a single nasal step and 19 eyes with single arcuate scotoma on standard automated perimetry (SAP), with central 10° being normal on 30–2 and 10–2 perimetry. The average mean sensitivity on MP, in glaucomatous and control eyes was 11.8 ± 3.9 dB and 16.6 ± 1.2 dB, respectively, $P = 0.0004$. The average mean defect on MP-1, in glaucomatous and control eyes was -6.5 ± 2.0 dB and -3.0 ± 1.2 Db, respectively, $P = 0.05$. The corresponding retinal hemisphere showed significant defects in MP. In eyes with single nasal steps, an absolute scotoma was seen in 14–28% of eyes 8–10° off fixation, moderate to mild defects were seen in 10–52% eyes, and 10% eyes showed involvement up to 4° from the fixation. Eyes with arcuate scotoma had an absolute scotoma on MP in 95% of eyes, 6–10° from fixation, with extension up to 2° from fixation in 21%. In glaucomatous eyes, the normal hemisphere on SAP showed a mild defect on MP in 43%. Control eyes did not show any defect in SAP or MP. **Conclusion:** A significant loss of central retinal sensitivity is recorded on MP in early glaucomatous neuropathy as compared to SAP. Paramacular absolute defects were seen at 6–10° from fixation.

Key words: HVF 10–2, macular changes in early glaucoma, microperimetry, OCT, preperimetric glaucoma, retinal sensitivity

In a glaucomatous eye, the optic nerve head and retinal nerve fiber layer undergo structural and possibly functional changes, even before visual field defects are seen on standard automated perimetry (SAP).^[1–3] The high definition of optical coherence tomography (OCT) has become a useful tool to evaluate the morphological changes in optic nerve head and macula, well before any visual defects become apparent. However, given the fact that there is significant interindividual variability in anatomy and topography of the optic nerve head; it may be difficult to rely on OCT alone for the preperimetric diagnosis of glaucoma.^[4,5] Microperimetry (MP), generates sensitivity maps at closely placed loci, with morphological correlation to retinal landmarks. The test is reproducible and has shown low interexaminer variability.^[6] Comparative studies on MP and SAP have shown that there is a good quantitative correlation of the numerical data between the two perimeters in advanced cases of glaucoma.^[7–11] However, there are very limited studies on mild to moderate glaucoma.^[12]

Glaucomatous visual field loss is believed to occur mainly in Bjerrum's area, 10–20° away from fixation, with the central field being affected on SAP only in advanced cases. Thus, this study aimed to explore the involvement of the central 10° of the visual field by MP in mild to moderate glaucoma as compared to SAP.

Glaucoma Research Facility and Clinical Services, ¹Vitreoretinal Services, Dr Rajendra Prasad Centre for Ophthalmic Sciences, All India Institute of Medical Sciences, New Delhi, India

Correspondence to: Dr. Dewang Angmo, Glaucoma Research Facility and Clinical Services, Room No. -374, Third Floor, Dr. Rajendra Prasad Centre for Ophthalmic Sciences, All India Institute of Medical Sciences, New Delhi - 110 029, India. E-mail: dewang45@gmail.com

Received: 28-Mar-2020

Revision: 21-Jul-2020

Accepted: 07-Oct-2020

Published: 16-Mar-2021

Access this article online

Website:

www.ijo.in

DOI:

10.4103/ijo.IJO_1199_20

Quick Response Code:



Methods

This is a prospective, observational case-control study. The study was carried out as per the tenets of the Declaration of Helsinki and was approved by our institutional ethics committee. Informed consent was obtained from all individual participants included in the study.

Patient selection

Perimetrically experienced glaucomatous patients, seen consecutively at our glaucoma service over 6 months, were included in the study. All patients aged >40 years and diagnosed to have glaucoma based on intraocular pressure (IOP) >21 mmHg on at least three occasions, glaucomatous optic neuropathy, and corresponding visual field defects on SAP (Humphrey Field Analyzer [HFA] II, Swedish Interactive Testing Algorithm [SITA] standard 30–2 and 10–2 protocols, Carl Zeiss Meditec, Inc, Dublin, CA). Glaucomatous disc changes were defined as a vertical cup to disc ratio of > 0.7, asymmetry of >0.2 between the two eyes, neuroretinal rim changes consisting of pallor or localized notching, and presence of nerve fiber layer defects, in the absence of any other ocular or neurological pathology. Visual field defects met Anderson's criteria for a glaucomatous

This is an open access journal, and articles are distributed under the terms of the Creative Commons Attribution-NonCommercial-ShareAlike 4.0 License, which allows others to remix, tweak, and build upon the work non-commercially, as long as appropriate credit is given and the new creations are licensed under the identical terms.

For reprints contact: WKHLRPMedknow_reprints@wolterskluwer.com

Cite this article as: Phuljhele S, Angmo D, Aalok L, Parwal S, Azad RV, Gupta V, *et al.* Functional evaluation of the macular area in early glaucoma using microperimetry. Indian J Ophthalmol 2021;69:876-81.

field defect and were reproduced on at least two consecutive visits. Patients with reproducible glaucomatous visual field defects in the form of a single nasal step or arcuate scotoma in one hemisphere on SAP (mild to moderate glaucoma),^[13] normal opposite hemisphere, and normal 10–2 SAP were included in the study. A visual field on SAP was considered normal when none of the loci were depressed at <5% on the pattern deviation map. Age-matched subjects having no ocular or neurological pathology and normal SAP 30–2 and 10–2 were taken as controls. Exclusion criteria were patients with advanced glaucoma, macular pathology, high myopes (refractive error >±5.0 D spherical and ±3.0 D cylinder), any media opacity, and unreliable/uncooperative patients.

Microperimetry

All patients and controls underwent MP (MP-1, Nidek Technologies Srl, Vigonza-Italy). “Macular 20°, 10 dB automated pattern,” with 4–2 threshold strategy, recording retinal sensitivity at 76 points in the central 10° around fixation was used. The procedure was performed through a dilated pupil, to maintain constant imaging of the retina. The patient was asked to fix at the central cross used as a fixation target. Goldmann size III stimulus of 400 Asb, was projected for 200 ms, against a white background of 4 Asb. The test started with a stimulus of 10 dB and this was increased in steps of 4 dB, till the threshold was crossed, after which the stimulus was reduced by step sizes of 2 dB, to determine the exact retinal sensitivity. The maximum attenuation possible was 20 dB. Patients were asked to respond whenever the stimulus was seen, by pressing a switch similar to that present on the HFA. False-positive responses were monitored by a stimulus projected on the optic disc to ensure the reliability of the test. The results of MP were represented in 76 locations, distributed along 16 equidistant meridians passing through fixation –1, 2, 4, 6, 8, and 10° from fixation [Fig. 1].

For analysis and description, the color-coded map generated by the inbuilt software was used, in which an absolute defect, seen as red, which represented no response from the patient even at attenuation of 0 dB; a moderate defect was seen as orange, the response between 2–6 dB; and a mild defect seen as yellow, represented a response of 8–10 dB.

Outcome measure

The outcome measure was reduced retinal sensitivity on MP.

Statistical analysis

Purposive sampling of patients having a single early/moderate defect in one hemisphere was done, limited by the period of recruitment i.e., 6 months was done. Thereby recruiting a total of 40 glaucoma patients.

For the convenience of description and analysis, the MP thresholds of all eyes were transposed, to locations corresponding to that for a superior visual field defect of the right eye. Any response >10 dB was considered to be within normal limits. The depth, extent of the defects, and frequency of involvement of each locus concerning fixation were analyzed in only one eye per patient. The involvement of a particular locus with a visual field defect on SAP was calculated by including the total number of eyes showing depressed sensitivity at that locus, irrespective of the severity.

Data were recorded in Excel software (Microsoft Corp.) and were analyzed using Statistical Package for the Social Sciences (SPSS) software (version 21.0, SPSS, Inc.). Data were presented as the mean ± standard deviation (SD). The mean deviation on SAP (MDSAP), mean pattern standard deviation on SAP (PSDSAP), mean sensitivity on MP (MSMP), and

mean defect on MP (MDMP), as generated by the respective software, were noted and evaluated for any correlation. The Mann-Whitney U test was used to compare the parameters of glaucomatous and control eyes. Spearman’s correlation test was applied to find out the correlation between SAP and MP parameters. For all analyses, *P* value ≤0.05 was considered statistically significant.

Results

The MP printouts of 40 glaucoma patients who met the inclusion criteria and 14 control eyes seen over 6 months were analyzed. Twenty-one eyes had an isolated nasal step and 19 had a single arcuate scotoma on SAP. The mean age of glaucoma patients was 55.47 ± 13.60 years, and of controls 50.69 ± 10.32 years, *P* = 0.4.

All glaucomatous eyes showed a loss of retinal sensitivity on MP, in the retinal quadrant/hemisphere corresponding to visual field defects on SAP 30–2 [Fig. 1]. None of the glaucomatous eyes had a scotoma on the SITA standard 10–2 protocol. None of the control eyes showed ≤10 dB reduction in retinal sensitivity at any locus in the central 10° on MP. The mean sensitivity on MP (MSMP) of glaucomatous and control eyes was 11.8 ± 3.9 dB (6.3–17.4) and 16.6 ± 1.2 dB (15.1–18.9), respectively, *P* = 0.001 and mean deviation on microperimetry (MDMP) was -6.5 ± 2.0 dB (-12.1 to -2.2) and -3.0 ± 1.2 dB (-4.8 to -0.8), *P* = 0.05. The average MD on SAP was -8.7 ± 4.5 dB for glaucomatous eyes and -2.15 ± 2.01 dB in controls, Table 1. The MDSAP showed a positive correlation with both MDMP and MSMP with a correlation coefficient of 0.67 and 0.78, respectively.

Microperimetric abnormalities in eyes with an isolated nasal step on SAP

Twenty-one eyes of 21 patients had an isolated nasal step on SAP. The average MDSAP, MDMP, and MSMP in these patients were -5.4 ± 1.5 (-2 to -10), -5.74 ± 2.1 dB (-2 to -10.5) and 13.6 ± 2.2 dB (17.4 to 8.1), respectively.

Decreased retinal sensitivities were seen in the corresponding temporal retinal quadrant, Fig. 2 and Table 2.

In eyes with a nasal step, loci showing significantly depressed sensitivity existed on the 10° circle at 22.5° and 45° meridians. Other commonly affected points were those on the 10° circle, 67.5°-157.5° meridians, in 48–76% of eyes, and on the 8° circle from 22.5° and 45° meridians, in 66% and 71% of eyes. Besides, 40% of eyes in the 6° circle showed subnormal retinal sensitivity at the 22.5° to 45° meridian.

Absolute defects on MP correlated with the meridional location of defects seen on SAP on 30–2 protocol, while all the moderate and mild defects on MP were in areas shown to be within normal limits on SAP on both 30–2 and 10–2 protocol.

Microperimetry features of eyes with an arcuate defect on SAP

A total of 19 patients had an arcuate defect in one hemisphere, with the other hemisphere being normal on SAP 30–2 and 10–2.

The mean MD SAP, MDMP, and MSMP in patients with an arcuate defect were -12.02 ± 3.4 (-5.3 to -19.4), -7.3 ± 1.6 (-5.3 to -12.1), 9.36 ± 2.1 (13.7 to 6.3) dB, respectively. The frequency of involvement of each locus at various depths of scotoma is described in Table 2 and depicted in Fig. 3. Eyes with an arcuate scotoma, showed an absolute scotoma on MP, extending from 10° to 2° from fixation in 5–21% of eyes adjacent to the temporal horizontal meridian, (0–45°). Moderate and mild defects were




Figure 1: (a) Distribution of loci tested in the “Central macula 20°” protocol on microperimetry (MP-1) used in our study. (b and c) SAP and MP-1 printouts of a patient with a single arcuate defect in the right eye. (b) Superior arcuate scotoma on SAP. (c) Corresponding retinal sensitivity loss in the inferior hemisphere of the retina on MP-1 (seen in Red). Also, mild to moderate defects (yellow-orange) detected on MP-1 in the opposite hemisphere, which was normal looking on SAP

Table 1: SAP and Microperimetry parameters in glaucoma and control eyes

	SAP		MP	
	MD (dB)	PSD (dB)	MSMP (dB)	MDMP (dB)
Control subjects	-2.15 ± 2.01	2.15 ± 0.89	16.6 ± 1.2	-3.0 ± 1.2
Glaucomatous eyes	-8.7 ± 4.5	8.9 ± 4.4	11.8 ± 3.9	-6.5 ± 2.0
P-value*	P < 0.001	P < 0.001	P = 0.001	P = 0.05

SAP - Standard automated perimetry, MP - Microperimetry, MD - Mean deviation, PSD - Pattern standard deviation, MSMP - mean sensitivity on MP and MDMP - mean defect on MP-1. *Mann-Whitney U test

Table 2: Depth and locations of defects, on microperimetry, in eyes with nasal step, arcuate defect, and in the corresponding opposite hemisphere

Location of defect	Degree of defect	Degree from fixation	Meridia involved	Percentage of eyes involved
Nasal Step	Absolute (Red)	8° to 10°	22.5° to 67.5°	14- 28%
	Moderate (Orange)	8° to 10°	0° to 180°	10- 28%
		6° to 4°	0° to 180°	05- 10%
	Mild (Yellow)	8 to 10°	0° to 180°	14- 52%
		6° to 4°	0° to 180°	05- 28%
		2°	0° to 180°	05- 10%
Arcuate Defect	Absolute (Red)	10° to 8°	0° to 135°	21- 95%
		6° to 4°	22.5° to 112.5°	16- 95%
		10° to 8°	22.5° to 135°	05- 32%
	Moderate (Orange)	6° to 4°	0° to 135°	05- 32%
		2°	45°	16%
		10° to 8°	135° to 180°	21- 42%
Opposite hemisphere	Absolute (Red)	6° to 4°	90° to 135°	16- 37%
		2°	0° to 180°	05- 21%
		10°	45° to 135°	05- 13%
	Moderate (Orange)	10°- 8°	45° to 135°	08- 10%
		6°- 4°	45° to 135°	0-5%
		10°- 8°	45° to 135°	20- 42%
Mild (Yellow)	6°- 2°	45° to 135°	18- 42%	
	2°	45° to 135°	13- 23%	

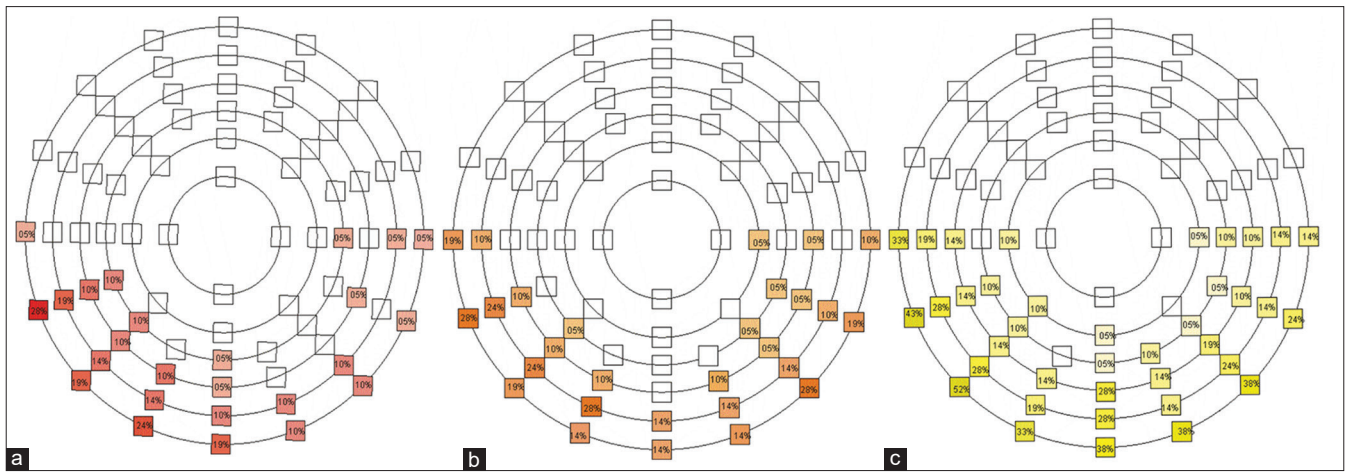


Figure 2: Percentage of eyes with a single nasal step on SAP ($n = 21$), showing a significant loss of retinal sensitivity on MP-1. (a) absolute defect. (b) moderate defect. (c) mild defect

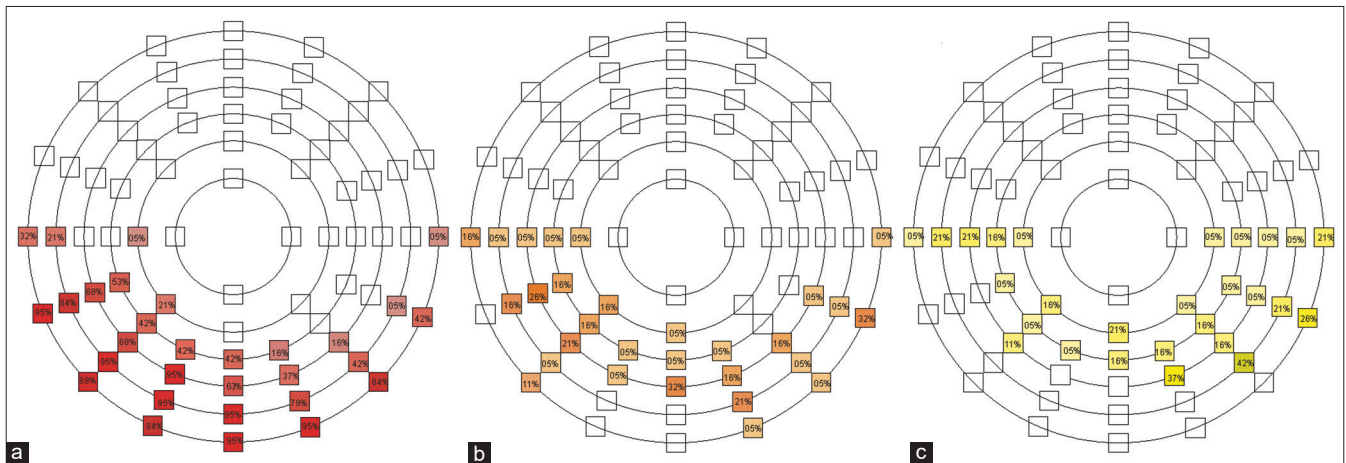


Figure 3: Percentage of eyes with a single arcuate scotoma on SAP ($n = 19$), showing a significant loss of retinal sensitivity on MP-1. (a) absolute defect. (b) moderate defect. (c) mild defect

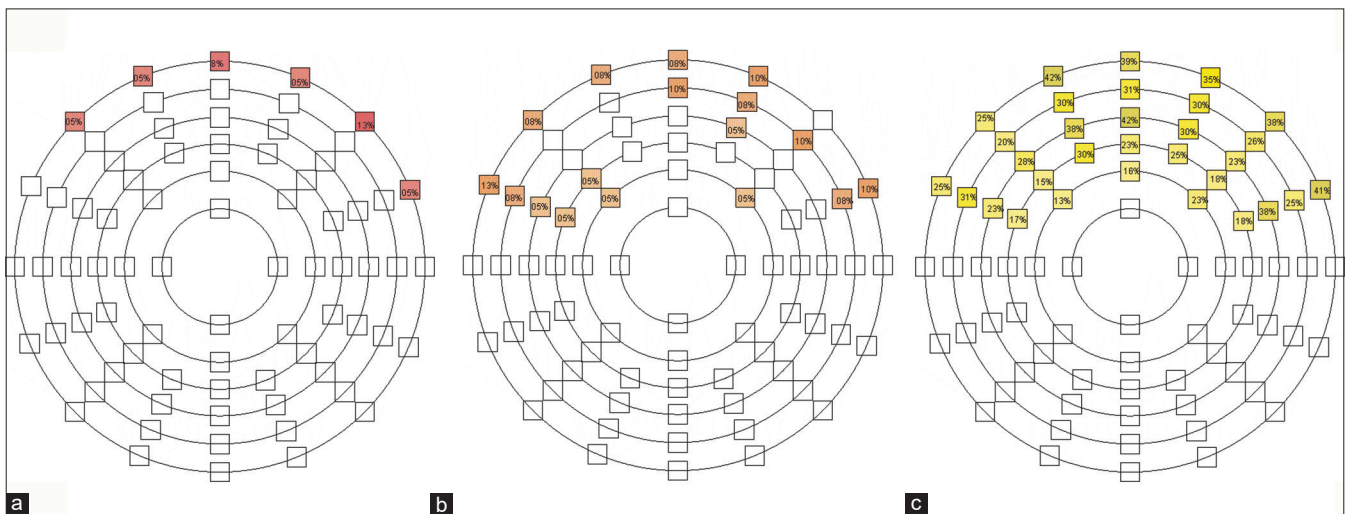


Figure 4: Percentage of eyes having opposite normal hemisphere on SAP ($n = 40$), but showing a significant loss of retinal sensitivity on MP-1. (a) absolute defect. (b) moderate defect. (c) mild defect

seen in the entire hemisphere, involving all the loci that did not have an absolute defect, up to and involving the central 4° as well. A reduction of sensitivity was seen in 5–21% of eyes at 180°, i.e., along the horizontal meridian corresponding to the papillomacular bundle.

Absolute defects on MP were along the meridional location of defects seen on SAP 30–2 protocol, while all the moderate and mild defects on MP were more central.

Microperimetry features of the hemisphere, with no defects on SAP

The uninvolved hemisphere on SAP 30–2 and 10–2, in the 40 eyes showing either a nasal step or arcuate defect in one hemisphere, showed mild to absolute defects as described in Table 2, [Fig. 4]. Although an absolute defect was seen only in the 10° circle, mild defects extended up to 2° from fixation in 13–23% of eyes, involving most of the hemisphere.

Discussion

The role of MP in the evaluation of glaucoma is yet to be established. Few studies have been done in early and several on advanced glaucoma,^[9-12,14] looking predominantly at the quantitative comparison between MPs and SAP.^[7,9-11,14] Our study was designed to particularly evaluate microperimetric changes in early cases of glaucoma, where the defect is limited to one hemisphere only and has not involved the central 10° on SAP (as evaluated by 10–2 protocol). Retinal sensitivity close to the fovea, and along the papillo-macular bundle, was specifically studied.

This study exclusively analyzed early/moderate visual field defects in one hemisphere unlike others of preperimetric glaucoma which are difficult to standardize and have mixed samples of visual field defects.^[15,16] Moreover, this has important clinical application for diagnosis of early glaucoma and early diagnosis of progression. Therefore, allowing early therapeutic intervention to decrease ocular morbidity.

Our study found a significant difference in MDMP and MSMP between glaucomatous eyes and healthy controls, similar to Oztürk *et al.*^[10] but contradictory to Klamann *et al.* where they did not find any significant difference in macular sensitivity between early glaucomatous eyes and normal healthy control eyes.^[15]

Kita *et al.* found that circumpapillary (cp) MP sensitivity and cp retinal nerve fiber layer (cpRNFL) thickness showed similar diagnostic power. The structure-function relationship was strong for the superotemporal and inferotemporal circumpapillary area.^[17] Rao *et al.* showed that visual sensitivity measurements of both SAP and MP demonstrated a similar relationship with the ganglion cell-inner plexiform layer (GCIPL) measurements of spectral domain optical coherence tomography (SD-OCT) at the macula in glaucoma.^[18] Therefore, MP can be a simple and more reliable method to determine the retinal sensitivity at specific loci, and also can detect early progression which was otherwise not seen on SAP.

In this study, patients with a nasal step on SAP had significant absolute or moderate microperimetric defects in the corresponding temporal retinal quadrants, 8–10° off fixation. An additional mild defect was present in 10–52% of eyes, extending till 4° from fixation involving almost entire hemisphere and mild defects involving almost the entire hemisphere. Therefore, MP identified abnormal retinal sensitivities over a much wider area in all the eyes as compared to SAP. Orzalesi *et al.* found a deep or mild scotoma on MP in 100% of eyes with focal RNFL defects, as compared to a significant defect seen in only 56% of eyes on SAP.^[19]

MP performed in eyes having a single arcuate scotoma on SAP, showed an absolute scotoma in loci along the central 6–10° arching above fixation. Besides, there appeared to be either a mild or moderate defect in the entire hemisphere, with a horizontal extension until 2° from fixation temporally as well. While SAP in such eyes showed an arcuate defect extending only between 10–25° from fixation.

Interestingly, this study also noted some involvement of the 180° meridian, i.e., the papillomacular bundle suggestive of the early involvement of these fibers in some eyes. The preperimetric involvement of macular fibers is observed in the form of macular nerve fiber thinning as reported on OCT and seems to have a good correlation with MP.^[14,20-22] Disante *et al.* studied the RNFL, ganglion cell layer (GCL), and its relationship with SAP. They concluded that there was a moderate correlation between the functional and structural parameters.^[23]

A global decrease in retinal sensitivity on MP was seen in the hemisphere that was normal on SAP 30–2 and 10–2, with certain loci being more depressed than the others suggesting some sub-perimetric damage. Lima *et al.* noted 21% of the normal SAP quadrants had a corresponding, abnormal performance on MP.^[11] Orzalesi *et al.* found a deep or mild microperimetric scotoma in 44% of eyes having focal RNFL defects, in areas that were normal on SAP.^[19]

Lima *et al.* found a strong correlation between 10–2 SAP and MP in each quadrant but also found that 75% of areas with abnormal visual sensitivity on MP and normal sensitivity with SAP showed a corresponding reduction in macular thickness on time-domain OCT.^[11] We found a moderate correlation between MSMP and PSDSAP, probably because the global damage identified on MP is not seen on SAP. Different patterns of involvement of the macula in early to moderate cases of glaucoma have been reported.^[14,24] Yusuf *et al.* showed that MP detects reduced retinal sensitivity close to fixation and a normal SAP in fellow eyes of glaucoma has reduced retinal sensitivity on MP.^[25]

Bogunovic *et al.* determined the visual threshold for each location of the Humphery 24–2 visual field by using nine fields of SD-OCT structural information.^[26] Kawaguchi *et al.* studied preperimetric glaucoma patients ($n = 15$), by hemispheric asymmetry testing and concluded macular symmetry testing on OCT values were significantly correlated with perimetric sensitivity and perimetric sensitivity asymmetry on 10–2 HFA (SAP).^[16] Thereby, highlighting the importance of macular changes in the early detection of glaucoma. Besides, OCT detected focal thinning of RNFL in the fellow eye of most patients with unilateral focal ischemia.^[26] This is similar to our study where the hemisphere normal on SAP showed reduced retinal sensitivity on MP.

A limitation of the present study was its small sample size, because we only targeted eyes with early glaucomatous damage, involving a single hemisphere. The cut-off sensitivity for a normal response used in this study is well below the normal values reported in the literature, the maximal threshold level of 20 dB on MP and is equivalent to 25 dB on SAP.^[27] This was done to obviate any errors due to variability in recording and to pick up only those defects that deviate significantly from normal. The extent and depth of scotoma could have been underestimated on SAP since a Bayesian strategy is used in SITA standard while the microperimetric examination used a full-threshold algorithm. MP uses a mesopic background (1.27 cd/m²) as opposed to the fully photopic in SAP (10 cd/m²) and thus may be more sensitive in detecting the defect, especially in diseases involving

photoreceptors.^[28,29] In our study, all patients underwent SAP first, then were dilated, and thereafter MP was done. Pupil dilation may affect the performance or sensitivity measured in SAP. But for MP, it is not shown to have produced any significant effect either on threshold sensitivity or on fixation stability.^[30]

Early perimetric changes on SAP are small, peripheral, and fluctuating. These need to be reproduced several times, before a diagnosis of glaucoma can be reached. MP, with its ability to identify more extensive involvement, in the presence of a barely detected nasal step on SAP, together with its lower variability, may allow identification of eyes with early glaucomatous damage, and earlier definitive diagnosis of glaucoma. MP could, therefore, be used in the early detection of glaucoma when equivocal/fluctuating defects are seen on SAP and thereby also can detect early progression. Oztürk and Migliorboth felt that MP did not offer any specific advantage over SAP, however, they evaluated the mean quadrantic sensitivities in a small number of visual field defects rather than an analysis of individual loci.^[8,10]

Conclusion

To conclude, this study demonstrates microperimetric abnormalities in the central 10° of the visual field, even up to 2–4° from fixation, in early glaucomatous optic neuropathy. Areas normal on visual field testing with SAP have decreased illumination sensitivity on retinal sensitivity map evaluated with MP. MP, therefore, can be used in the diagnosis of early glaucoma, in conjunction with, or even before SAP.

Financial support and sponsorship

Nil.

Conflicts of interest

There are no conflicts of interest.

References

- Sommer A, Katz J, Quigley HA, Miller NR, Robin AL, Richter RC, *et al.* Clinically detectable nerve fiber atrophy precedes the onset of glaucomatous field loss. *Arch Ophthalmol* 1991;109:77-83.
- Kerrigan-Baumrind LA, Quigley HA, Pease ME, Kerrigan DF, Mitchell RS. Number of ganglion cells in glaucoma eyes compared with threshold visual field tests in the same persons. *Invest Ophthalmol Vis Sci* 2000;41:741-8.
- Reyes RD, Tomita G, Kitazawa Y. Retina nerve fiber layer thickness within the area of apparently normal visual field in normal tension glaucoma with hemifield defect. *J Glaucoma* 1998;7:329-35.
- Guedes V, Schuhman JS, Hertzmark E, Wollstein G, Correnti A, Mancini R, *et al.* Optical coherence tomography measurement of macular and nerve fiber layer thickness in normal and glaucomatous human eyes. *Ophthalmology* 2003;110:177-89.
- Lisboa R, Leite MT, Zangwill LM, Tafreshi A, Weinreb RN, Medeiros FA. Diagnosing preperimetric glaucoma with spectral domain optical coherence tomography. *Ophthalmology* 2012;119:2261-9.
- Weingessel B, Sacu S, Vécsei-Marlovits PV, Weingessel A, Weingessel A, Richter-Mueksch S, *et al.* Interexaminer and intraexaminer reliability of the microperimeter MP. *Eye (Lond)* 2009;23:1052-8.
- Okada K, Watanabe W, Koike I, Tsumamoto Y, Mishima HK. Alternative method of evaluating visual field deterioration in very advanced glaucomatous eye by microperimetry. *Jpn J Ophthalmol* 2003;47:178-81.
- Miglior S. Microperimetry and glaucoma. *Acta Ophthalmol Scand Suppl* 2002;236:19.
- Rensch F, Jonas JB. Direct microperimetry of alpha zone and beta zone parapapillary atrophy. *Br J Ophthalmol* 2008;92:1617-9.
- Oztürk F, Yavas GF, Küsbeci T, Ermiş SS. A comparison among Humphrey field analyzer, Microperimetry, and Heidelberg retina tomograph in the evaluation of macula in primary open angle glaucoma. *J Glaucoma* 2008;17:118-21.
- Lima VC, Prata TS, De Moraes CG, Kim J, Kim J, Seiple W, *et al.* A comparison between microperimetry and standard achromatic perimetry of the central visual field in eyes with glaucomatous paracentral visual-field defects. *Br J Ophthalmol* 2010;94:64-7.
- Rao HL, Januwada M, Hussain RSM, Pillutla LN, Begum VU, Chaitanya A, *et al.* Comparing the structure-function relationship at the macula with standard automated perimetry and microperimetry. *Invest Ophthalmol Vis Sci* 2015;56:8063-8.
- Sihota R, Gupta V, Tuli D, Sharma A, Sony P, Srinivasan G. Classifying patterns of localized glaucomatous visual field defects on automated perimetry. *J Glaucoma* 2007;16:146-52.
- Kulkarni SV, Coupland SG, Stitt DM, Hamilton J, Brownstein JJ, Damji KF. Efficacy of SLO-microperimetry and Humphrey for evaluating macular sensitivity changes in advanced glaucoma. *Can J Ophthalmol* 2013;48:406-12.
- Klamann MK, Grünert A, Maier AK, Gonnermann J, Jousen AM, Huber KK. Comparison of functional and morphological diagnostics in glaucoma patients and healthy subjects. *Ophthalmic Res* 2013;49:192-8.
- Kawaguchi C, Nakatani Y, Ohkubo S, Higashide T, Kawaguchi I, Sugiyama K. Structural and functional assessment by hemispheric asymmetry testing of the macular region in preperimetric glaucoma. *Jpn J Ophthalmol* 2014;58:197-204.
- Kita Y, Holló G, Murai A, Kita R, Saito T, Hirakata A. Circumpapillary structure-function relationships with microperimetry and spectral domain optical coherence tomography in glaucoma: A pilot study. *Clin Ophthalmol* 2018;12:2535-544.
- Rao HL, Hussain RS, Januwada M, Pillutla LN, Begum VU, Chaitanya A, *et al.* Structural and functional assessment of macula to diagnose glaucoma. *Eye (Lond)* 2017;31:593-600.
- Orzalesi N, Miglior S, Lonati C, Rosetti L. Microperimetry of localized retinal nerve fiber layer defects. *Vision Res* 1998;38:763-71.
- Sihota R, Naithani P, Sony P, Gupta V. Temporal retinal thickness in eyes with glaucomatous visual field defects using optical coherence tomography. *J Glaucoma* 2015;24:257-61.
- Sato S, Hirroka K, Baba T, Tenkumo K, Nitta E, Shiraga F. Correlation between the ganglion cell inner plexiform layer thickness measured with cirrus HD-OCT and macular visual field sensitivity measured with microperimetry. *Invest Ophthalmol Vis Sci* 2013;54:3046-51.
- Verma A, Rani PK, Raman R, Pal SS, Laxmi G, Gupta M, *et al.* Is neuronal dysfunction an early sign of diabetic retinopathy? Microperimetry and spectral domain optical coherence tomography (SD-OCT) study in individuals with diabetes, but no diabetic retinopathy. *Eye* 2009;23:1824-30.
- Disante P, Lombardo S, Verticchio Vercellin AC, Raimondi M, Rolando M, Tinelli C, *et al.* Structure/functional relationship and retinal ganglion cell counts to discriminate glaucomatous damages. *BMC Ophthalmol* 2015;15:185.
- Huang P, Shi Y, Wang X, Zhang SS-M, Zhang C. Use of microperimetry to compare macular light sensitivity in eyes with open-angle and angle-closure glaucoma. *Jpn J Ophthalmol* 2012;56:138-44.
- Bogunović H, Kwon YH, Rashid A, Lee K, Critser DB, Garvin MK, *et al.* Relationships of retinal structure and Humphrey 24-2 visual field thresholds in patients with glaucoma. *Invest Ophthalmol Vis Sci* 2014;56:259-71.
- Yusuf IH, Jolly JK, Ratnarajan G, Salmon JF. Microperimetry and OCT imaging in the fellow eye of patients with unilateral focal ischaemic glaucoma. *Eye (Lond)* 2018;32:1372-9.
- Han RC, Jolly JK, Xue K, MacLaren RE. Effects of pupil dilation on MAIA microperimetry. *Clin Exp Ophthalmol* 2017;45:489-95.
- Greenstein VC, Hood DC. The effects of light adaptation on L-cone sensitivity in retinal disease. *Clin Vis Sci* 1992;7:1-7.
- Acton JH, Bartlett NS, Greenstein VC. Comparing the Nidek MP-1 and Humphrey field analyzer in normal subjects. *Optom Vis Sci* 2011;88:1288-97.
- Acton JH, Smith RT, Greenberg JP, Greenstein VC. Comparison between MP-1 and Humphrey visual field defects in glaucoma and retinitis pigmentosa. *Optom Vis Sci* 2012;89:1050-8.