

Oncology

Development of a Large Pelvic Sperm Granuloma Status Post Radical Prostatectomy: A Case Report



Christopher Miller*, R. Caleb Kovell

University of Pennsylvania, Division of Urology, Perelman Ctr, West Pav, 3rd Flr, 3400 Civic Center Blvd, Philadelphia, PA 19104, USA

ARTICLE INFO

Article history:

Received 9 July 2017

Accepted 24 July 2017

Available online 17 August 2017

Keywords:

Prostatectomy

Sperm granuloma

Pelvic mass

ABSTRACT

A 72 year old male developed severe obstructive voiding symptoms status post radical prostatectomy. Imaging showed a large pelvic mass causing mass effect on the bladder that ultimately proved to be a sperm granuloma. To the best of our knowledge the development of sperm granuloma post-prostatectomy has not been previously reported.

© 2017 The Authors. Published by Elsevier Inc. This is an open access article under the CC BY-NC-ND license (<http://creativecommons.org/licenses/by-nc-nd/4.0/>).

Case report

A 72 year old male with a history of prostate cancer status post radical prostatectomy in the distant past and subsequent biochemical recurrence status post adjuvant radiation therapy presented to clinic after being lost to follow up for several years with complaints of gross hematuria and progressively worsening lower urinary tract symptoms which included frequency, hesitancy, feeling of incomplete emptying, straining to void and decreased force of stream. His post void residual was elevated at 146 mL. His most recent PSA remains low, but detectable at 0.60 ng/mL. He had similar symptoms four years ago and was ultimately diagnosed with a bladder neck contracture. This was treated with a four quadrant transurethral incision of his bladder neck without known recurrence. Additional past medical history includes hypertension and hyperlipidemia.

A CT Urogram was ordered for his gross hematuria evaluation. This showed a 1.4 cm bladder calculus raising concern for return of his bladder neck contracture. Additionally, a 3.1 × 2.0 cm left sided pelvic soft tissue mass in the prostatic fossa causing mass effect on the bladder and displacement of the distal left ureter was identified. Given the patient's history, there was concern for recurrent malignancy. A representative image is seen in Fig. 1.

Cystoscopic evaluation revealed a fibrotic, but open, bladder neck. His bladder stone was identified and removed. An indentation from external mass effect was seen in the left portion of the bladder near the trigone, but there were no erythematous or papillary

mucosal lesions within the bladder. Post-operatively the patient was sent for a CT-guided biopsy of his pelvic mass. Pathology and cytopathology showed numerous sperm, macrophages and fibrous tissue which was consistent with a sperm granuloma. No malignancy was identified. A representative image from his cytopathology slides is shown in Fig. 2.

He was followed up 3 months later at which time he was reimaged with a pelvic ultrasound. This showed the mass along the left posterior aspect of the urinary bladder and contiguous with bladder wall now measuring 1.8 × 1.9 cm. This was thought to be very similar in size when accounting for differences in imaging techniques. He is now without any urinary complaints after removal of his bladder stone. He specifically denies dysuria,

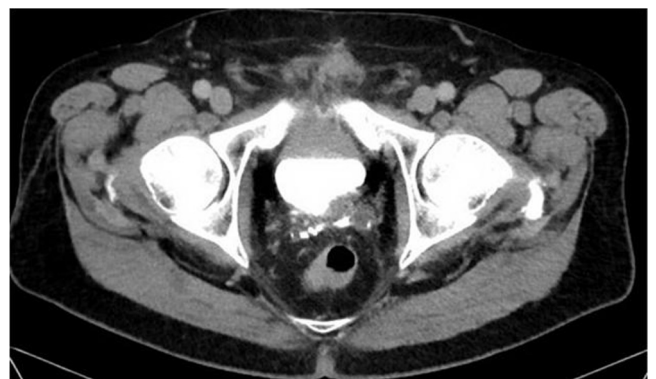

Fig. 1. A 3.1 × 2.0 cm left pelvic mass concerning for malignancy is seen compressing the bladder and displacing the left distal ureter anteriorly.

* Corresponding author.

E-mail address: Christopher.Miller3@uphs.upenn.edu (C. Miller).

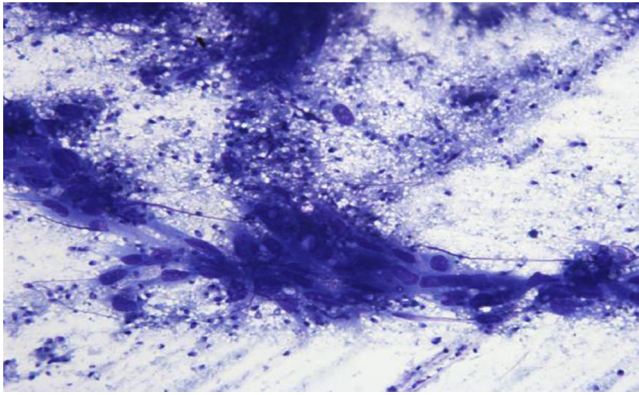


Fig. 2. Representative cytopathology slide showing presence of sperm.

frequency, incomplete emptying and difficulty with urination. His hematuria has also resolved. He is being followed closely for his persistently elevated PSA.

Discussion

Sperm granulomas are inflammatory lesions located outside of the testicle.¹ They are thought to represent a chronic immune response to extravasated sperm caused by trauma, surgery or infection.¹ After disruption of the blood-epididymal barrier, the immune system reacts to the perceived foreign body by walling off the threat with macrophages, neutrophils and connective tissue.² In practice these masses are most frequently seen after vasectomy where they occur in 28% of the time.³ In this setting there is a theoretical possibility of increase success with vasectomy reversal since the sperm granuloma may serve as a pop off valve that allows less pressure in the seminiferous tubules.³

Based on their known cause and prevalence after vasectomy, it is logical that sperm granulomas may occur in the pelvis after radical prostatectomy as the vas deferens is also cut in this procedure. On review of the literature, we were not able to identify a previously described case of sperm granuloma formation after radical prostatectomy. This may be because phenomena would not be expected to be clinically relevant unless the sperm granuloma reached a size large enough to cause symptoms, which would be quite rare. That said, as many men have had post-operative imaging after prostatectomy over years and development of a new pelvic mass would raise suspicion for malignancy, it is somewhat surprising that a pelvic sperm granuloma has not been identified to this point. This leads us to believe that this entity must occur in the extraperitoneal space at a much lower rate than in the scrotum. We would also postulate that sperm granuloma may be even less common after robotic prostatectomy due to the intra-abdominal nature of the procedure.

Conclusion

Pelvic sperm granuloma can develop after radical prostatectomy at the site of the transected vas deferens end. The rate of formation and clinical significance of this entity is unknown, but it should be considered in the differential for a recurrent pelvic mass after radical prostatectomy.

Conflicts of interest

Neither author has funding or conflicts of interest to report.

References

1. Oh C, Nisenbaum HL, Langer J, et al. Sonographic demonstration, including color Doppler imaging, of recurrent sperm granuloma. *J Ultrasound Med.* 2000;19, 333.
2. Gregory M, Cry DC. The blood-epididymis barrier and inflammation. *Spermatogenesis.* 2014;4. e979619.
3. Boorjian S, Lipkin M, Goldstein M. The impact of obstructive interval and sperm granuloma on outcome of vasectomy reversal. *J Urol.* 2004;171, 304.