

CASE REPORT

Open Access



# Coin-shaped corneal endothelial scar in herpes zoster ophthalmicus: a case report

Seung Hyeun Lee, Yeoun Sook Chun and Kyoung Woo Kim\*

## Abstract

**Background:** Herpes zoster ophthalmicus includes a wide spectrum of lesions at the ocular surface, including epithelial, stromal, endothelial keratitis, and uveitis. Thus far, the occurrence of corneal endothelial disorder in herpes zoster ophthalmicus and the causative virus have not been confirmed, and the differential diagnosis and establishment of therapeutic strategies are challenging. Corneal endothelial coin-shaped lesions are well known to occur in cytomegalovirus-related corneal endotheliitis but have not been reported in patients with herpes zoster ophthalmicus.

**Case presentation:** A 39-year-old Asian female was referred to our ophthalmology department with recurrent anterior uveitis accompanied by coin-shaped corneal endothelial scar-like lesions that appeared after right facial herpes zoster. Diffuse corneal stromal haziness was mostly limited in the anterior stroma. The coin-shaped corneal endothelial lesions were separate from stromal lesions and showed a high-reflective scar-like line in sections of anterior segment optical coherence tomography. Anterior uveitis recurred each time she discontinued oral antiviral drug treatment for 12 months after the first event, but was remitted by the maintenance medications of combined topical ganciclovir gel with oral valaciclovir, at a dose lower than the usual adult dose, for acute or recurrent zoster-associated anterior uveitis. Corneal endothelial function remained normal and corneal endothelial and stromal lesions were unchanged throughout the treatment and follow-up period.

**Conclusions:** In patients with a history of facial herpes zoster with coin-shaped corneal endothelial scar accompanying recurrent anterior uveitis, suspicion for active varicella-zoster virus is warranted, and prolonged intake of oral antiviral agents is required despite varicella-zoster virus DNA not being detected in aqueous humor.

**Keywords:** Anterior uveitis, Coin-shaped corneal endothelial scar, Facial herpes zoster, Herpes zoster ophthalmicus, Herpes zoster virus, Recurrence

## Background

Herpes zoster ophthalmicus (HZO) is a disease of reactivation and repopulation of varicella-zoster virus (VZV) throughout the ophthalmic branch (V1) from the trigeminal nerve. Once VZV invades the nasociliary nerve, in particular, various eye tissues such as conjunctiva, cornea, sclera, iris, choroid, optic nerve, and retina are affected and become inflamed [1]. Corneal

complications occur in about 65–75% of HZO, and in order of the frequency they include punctate epithelial keratitis, pseudodendritic keratitis, anterior stromal keratitis, keratouveitis, neurotrophic keratitis, and disciform stromal keratitis [2, 3]. Although most of these corneal complications show a transient course, limited cases may progress to a chronic form, such as neovascularized lipid keratopathy exclusively in nummular anterior stromal keratitis and disciform stromal keratitis [1].

We first present a case of coin-shaped corneal endothelial scar in HZO that mimicked cytomegalovirus (CMV)-induced coin-shaped corneal endotheliitis and was

\*Correspondence: [kkanssa@cau.ac.kr](mailto:kkanssa@cau.ac.kr)

Department of Ophthalmology, Chung-Ang University Hospital, Chung-Ang University College of Medicine, 102 Heukseok-ro, Dongjak-gu, Seoul 06973, Republic of Korea



© The Author(s) 2022. **Open Access** This article is licensed under a Creative Commons Attribution 4.0 International License, which permits use, sharing, adaptation, distribution and reproduction in any medium or format, as long as you give appropriate credit to the original author(s) and the source, provide a link to the Creative Commons licence, and indicate if changes were made. The images or other third party material in this article are included in the article's Creative Commons licence, unless indicated otherwise in a credit line to the material. If material is not included in the article's Creative Commons licence and your intended use is not permitted by statutory regulation or exceeds the permitted use, you will need to obtain permission directly from the copyright holder. To view a copy of this licence, visit <http://creativecommons.org/licenses/by/4.0/>. The Creative Commons Public Domain Dedication waiver (<http://creativecommons.org/publicdomain/zero/1.0/>) applies to the data made available in this article, unless otherwise stated in a credit line to the data.

remitted by combination therapy of low-dose oral valacyclovir and topical ganciclovir gel.

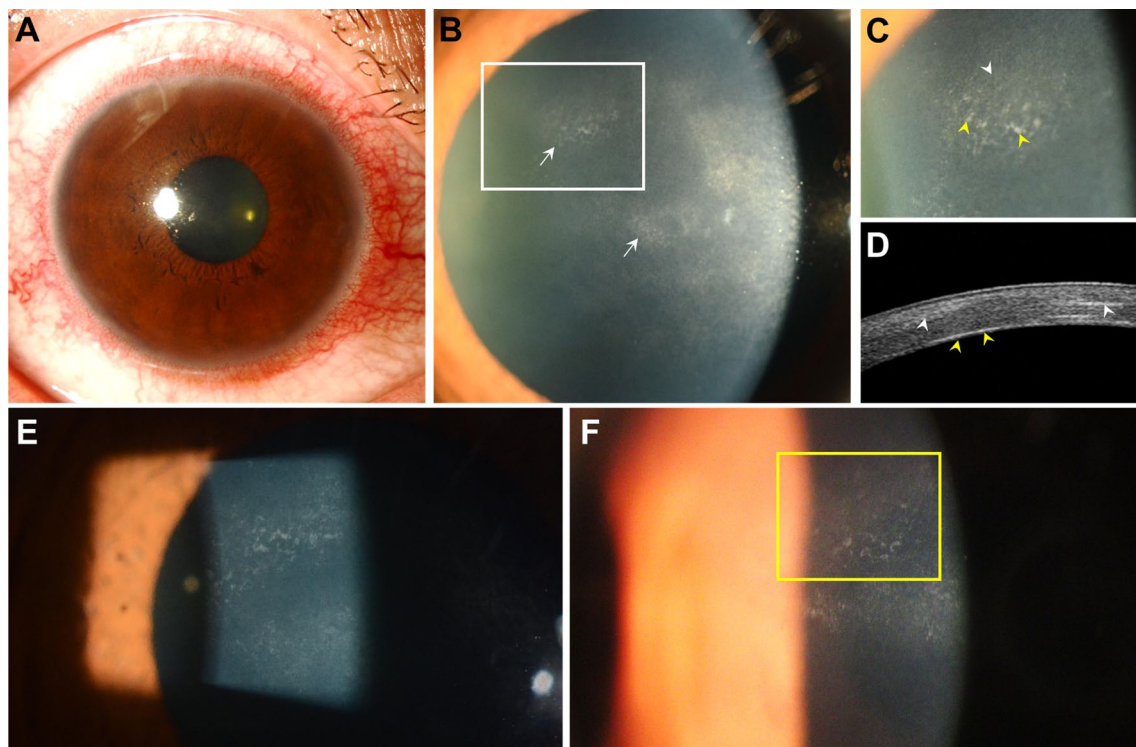
### Case presentation

A 39-year-old Asian female was referred for corneal endothelial abnormality with recurrent anterior uveitis and intraocular pressure (IOP) elevation in her right eye. One month before her initial ocular symptoms, she had skin lesions with pain, having noticed blisters on the forehead and swelling with redness on her right upper and lower eyelids; she had been diagnosed with zoster at the right ophthalmic branch dermatome of the trigeminal nerve. As a usual treatment of zoster, the initial episode of the zoster was treated with oral famciclovir 250 mg three times daily for 1 week. She was previously diagnosed with hepatitis, but she had no other past medical, surgical, social, or family history to specify.

On her first visit to our institute, the corrected visual acuity of the right eye was 20/20 and IOP was 14 mmHg. Copious ciliary injection was noted (Fig. 1A), and at 10 o'clock mid-periphery of the cornea and the center,

coin-shaped corneal endothelial scar-like lesions were observed between or below the areas of cornea stromal haziness (Fig. 1B, C). On anterior segment ocular optical tomography, corneal endothelial lesions appeared as highly reflective lines at the level of Descemet's membrane (Fig. 1D). There was no corneal edema in the area of corneal endothelial lesions, and the corneal endothelial cell density was normal.

Herpes simplex virus (HSV), CMV, VZV, Epstein-Barr virus (EBV), and human herpesvirus (HHV) type 6 were all negative by multiplex polymerase chain reaction (PCR) from aqueous humor sample. Serological anti-human immunodeficiency virus antibody, antinuclear antibody, rheumatoid factor, and human leukocyte antigen-B51 were negative. Differential blood cell counts were also within the normal range. However, based on the history of typical facial zoster at V1 dermatome and the concurrent recurrent anterior uveitis, the patient was presumed to have HZO, and oral valaciclovir (ValACV) 500 mg twice per day, topical ganciclovir gel (Virgan, Laboratoires Théa, Clermont-Ferrand, France) five times



**Fig. 1** The coin-shaped corneal endothelial scar with inflammation at the initial referral. **A, B** Ciliary injection (**A**) and multiple corneal hazy lesions (**B**, arrows) are shown. **C, D** At 10 o'clock mid-periphery of the cornea (**C**, the magnified view of the white rectangle in **B**), a coin-shaped corneal endothelial scar-like lesion comprising scar-like opaque foci (**C**, yellow arrowheads) with overlying corneal stromal haziness (**C**, white arrowhead) is noted. Anterior segment optical tomography (**D**) at the area of the lesion (**C**), accordingly, revealed a highly reflective line at the level of Descemet's membrane (**D**, yellow arrowheads) and overlying stromal opaque lesions (**D**, white arrowheads). **E** After 5 months, the coin-shaped endothelial lesions remained without noticeable change. **F** At 1 year, the coin-shaped corneal endothelial scar-like lesions became sparse (inside the yellow rectangle)

per day, and 0.1% fluorometholone four times per day were started. After 5 months, while anterior uveitis was in remission, coin-shaped endothelial lesions remained similar in appearance (Fig. 1E). Although the anterior uveitis recurred once within 10 days after discontinuance of ValACV, there was no additional recurrence of anterior uveitis with intake of oral ValACV 500 mg twice per day for 1 year afterward. At 1 year, the coin-shaped corneal endothelial scar-like lesions remained but became sparse (Fig. 1F). The corneal endothelial cell density was normal, without occurrence of corneal edema.

### Discussion and conclusion

One-third of HZO patients experience attacks of anterior uveitis that occur 2–4 weeks after the initial onset of HZO, and they also accompany corneal epithelial, stromal, or endothelial abnormalities [4]. The diagnosis of zoster anterior uveitis is usually clinically based on the history of herpes zoster, and as a confirmatory test, a polymerase chain reaction test is performed using aqueous humor. Despite the ability of PCR to distinguish viruses such as HSV, VZV, and CMV, the sensitivity of the test may decrease during the administration of antiviral agents, as in this case [4]. In addition, while the multiplex PCR performed in this case has the advantage of detecting various targets at once, false negative results may occur due to competition and interference between primers [5, 6].

The chronic or recurrent course of HZO usually occurs in the form of anterior uveitis, whereas corneal complications usually present epithelial keratitis or pseudodendritic keratitis early in the disease. Although relatively rare, other known corneal involvements of HZO include lipid keratopathy caused by disciform stromal keratitis, corneal thinning, corneal perforation, and persistent corneal edema caused by severe endotheliitis [1, 3, 7]. However, the coin-shaped corneal endothelial lesion observed in this case has not been reported. It is presumed to be a scar lesion because its shape did not change despite the clinical improvement observed on anterior segment ocular optical tomography. According to a previous study that reported detecting VZV DNA on the ocular surface for more than 1 month after onset of HZO [8], it is plausible that VZV continues damaging corneal tissue during the prolonged period. Also, in this case, VZV might cause both severe stromal keratitis and corneal endotheliitis, which might have caused coin-shaped inflammatory scar over recurrences.

The 50% effective dose (ED50) of the expected biological effects of acyclovir (ACV) against VZV is known to be between 2.06 and 6.28  $\mu\text{M}$  [9]. The concentration of ACV in the anterior chamber reached 3.26  $\mu\text{M}$  when oral acyclovir 400 mg was taken five times daily [10]. Based

on the similarity of blood ACV concentrations between 4000 mg daily oral ACV and 1000 mg daily oral ValACV [11], it can be assumed that the ACV concentration of about 6–7  $\mu\text{M}$  dose was maintained in the anterior chamber after oral 500 mg of ValACV twice daily. The four to six times daily use of topical 3% ACV ointment, which is known as the effect equivalent of 0.15% ganciclovir [12], causes concentrations of up to 7.5  $\mu\text{M}$  in the anterior chamber [13] and it is even higher than ED50 of ACV to VZV. In our case, the remission of anterior uveitis, in this case, was oral antiviral dependent. This is consistent with a previous study showing that local preparations were ineffective in early HZO, which may be due to VZV pathologically invading the nerves and blood vessels behind the eye; thus, oral antiviral agents may affect the tissue and trigeminal nerve pathways [14]. Furthermore, the recurrence after discontinuing oral ValACV and the remission after reintake of oral ValACV suggests that this case is associated with the reactivation of VZV.

Despite the corneal endothelial lesion, in this case, not resembling the coin-shaped lesion usually observed in CMV corneal endotheliitis, we suggest that severe stromal inflammation in HZO may accompany adjacent round endothelial scar at deeper layers of the endothelium.

In conclusion, in patients with a history of facial herpes zoster with coin-shaped corneal endothelial scar accompanying recurrent anterior uveitis, suspicion of active VZV is warranted, and prolonged intake of oral antiviral agents is required, despite VZV DNA not being detected in aqueous humor.

### Abbreviations

HZO: Herpes zoster ophthalmicus; HSV: Herpes simplex virus; CMV: Cytomegalovirus; VZV: Varicella zoster virus; EBV: Epstein–Barr virus; HHV: Human herpes virus; IOP: Intraocular pressure; ACV: Acyclovir.

### Acknowledgements

Not applicable.

### Authors' contributions

SHL and KWK were responsible for substantial contributions to the conception or design of the work and were major contributors in writing the manuscript. YSC was responsible for the interpretation of results. SHL, YSC, and KWK were responsible for the final approval of the version to be published and reviewed. All authors read and approved the final manuscript.

### Funding

None.

### Availability of data and materials

All data generated or analyzed during this study are included in this published article.

### Declarations

### Ethics approval and consent to participate

Not applicable.

### Consent for publication

Written informed consent was obtained from the patient for publication of this case report and any accompanying images. A copy of the written consent is available for review by the Editor-in-Chief of this journal.

### Competing interests

The authors declare that they have no competing interests.

Received: 19 May 2021 Accepted: 9 February 2022

Published online: 17 March 2022

### References

1. Liesegang TJ. Herpes zoster ophthalmicus natural history, risk factors, clinical presentation, and morbidity. *Ophthalmology*. 2008;115:53–12.
2. Karbassi M, Raizman MB, Schuman JS. Herpes zoster ophthalmicus. *Surv Ophthalmol*. 1992;36:395–410.
3. Liesegang TJ. Corneal complications from herpes zoster ophthalmicus. *Ophthalmology*. 1985;92:316–24.
4. Cunningham ET Jr, Miserocchi E, Tugal-Tutkun I, Zierhut M. Varicella zoster virus-associated uveitis. *Ocul Immunol Inflamm*. 2018;26:167–70.
5. Li Y, Guo SJ, Shao N, et al. A universal multiplex PCR strategy for 100-plex amplification using a hydrophobically patterned microarray. *Lab Chip*. 2011;11:3609–18.
6. Polz MF, Cavanaugh CM. Bias in template-to-product ratios in multitemplate PCR. *Appl Environ Microbiol*. 1998;64:3724–30.
7. Reijo A, Antti V, Jukka M. Endothelial cell loss in herpes zoster keratouveitis. *Br J Ophthalmol*. 1983;67:751–4.
8. Zaal MJ, Volker-Dieben HJ, Wienees M, D'Amato J, Kijlstra A. Longitudinal analysis of varicella-zoster virus DNA on the ocular surface associated with herpes zoster ophthalmicus. *Am J Ophthalmol*. 2001;131:25–9.
9. Biron KK, Elion GB. In vitro susceptibility of varicella-zoster virus to acyclovir. *Antimicrob Agents Chemother*. 1980;18:443–7.
10. Hung SO, Patterson A, Rees PJ. Pharmacokinetics of oral acyclovir (Zovirax) in the eye. *Br J Ophthalmol*. 1984;68:192–5.
11. Perry CM, Faulds D. Valaciclovir. A review of its antiviral activity, pharmacokinetic properties and therapeutic efficacy in herpesvirus infections. *Drugs*. 1996;52:754–72.
12. Colin J. Ganciclovir ophthalmic gel, 0.15%: a valuable tool for treating ocular herpes. *Clin Ophthalmol*. 2007;1:441–53.
13. Poirier RH, Kingham JD, de Miranda P, Annel M. Intraocular antiviral penetration. *Arch Ophthalmol*. 1982;100:1964–7.
14. Marsh RJ, Cooper M. Ophthalmic herpes zoster. *Eye (Lond)*. 1993;7(Pt 3):350–70.

### Publisher's Note

Springer Nature remains neutral with regard to jurisdictional claims in published maps and institutional affiliations.

Ready to submit your research? Choose BMC and benefit from:

- fast, convenient online submission
- thorough peer review by experienced researchers in your field
- rapid publication on acceptance
- support for research data, including large and complex data types
- gold Open Access which fosters wider collaboration and increased citations
- maximum visibility for your research: over 100M website views per year

At BMC, research is always in progress.

Learn more [biomedcentral.com/submissions](https://biomedcentral.com/submissions)

