

Delayed Mammoplasty with Silicone Gel Implants following DIEP Flap Breast Reconstruction

Jules A. Walters, III, MD*
 Erika A. Sato, MD*
 Carlos A. Martinez, MD†
 Jason J. Hall, MD, FACS*,†
 Sean G. Boutros, MD,
 FACS*,†

Background: The deep inferior epigastric artery perforator (DIEP) flap is a state-of-the-art option for breast reconstruction. However, thin patients with medium- to large-size native breasts are not ideal candidates due to the limited amount of available tissue. We reviewed our experience utilizing the DIEP flap in combination with prosthetic implants.

Methods: We conducted a retrospective chart review of 7 patients, totaling 11 implants, who underwent breast reconstruction with the DIEP flap and subsequent mammoplasty. All cases underwent previous mastectomies. No implant placement was offered at the time of their DIEP flap reconstruction. Immediate breast reconstruction with the DIEP flap was performed in 9 cases, whereas 2 required delayed reconstruction secondary to postmastectomy radiotherapy. No patients received postreconstruction radiotherapy. Breast asymmetry and inadequate volume were the primary indications for mammoplasty. For all cases, we used smooth, round silicone gel implants, which were placed in the subpectoral region.

Results: Mean age was 43 years. One patient was actively smoking. Four patients underwent bilateral implant placement. The mean time of delay between breast reconstruction and mammoplasty was 61 weeks. Average volume of silicone implants was 229 mL. A medial pedicle vertical mastopexy was performed in 1 patient on a nonreconstructed breast to achieve symmetry. Five patients underwent nipple reconstruction. All patients underwent delayed mammoplasty without intraoperative complications and good aesthetic results.

Conclusions: Delayed mammoplasty following DIEP flap breast reconstruction is a safe and feasible procedure for patients who seek an aesthetic and natural-looking breast but lack adequate abdominal tissue. (*Plast Reconstr Surg Glob Open* 2015;3:e540; doi: 10.1097/GOX.0000000000000527; Published online 20 October 2015.)

Improvements in the free flap breast reconstruction techniques resulted in the development of the deep inferior epigastric artery perforator (DIEP)

flap.¹⁻⁶ However, patients who are thin with medium- to large-size breasts are not ideal candidates for this type of reconstruction due to the limited amount of available abdominal tissue required for desired size and symmetry. Before the advent of the DIEP flap, the solution to overcome a thin body habitus without sacrificing aesthetics in this patient population was the use of the latissimus dorsi flap or the transverse rectus abdominis myocutaneous flap in combination with an implant.⁷⁻¹¹ These procedures can provide the natural appearance of autologous reconstruction combined with the volume of the prosthesis. In addition, it has

From the *Department of Surgery, The University of Texas School of Medicine, Houston, Tex.; †Houston Plastic & Craniofacial Surgery, Houston, Tex.

Received for publication September 19, 2014; accepted September 1, 2015.

Copyright © 2015 The Authors. Published by Wolters Kluwer Health, Inc. on behalf of The American Society of Plastic Surgeons. All rights reserved. This is an open-access article distributed under the terms of the Creative Commons Attribution-Non Commercial-No Derivatives License 4.0 (CCBY-NC-ND), where it is permissible to download and share the work provided it is properly cited. The work cannot be changed in any way or used commercially.

DOI: 10.1097/GOX.0000000000000527

Disclosure: The authors have no financial interest to declare in relation to the content of this article. The Article Processing Charge was paid for by the authors.

been shown that complications are reduced when an implant reconstruction is combined with an autologous flap.¹² Likewise, breast reconstruction by autologous fat grafting has emerged as a practical option due to its versatility and minimal complications, although its use has been limited to the correction of small volume or contour deformities in patients with sufficient volume of donor sites.

A number of options can be considered for thin patients who wish to maintain or increase their breast size or whose abdominal tissue is not adequate for the desired projection. However, these procedures usually require repositioning and team approaches. Gluteal artery perforator flaps can provide ample tissue alone for thin patients, but can be more technically demanding and can result in challenging donor-site deformities. The body lift perforator flap offers a technically demanding solution for this patient population and does not require the use of implants. However, it requires supine and prone positioning and longer operative times.¹³

In our experience, a safe, simple solution is the use of the DIEP flap in combination with prosthetic implants. The perfect candidates for mammoplasty following a DIEP flap include those patients with a thin body habitus and large-size breasts, especially in the cases of bilateral breast reconstruction, where the amount of abdominal tissue is inadequate to create 2 aesthetically pleasing breasts. We reviewed our experience performing a combined, 2-stage reconstruction using the DIEP flap with prosthetic implants to improve the aesthetic results in the post-mastectomy population.

PATIENTS AND METHODS

After institutional review board approval, 184 consecutive patients who underwent breast reconstruction with the DIEP flap from July 2007 to November 2012 were identified. A total of 314 flaps were performed by either 1 of 2 surgeons in a single practice group (54 patients required unilateral reconstruction, whereas 130 required bilateral reconstruction). We then gathered the data of patients who underwent mammoplasty following DIEP flap reconstruction; 7 patients, totaling 11 implants, were selected for our study and retrospectively reviewed. Variables such as age, American Society of Anesthesiologists score, preoperative and postoperative radiotherapy (RT), indications for mammoplasty, implant details (type, size, and location), complications, and postoperative visits were collected. Table 1 summarizes the data collection.

No patients were offered implant placement at the time of their DIEP flap reconstruction. The

patients were counseled in detail about the risks of implant placement as a second-stage reconstruction including devascularization of the flap with subsequent loss and an increased risk of revisionary surgery or capsular contracture. During the first stage, immediate breast reconstruction with the DIEP flap was performed in 9 cases, whereas 2 required delayed reconstruction secondary to postmastectomy radiation therapy. One patient who underwent immediate reconstruction had a previous partial mastectomy followed by RT. Breast asymmetry and inadequate volume were the primary indications for mammoplasty. Smooth, round silicone gel implants were used in all the patients, as they provide the most natural feel. Although we do not use implant sizers, the implant volume was chosen upon chest dimensions, always aiming to spare approximately 1 cm to avoid added pressure to the flap pedicle. Following dissection under direct vision of the subpectoral pocket, implants were placed using a Keller funnel. Partial release of the pectoralis muscle was performed as needed, by inferior dissection perpendicular to the muscle fibers, as placing the implant under the pectoralis muscle proved arduous in some cases, notably in those patients with previous radiation. Full-thickness release of the pectoralis muscle was not needed in any case.

Details of additional procedures and intraoperative findings during the second-stage reconstruction with the implant placement were documented. Information regarding intraoperative and postoperative complications was collected. During follow-up, patients provided a subjective scale of overall satisfaction.

RESULTS

Seven patients underwent delayed implant-based mammoplasty following reconstruction with the DIEP flap, totaling 11 implants. Mean age of the group was 43 years (range between 33 and 52 years), with an American Society of Anesthesiologists score of 1 in all cases. Only 1 patient (no. 2) was actively smoking. Four patients underwent bilateral breast reconstruction. In all patients, the internal mammary was utilized as the recipient vessel. Three patients received RT before the first stage of the reconstruction. No patients received postreconstruction RT. Superficial necrosis of the mastectomy skin flaps in 1 patient was the only complication following the first stage of reconstruction. The mean time of delay between DIEP flap breast reconstruction and mammoplasty was 61 weeks (range between 19 and 127 weeks). In 3 patients, mammoplasty was indicated due to asymmetry. Two patients presented

Table 1. Patient Data

Patient No.	Age (yr)	Indications for Augmentation	Preoperative RT*	Implant Location	Implant Type and Size	Outcome**
1	33	Asymmetry	Not required	Subpectoral	L: Smooth, 125 mL	No complications
2	46	Fuller appearance	Not required	Subpectoral	L: Smooth, 180 mL	No complications
3	46	Fuller appearance	Not required	Subpectoral	R: Smooth, 180 mL L: Smooth, 304 mL	No complications
4	38	Inadequate volume, bilateral superior pole deformity	Not required	Subpectoral	R: Smooth, 304 mL L: Smooth, 280 mL	No complications
5	52	Asymmetry	Required	Subpectoral	L: Smooth; 180 mL	No complications
6	49	Asymmetry	Required	Subpectoral	L: Smooth; 210 mL	No complications
7	37	Inadequate volume	Required (only on left breast)	Subpectoral	L: Smooth, 265 mL R: Smooth; 210 mL	No complications

*No postoperative RT was required in any flap.

**Following augmentation mammoplasty.

L, left; R, right.

with postreconstruction inadequate volume when compared to their native breasts (1 patient also had deformities to the superior poles in both breasts), and a fuller appearance was the primary concern in the remaining 2 patients.

Smooth, round silicone gel implants were used in all cases, with an average volume of 229 mL (range between 125 and 304 mL). The implant was placed through an inframammary fold incision or a vertical incision depending on the preexisting scar pattern. A medial pedicle vertical mastopexy was designed in the native contralateral breast of 1 patient to achieve symmetry. Five patients underwent nipple reconstruction. All patients underwent delayed mammoplasty without intraoperative complications and good aesthetic results. Mean follow-up period was 37 weeks (range between 4 and 120 weeks). There were no postmammoplasty complications and all patients were satisfied.

CASE REPORTS

Case 1

A 49-year-old woman with a history of left-sided ductal carcinoma underwent left mastectomy. Delayed reconstruction with the DIEP flap was performed after she underwent RT and chemotherapy. She was concerned about the inadequate volume in the reconstructed breast, and she sought to improve her appearance. To obtain more volume, she underwent mammoplasty following a 13-week postoperative period with a 340-cm³ silicone gel implant placed in the subpectoral region; she underwent nipple reconstruction. Patient satisfaction was achieved and no complications occurred (Fig. 1).

Case 2

A 46-year-old woman with history of multifocal ductal carcinoma underwent bilateral skin-sparing mastectomies with immediate reconstruction using the DIEP

flap. Postoperatively, the patient was satisfied with the results, but she desired a fuller appearance. She underwent mammoplasty 97 weeks after breast reconstruction; 304-cm³ silicone gel implants were placed in the subpectoral region bilaterally. She also underwent nipple reconstruction. There were no complications. Postoperatively, the patient was highly satisfied with the results (Fig. 2).

Case 3

A 37-year-old woman with history of left-sided breast cancer status post mastectomy and RT underwent delayed left breast reconstruction with the DIEP flap. She also underwent a prophylactic mastectomy with immediate right-sided reconstruction. Due to inadequate volume, she sought further options for an improved appearance. She underwent bilateral revisionary surgery 54 weeks following reconstruction. A subpectoral 265-cm³ silicone gel implant was placed in the left breast, whereas a 210-cm³ implant was required for the right breast. The patient also underwent nipple reconstruction. The patient tolerated the procedure without complications. Due to the history of RT, the left breast implant settled higher than the right postoperatively; nonetheless, she was highly satisfied with the results (Fig. 3).

DISCUSSION

The advantages of the DIEP flap over other reconstructive techniques have been extensively reported, and it is an excellent choice for autologous reconstruction given its low rate of donor-site complications when compared to other autologous techniques.¹⁴⁻¹⁶ The combined approach of autologous tissue and prosthetic implants or expanders has been advocated by Kronowitz et al, Spear and Wolfe, and Serletti and Moran^{7,9,10} to improve appearance and symmetry in thin patients with large pre-mastectomy breast volumes.^{8,10}

The subcutaneous fat of the DIEP flap closely resembles the appearance and texture of the natural

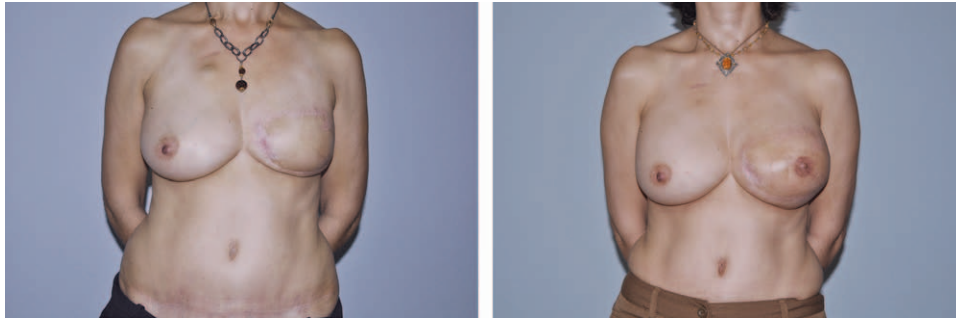


Fig. 1. A, A 49-year-old woman with delayed DIEP flap breast reconstruction following radiation and chemotherapy. B, Postoperative result with a 340-mL silicone gel implant and nipple reconstruction.

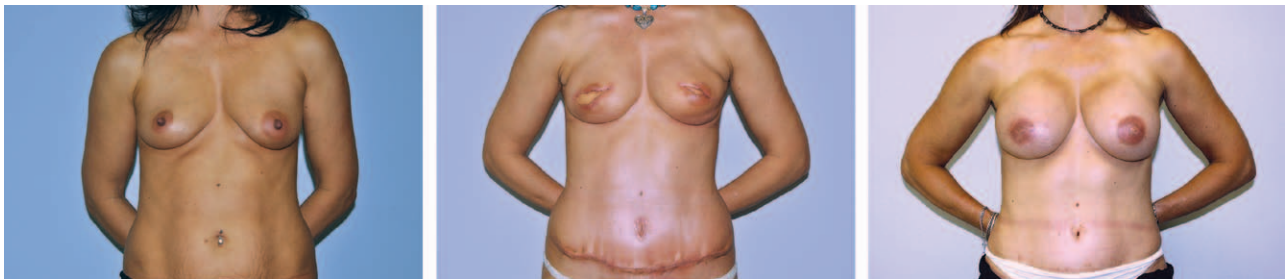

Fig. 2. A, A 46-year-old woman with multifocal ductal cancer. B, Underwent bilateral DIEP flap breast reconstruction following skin-sparing mastectomies. C, Postoperative results with 340-cm³ silicone gel implants and additional nipple reconstructions.

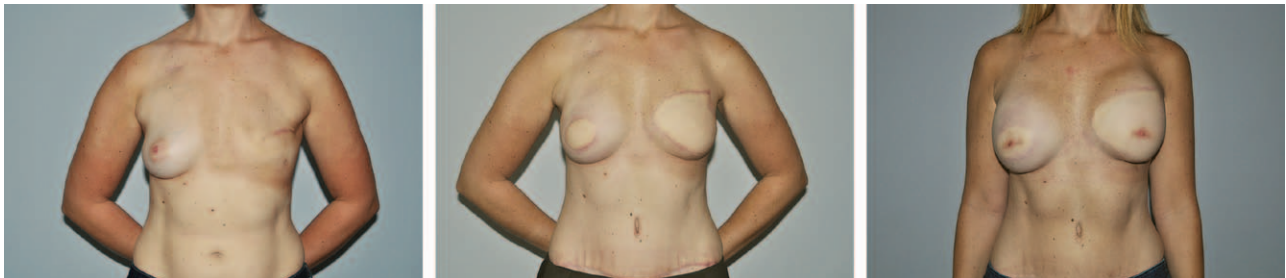

Fig. 3. A 37-year-old woman with history of bilateral mastectomies (A) and delayed DIEP flap breast reconstruction (B). C, Postoperative results with a left-sided, 265-cm³ and right-sided, 210-cm³ silicone gel implants, with additional nipple reconstructions.

breast, giving an aesthetically pleasing shape to the reconstruction, whereas the secondary placement of a silicone gel implant provides the desired volume. As opposed to other tissue-based reconstruction techniques like the latissimus dorsi flap, where a larger implant is required due to the reduced volume provided by the flap, smaller implants can achieve a fuller look when combined with the DIEP flap (average size in our cases was 229mL), thus possibly decreasing the rate of complications that may arise from mechanical pressure from the underlying implant.

For all of our patients, we chose a 2-stage breast reconstruction with delayed mammoplasty. Kronowitz et al⁷ and Spear and Wolfe⁹ noted that immediate mammoplasty of the reconstructed breast with the transverse rectus abdominis myocutaneous flap was prone to complications, including flap failure and an increased rate of infection. Others¹⁷ have

reported primary placement of implants following breast reconstruction with the DIEP flap, supporting the idea that immediate implant placement could reduce unintentional damage to the pedicle by avoiding the need for a second surgery, with no statistically significant results. Furthermore, in their series, 3 flaps with primary mammoplasty presented with complications, including 2 cases of partial flap necrosis.

We believe that a delayed approach could prevent postoperative flap complications. DIEP flap reconstruction is a long and technically demanding procedure. Immediate implant placement leads to additional operative time, increasing the chance for infection and other postoperative complications. In our experience, the majority of patients undergo a second surgery for revision and/or nipple reconstruction, and this is an ideal time to undergo implant placement. We believe

that an approximate waiting period of 4 months is an ideal time frame between both stages, as it provides sufficient time to decrease the inflammation caused by the reconstruction and the revascularization of the flap based on the pectoralis interface. Additional precautions are taken in the cases of postreconstructive RT, where waiting periods could take up to 1 year.

Literature in regard to mammoplasty suggests that a subpectoral placement of the implant may reduce the incidence of capsular contracture,¹⁸ whereas concealing any contour deformities that may arise with time. Furthermore, a submuscular plane seems like an ideal choice, as it offers protection to the perforators by keeping them above the muscle. Also, in the event of a problem with the pedicle, the pectoralis could provide revascularization to the substance of the flap and prevent complete loss of the flap, which would be unlikely to occur with placement of the implant immediately deep to the DIEP flap itself. Capsular contracture is a common complication that has been extensively reported.⁷⁻⁹ However, we did not find any evidence in our relatively short follow-up period.

CONCLUSIONS

Increased options in the field of reconstruction with autologous tissue will improve our ability to recreate the premastectomy appearance of the breast. Delayed mammoplasty following DIEP flap breast reconstruction is a safe and feasible procedure for patients who seek an aesthetic and natural-looking breast but lack adequate abdominal tissue. Larger cohorts comparing the outcomes of immediate versus delayed following breast reconstruction with the DIEP flap are needed to assess their pearls and pitfalls, in addition to the subpectoral versus subflap approach for implant placement.

Sean G. Boutros, MD

Houston Plastic & Craniofacial Surgery
6400 Fannin, Suite 2290
Houston, TX 77030

E-mail: drseanboutros@drseanboutros.com

REFERENCES

- Hamdi M, Weiler-Mithoff EM, Webster MH. Deep inferior epigastric perforator flap in breast reconstruction: experience with the first 50 flaps. *Plast Reconstr Surg.* 1999;103:86-95.
- Guerra AB, Metzinger SE, Bidros RS, et al. Bilateral breast reconstruction with the deep inferior epigastric perforator (DIEP) flap: an experience with 280 flaps. *Ann Plast Surg.* 2004;52:246-252.
- Keller A. The deep inferior epigastric perforator free flap for breast reconstruction. *Ann Plast Surg.* 2001;46:474-479.
- Blondeel N, Vanderstraeten GG, Monstrey SJ, et al. The donor site morbidity of free DIEP flaps and free TRAM flaps for breast reconstruction. *Br J Plast Surg.* 1997;50:322-330.
- Blondeel PN. One hundred free DIEP flap breast reconstructions: a personal experience. *Br J Plast Surg.* 1999;52:104-111.
- Gill PS, Hunt JP, Guerra AB, et al. A 10-year retrospective review of 758 DIEP flaps for breast reconstruction. *Plast Reconstr Surg.* 2004;113:1153-1160.
- Kronowitz SJ, Robb GL, Youssef A, et al. Optimizing autologous breast reconstruction in thin patients. *Plast Reconstr Surg.* 2003;112:1768-1778.
- Miller MJ, Rock CS, Robb GL. Aesthetic breast reconstruction using a combination of free transverse rectus abdominis musculocutaneous flaps and breast implants. *Ann Plast Surg.* 1996;37:258-264.
- Spear SL, Wolfe AJ. The coincidence of TRAM flaps and prostheses in the setting of breast reconstruction. *Plast Reconstr Surg.* 2002;110:478-486.
- Serletti JM, Moran SL. The combined use of the TRAM and expanders/implants in breast reconstruction. *Ann Plast Surg.* 1998;40:510-514.
- Kronowitz SJ. Current status of implant-based breast reconstruction in patients receiving postmastectomy radiation therapy. *Plast Reconstr Surg.* 2012;130:513e-523e.
- Chang DW, Barnea Y, Robb GL. Effects of an autologous flap combined with an implant for breast reconstruction: An evaluation of 1000 consecutive reconstruction of previously irradiated breasts. *Plast Reconstr Surg.* 2008;62:488-493.
- DellaCroce FJ, Sullivan SK, Trahan C, et al. Body lift perforator flap breast reconstruction: a review of 100 flaps in 25 cases. *Plast Reconstr Surg.* 2012;129:551-561.
- Man LX, Selber JC, Serletti JM. Abdominal wall following free TRAM or DIEP flap reconstruction: a meta-analysis and critical review. *Plast Reconstr Surg.* 2009;124:752-764.
- Bonde CT, Christensen DE, Elberg JJ. Ten years' experience of free flaps for breast reconstruction in a Danish microsurgical centre: an audit. *Scand J Plast Reconstr Surg Hand Surg.* 2006;40:8-12.
- Sheer AS, Novak CN, Neligan PC, et al. Complications associated with breast reconstruction using a perforator flap compared with a free TRAM flap. *Ann Plast Surg.* 2006;56:355-58.
- Figus A, Canu V, Iwuagwu FC, et al. DIEP flap with implant: a further option in optimising breast reconstruction. *J Plast Reconstr Aesthet Surg.* 2009;62:1118-1126.
- Hodgson EL, Malata CM. Implant-based breast reconstruction following mastectomy. *Breast Dis.* 2002;16:47-63.