

# Feasibility Study to Determine if Microfracture Surgery Using Water Jet Drilling Is Potentially Safe for Talar Chondral Defects in a Caprine Model

CARTILAGE  
2021, Vol. 13(Suppl 2) 1627S–1636S  
© The Author(s) 2019



Article reuse guidelines:  
sagepub.com/journals-permissions  
DOI: 10.1177/1947603519880332  
journals.sagepub.com/home/CAR



Aimee C. Kok<sup>1</sup> , Steven den Dunnen<sup>2</sup>, Kaj T.A. Lambers<sup>1</sup>,  
Gino M.M.J. Kerkhoffs<sup>1</sup>, and Gabrielle J.M. Tuijthof<sup>1,2</sup>

## Abstract

**Objective.** Surgical microfracture is considered a first-line treatment for talar osteochondral defects. However, current rigid awls and drills limit access to all locations in human joints and increase risk of heat necrosis of bone. Using a flexible water jet instrument to drill holes can improve the reachability of the defect without inducing thermal damage. The aim of this feasibility study is to determine whether water jet drilling is potentially safe compared with conventional microfracture awls by studying side effects and perioperative complications, as well as the quality of cartilage repair tissue. **Design.** Talar chondral defects with 6-mm diameter were created bilaterally in 6 goats (12 samples). One defect in each goat was treated with microfracture created with conventional awls, the contralateral defect was treated with holes created with 5-second water jet bursts at a pressure of 50 MPa. Postoperative complications were recorded and after 24 weeks analyses were performed using the ICRS (International Cartilage Repair Society) macroscopic score and modified O'Driscoll histological score. **Results.** Several practical issues using the water jet in the operating theatre were noted. Water jet drilling resulted in fibrocartilage repair tissue similar to the repair tissue from conventional awls. **Conclusions.** These results suggest that water jet drilling gives adequate fibrocartilage repair tissue. Furthermore, the results highlight essential prerequisites for safe application of surgical water jet drilling: stable water pressure, water jet beam coherence, stable positioning of the nozzle head when jetting, and minimizing excessive fluid extravasation.

## Keywords

animal models, general, ankle, joint involved, microfracture, procedures, cartilage repair, repair

## Introduction

(Osteo-)chondral defects of the talus (OCDT) are caused by damaged cartilage and underlying bone. Symptoms include prolonged deep ankle pain and swelling, while resulting in osteoarthritis and chronic disability over time.<sup>1</sup> Debridement and bone marrow stimulation, or microfracture, is a commonly used first-line treatment option for OCDT smaller than 15 mm.<sup>2,3</sup> During this arthroscopic procedure, the defect is debrided and the calcified layer covering the defect is punctured, introducing blood with mesenchymal stem cells that will produce fibro-cartilaginous repair tissue.<sup>4</sup> Pain reduction, functional improvement, and patient satisfaction are described to be 61% to 86% in both primary and secondary OCDT.<sup>5,6</sup> However, limited research is available on whether improvement of the surgical technique is possible.<sup>7</sup>

The current technique mainly involves hammering microfracture awls or drilling K-wires. Both are rigid instruments that allow a limited approach of more posterior or lateral defects causing suboptimal distribution and nonperpendicular

placement of the microfracture holes. This can cause the surgeon to wedge the instrument on the tibia when treating such a defect. Also, collateral damage to the surrounding bone structure can occur in terms of heat necrosis or impaction of bone when drilling with K-wires or using awls, respectively.<sup>8</sup>

Water jet cutting is originally an industrial technique that uses a focused water beam to cut through material.<sup>9</sup> It is being used for medical treatment of soft tissue in fields such as oral implantology and the preparation of skin

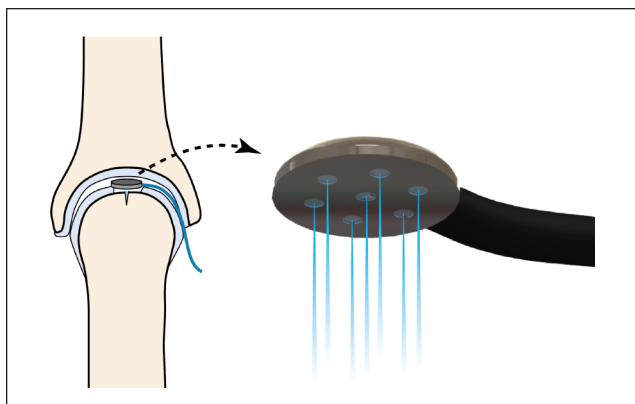
<sup>1</sup>Department of Orthopaedic Surgery, Amsterdam Academic Medical Centre, University of Amsterdam, Amsterdam Movement Sciences, Amsterdam, Netherlands

<sup>2</sup>Department of BioMechanical Engineering, Delft University of Technology, Delft, Netherlands

### Corresponding Author:

Aimee C. Kok, Department of Orthopaedic Surgery, Amsterdam Academic Medical Centre, Meibergdreef 9, Amsterdam, 1105 AZ, Netherlands.

Email: a.kok@amc.uva.nl



**Figure 1.** Graphic illustration of the proposed minimally invasive water jet surgical instrument. The flexible tubing that offers the water/saline supply facilitates the reachability in the tight joint spaces and the nozzle head can be designed such that it allows multiple water jets to be jetting simultaneously. As can be seen in the left picture, the opposing surface layer can act to offer the counterforce needed for the recoil and stable jetting.

grafts, as well as in hepatobiliary, colorectal, and renal surgery.<sup>10-19</sup> Experimental research has shown that water jets can also be used for cutting hard biological tissue such as bone,<sup>8,20</sup> making it a feasible option for arthroplasty revision surgery<sup>21-24</sup> and creating microfracture holes.<sup>8,25,26</sup> This feasibility study in a live animal model is a necessary step in the development of a foreseen arthroscopic water jet surgical instrument (**Fig. 1**). Such a surgical instrument could be superior to the current rigid instruments, since it provides a flexible tubing to maneuver into the joint. The tubing facilitates access while avoiding collateral damage due to wedging. Also, water jet technology is a cold machining process that will not heat up tissue<sup>27</sup> and never becomes blunt. Furthermore, the instrument tip can be equipped with multiple nozzles to create several holes in one drilling session (**Fig. 1**). This improves the reproducibility and treatment coverage while diminishing surgery duration.

The aim of this feasibility study is to determine whether water jet drilling can be safely applied as an alternative for conventional microfracture awls by studying potential side effects and perioperative complications, as well as the quality of cartilage repair tissue.

## Materials and Methods

The study setup is similar to previous studies performed by our group using a caprine model. We use the caprine model, because of the reasonable similarity to a human situation in terms of cartilage thickness, weight, and healing potential<sup>28-31</sup> and our extensive experience with this model.

## Caprine Model

Six female Dutch milk goats (*Capra hircus sana*) were used in this study. The average weight was 77.7 kg (range 60.8-86.8 kg). Before entering the study, all goats were screened for absence of pregnancy and disease. Group housing was arranged starting at least 1 week before until 1 week after surgery to minimize stress on the animals.

Since no studies using pure water jets to drill in *in vivo* mammalian bone are available, no sample size calculation could be performed. Instead, the number of animals was based on earlier research on cartilage repair in large animal models.<sup>29-35</sup> The study protocol was approved by the local Animal Welfare Committees (ORCA182).

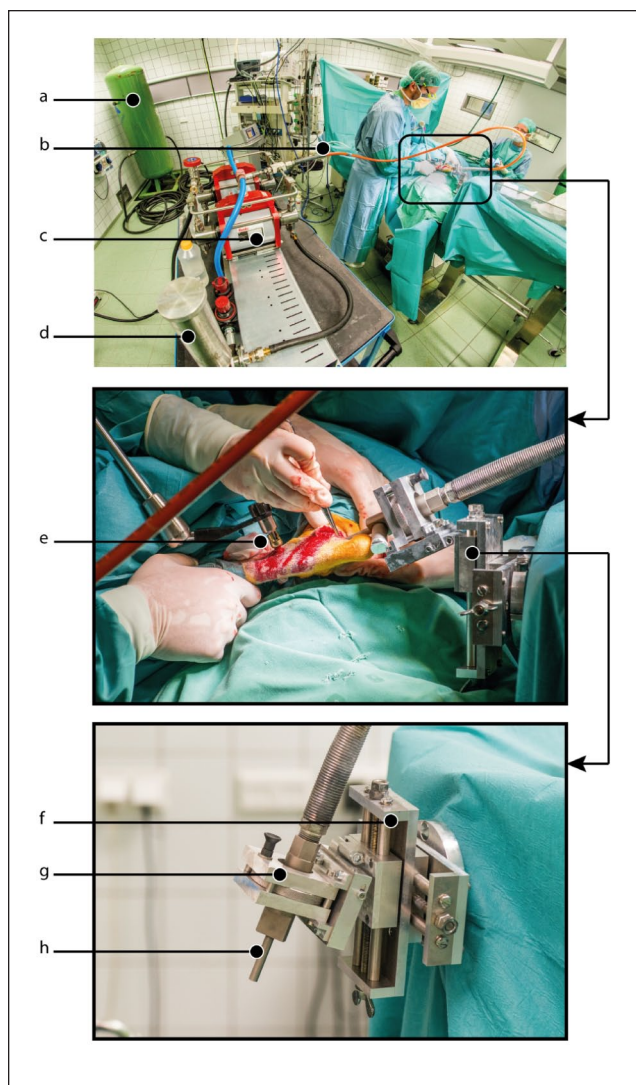
## Operative Technique

All surgical procedures were performed in a standardized manner by the first author (ACK) and an assistant using a protocol presented earlier.<sup>29,30</sup> Through a posterolateral approach access was gained to the talus. Using a sharp surgical spoon, a chondral defect of approximately 6 mm diameter was created at the center of the talar dome.<sup>36</sup> The subchondral bone layer was kept intact to prevent spontaneous blood introduction and to allow the microfracture treatment by puncturing the subchondral bone layer, enabling the inflow of mesenchymal stem cells.

The chondral defects were treated with conventional microfracture or water jet drilling based on a computer-generated randomization scheme. The contralateral talus received the other treatment in the same session. This way, the goat served as its own control. Conventional microfracture was performed according to the technique originally described by Steadman *et al.*<sup>4</sup> A 1.1-mm K-wire was used to create at least 3 evenly distributed holes to a depth that resulted in adequate bleeding to produce a blood clot in the defect.

Water jet drilling was performed by using a custom-made setup. An air compressor connected to a 300-L accumulator was used to power the air-driven high-pressure pump (P160 Resato, Roden, Netherlands, [www.resato.com](http://www.resato.com); **Fig. 2**) offering a water pressure of 50 MPa. Sterile 0.9 % saline infusion fluid was used to feed the pump with a custom-built water container. This is the same fluid used during conventional arthroscopy for fluid management. However, notice that the pressures for routine irrigation (50-113 mm Hg equal to 7-15 kPa) are a factor 1000 lower compared with the setting in this study.<sup>37</sup>

All parts of the pump that would come into contact with saline were sterilized at 134°C and assembled under sterile conditions at the operating theatre. The pressurized saline was fed through a high-pressure hose (Holmatro, Raamsdonksveer, Netherlands) into a custom-made nozzle head consisting of a straight tube with a 0.4-mm diameter



**Figure 2.** Overview of the complete water jet set up in the operating room. Top: overview of operating theatre. Center: water jet alignment of the water jet instrument with the defect in the talar bone and external fixator to fixate the goat's leg to the operating table. Bottom: alignment tool and water jet nozzle head. (a) 300-L accumulator; (b) high-pressure tube; (c) air-driven water pump; (d) water container; (e) fixating screw for the goat leg; (f) omnidirectional alignment support for nozzle head; (g) off-center turning wheel; (h) nozzle head.

sapphire nozzle (Salomon Jetting Parts B.V., Maasdam, Netherlands). Using a low-pressure water stream, the nozzle head was aligned perpendicularly to the defect in the talar bone and fixed using a custom-made support structure that allowed omnidirectional movement (Fig. 2). As it appeared that the alignment of the talar bone was slightly disturbed during a water jet burst, it was necessary to rigidly fixate the leg of the goat. This was achieved by introducing a predrilled 8 mm screw in the tibia (Fig. 2e). To this end, a stab incision was made away from the primary surgical site.

The screw was attached to an external existing fixator, which was connected to the operating table. Four to six holes were created per defect using a 0.4-mm diameter water jet burst lasting 5 seconds at a pressure of 50 MPa.<sup>25</sup> These machine settings were chosen as such to ensure that the power of each water jet was unquestionably sufficient to drill a hole through the subchondral bone layer. We based this on our previous research, where we water jet drilled in bones with varying mineral densities using numerous machine settings, and determined the drilling depth with micro-computed tomographic analyses.<sup>25,26,38</sup> An even distribution was achieved by turning the nozzle head in plane with an off-center turning wheel following each burst. The saline pressure was monitored using the integrated pressure gauge at the pump.

After treatment, the surgical wound was rinsed and closed intracutaneously with absorbable sutures. Immediate postoperative weight bearing was encouraged. Anesthesia and pain medication protocols are presented in the appendix.

### Follow-up

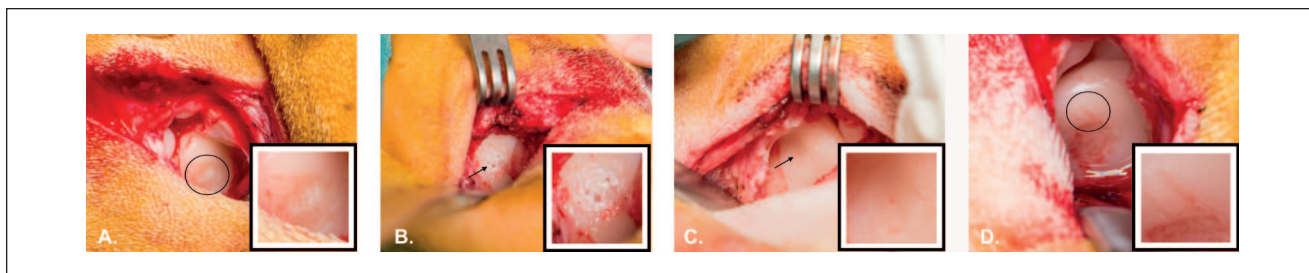
Follow-up was completed at an off-site farm under daily observation with neither food nor exercise restriction analogous to our previous published protocol.<sup>29,30</sup> After 24 weeks, the goats were euthanized following the protocol presented in the appendix.

### Analysis

To assess potential safety issues all wound and rehabilitation related adverse events were registered during surgery and daily onward until the end of the study. Also, the technical performance of the water jet and the effects of water jet drilling on the surrounding soft tissue were noted during the procedures. This provided descriptive data on the use of water jet drilling in an *in vivo* joint.

To determine if water jet drilling results in similar treatment execution as conventional microfracture, the visibility of holes and bleeding were noted during surgery. Also, resulting repair tissue quality was assessed by postmortem repair tissue analyses similar to those in our previous animal studies.<sup>30,31</sup> In short, the tali were collected and photographed for macroscopic analysis using the ICRS (International Cartilage Repair Society) score by 2 independent and blinded observers (ACK, KTAL).<sup>39</sup> The ICRS score ranges from 0 to 12, with 0 being the worst possible outcome. Directly afterward 20 × 20 mm blocks were cut of the talus around the defect and these blocks were fixed in 4% formaldehyde in a 0.1 M phosphate buffer. A histological expert dehydrated and embedded these blocks in methylmetacrylate according to a standardized protocol. Representative histological slices at a quarter and halfway through of the defect cut, stained with





**Figure 3.** Perioperative photographs. **(A)** The chondral defect created before treatment. **(B)** A chondral defect treated with conventional microfracture. **(C)** A chondral defect treated with water jet. Blood droplets can be seen in the hole. **(D)** An undesired abrasion on the rim of the defect caused by the water jet recoiling due to insufficient fixation of the talar bone.

hematoxylin and eosin and safranin-O and scored using the modified O’Driscoll score by 2 independent and blinded observers (ACK, KTAL).<sup>40</sup>

## Results

### Complications

One postoperative complication was noted. In this case, the goat showed signs of a prolonged wound healing with swelling and reluctance to weightbearing starting 2 days after surgery on the water jet side. Antibiotics were administered which resolved the symptoms.

### Water Jet Technique Performance

In 4 out of the 6 cases, the 4 to 6 water jet–drilled holes were visible after treatment in a comparable manner as the holes created with conventional microfracture (**Fig. 3B** and **C**). In the first 2 cases, only 2 water jet–drilled holes were clearly visible.

We confirmed minor signs of bleeding from the water jet holes once created, but the blood took longer to appear than with conventional microfracture.

In addition, it was noted in several cases that the soft tissue around the surgical incision appeared swollen directly after treatment with the water jets due to extravasation of the saline. This phenomenon had a similar appearance as extravasation seen in prolonged arthroscopic procedures. The swelling subsided in the days after surgery.

Last, in 1 case the surgery had to be cancelled after anesthesia due to insufficient pressure build-up of the water jet pump to perform the treatment. The surgery was rescheduled and performed 1 week later after resolving the issue. Figure 4 shows representative macroscopic and histologic samples of the best and worst cases of each of the 2 surgical techniques.

### Macroscopic ICRS Score

The median total ICRS score for the water jet tali was 9.5 (range: 6-12) for observer 1 and 9 (range 2-11) for observer

2 (**Fig. 5**). For the conventional microfracture group the median ICRS score was similar: 9.5 (range 5-11) and 9 range (2-10) for observers 1 and 2, respectively (**Fig. 5**).

### Histological Analysis

The median total modified O’Driscoll score for the water jet tali was 15 (range: 7-17) for observer 1 and 13 (range: 3-20) for observer 2 (**Fig. 6**). The control group median total modified O’Driscoll score was 13 (range: 11-21) and 15 (range: 9-20) for observers 1 and 2, respectively (**Fig. 6**). Note that for observer 1, the subitem repair cartilage thickness showed 1 out of 6 samples scoring 100% thickness in the water jet group versus 5 out of 6 samples in the conventional microfracture group. The remaining samples in both groups scored 50% to 100% thickness (5 samples versus 1 sample, respectively).

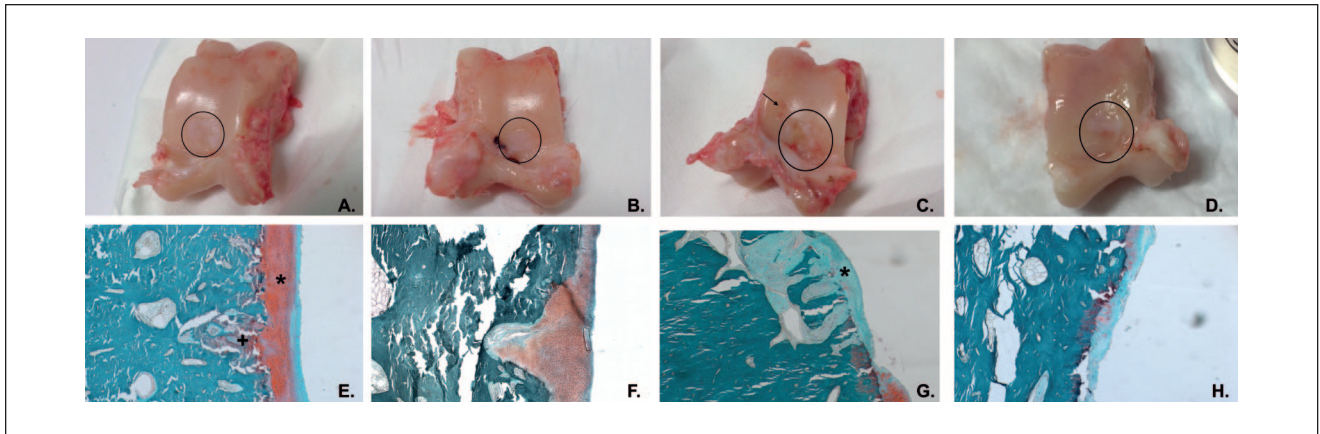
## Discussion

The aim of this study was to determine whether water jet is a safe alternative in comparison to conventional microfracture awls by studying potential side effects and perioperative complications, as well as the quality of cartilage repair tissue.

Concerning the safety and potential of water jet drilling for creating microfracture holes, we analyzed the actual effect of the drilling, the appearance of bleeding from the created holes and the postoperative complications.

There is no commercial medical water jet system available that could generate the desired water volume flow to drill into bone. To meet this high flow demand, a custom-made setup was built using all available knowledge. It was tested extensively during several pilot sessions using cadaveric caprine talar bones and total lower extremities. These pilot tests and previous studies,<sup>8,25,38</sup> lead to the choice of conservative machine settings to guaranty a functional water jet without a potential overshoot in depth.

In the first 2 goats, we encountered difficulty with achieving a sufficiently stable fixation between the leg and the water jet nozzle because recoil from the drilling caused



**Figure 4.** Representative examples of the macroscopic and microscopic analyses. **(A)** A defect filled with repair tissue treated with water jet that resulted in a good ICRS (International Cartilage Repair Society) macroscopic score. **(B)** A defect filled with repair tissue treated with conventional technique that resulted in a good ICRS macroscopic score. **(C)** A defect treated with water jet that resulted in a poor ICRS macroscopic score. Unintended water jet abrasions in the cartilage outside the defect are also seen (arrow). **(D)** A defect treated with conventional technique that resulted in a poor ICRS macroscopic score. **(E)** A safranin-O-stained histological slice, magnification 100 $\times$ , corresponding to the sample in **A** (water jet), with average staining (+). A perforation of the subchondral layer is also visible (\*). **(F)** A safranin-O-stained histological slice, magnification 100 $\times$ , corresponding with the sample in **B** (water jet) with poorly stained fibrous tissue (\*). **(G)** A safranin-O stained histological slice, magnification 100 $\times$ , corresponding with the sample in **C** (conventional microfracture) with little staining (\*), but a regular surface appearance. **(H)** A safranin-O-stained histological slice, magnification 100 $\times$ , with poorly stained fibrous tissue and a fibrillated surface.

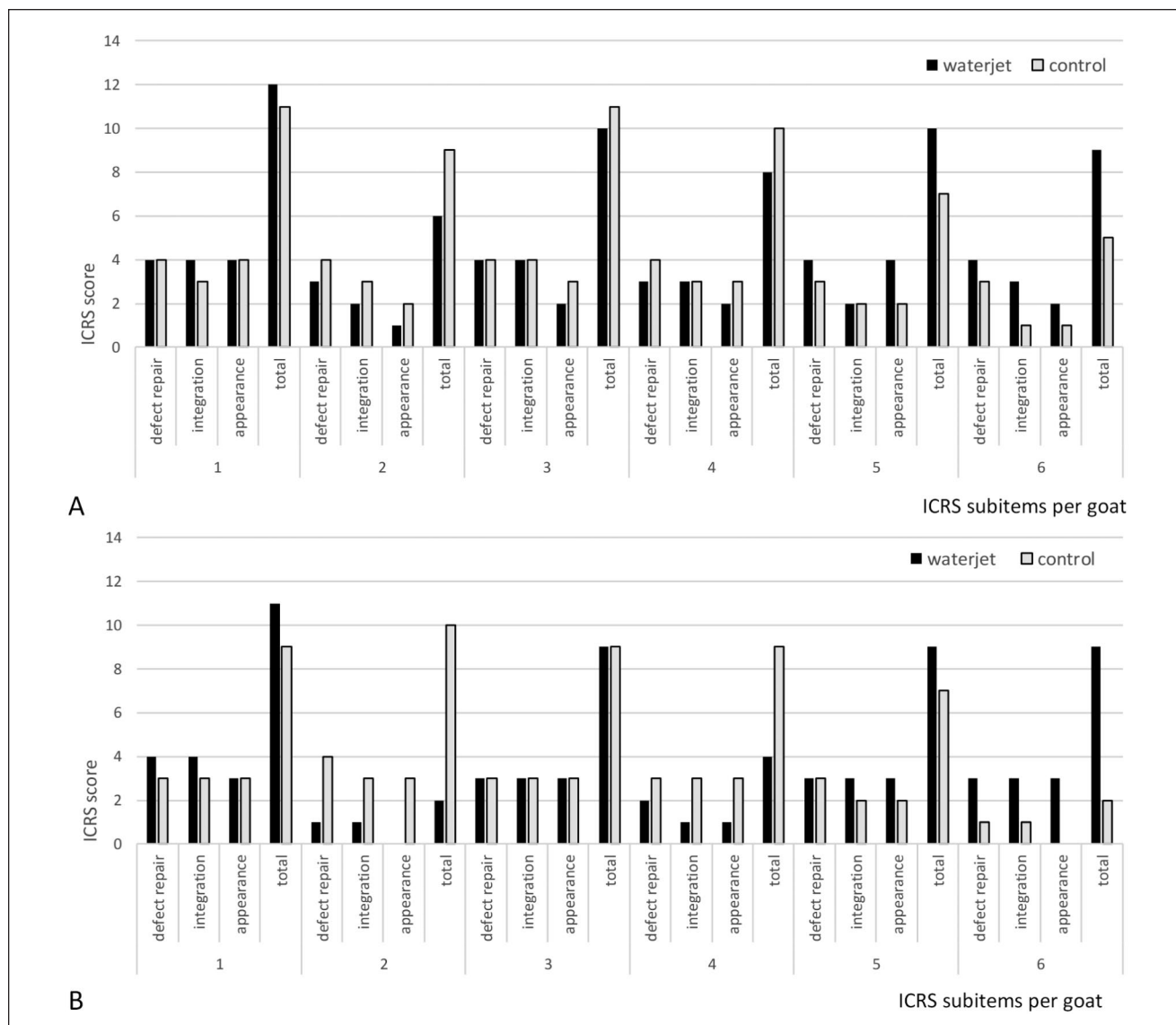
movement of the leg. Also, achieving the correct alignment of the nozzle over the defect to allow the desired geometry and perpendicular placement of the holes was hampered initially by relatively large nozzle head compared with the minimal exposure of the talus. This resulted in unsuccessful drilling in one case and undesired abrasion of cartilage outside the defect in another case (**Figs. 3D and 4**). This confirms our conclusions from previous experiments that effective water jet drilling is strongly dependent on consistent correct alignment and distance from the nozzle to the bone.<sup>8,9,38,41,42</sup>

The water jet setup was adjusted to fit a smaller and straight nozzle head, which increased maneuverability in alignment while producing a more coherent water jet beam and reducing potential pressure loss. Also, the caprine leg was more rigidly fixed to the operating table using an omni-tract during the procedure (**Fig. 2E**). These modifications contributed to a significant improvement of the amount of successfully created water jet microfracture holes.

Finally, a last challenge with the custom-made set up was that in some cases the pressure during the water jet drilling would gradually drop from the initial 50 MPa at the beginning of the water jet burst to a critical low level of 35 MPa at the end. This was due to exhaustion of the compressed air in the 300-L accumulator. As it takes a couple hours for the accumulator to fill again, this effect impaired the drilling capacity of the water jet during the procedure so that not all desired holes could be drilled.

There was one superficial wound infection in our study. However, with the limited sample size in this study, we are unable to determine the actual risk of postoperative complications when using water jet drilling in talar defects compared with regular treatment at this time. Extravasation of irrigation fluid was observed into the soft tissue surrounding the caprine ankle. This was due to backsplash and to some extent this was expected. With the current settings, approximately 130 mL of water was used per water jet burst, thus in total around 0.8 L was used per talus. Extravasation of irrigation fluid has been a commonly known issue in shoulder and hip arthroscopy.<sup>43,44</sup> It frequently leads to short-term discomfort for the patient, but true complications are rare. However, these can potentially have serious effects such as neuropraxia, increased muscle pressure leading to rhabdomyolysis, metabolic acidosis, or pulmonary edema and upper airway obstruction in the case of shoulder arthroscopy.<sup>43,45-47</sup> Neither did we encounter such complications in our study, nor did we find a relationship between the postoperative swelling and an increased risk of wound related issues. However, the majority of the backplash was able to leak out of the open surgical wound and when extrapolating this phenomenon to an arthroscopic setting where the water is introduced in a confined space, it could potentially become a complicating factor.

The one case in our study where the extravasation was particularly present also showed a low ICRS macroscopic score for both observers compared with the contralateral, conventionally treated, talus (6 vs. 9 for observer 1 and 2 vs.



**Figure 5.** ICRS (International Cartilage Repair Society) subitems and total score for each individual goat. **(A)** Observer 1. **(B)** Observer 2. The water jet treatment is shown in black bars and the conventional microfracture treatment in gray bars.

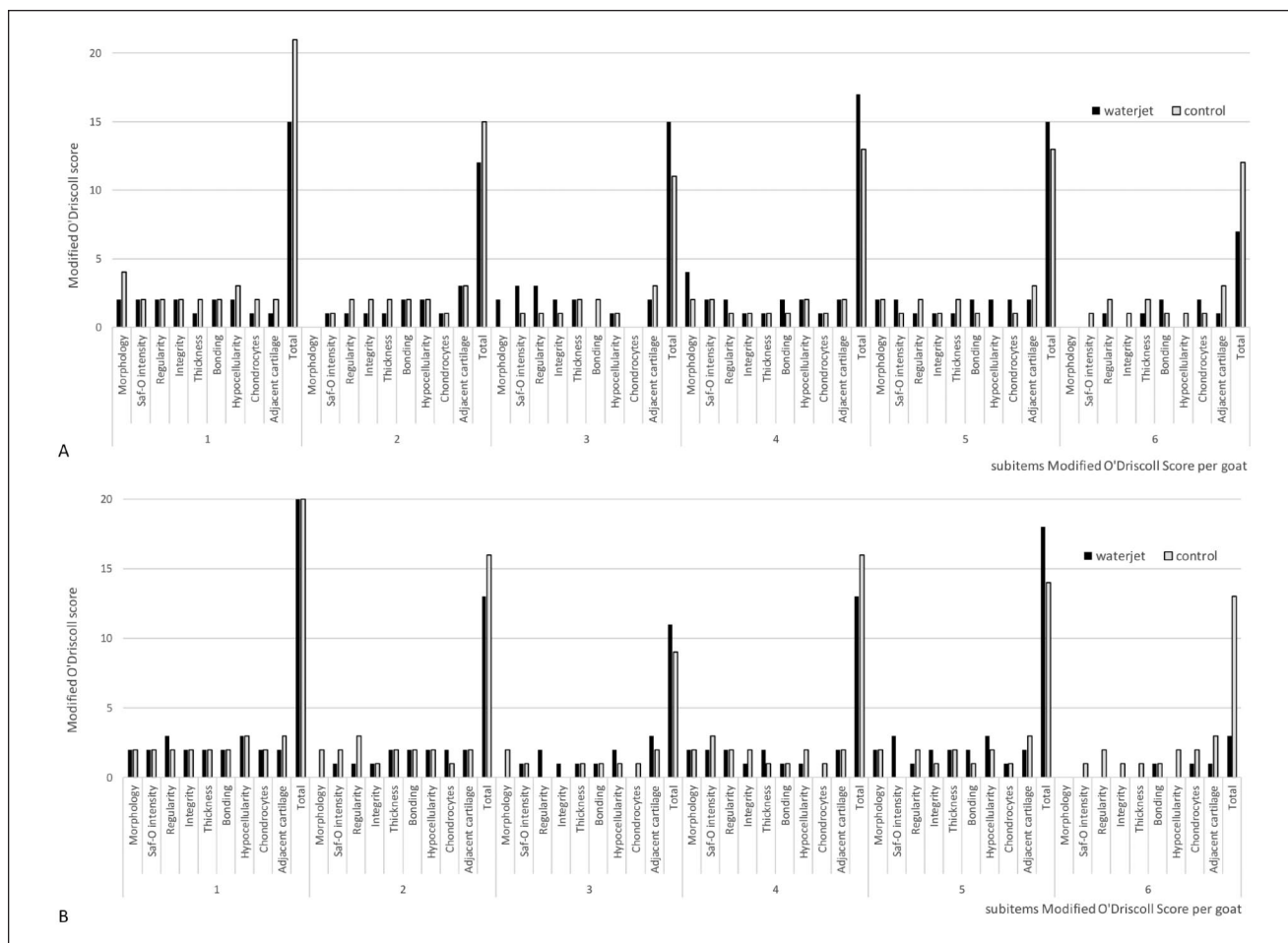
10 for observer 2) with severe fissures in the macroscopic appearance and minimal integration into the adjacent healthy cartilage (Figs. 4 and 5). The modified O'Driscoll score histological score did not show this difference but resulted in an average quality repair tissue for both tali. Therefore, it is more likely that this degraded aspect was caused by cartilage abrasion by the water jet recoil and subsequent motion of the nozzle head rather than related to the extravasation. Reliable positioning and recoil resistance of the water jet are imperative to optimize the water jet setup.

A previous *in vivo* water jet study on pigs indicated thromboembolic effects can arise due to abrasive water jet cutting, which uses a mixture of water, abrasives (hard solid cutting enhancing particles) and air (90 vol%).<sup>24</sup> In this

study, a saline solution was used instead to avoid injecting the thromboembolic-inducing air, since previous research using only saline did not hinder the ability of water jet to drill bone<sup>25,26,38</sup> and no respiratory anomalies were detected.

Analysis of quality of the repair tissue gave no clear difference in the macroscopic or microscopic quality of the repair tissue between groups apart from the subitem repair cartilage thickness of the modified O'Driscoll score for one observer in favor of the conventional treatment (Fig. 6). However, scores showed a large range of outcomes within both goats and treatment groups. This might be related to limitations of this study.

First, this is a feasibility animal model study with a limited sample size, artificially created chondral defects and an



**Figure 6.** The modified O'Driscoll scores for each individual goat. **(A)** Observer 1. **(B)** Observer 2. The water jet treatment is shown in black bars and the conventional microfracture treatment in gray bars for the total modified O'Driscoll score.

experimental setup of the water jet device, which makes the results sensitive to outliers and highlights limitations of the water jet setup. However, we believe the setup to be representative enough to have exposed major contraindications for water jet drilling in bone if present, such as severe impedance of the sterile surgical field or gross disruption of the cartilage repair process. Since no such undesired events occurred, using water jets seems to be a potentially safe alternative to the conventional rigid awls for microfracture in chondral defects. A follow-up study with the improved water jet set up and an ample sample size would shed light on the comparative results and could be designed based on the current results.

Second, visually confirming the created holes and assessing their geometry was more difficult than expected due to the small diameter of the holes and the longer time to visualize direct blood flow into the defect due to the supposedly high-pressure washout. We know from previous research that a smaller diameter of microfracture holes does not alter repair tissue quality.<sup>30</sup> Bleedings only occurred

after treatment with either surgical technique, since the initial chondral defect with intact subchondral bone layer did not show any bleedings (Fig. 3A vs. 3B and C). Therefore, water jet drilling introduces sufficient blood for the formation of fibrous repair tissue, even in this setup with its limitations. Postoperative imaging to confirm the water jet holes, using computed tomography scans for example, could have provided an objective assessment, but were deemed an unnecessary burden for the animals since extensive imaging in *ex vivo* studies has shown the ability of water jet to machine bone when the technique is used correctly.<sup>8,25,26,38,48</sup>

The next steps in the development of the water jet drilling technique will be the design of a medical pump that offers stable high pressures and a flexible arthroscopic water jet drill that is suitable for performing microfracture during an arthroscopic procedure (Fig. 1). For the former the build-up and maintenance of constant high pressure is crucial, as highlighted by this study. For the latter, consistent water jet beam coherence, stability and recoil resistance of the nozzle head



are imperative to increase reproducibility and reliability of the water jet drilling (Fig. 1). Finally, the results highlight the need to minimize water use and backsplash in order to decrease soft tissue extravasation of fluid. Several experimental studies have shown that this can be achieved with limited jet times or changing the nozzle diameter.<sup>8,26,38</sup> Once all these technical improvements are implemented, the development of the intended arthroscopic water jet surgical instrument should be tested in a solid noninferiority study.

In summary, this feasibility study indicates that water jet drilling in chondral defects in the caprine talus results in repair tissue quality that appears similar to repair tissue created using conventional microfracture awls. Additionally, the results highlight essential prerequisites for safe application of the water jet drilling technique: stable water pressure, water jet beam coherence, stable positioning of nozzle head when jetting, and minimizing excessive fluid extravasation.

## Appendix

### *Anesthesia, Pain Medication, and Euthanasia Protocols Used in This Study*

#### 1. Anesthesia

Premedication:	1.5 mg atropine/700 mg ketamine and 5 mg midazolam
Infusion:	Ringer's lactate $\pm$ 5 mL/kg/h
Induction:	Etomidate 10 to 20 mg intravenous (IV; on effect) per goat
Maintenance:	Bolus 250 $\mu$ g fentanyl IV, repeat on indication based on heart rate Bolus 15 mg midazolam IV, repeat on indication based on heart rate Isoflurane 1.5% to 2.0% per inhalation
Ventilation:	Regular air + O <sub>2</sub> (40%) Volume $\pm$ 8-10 mL/kg Frequency 14-20 times/min Percentage CO <sub>2</sub> : 4% to 4.5% Pressure: 0/12 to 0/25 cm H <sub>2</sub> O

Blood gas analysis and correction of metabolic acidosis using sodium bicarbonate 8.4%.

#### 2. Pain medication

Preoperatively: Day -1	0.6 mg/kg ketoprofen intramuscularly (IM) once daily during 3 to 5 days.
Day 0	0.6 mg/kg ketoprofen IM Epidural injection using 0.1 mg/kg morphine in 4 mL sodium chloride 0.9%
Postoperatively: Day 0	0.6 mg buprenorphine IM Buprenorphine transdermal patch
Day 1-5	0.6 mg/kg ketoprofen IM

#### 3. Euthanasia protocol

Premedication:	1.5 mg atropine/700 mg ketamine and 5 mg midazolam
Euthanasia:	Pentobarbital sodium 20 mg/kg IV

### Authors' Note

The customized set up was designed and developed at the Technical University Delft (TUD). Animal treatment was performed at the Centre for animal studies at the Vrije Universiteit Amsterdam. Histological samples were processed at the Academic Centre for Dentistry Amsterdam (ACTA).

### Acknowledgments and Funding

We thank K. W. Meyer, P. Sinnige, G. Vink, K. Opdam, T. Pahlplatz, R. van Antwerpen, M. Stijntjes and T. Crijns for their practical assistance; A. Bakker and M. van Duin for their histological processing. R. van Antwerpen is also thanked for his assisting in designing the custom-made water jet head and frame. Finally, the company Resato

is thanked for supplying the high-pressure pump. This work was supported by the Technology Foundation TTW, Applied Science Division of NWO, and the technology program of the Ministry of Economic Affairs, The Netherlands (Project No. 10851).

### Ethical Approval

The study protocol was approved by the local Animal Welfare Committees (ORCA182).

### Animal Welfare

The present study followed international, national, and/or institutional guidelines for humane animal treatment and complied with relevant legislation.



## ORCID iD

Aimee C. Kok  <https://orcid.org/0000-0001-9012-0679>

## References

- O'Loughlin PF, Heyworth BE, Kennedy JG. Current concepts in the diagnosis and treatment of osteochondral lesions of the ankle. *Am J Sports Med.* 2010;38(2):392-404. doi:10.1177/0363546509336336
- Looze CA, Capo J, Ryan MK, Begly JP, Chapman C, Swanson D, *et al.* Evaluation and management of osteochondral lesions of the talus. *Cartilage.* 2017;8(1):19-30. doi:10.1177/1947603516670708
- Zengerink M, Struijs PAA, Tol JL, van Dijk CN. Treatment of osteochondral lesions of the talus: a systematic review. *Knee Surg Sports Traumatol Arthrosc.* 2010;18(2):238-46. doi:10.1007/s00167-009-0942-6
- Steadman JR, Rodkey WG, Rodrigo JJ. Microfracture: surgical technique and rehabilitation to treat chondral defects. *Clin Orthop Relat Res.* 2001;(391 Suppl):S362-9. doi:10.1097/00003086-200110001-00033
- Dahmen J, Lambers KTA, Reilingh ML, van Bergen CJA, Stufkens SAS, Kerkhoffs GMMJ. No superior treatment for primary osteochondral defects of the talus. *Knee Surg Sports Traumatol Arthrosc.* 2018;26:2142-57. doi:10.1007/s00167-017-4616-5
- Lambers KTA, Dahmen J, Reilingh ML, van Bergen CJA, Stufkens SAS, Kerkhoffs GMMJ. No superior surgical treatment for secondary osteochondral defects of the talus. *Knee Surg Sports Traumatol Arthrosc.* 2018;26:2158-70. doi:10.1007/s00167-017-4629-0
- Kok AC, Dunnen SD, Tuijthof GJ, van Dijk CN, Kerkhoffs GM. Is technique performance a prognostic factor in bone marrow stimulation of the talus? *J Foot Ankle Surg.* 2012;51(6):777-82. doi:10.1053/j.jfas.2012.08.005
- den Dunnen S, Mulder L, Kerkhoffs GMMJ, Dankelman J, Tuijthof GJM. Waterjet drilling in porcine bone: the effect of the nozzle diameter and bone architecture on the hole dimensions. *J Mech Behav Biomed Mater.* 2013;27:84-93. doi:10.1016/j.jmbbm.2013.06.012
- Summers DA. *Waterjetting technology.* London, England: Taylor & Francis; 1995.
- Basting RF, Corvin S, Antwerpen C, Djakovic N, Schmidt D. Use of water jet resection in renal surgery: early clinical experiences. *Eur Urol.* 2000;38(1):104-7. doi:10.1159/000020261
- Cai MY, Zhou PH, Yao LQ, Xu MD, Zhong YS, Li QL, *et al.* Peroral endoscopic myotomy for idiopathic achalasia: randomized comparison of water-jet assisted versus conventional dissection technique. *Surg Endosc.* 2014;28(4):1158-65. doi:10.1007/s00464-013-3300-1
- Fritsche HM, Otto W, Eder F, Hofstädter F, Denzinger S, Chaussy CG, *et al.* Water-jet-aided transurethral dissection of urothelial carcinoma: a prospective clinical study. *J Endourol.* 2011;25(10):1599-603. doi:10.1089/end.2011.0042
- Rau HG, Meyer G, Jauch KW, Cohnert TU, Buttler E, Schildberg FW. Liver resection with the water jet: conventional and laparoscopic surgery [in German]. *Chirurg.* 1996;67(5):546-51.
- Takeuchi Y, Uedo N, Ishihara R, Iishi H, Kizu T, Inoue T, *et al.* Efficacy of an endo-knife with a water-jet function (Flushknife) for endoscopic submucosal dissection of superficial colorectal neoplasms. *Am J Gastroenterol.* 2010;105(2):314-22. doi:10.1038/ajg.2009.547
- Schumacher B, Charton JP, Nordmann T, Vieth M, Enderle M, Neuhaus H. Endoscopic submucosal dissection of early gastric neoplasia with a water jet-assisted knife: a Western, single-center experience. *Gastrointest Endosc.* 2012;75(6):1166-74. doi:10.1016/j.gie.2012.02.027
- De la Maza SF, Conrad S, Graefen M, Noldus J, Huland H. Early clinical experience with water-jet dissection (hydrojet) during nerve-sparing radical retropubic prostatectomy. *Minim Invasive Ther Allied Technol.* 2002;11(5-6):257-64. doi:10.1080/13645706.2003.11873723
- Rau HG, Duessel AP, Wurzbacher S. The use of water-jet dissection in open and laparoscopic liver resection. *HPB (Oxford).* 2008;10(4):275-80. doi:10.1080/13651820802167706
- Bibbo C. VERSAJET hydrosurgery technique for the preparation of full thickness skin grafts and the creation of retrograde split thickness skin grafts. *J Foot Ankle Surg.* 2010;49(4):404-7. doi:10.1053/j.jfas.2010.04.013
- Hreha P, Hloch S, Magurova D, Valicek J, Kozak D, Harnicarova M, *et al.* Water jet technology used in medicine. *Teh Vjesn Gaz.* 2010;17(2):237-40.
- Hloch S, Kl'oc J, Hreha P, Magurova D, Kozak D, Knapcikova L. Water jet technology using in orthopaedic surgery. *Teh Vjesn Gaz.* 2013;20(2):351-7.
- Honl M, Rentzsch R, Müller G, Brandt C, Bluhm A, Hille E, *et al.* The use of water-jetting technology in prostheses revision surgery—first results of parameter studies on bone and bone cement. *J Biomed Mater Res.* 2000;53(6):781-90. doi:10.1002/1097-4636(2000)53:6<781::aid-jbm20>3.0.co;2-g
- Honl M, Rentzsch R, Schwieger K, Carrero V, Dierk O, Dries S, *et al.* The water jet as a new tool for endoprosthesis revision surgery—an in vitro study on human bone and bone cement. *Biomed Mater Eng.* 2003;13(4):317-25.
- Honl M, Schwieger K, Carrero V, Rentzsch R, Dierk O, Dries S, *et al.* The pulsed water jet for selective removal of bone cement during revision arthroplasty [in German]. *Biomed Tech (Berl).* 2003;48(10):275-80.
- Kuhlmann C, Pude F, Bishop C, Krömer S, Kirsch L, Andreae A, *et al.* Evaluation of potential risks of abrasive water jet osteotomy in-vivo [in German]. *Biomed Tech (Berl).* 2005;50(10):337-42.
- den Dunnen S, Kraaij G, Biskup C, Kerkhoffs GMMJ, Tuijthof GJM. Pure waterjet drilling of articular bone: an in vitro feasibility study. *J Mech Eng.* 2013;59(7-8):425-32. doi:10.5545/sv-jme.2012.928
- den Dunnen S, Dankelman J, Kerkhoffs GM, Tuijthof G. Colliding jets provide depth control for water jetting in bone tissue. *J Mech Behav Biomed Mater.* 2017;72:219-28. doi:10.1016/j.jmbbm.2017.05.009
- Schmolke S, Pude F, Kirsch L, Honl M, Schwieger K, Krömer S. Temperature measurements during abrasive water jet osteotomy [in German]. *Biomed Tech (Berl).* 2004;49(1-2):18-21.

28. Chu CR, Szczodry M, Bruno S. Animal models for cartilage regeneration and repair. *Tissue Eng Part B Rev.* 2010;16(1):105-15. doi:10.1089/ten.TEB.2009.0452
29. van Bergen CJA, Kerkhoffs GMMJ, Marsidi N, Korstjens CM, Everts V, van Ruijven LJ, *et al.* Osteochondral defects of the talus: a novel animal model in the goat. *Tissue Eng Part C Methods.* 2013;19(6):449-57. doi:10.1089/ten.TEC.2012.0401
30. Kok AC, Tuijthof GJM, den Dunnen S, Van Tiel J, Siebelt M, Everts V, *et al.* No effect of hole geometry in microfracture for talar osteochondral defects. *Clin Orthop Relat Res.* 2013;471(11):3653-62. doi:10.1007/s11999-013-3189-y
31. van Bergen CJA, Kerkhoffs GMMJ, Özdemir M, Korstjens CM, Everts V, van Ruijven LJ, *et al.* Demineralized bone matrix and platelet-rich plasma do not improve healing of osteochondral defects of the talus: an experimental goat study. *Osteoarthritis Cartilage.* 2013;21(11):1746-54. doi:10.1016/j.joca.2013.07.014
32. Beardmore AA, Brooks DE, Wenke JC, Thomas DB. Effectiveness of local antibiotic delivery with an osteoinductive and osteoconductive bone-graft substitute. *J Bone Joint Surg Am.* 2005;87(1):107-12. doi:10.2106/JBJS.C.01670
33. Newton PO, Lee SS, Mahar AT, Farnsworth CL, Weinstein CH. Thoracoscopic multilevel anterior instrumented fusion in a goat model. *Spine (Phila Pa 1976).* 2003;28(14):1614-20.
34. Saris DB, Dhert WJ, Verbout AJ. Joint homeostasis. The discrepancy between old and fresh defects in cartilage repair. *J Bone Joint Surg Br.* 2003;85(7):1067-76.
35. Kruyt MC, Dhert WJ, Oner FC, van Blitterswijk CA, Verbout AJ, de Bruijn JD. Analysis of ectopic and orthotopic bone formation in cell-based tissue-engineered constructs in goats. *Biomaterials.* 2007;28(10):1798-805. doi:10.1016/j.biomaterials.2006.11.038
36. Jackson DW, Lalor PA, Aberman HM, Simon TM. Spontaneous repair of full-thickness defects of articular cartilage in a goat model. A preliminary study. *J Bone Joint Surg Am.* 2001;83-A(1):53-64.
37. Tuijthof GJM, van den Boomen H, van Heerwaarden RJ, van Dijk CN. Comparison of two arthroscopic pump systems based on image quality. *Knee Surg Sports Traumatol Arthrosc.* 2008;16:590-4. doi:10.1007/s00167-008-0513-2
38. den Dunnen S, Dankelman J, Kerkhoffs GMMJ, Tuijthof GJM. How do jet time, pressure and bone volume fraction influence the drilling depth when waterjet drilling in porcine bone? *J Mech Behav Biomed Mater.* 2016;62:495-503. doi:10.1016/j.jmbbm.2016.05.030
39. Brittberg M, Peterson L. Introduction of an articular cartilage classification. *ICRS Newslett.* 1998;(1):5-8.
40. O'Driscoll SW, Marx RG, Beaton DE, Miura Y, Galloway SH, Fitzsimmons JS. Validation of a simple histological-histochemical cartilage scoring system. *Tissue Eng.* 2001;7(3):313-20. doi:10.1089/10763270152044170
41. Tikhomirov RA, Petukhov EN, Babanin VF, Starikov ID, Kovalev VA, Birman V. High-pressure jetcutting. New York: ASME Press; 1992.
42. Morad S, Ulbricht C, Harkin P, Chan J, Parker K, Vaidyanathan R. Modelling and control of a water jet cutting probe for flexible surgical robot. 2015 IEEE International Conference on Automation Science and Engineering; 2015 Aug 24-28; Gothenburg, Sweden. p. 1159-64.
43. Ekhtiari S, Haldane CE, de Sa D, Simunovic N, Ayeni OR. Fluid extravasation in hip arthroscopy: a systematic review. *Arthroscopy.* 2017;33(4):873-80. doi:10.1016/j.arthro.2016.11.009
44. Lo IKY, Burkhart SS. Immediate postoperative fluid retention and weight gain after shoulder arthroscopy. *Arthroscopy.* 2005;21(5):605-10. doi:10.1016/j.arthro.2005.01.008
45. Borgeat A, Bird P, Ekatothramis G, Dumont C. Tracheal compression caused by periarticular fluid accumulation: a rare complication of shoulder surgery. *J Shoulder Elbow Surg.* 2000;9(5):443-5. doi:10.1067/mse.2000.109320
46. Mohammed KD, Hayes MG, Saies AD. Unusual complications of shoulder arthroscopy. *J Shoulder Elbow Surg.* 2000;9(4):350-3. doi:10.1067/mse.2000.106319
47. Lim JK, Ang KC, Wang SC, Kumar VP. Rhabdomyolysis following shoulder arthroscopy. *Arthroscopy.* 2006;22(12):1366.e1-e5. doi:10.1016/j.arthro.2006.04.089
48. Bach FW, Biskup C, Kremer G, Schmolke S. Investigation of the AWIJ-drilling process in cortical bone. Proceedings of the 2007 American WJTA Conference and Expo; 2007 Aug 19-21; Houston, TX.