



## Surgical Technique

## One and a Half-Stage Revision With Prosthetic Articulating Spacer for Definitive Management of Knee Periprosthetic Joint Infection

Ahmed Siddiqi, DO, MBA <sup>a, b, c</sup>, Yusuf Mahmoud, MD <sup>b</sup>, Salvador A. Forte, DO <sup>d</sup>, Thomas A. Novack, MD <sup>e</sup>, James Nace, DO, FAOAO, MPT <sup>e, \*</sup>

<sup>a</sup> Orthopedic Institute Brielle Orthopaedics, A Division of Ortho NJ, Manasquan, NJ, USA

<sup>b</sup> Hackensack Meridian School of Medicine, Nutley, NJ, USA

<sup>c</sup> Hackensack Meridian Health Edison, NJ, USA

<sup>d</sup> Department of Orthopedic Surgery, Philadelphia College of Osteopathic Medicine, Philadelphia, PA, USA

<sup>e</sup> Rubin Institute for Advanced Orthopedics, Sinai Hospital of Baltimore, Baltimore, MD, USA

## ARTICLE INFO

## Article history:

Received 16 April 2022

Received in revised form

26 June 2022

Accepted 8 July 2022

Available online xxx

## Keywords:

Periprosthetic joint infection

Staged revision

Total knee arthroplasty

TKA spacer

TKA

## ABSTRACT

This paper is a comprehensive review that describes indications, contraindications, clinical outcomes, and pearls and pitfalls of 1.5-stage revision total knee arthroplasty (TKA) utilizing a primary TKA femoral component, all-polyethylene tibial component, and hand-crafted antibiotic cement for the management of chronic periprosthetic joint infection. The 1.5-stage exchange TKA details placement of an articulating spacer for an indefinite period, prolonging revision until reinfection, deterioration of functional status, or construct failure. A 1.5-stage revision TKA technique is a viable option for treatment of chronic periprosthetic knee infections. The inherent advantages of decreased health-care costs, decreased morbidity and mortality, and improved emotional ease from having a single procedure is attractive, especially if reinfection rates are determined to be equivocal to 2-stage revision.

© 2022 The Authors. Published by Elsevier Inc. on behalf of The American Association of Hip and Knee Surgeons. This is an open access article under the CC BY-NC-ND license (<http://creativecommons.org/licenses/by-nc-nd/4.0/>).

## Introduction

Periprosthetic joint infection (PJI) remains a serious problem resulting in significant morbidity and mortality to patients and increased health-care costs [1]. PJI has an estimated prevalence of up to 3% in total knee arthroplasty (TKA) [1]. TKA is one of the most common procedures performed in the United States with PJI projections reaching 10,000 by 2030, [2] and PJI is the most common cause of early failure after TKA [1]. Typically, surgical management is indicated for PJI, with multiple different techniques being described [3,4]. The goal of revision surgery is complete eradication of infection with preservation of knee function.

Historically, 2-stage revision TKA was the gold standard for treatment of chronic PJI, [4] with success rates varying in the

literature from 73% to 96% [5]. Originally described by Insall et al. [6] in 1983, a variety of different techniques have been described, including static spacer, preformed molds, and other hand-crafted spacers [4,5,7]. The long-term functional data after replantation have also deemed this treatment a success; however, interim functional outcomes between procedures are not as promising [8]. More recently, there have been promising results demonstrating equivocal reinfection rates of 1-stage revision TKA compared to 2-stage revision [9–16] (Table 1).

Single-stage revision TKA was originally described by Borden and Gearen in 1987, and it is currently gaining popularity as a viable alternative associated with decreased patient morbidity and mortality, shorter hospital length of stay, improved functional scores, and decreased health-care costs [9]. Much of the early literature for these techniques came from Europe, while there has been a recent increase in popularity in North America [4]. A meta-analysis of 687 patients with chronic TKA PJI concluded an 87.1% eradication rate [4]. This procedure entails resection of infected TKA components with subsequent thorough debridement and implantation of revision TKA components in a single surgery. Subsequent PJI after single-stage revision TKA can

\* Corresponding author. Rubin Institute for Advanced Orthopedics, Sinai Hospital of Baltimore, 2401 W. Belvedere Ave., Baltimore, MD 21215, USA. Tel.: +1 410 601 7573.

E-mail address: [Jnace@lifebridgehealth.org](mailto:Jnace@lifebridgehealth.org)

**Table 1**  
Eradication rates of recent 1-stage and 2-stage revision TKA studies for chronic PJI.

| Author                | Year | Stage     | Spacer type  | Patients (n) | Mean follow-up (y) | Eradication rate (%) |
|-----------------------|------|-----------|--|--------------|--------------------|----------------------|
| Haddad et al. [9]     | 2015 | Two stage | Articulating antibiotic-loaded cement spacer   | 74           | 6.5                | 93                   |
| Lichstein et al. [10] | 2016 | Two stage | Static spacer  | 121          | 3.7                | 94                   |
| Massin et al. [11]    | 2016 | Two stage | Static spacer  | 177          | 4.6                | 69                   |
| Siddiqi et al. [12]   | 2019 | Two stage | All cement articulating spacer   | 137          | 4.6                | 70.8                 |
| Petis et al. [13]     | 2019 | Two stage | 240 (98%) nonarticulating spacer, 5 (2%) articulating spacer (femoral component, all-poly tibia) | 245          | 14                 | 83                   |
| Tibrewal et al. [14]  | 2014 | Single    | —  | 50           | 10.5               | 92                   |
| Zahar et al. [15]     | 2016 | Single    | —  | 46           | 10                 | 90                   |
| Haddad et al. [9]     | 2015 | Single    | —  | 28           | 6.5                | 100                  |
| Massin et al. [11]    | 2016 | Single    | —  | 108          | 3.5                | 77                   |
| Jenny et al. [16]     | 2016 | Single    | —  | 114          | 3.2                | 61.8                 |

be devastating, requiring further surgeries with resection of revision components. This is both costly and, more importantly, morbid to the patient. The 1.5-stage revision TKA offers the patient a well-functioning articulating spacer *possibly delaying a second procedure indefinitely*. However, if a second procedure is ultimately needed, the resection of the spacer will be more facile than revision components, *possibly more cost-effective*, and preserve more bone, incurring less morbidity to the patient. The 1.5-stage exchange TKA details placement of a prosthetic articulating spacer intended to remain for an indefinite period, prolonging revision until reinfection, deterioration of functional status, or construct failure from aseptic loosening. *Our institutional results of this novel technique have demonstrated 85% infection-free survivorship at nearly 3 years [10]*.

This paper is a comprehensive review that describes indications, contraindications, clinical outcomes, and pearls and pitfalls of 1.5-stage revision TKA utilizing a primary TKA femoral component, all-polyethylene tibial component, and hand-crafted antibiotic cement for the management of chronic PJI (<https://www.vumedi.com/video/15-stage-revision-with-prosthetic-articulating-spacer-for-the-definitive-management-of-knee-peripros/>).

### Indications

Treatment of PJI is a multifactorial decision-making process based on bacterial identification, virulence, health of host, bone and soft-tissue quality, and timing of symptoms. Currently, single-stage exchange may be reserved for patients unable to tolerate 2 surgeries or for patients with minimal or no comorbidities with an identified low-virulent organism and a reasonable soft-tissue window [5,9,11]. Higher failure rates have been reported for single-stage revision in patients with fungal and gram-negative infections, as well as patients with multiple medical comorbidities [12]. The indications for 1.5-stage exchange TKA in treating chronic PJI are broad because it offers preserved knee function and local concentration of antibiotics, with the ability to perform a second-stage if needed [13,14]. The indications will continue to evolve potentially including culture-negative infections: In a recent study, single-stage exchange TKA revision showed comparable outcomes to 2-stage exchange TKA revision in chronic culture-negative PJI [15]. All hosts and organisms may be considered for this technique.

### Contraindications

The major contraindications are massive bone loss, loss of extensor mechanism, collateral ligament insufficiency resulting in gross instability, or failure of multiple articulating spacers. In such cases, a static antibiotic spacer is typically recommended. Relative

contraindications include extensive soft-tissue loss precluding primary closure of wound, antibiotic-resistant organisms, and presence of a sinus tract [13].

### Preoperative evaluation

Preoperative evaluation necessitates a thorough surgical history, assessment of medical comorbidities, radiographic evaluation, physical examination, and diagnostic evaluation for PJI. Surgical history should include any surgical interventions prior to the index procedure and history of prior PJI with subsequent management including any antimicrobials that were administered. Efforts should be made to obtain prior office notes and operative notes to glean information regarding previous implant selection and any intraoperative difficulties or perioperative complications such as draining sinuses or wound healing issues. Timing of symptoms from the index procedure, greater than 3 months, and symptom duration, greater than 6 weeks, are used to differentiate acute from chronic PJI [16]. *Some studies have reported the cutoff between acute and chronic PJI with symptom duration as early as 3 weeks [17]*. History of recent dental procedures or invasive hematogenous procedures should also be noted. Radiographic preoperative evaluation includes bilateral weight-bearing anteroposterior, lateral and sunrise radiographs to assess for radiolucencies, gross bone loss, level of constraint, and implant selection. A CT scan or nuclear study is not routinely used.

A thorough physical exam includes inspection of skin for integrity, sinus tracts, previous scars, erythema, and swelling. This soft-tissue envelope assessment is essential. Visual gait analysis can detect gross dynamic knee instability throughout ambulation. A full knee examination assesses passive and active range of motion, flexion contracture, flexion-extension instability, and varus-valgus laxity or deformity.

All patients should be medically optimized prior to surgery, and a full panel of labs should be obtained including complete blood count, complete metabolic panel, erythrocyte sedimentation rate, C-reactive protein, thyroid-stimulating hormone, vitamin-D levels, and *nutritional labs (albumin, prealbumin)*. Particular attention should be paid to preoperative kidney function, as nephrotoxic antibiotics are typically utilized in the perioperative period, and acute kidney injury has been reported after knee surgery and *spacer implantation [18,19]*.

Patients are typically diagnosed with PJI using the most recent Musculoskeletal Infection Society Definition of PJI [16]. Per the International Consensus Meeting, ideally the organism should be identified preoperatively and susceptible to antibiotics [16].

## Surgical technique

### Setup

The patient is placed in the supine position, all bony prominences are padded, and the nonoperative leg is appropriately secured to the table. A nonsterile thigh tourniquet is applied to the operative extremity prior to skin preparation and draping unless a sterile tourniquet is needed depending on the length of the prior incision. Perioperative antibiotics are administered based on preoperative aspiration cultures. In culture-negative infections, it is the authors' standard protocol to administer weight-based cefazolin and 1 gram of vancomycin prior to incision. One gram of tranexamic acid is also routinely given intravenously prior to the procedure at the discretion of the anesthesiologist and surgeon. The previous incision is delineated using a sterile marking pen, and an antimicrobial incision drape is applied. Two sterile tables are utilized including instruments, gowns, gloves, and drapes. The second "clean" setup is covered during the "first stage" of the procedure.

### Approach

The previous incision is most often used; however, if multiple incisions are present, the most lateral incision is utilized, as the main blood supply to the skin over the anterior knee comes from the medial aspect of femoral and popliteal vessel anastomosis. Allow for at least a 6-cm skin bridge between incisions to avoid skin necrosis and subsequent wound complications. If there are transverse incisions, be sure to make your incision at 90 degrees to said incision, and no less than a 60-degree angle should be created. Develop thick medial and lateral flaps to preserve vascularity and perform medial parapatellar arthrotomy. *It is important to create subfascial flaps as the creation of subcutaneous flaps are likely to result in wound complications.* Extensile exposure may be achieved with a quadriceps snip, V-Y turndown, or tibial tubercle osteotomy.

Upon entering the knee joint, initial exposure can be aided by performing a generous medial release past the mid-sagittal line. It is important to be cognizant of medial and lateral dynamic and static stabilizers when performing synovectomy and extensive debridement of medial and lateral gutters. Take a minimum of 5 tissue samples for aerobic and anaerobic cultures with additional fungal and acid-fast bacillus cultures if clinically warranted.

### Technique

#### Removing components

Several different techniques and tools are available for component removal, but the typical progression is to remove the modular tibial polyethylene, followed by the femoral component and then the tibial baseplate. The patellar component is usually removed last to protect the extensor mechanism during removal of other components. All efforts should be made to minimize iatrogenic bone loss during component removal along the prosthesis-cement interface rather than the cement/bone interface. The author's preferred method is to use a 13 × 90 × 1.37-mm sagittal saw blade as the workhorse for removing the components along the cement-implant junction. Small osteotomes may be used for the posterior femoral condyle interface. Once the adhesion between prosthesis and cement has been disrupted, use appropriate extraction tools to remove the components. A small white-handled curved bone tamp and mallet will facilitate removal. Remove all cement from the remaining bone and intramedullary canal with a long pituitary rongeur, rigid or flexible reamers, and an intramedullary canal brush. It may be prudent to have a diamond-tipped saw or burr, a


cement removal set, or even ultrasonic devices for cement removal. Making note of the explanted component sizes and preoperative templating of the contralateral nonoperative knee can aid in determining appropriate implant sizes for reconstruction.

### Debridement

Perform a complete synovectomy and extensive debridement of all nonviable tissues including cement, bone, tendon, fascia, subcutaneous tissue, and capsule. Remove intramedullary cement with osteotome, curettes, and cement extractor tools. Complete removal of cement may require a drill or flexible reamer over a long guidewire. Be sure to preserve collateral ligaments and the extensor mechanism during excisional debridement to allow for implantation of an unconstrained prosthesis. Thorough irrigation and debridement of the wound is a crucial step in the process. Several different irrigant solutions and combinations have been proposed and reviewed, including chlorhexidine, povidone-iodine, as well as commercial irrigant adjuncts, without 1 solution conferring a distinct advantage. However, certain irrigation solutions, and their combinations, have been found to be potentially harmful [20–22]. It is the authors' preferences to irrigate the wound using low-pressure pulsatile lavage with at least 9 liters of 0.9% normal saline in conjunction with a triple-wash full-strength povidone-iodine solution. A femoral canal brush with the handle cut is chucked on to a power drill and used for further mechanical debridement of both femoral and tibial canals (Fig. 1).

### Reconstruction

Prosthetic articulating knee spacers have been utilized for several years, with the advent of several technique modifications as the procedure has become more popular [23]. The goal of this procedure is to reconstruct a balanced knee by making freshening osteotomies to produce neutral alignment and balanced gaps while being able to eradicate the infection. Recently, a gap-balancing technique has been described, in which the authors create a stable tibial cut, restore the distal femoral cut, and then use gap tensioners and metallic augments to balance the joint [23]. With our technique, we utilize a tibial osteotomy based on tibial anatomy and preoperative templating along with a combination of measured resection and soft-tissue balancing techniques. A neutral tibial osteotomy is created to obtain a stable tibial platform; this can be done either using an intramedullary or extramedullary cutting guide or by hand. Proper rotation of the tibial component is established using the tibial tubercle and a floating trial as references. Proper rotation of the femur is established using the trans-epicondylar axis, and rotation is confirmed based on the neutral tibia osteotomy in flexion. Soft-tissue releases may be performed to obtain soft-tissue balance. It is important to note the gaps since the largest available all-polyethylene tibial thickness is typically approximately 16 mm. Some manufacturers make a full-tibial 5- to 10-mm augment that the all-polyethylene tibial keel will fit through. This can be used to "build up" the tibial side in cases of massive bone loss. *Antibiotic cement buildup can also be used for the spacers to remain cost-effective.* The tibial sizing is based on optimal tibial coverage. The femoral size is determined based on having approximately 1- to 2-mm cement mantle. In addition, one must be cognizant to restore posterior condylar offset since some posterior bone loss is likely present. In extreme cases, we have employed short femoral stems, posterior condyle augments, and/or distal augments. For the tibia, a tibial Schanz or Knowles pin can be drilled into and attached to the bottom of the all-polyethylene tibia to act as a stem if needed when bone loss is significant [3]. The trial is then built and preliminarily placed to make sure it will fit



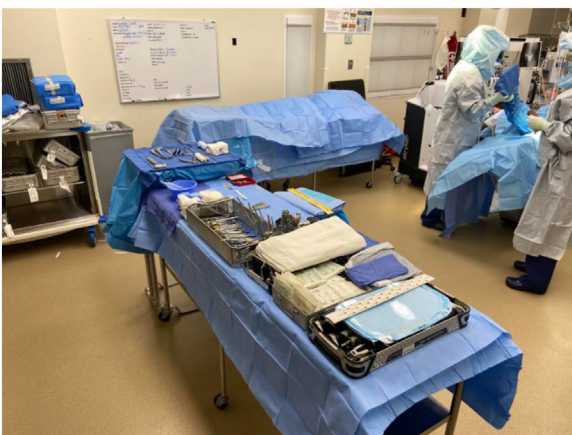
**Figure 1.** Chucked femoral canal brush.

appropriately and to allow the surgeon to evaluate the soft-tissue balance. We typically use cruciate-retaining polyethylene trials, even if a posterior-stabilized final implant is intended, to allow for a better assessment of balance.

Once a clean wound bed is established, the entire surgical team rescrubs, regowns, and regloves. A blue surgical towel is placed over the wound, and 1 assistant stays “contaminated” to hold the extremity with slight traction. The operative leg is repped while a new down sheet, split sheets, stockinette, and then finally extremity drape are placed. All previous surgical instruments are isolated on a separate table and noted as contaminated. A new sterile setup with new instrumentation is obtained for implantation (Fig. 2).

#### *Implantation of articulating spacer*

A trial with the final components is performed prior to cementation for confirmation of alignment and size. The author



**Figure 2.** “Contaminated” table covered with a sterile drape, and a new “clean” table with new sterile instrumentation.

typically implants a metal femoral component and an all-polyethylene tibial component. Antibiotic calcium sulfate beads (STIMULAN; Biocomposites, Wilmington, NC) are placed in the canal prior to implantation. The final femoral component and all-polyethylene tibial component are cemented using a third-generation cement technique. The implants are cemented in with a dry bone surface to allow for stable components and to ensure spacer longevity. Typically, 2–4 bags of cement are mixed according to bone loss. Mix the powder and polymer first and then add the antibiotics for better elution. Each 40-gram bag of cement is hand-crafted with culture-specific, heat-stable antibiotics, which often include vancomycin, gentamycin, and tobramycin. A typical 40-gram bag of cement contains 1 gram of vancomycin powder and an additional 2.4 grams of tobramycin antibiotic powder to ensure approximately 10% antibiotic concentration [24]. In the case of a fungal infection, several different antifungals can be utilized, including voriconazole, fluconazole, and amphotericin B, with the appropriate medication and dosage based on the identified fungus [14]. Extra care must be taken to cement the components in the correct alignment and rotation due to preexisting bone loss. The surgeon must confirm and maintain the rotation and alignment when impacting the components while allowing the cement to cure. For instance, a plastic impactor along the lateral femoral flange can be utilized to maintain external femoral rotation while holding the knee in extension without excessive compression. The tibia and femur can be cemented in 2 separate batches if maintaining alignment poses a challenge. Once cured, excess cement around the rim is carefully removed with an osteotome, making sure not to disrupt the cement mantle.

#### *Closure*

The wound is once again copiously irrigated with normal saline. A standard multilayer closure of the arthrotomy, subcutaneous tissue, and skin is performed with monofilament sutures. Antibiotic calcium sulfate beads are placed along the capsule prior to closure. A recent systematic review has reported favorable results with the use of beads as an adjunct in the treatment of PJI [25]; however, the

literature is not robust enough to declare their superiority as a treatment. Furthermore, adverse outcomes including persistent wound drainage, purulent exudate, and local tissue irritation have been reported when large volumes—greater than 30 cc—of these beads are used or when placed in a subcutaneous position [25]. Vancomycin powder can also be placed during multilayer closure, which has been reported to decrease early postoperative infections after revision arthroplasty [25]. Our preferred technique is to leave the antibiotic powder coarse as this may increase its elution properties. Closed incisional negative pressure wound therapy is used in obese patients (body mass index >35) or those with a tenuous closure for 7 days. A recent randomized clinical trial has shown that this may decrease the rate of wound complications in these higher risk patients [26]. A large compressive ace wrap is placed. The patient is allowed to bear weight as tolerated with full range of motion. If there is concern for soft-tissue compromise requiring a period of rest/immobilization, patients wear a knee immobilizer or a hinged knee brace locked in extension for 2–6 weeks. Standard postoperative radiographs are taken in the recovery room (Fig. 3).

### Postoperative considerations

Postoperatively, broad-spectrum antibiotics are continued intravenously and transitioned to culture-specific therapy for an average of 6 weeks or until a downtrend in erythrocyte sedimentation rate and C-reactive protein is established. Infectious disease consultation is typically obtained, unless the infectious agent and specific sensitivities are known. Routine clinical and radiographic examinations are performed periodically, looking for clinical signs of infection, instability, or failure of the prosthesis. Bilateral standing anteroposterior, lateral, and sunrise radiographs are taken at 6 weeks postoperatively and then every 3 months up to 1 year to look for signs of interval alignment changes, loosening, or osteolysis. After the 1-year follow-up visit, this interval is increased to every 6 months. Second-stage revision is not considered unless infection recurs or clinical or radiographic failure occurs from reported increased pain and radiographic evidence of loosening. Well-functioning prosthetic articulating spacers are retained with

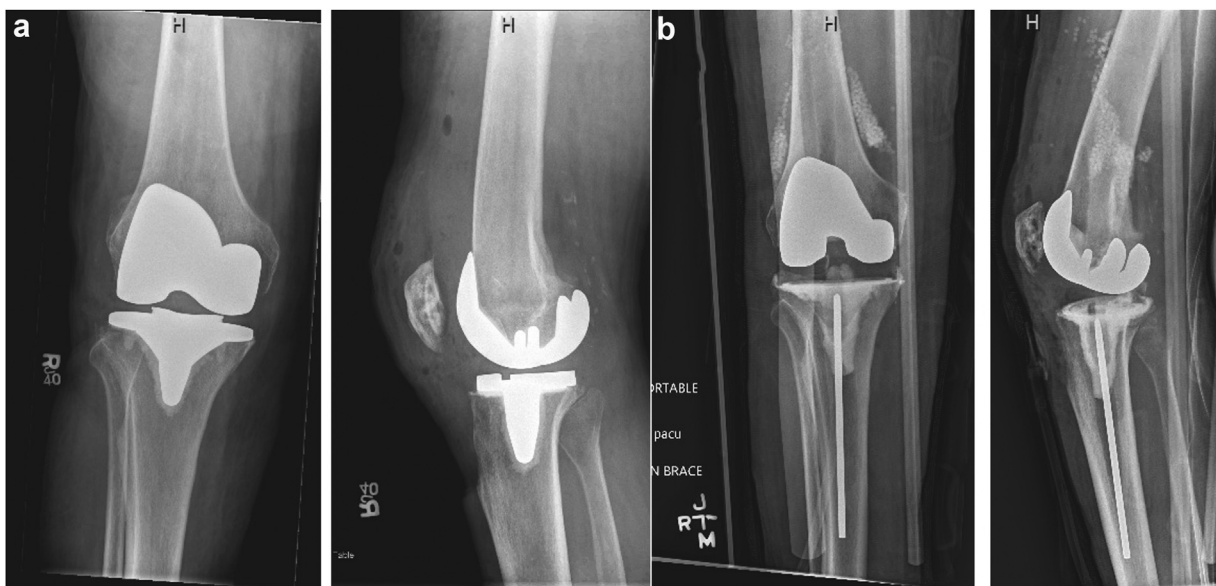
periodic clinical and radiographic follow-up as described above, with the caveat that the patient should return immediately for re-evaluation if they experience a change in their clinical status.

### Cost

One of the major benefits of using a 1.5-stage prosthetic antibiotic TKA spacer is the cost saving by potentially avoiding a second revision surgery. Previous literature has demonstrated the increased costs of using a knee spacer with explantation and replantation stages, particularly in comparison with aseptic revision [27]. Further studies have also supported that a 1-stage revision not only leads to lower overall costs but also is cost-effective compared to a 2-stage approach [27]. There is also the emotional cost of doing multiple surgeries in a short interval time period, as revision surgery has been shown to be related to decreased emotional health and satisfaction [28]. There is a “psychological savings” for the patient knowing that another procedure will not have to be performed a few months after the first stage. This allows for more normal recovery and rehabilitation and allows the patient to be able to get back to their life, and employment, on a more regular schedule. Another important aspect of the procedure is being able to apply the appropriate procedural codes. While any procedure for PJI can pose its inherent challenges to the surgeon and patient, remuneration and coding is an important aspect to discuss. The authors typically code as an “extensive excisional debridement including deep tissue, tendon and bone of tibia, femur and patella, revision TKA using permanent components, and application of handcrafted antibiotic cement”, which captures the true complexity of the case.

### Clinical outcomes

This technique has shown excellent short-term outcomes and promising midterm results. In evaluating 31 chronic PJI cases treated with 1.5-stage exchange TKA using a cobalt–chrome femoral component and an all-polyethylene tibial component, Hernandez et al. [28] noted a 16% reimplantation rate and a 90% PJI eradication



**Figure 3.** (a) Preoperative anteroposterior and lateral radiographs of a patient with a right total knee periprosthetic joint infection. (b) Postoperative radiographs of a right knee after placement of an articulating antibiotic spacer. Note that cruciate-retaining components were used, as the patient had a functional posterior cruciate ligament. Absorbable antibiotic beads (STIMULAN; Biocomposites, Wilmington, NC) can also be appreciated.

rate at a mean follow-up of 2.7 years. Reimplantation occurred at a mean of 1.5 years after placement of the initial articulating spacer. Additionally, of the 5 knees that were reimplanted, none showed radiographic evidence of loosening, and none were clinically loose on reimplantation. These 5 elective reimplantations were due to persistent pain and instability [29]. Similarly, Zamora et al. [29] evaluated 19 chronic PJI cases treated with 1.5-stage TKA exchange arthroplasty, and at a mean 3.7 years of follow-up, infection was eradicated in 90%, and 26% had reimplanted for recurrent pain and instability after 12 months. Furthermore, infection rate, knee range of motion, and quality of life score differences between 1.5-stage exchange and 2-stage exchange arthroplasties were not statistically significant [30]. Choi et al. [31] evaluated 7 patients with unplanned retained articulating TKA spacers, and at a mean 2.64 years of follow-up, 86% eradicated the infection and retained their spacer with good pain control and knee function [31].

In a multicenter study, Siddiqi et al. [13] evaluated 57 chronic PJI cases treated with a retained articulating spacer, and at a mean of 4.4 years, 78.9% eradicated the infection. The retained spacer cohort demonstrated noninferiority in reinfection and reoperation rates to the conventional 2-stage revision group. Due to pain and unsatisfactory postoperative motion, 38.6% of patients elected to have the second-stage reimplantation at a mean of 4.4 years. Both 1.5-stage and 2-stage exchange cohorts had comparable mean final range of motion of 105.8 and 101.8 degrees, respectively, [13].

It is important to note that reimplantation is not considered a treatment failure. The 1.5-stage exchange arthroplasty allows for a second stage to occur with the goal of PJI eradication and preserved knee function. This surgery is proposed to the patient as the initial stage of a 2-stage exchange arthroplasty but with plans to maintain the articulating spacer in situ for as long as the patient tolerates or until infection recurs or the implant fails. This novel technique results in competitive success rates compared to 1- and 2-stage exchange arthroplasty with the clinical difference that it prevents infection-free patients with maintained knee function from undergoing a potentially avoidable surgery.

#### Case series

More recently, our own institutional cohort review analyzed all patients undergoing 1.5-stage ( $n = 114$ ) and 2-stage TKA exchange ( $n = 48$ ) with a mean 2.6-year follow-up [10]. The infecting organism profile was similar between the 2 groups (*Staphylococcus coagulase negative*, 14.9% vs 16.7%, respectively; methicillin-sensitive staphylococcus aureus (MSSA) 13% vs 12.5%, respectively; methicillin-resistant staph aureus (MRSA) 11.4% vs 10.4%, respectively; culture negative 36% vs 44%, respectively). The 1.5-stage exchange TKA resulted in a 10.1% difference in infection-free survival (85.1% vs 75.0%,  $P = .158$ ) compared to 2-stage exchange. Postoperative complications were lower among 1.5-stage exchanges (8.8% vs 31.3%,  $P < .001$ ) while The Knee Injury and Osteoarthritis Outcome Score, Joint Replacement (KOOS, JR) scores improved more from baseline in the 1.5-stage group (24.7-point difference vs 16.6-point difference,  $P < .001$ ) than those in the 2-stage cohort. At our institution, we have found that 1.5-stage exchange may be an effective alternative to the traditional 2-stage exchange with noninferior infection eradication and lower postoperative complications.

#### Pearls and pitfalls

There are several surgical “pearls” that the authors have discovered over the past several years. The most important aspect of the surgery is to do a thorough debridement, but care must be taken to preserve collateral ligaments, if possible. As a draping tip, when changing to the “clean” setup, have 1 person stay

“contaminated” and support the leg while everyone else changes and places new drapes; then the leg can be prepped and then passed off to a “clean” person. When evaluating joint line restoration in cases of bone loss, several different techniques can be employed, including utilizing the location of the meniscus scar, location of patella, or measuring approximately 28 mm from medial epicondyle and 24 mm from lateral epicondyle. When placing the femoral component, pay attention to the anterior flange and, if necessary, apply posterior pressure on the lateral flange to prevent the femoral component from internally rotating and anteriorization of the femoral component, as posterior condylar bone loss is not uncommon. Finally, when allowing the cement to cure, hold the leg in extension but do not apply excessive axial pressure, as it could cause slight subsidence of the components in the weaker subchondral bone and cause the knee to be too loose or unstable.

There are also several issues that we have learned to avoid during the procedure. Many surgeons make the error of rushing to remove components and place trials; performing a satisfactory debridement of all surfaces is paramount in resolution of the infection. When evaluating bone loss and sizing trial components, it may be necessary to place augments—particularly distal or posterior femur—in order to attain proper bone contact and gap balance; do not rely on cement to fill (>4 mm) sites of excessive bone loss when augments are available. Finally, when cementing, be meticulous and always check in the back of the joint prior to closure, as cement used to correct small posterior condylar defects may escape posteriorly.

#### Summary

A 1.5-stage revision TKA technique is a viable option for treatment of chronic periprosthetic knee infections (Table 2). The inherent advantages of decreased health-care costs, decreased morbidity and mortality, and improved emotional ease from having a single procedure are attractive, especially if reinfection rates are determined to be equivocal to 2-stage revision [13]. Further studies are needed to determine the generalizability and indications of performing a 1.5-stage revision as treatment for chronic PJI in TKA. The author's current practice is to perform this 1.5-stage revision technique on nearly all patients with PJI unless there is significant soft-tissue or bony compromise. We have found that this technique provides patients a knee with excellent function and avoids the need to quickly plan the next revision surgery. If a second stage is ever required in the future, this can be done on a more-elective basis with more emotional ease and ample time for patient and surgeon planning.

#### Conflicts of interest

Mr. Ahmed Siddiqi is a paid consultant for Zimmer Biomet and Intellijoint Surgical; is an unpaid consultant for AZSolutions,

**Table 2**

Grades of recommendation for the management of chronic periprosthetic TKA infections.

| Reconstruction     | Grade of recommendation |
|--------------------|-------------------------|
| 1-Stage exchange   | B                       |
| 1.5-Stage exchange | B                       |
| 2-Stage exchange   | B                       |

According to Wright [32], grade A indicates good evidence (level I studies with consistent findings) for or against recommending intervention; grade B, fair evidence (level II or III studies with consistent findings) for or against recommending intervention; grade C, poor-quality evidence (level IV or V studies with consistent findings) for or against recommending intervention; and grade I, insufficient or conflicting evidence not allowing a recommendation for or against intervention.

LLC; and has stock or stock options in ROMTech, Monogram Orthopaedics, and AZSolutions, LLC. Mr. James Nace is a paid consultant for Microport; receives research support from United, Stryker, and Microport; is in the editorial or governing board of *Journal of Arthroplasty*, *Journal of Knee Surgery*, and *Knee*; is a board member in Arthritis Foundation. All other authors declare no potential conflicts of interest.

For full disclosure statements refer to <https://doi.org/10.1016/j.artd.2022.07.009>.

## References

- [1] Peersman G, Laskin R, Davis J, Peterson M. Infection in total knee replacement: a retrospective review of 6489 total knee replacements. *Clin Orthop Relat Res* 2001;392:15–23.
- [2] Kurtz S, Ong K, Lau E, Mowat F, Halpern M. Projections of primary and revision hip and knee arthroplasty in the United States from 2005 to 2030. *J Bone Joint Surg* 2007;89:780–5. <https://doi.org/10.2106/JBJS.F.00222>.
- [3] Gililland JM, Carlson VR, Fehring K, Springer BD, Griffin WL, Anderson IA. Balanced, stemmed, and augmented articulating total knee spacer technique. *Arthroplast Today* 2020;6:981–6.
- [4] Siddiqi A, George NE, White PB, Szczec BW, Thompson JV, Etcheson JI, et al. Articulating spacers as a modified one-stage revision total knee arthroplasty: a preliminary analysis. *Surg Technol Int* 2018;32:239–48.
- [5] Pangaud C, Ollivier M, Argenson JN. Outcome of single-stage versus two-stage exchange for revision knee arthroplasty for chronic periprosthetic infection. *EFORT Open Rev* 2019;4:495–502.
- [6] Insall JN, Thompson FM, Brause BD. Two-stage reimplantation for the salvage of infected total knee arthroplasty. *J Bone Joint Surg Am* 1983;65:1087–98.
- [7] Haddad FS, Masri BA, Campbell D, McGraw RW, Beauchamp CP, Duncan CP. The PROSTALAC functional spacer in two-stage revision for infected knee replacements. *J Bone Joint Surg Br* 2000;82:807–12. <https://doi.org/10.1302/0301-620X.82B6.0820807>.
- [8] Freeman MG, Fehring TK, Odum SM, Fehring K, Griffin WL, Mason JB. Functional advantage of articulating versus static spacers in 2-stage revision for total knee arthroplasty infection. *J Arthroplasty* 2007;22:1116–21.
- [9] Haddad FS, Sukeik M, Alazzawi S. Is single-stage revision according to a strict protocol effective in treatment of chronic knee arthroplasty infections? *Clin Orthop Relat Res* 2015;473:8–14.
- [10] Lichstein P, Su S, Hedlund H, Maloney WJ, Goodman SB, Huddleston 3rd JI. Treatment of periprosthetic knee infection with a two-stage protocol using static spacers. *Clin Orthop Relat Res* 2016;474:120–5.
- [11] Massin P, Delory T, Lhotellier L, Pasquier G, Roche O, Cazenave A, et al. Infection recurrence factors in one- and two-stage total knee prosthesis exchanges. *Knee Surg Sports Traumatol Arthrosc* 2016;24:3131–9.
- [12] Siddiqi A, Nace J, George NE, Buxbaum EJ, Ong AC, Orozco FR, et al. Primary total knee arthroplasty implants as functional prosthetic spacers for definitive management of periprosthetic joint infection: a multicenter study. *J Arthroplasty* 2019;34:3040–7.
- [13] Petis SM, Perry KI, Mabry TM, Hanssen AD, Berry DJ, Abdel MP. Two-stage exchange protocol for periprosthetic joint infection following total knee arthroplasty in 245 knees without prior treatment for infection. *J Bone Joint Surg Am* 2019;101:239–49.
- [14] Tibrewal S, Malagelada F, Jeyaseelan L, Posch F, Scott G. Single-stage revision for the infected total knee replacement: results from a single centre. *Bone Joint J* 2014;96-B:759–64.
- [15] Zahar A, Kendoff DO, Klatte TO, Gehrke TA. Can good infection control be obtained in one-stage exchange of the infected TKA to a rotating hinge design? 10-year results. *Clin Orthop Relat Res* 2016;474:81–7.
- [16] Jenny J-Y, Barbe B, Cazenave A, Roche O, Massin P. French Society for Hip and Knee Surgery (SFHG): patient selection does not improve the success rate of infected TKA one stage exchange. *Knee* 2016;23:1012–5.
- [17] Castellani L, Daneman N, Mubareka S, Jenkinson R. Factors associated with choice and success of one- versus two-stage revision arthroplasty for infected hip and knee prostheses. *HSS J* 2017;13:224–31.
- [18] Nace J, Siddiqi A, Talamo CT, Chen AF. Diagnosis and management of fungal periprosthetic joint infections. *J Am Acad Orthop Surg* 2019;27:e804–18.
- [19] van den Kieboom J, Tirumala V, Box H, Oganessian R, Klemm C, Kwon Y-M. One-stage revision is as effective as two-stage revision for chronic culture-negative periprosthetic joint infection after total hip and knee arthroplasty. *Bone Joint J* 2021;103-B:515–21.
- [20] Parvizi J, Gehrke T. Definition of periprosthetic joint infection. *J Arthroplasty* 2014;29:1331.
- [21] Dagneaux L, Limberg AK, Osmon DR, Leung N, Berry DJ, Abdel MP. Acute kidney injury when treating periprosthetic joint infections after total knee arthroplasties with antibiotic-loaded spacers: incidence, risks, and outcomes. *J Bone Joint Surg Am* 2021;103:754–60.
- [22] Kavolus JJ, Schwarzkopf R, Rajae SS, Chen AF. Irrigation fluids used for the prevention and treatment of orthopaedic infections. *J Bone Joint Surg Am* 2020;102:76–84.
- [23] Carli AV, Sethuraman AS, Bhimani SJ, Ross FP, Bostrom MPG. Selected heat-sensitive antibiotics are not inactivated during polymethylmethacrylate curing and can be used in cement spacers for periprosthetic joint infection. *J Arthroplasty* 2018;33:1930–5.
- [24] Abosala A, Ali M. The use of calcium sulphate beads in periprosthetic joint infection, a systematic review. *J Bone Joint Infect* 2020;5:43–9.
- [25] Newman JM, Siqueira MBP, Klika AK, Molloy RM, Barsoum WK, Higuera CA. Use of closed incisional negative pressure wound therapy after revision total hip and knee arthroplasty in patients at high risk for infection: a prospective, randomized clinical trial. *J Arthroplasty* 2019;34:554–559.e1.
- [26] Kasch R, Merk S, Assmann G, Lahm A, Napp M, Merk H, et al. Comparative analysis of direct hospital care costs between aseptic and two-stage septic knee revision. *PLoS One* 2017;12:e0169558.
- [27] Boettner F, Cross MB, Nam D, Kluthe T, Schulte M, Goetze C. Functional and emotional results differ after aseptic vs septic revision hip arthroplasty. *HSS J* 2011;7:235–8.
- [28] Hernandez NM, Buchanan MW, Seyler TM, Wellman SS, Seidelman J, Jiranek WA. 1.5-Stage exchange arthroplasty for total knee arthroplasty periprosthetic joint infections. *J Arthroplasty* 2021;36:1114–9.
- [29] Zamora T, Garbus DS, Greidanus NV, Masri BA. One and a half stage exchange arthroplasty for infected total knee arthroplasty. *Orthopaedic Proc* 2020;102:5.
- [30] Choi H-R, Freiberg AA, Malchau H, Rubash HE, Kwon Y-M. The fate of unplanned retention of prosthetic articulating spacers for infected total hip and total knee arthroplasty. *J Arthroplasty* 2014;29:690–3.
- [31] Choi HR, Freiberg AA, Malchau H, Rubash HE, Kwon YM. The fate of unplanned retention of prosthetic articulating spacers for infected total hip and total knee. *J Arthroplasty* 2014;29:690–3.
- [32] Wright JG, Swiontkowski MF, Heckman JD. Introducing levels of evidence to the journal. *J Bone Joint Surg Am* 2003;85:1–3.