

OPEN ACCESS

Full open access to this and thousands of other papers at <http://www.la-press.com>.

Prenatal Diagnosis of an Aneurysm of the Vein of Galen by Three-Dimensional Power and Color Doppler Ultrasonography

Livia Teresa Moreira Rios¹, Edward Araujo Júnior², Luciano Marcondes Machado Nardozza², Antonio Fernandes Moron² and Marília da Glória Martins¹

¹Mother-Child Unit, University Hospital, Federal University of Maranhão (UFMA), São Luiz, MA, Brazil.

²Department of Obstetrics, São Paulo Federal University (UNIFESP), São Paulo, SP, Brazil.

Corresponding author email: araujojred@terra.com.br

Abstract: Aneurysm of the vein of Galen is a complex arteriovenous malformation which is of multiply communications between of the vein of Galen and the cerebral arteries. It represents less than 1% of the cerebral arteriovenous malformations. Few cases using three-dimensional (3D) power and color Doppler ultrasound have been reported in the literature. We present a case of an aneurysm of the vein of Galen diagnosed at 25th week of pregnancy. We demonstrate the main findings of 3D power and color Doppler ultrasonography in this anomaly. A 36-year-old pregnant woman, gravida 3, para 2 was referred to our institution because of a midline cystic mass diagnosed in a previous ultrasonography undertaken at 24 weeks' gestation. The ultrasonographic finding consisted of a male fetus with a midline cystic mass, with positive flow detection by color Doppler and ventriculomegaly due to the compressive effects of the malformation. The 3D color and power Doppler ultrasonography allowed us to reconstruct the architecture of the vascular malformation, and it showed the spatial relationships of aneurysm of the vein of Galen with the other structures of the brain. Pregnancy was interrupted at 29 weeks' gestation because of presence of cardiomegaly. A male newborn survived for 36 hours only. The 3D ultrasound can be used as advent image technique in prenatal diagnosis of aneurysm of the vein of Galen.

Keywords: prenatal diagnosis, aneurysm of the vein of Galen, power Doppler, three-dimensional ultrasound

Clinical Medicine Insights: Case Reports 2012:5 77–80

doi: [10.4137/CCRep.S9597](https://doi.org/10.4137/CCRep.S9597)

This article is available from <http://www.la-press.com>.

© the author(s), publisher and licensee Libertas Academica Ltd.

This is an open access article. Unrestricted non-commercial use is permitted provided the original work is properly cited.

Introduction

Aneurysm of the vein of Galen is a complex arteriovenous malformation that has multiple implications for the vein of Galen and the cerebral arteries.¹ The embryology is unknown, but probably it is due of persistence of the embryonic median prosencephalic vein and not of the vein of Galen.² Aneurysm of the vein of Galen can demonstrate signs of volume overload as cardiomegaly and hydrops, so the neonatal prognosis usually is poor, with high incidence of morbidity and mortality.³ The aneurysm of the vein of Galen produces a large systemic shunt causing changes in the cardiovascular system as pulmonary hypertension, right-to-left atrial shunting through the foramen ovale and cardiomegaly. These can, in turn, lead to severe congestive heart failure, due to the fact that the large excess of flow exceeds the capacity of the physiological right-to-left shunt mechanisms.⁴

The prenatal diagnosis of the vein of Galen is done by identifying blood flow in the cyst using spectral or color Doppler.⁴ Power Doppler has the capacity to obtain signal in vessels with low flow velocity, and the three-dimensional (3D) power Doppler can reconstruct the architecture of the vessel.⁵ There are few case reports using 3D power and color Doppler ultrasound in prenatal diagnosis of the vein of Galen.^{3,5,6-8}

We present a case of an aneurysm of the vein of Galen diagnosed at 25th week of pregnancy. We demonstrate the main findings of 3D power and color Doppler ultrasonography of this anomaly.

Case Report

A 36 year old pregnant woman (gravida 3 para 2) was referred to our service because the fetus presented a cystic mass in median line of the brain evidenced in two-dimensional (2D) ultrasound scan realized at 24th week. A new ultrasound scan evidenced a fetus of male sex, the morphology was normal except the brain that presented a large cystic mass along the median line in topography of posterior fossa in axial plane (Fig. 1A). This cystic mass presented flow in power Doppler ultrasound (Fig. 1B). The 3D ultrasound scan was realized with a Voluson 730 Pro machine (General Electric Medical Systems, Zipf, Austria) with a convex volumetric transducer (RAB 4-8L). The 3D power and color Doppler allowed us to reconstruct the architecture of the vascular malformation, and it showed the spatial relationships of the aneurysm of the vein of Galen with the other structures of the brain (Fig. 1C and D). The information provided by 3D ultrasound permitted the counseling of parents about the poor prognosis. As a result of compression of the cystic mass in

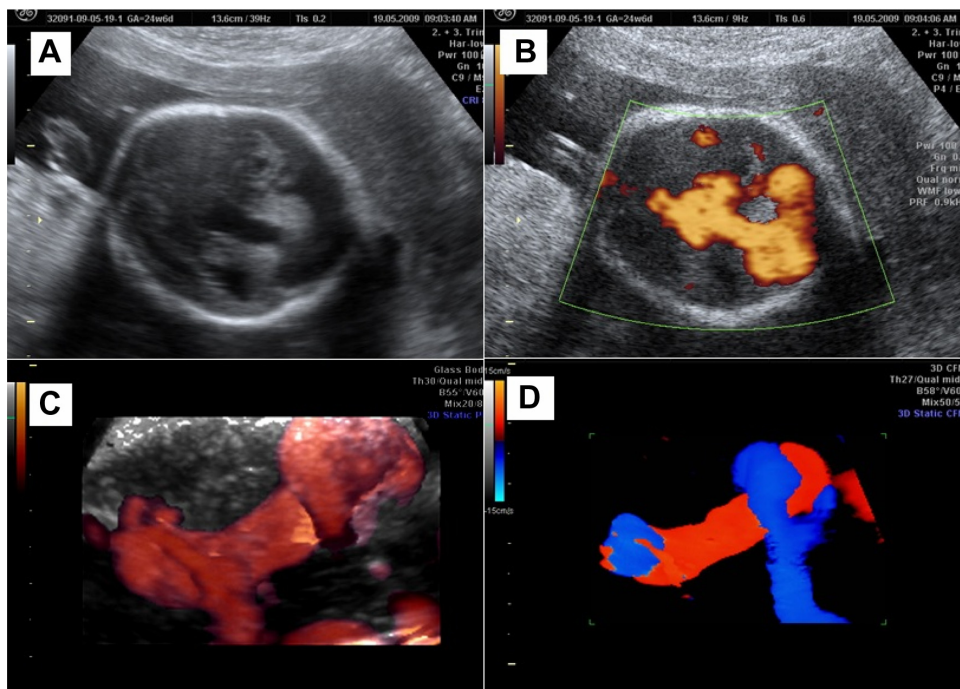


Figure 1. Aneurysm of the vein of Galen (A) image in gray scale in axial plane of fetus head; (B) image in two-dimensional power Doppler in axial plane of fetus head; (C) three-dimensional power Doppler architecture; (D) three-dimensional color Doppler architecture.



Sylvius aqueduct ventriculomegaly occurred. The fetus evolved to cardiomegaly and hydrops, and the pregnancy was interrupted by C-section in 29th week. The newborn presented hydrops and the cervical vessels were extended. The newborn died 36 hours after the labor. The necropsy was not undertaken because the parents did not permit it.

Discussion

In this case report, we demonstrated the 3D reconstruction of aneurysm of the vein of Galen by color and power Doppler. The 3D power Doppler is of particular importance to reconstruct maternal-fetal vessels because of the capacity to obtain a signal in vessels with low flow, the independence of angle and the absence of aliasing effect.⁹ The prenatal diagnosis of aneurysm of the vein of Galen is usually realized by 2D ultrasound with spectral and color Doppler,⁴ but there are few articles that used 3D power Doppler ultrasound with adjuvant technique.^{3,5,6,8} These authors wrote that the 3D power Doppler permitted the assessment of vascular connections of aneurysm. The only article that described the use of 3D color Doppler to assess the architecture of aneurysm of the vein of Galen was described by Ruano et al.⁷ These authors showed similar images of 3D power and color Doppler, and they concluded that both techniques were able to provide further mapping of the malformation by imaging its whole angioarchitecture from the circle of Willis to the right atria.

The proven benefit of 3D power Doppler in diagnosis of aneurysm of the vein of Galen was not proven. As the 3D power Doppler has the capacity to map the aneurysm and all its vascular connections, it is possible that this technique can assess the relationships between vascular and brain structures. These relationships can aid pediatric neurosurgery undertaken on these cerebral vascular malformations, selecting cases with possibility of postnatal therapy as surgery, ligation or embolization of the aneurysm. In severe cases with cardiac failure and hydrops associated with great aneurysm, the termination of pregnancy can be discussed with the parents, in countries where the pregnancy interruption for fetal malformations is permitted.

In summary, we presented a case report of aneurysm of the vein of Galen by 3D power and color Doppler ultrasound. We believe that both techniques

present similar results to 3D reconstruction of architecture of this vascular malformation. The 3D ultrasound can be used as advent image technique in prenatal diagnosis of aneurysm of the vein of Galen. New studies are necessary to assess the real applicability of this method.

Author Contributions

Conceived and designed the experiments: LTMR. Analysed the data: EAJ. Wrote the first draft of the manuscript: LTMR. Contributed to the writing of the manuscript: EAJ. Agree with manuscript results and conclusions: MGM. Jointly developed the structure and arguments for the paper: LMMN. Made critical revisions and approved final version: AFM. All authors reviewed and approved of the final manuscript.

Disclosures and Ethics

As a requirement of publication author(s) have provided to the publisher signed confirmation of compliance with legal and ethical obligations including but not limited to the following: authorship and contributorship, conflicts of interest, privacy and confidentiality and (where applicable) protection of human and animal research subjects. The authors have read and confirmed their agreement with the ICMJE authorship and conflict of interest criteria. The authors have also confirmed that this article is unique and not under consideration or published in any other publication, and that they have permission from rights holders to reproduce any copyrighted material. Any disclosures are made in this section. The external blind peer reviewers report no conflicts of interest.

References

1. Brunelle F. Arteriovenous malformation of the vein of Galen in children. *Pediatr Radiol.* 1997;27:501–13.
2. Evans A, Twining P. Case report: *in utero* diagnosis of a vein of Galen aneurysm using color flow Doppler. *Clin Radiol.* 1991;44:281–2.
3. Heling KS, Chaoui R, Bollmann R. Prenatal depiction of the angioarchitecture of an aneurysm of the vein of Galen with three-dimensional color power angiography. *Ultrasound Obstet Gynecol.* 2000;15:333–6.
4. Mai R, Rempen A, Kristen P. Prenatal diagnosis and prognosis of a vein of Galen aneurysm assessed by pulsed and color Doppler sonography. *Ultrasound Obstet Gynecol.* 1996;7:228–30.
5. Lee TH, Shih JC, Peng SS, Lee CN, Shyu MK, Hsieh FJ. Prenatal depiction of angioarchitecture of an aneurysm of the vein of Galen with three-dimensional color power angiography. *Ultrasound Obstet Gynecol.* 2000;15:337–40.
6. Gerards FA, Engels MA, Barkhof F, van den Dungen FA, Vermeulen RJ, van Vugt JM. Prenatal diagnosis of aneurysms of the vein of Galen (vena magna cerebri) with conventional sonography, three-dimensional sonography, and magnetic resonance imaging: report of 2 cases. *J Ultrasound Med.* 2003;22:1363–8.



7. Ruano R, Benachi A, Aubry MC, Brunelle F, Dumez Y, Dommergues M. Perinatal three-dimensional color power Doppler ultrasonography of vein of Galen aneurysms. *J Ultrasound Med.* 2003;22:1357–62.
8. Sepulveda W, Vanderheyden T, Pather J, Pasquini L. Vein of Galen malformation: prenatal evaluation with three-dimensional power Doppler angiography. *J Ultrasound Med.* 2003;22:1395–8.
9. Guimarães Filho HA, Araujo Júnior E, Mattar R, Mattar R, Da Costa LL, de Mello Júnior CF, et al. Placental blood flow measured by three-dimensional power Doppler ultrasound at 26 to 35 weeks gestation in normal pregnancies. *J Matern Fetal Neonatal Med.* 2010;23:69–73.