



Since January 2020 Elsevier has created a COVID-19 resource centre with free information in English and Mandarin on the novel coronavirus COVID-19. The COVID-19 resource centre is hosted on Elsevier Connect, the company's public news and information website.

Elsevier hereby grants permission to make all its COVID-19-related research that is available on the COVID-19 resource centre - including this research content - immediately available in PubMed Central and other publicly funded repositories, such as the WHO COVID database with rights for unrestricted research re-use and analyses in any form or by any means with acknowledgement of the original source. These permissions are granted for free by Elsevier for as long as the COVID-19 resource centre remains active.



Vaccine-induced immune thrombotic thrombocytopenia

Frederikus A Klok, Menaka Pai, Menno V Huisman, Michael Makris

In response to the COVID-19 pandemic, vaccines for SARS-CoV-2 were developed, tested, and introduced at a remarkable speed. Although the vaccine introduction had a major impact on the evolution of COVID-19, some potential rare side-effects of the vaccines were observed. Within a short period, three scientific groups from Norway, Germany, and the UK reported cerebral venous sinus thrombosis with thrombocytopenia and anti-platelet factor 4 (anti-PF4) antibodies in individuals following AstraZeneca–Oxford vaccination and named this new syndrome vaccine-induced immune thrombotic thrombocytopenia (VITT). This syndrome was subsequently reported in individuals who received Johnson & Johnson vaccination. In this Viewpoint, we discuss the epidemiology, pathophysiology, and optimal diagnostic and therapeutic management of VITT. Presentation of an individual with possible VITT should raise prompt testing for anti-PF4 antibodies and initiation of treatment targeting autoimmune processes with intravenous immunoglobulin and prothrombotic processes with non-heparin anticoagulation.

Introduction

COVID-19 infection, due to SARS-CoV-2, has had an impact on people and economies worldwide. As of Sept 13, 2021, over 220 million infections and more than 4·6 million COVID-19-related deaths have been reported.¹ On March 11, 2020, WHO declared the infection a pandemic, and less than 9 months later the first vaccine for SARS-CoV-2 from Pfizer-BioNTech was first approved by the UK Medicines and Healthcare Products Regulatory Agency (MHRA). As of July 26, 2021, 3·85 billion doses of vaccines for SARS-CoV-2 have been administered in 180 countries.²

Reports of thrombosis in relation to vaccination for SARS-CoV-2 started appearing in late February 2021, which led to an investigation by the MHRA and European Medicines Agency (EMA), who announced on March 11, 2021, that no association was identified. However, three scientific groups from Norway, Germany, and the UK reported the following week, in the press and on social media, the identification of cerebral venous sinus thrombosis with thrombocytopenia and anti-platelet factor 4 (anti-PF4) antibodies in individuals following AstraZeneca–Oxford vaccination.^{3–5} Although initially several terms were used to describe the syndrome, such as vaccine-associated thrombosis with thrombocytopenia and vaccine-induced prothrombotic immune thrombocytopenia, the term that has gained widespread use is vaccine-induced immune thrombotic thrombocytopenia (VITT). Thrombosis with thrombocytopenia syndrome has also been used, but it is a more general term that can be caused by other conditions, such as antiphospholipid syndrome and thrombotic thrombocytopenic purpura.

Similar to the COVID-19 infection, social media has had a substantial role in disseminating information about VITT, since its announcement in a press conference and on social media on March 19, 2021 (figure 1). Three authors (FK, MP, MM) have been active on Twitter in providing updates about VITT. COVID-19 and VITT have shown that social media rather than medical journals will be at the forefront of sharing information in the future.

Epidemiology

Incidence

The reported risk of VITT has varied substantially between countries and between individuals exposed to the AstraZeneca–Oxford vaccine. This disparity is partially due to significant differences in the age and sex of those vaccinated as well as incongruence in the way data are collected and reported. In Norway, Schultz and colleagues⁴ reported five cases of VITT among 130 000 individuals who received the AstraZeneca–Oxford vaccine giving an incidence of one in 26 000. In the UK, the MHRA reported 367 VITT cases after 24·7 million of the first vaccination and 44 cases after the second AstraZeneca–Oxford vaccination, giving rates of one case per 67 302 vaccinations and one case per 518 181 vaccinations, respectively.⁶ See and colleagues,⁷ from the USA, reported 12 cases of VITT after the Johnson & Johnson vaccine after 7 million doses, suggesting a rate of one case per 583 000 vaccinations.

SARS-CoV-2 vaccine type

VITT has been reported almost exclusively after the AstraZeneca–Oxford and Johnson & Johnson adenoviral vaccines, with most after the first vaccination.^{8,9} No confirmed case reports have been published after the mRNA vaccine from Pfizer-BioNTech, but the MHRA received 15 notifications of thrombosis and thrombocytopenia associated with this vaccine from health-care professionals and the public.⁶ One probable VITT case was reported in the USA after Moderna vaccination.¹⁰

Age

An association exists between risk of VITT and younger age. The MHRA gives the risk of VITT after the first dose of AstraZeneca–Oxford vaccination as one in 100 000 for people older than 50 years and one in 50 000 for those aged 49 years or younger.⁶ The MHRA does not provide information on the risk of VITT by decade of age, and the risk cannot be calculated because the data on people receiving AstraZeneca–Oxford vaccine by decade of age

Lancet Haematol 2021; 9: 73–80

Published Online

November 11, 2021

[https://doi.org/10.1016/S2352-3026\(21\)00306-9](https://doi.org/10.1016/S2352-3026(21)00306-9)

Department of Medicine—

Thrombosis and Hemostasis,

Leiden University Medical

Center, Leiden, Netherlands

(F A Klok MD,

Prof M V Huisman MD); Center

for Thrombosis and

Hemostasis, University Medical

Center Mainz, Mainz, Germany

(F A Klok); Department of

Medicine, McMaster

University, Hamilton ON,

Canada (M Pai MD);

Department of Infection,

Immunity and Cardiovascular

Disease, University of Sheffield,

Sheffield, UK; and Sheffield

Haemophilia and Thrombosis

Centre, Royal Hallamshire

Hospital, Sheffield, UK

(Prof M Makris MD)

Correspondence to:

Frederikus A Klok, Department of

Medicine—Thrombosis and

Hemostasis, Leiden University

Medical Center, Leiden 2333 ZA,

Netherlands

f.a.klok@lumc.nl; @Erik_Klok_

MD

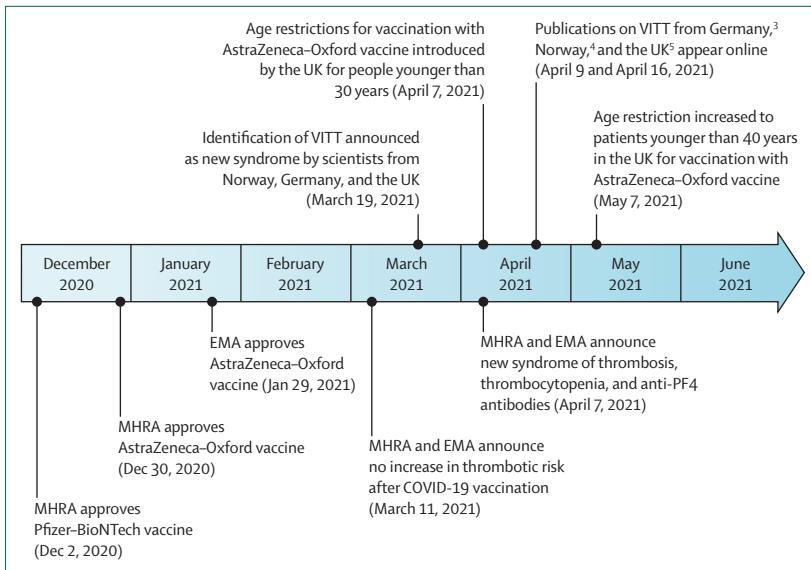


Figure 1: Timeline of the development of adenovirus-based coronavirus vaccines and first recognition of vaccine-induced immune thrombotic thrombocytopenia

On August 12, 2021, the full report from the first 294 UK cases was published.⁹ EMA=European Medicines Agency. MHRA=Medicines and Healthcare Products Regulatory Agency. VITT=vaccine-induced immune thrombotic thrombocytopenia.

have not been made public. In the UK VITT case series,⁹ mean age at diagnosis was 48 years with 85% of individuals being aged less than 60 years.⁹

Sex

Because four (80%) of five individuals from Norway⁴ and nine (82%) of 11 individuals from Germany³ were female it was initially thought that female sex was a risk factor for VITT. However, these countries used the AstraZeneca-Oxford vaccine initially in frontline health-care workers who were primarily female. A report from the UK suggested that the VITT sex bias might not be so extreme, because only 119 (54%) of 220 individuals with definite or probable VITT were female.⁹

Comorbidities and previous COVID-19 infection

No studies have directly compared the comorbidities of individuals with VITT with those of the general population. In the UK study of 165 individuals with definite or probable VITT, 14 (8%) had a history of an autoimmune disorder, four (2%) had a history of previous venous thrombosis, four (2%) had a history of cancer, and 31 (19%) had one or more risk factors for arterial disease (obesity, smoking, hypertension, or diabetes).⁹ Three (1%) of 220 individuals in the UK cohort reported COVID-19 infection in the previous 3 months and ten (5%) had serological evidence of previous infection.⁹

Pathophysiology

VITT is an autoimmune condition, characterised by antibodies that directly activate platelets, triggering thrombosis in the arterial and venous circulation.

Individuals with VITT develop a consumptive coagulopathy, with thrombocytopenia, hypofibrinogenemia, and an elevated D-dimer concentration. The earliest papers describing VITT showed that individuals had high titre IgG antibodies directed against platelet factor 4 (PF4), a molecule stored in platelet α granules and released during platelet activation.^{3-5,7} PF4 is probably part of our innate immune defence; this cationic molecule binds and opsonises polyanionic surfaces of pathogens, facilitating binding of anti-PF4 antibodies produced by preformed B cells.^{11,12} In VITT, anti-PF4 antibodies have a different role by binding platelet Fc γ RIIA, which causes platelet activation through intracellular signalling and release of procoagulant platelet microparticles. Released platelet microparticles can carry PF4, and VITT antibodies cluster PF4 on the platelet surface as they bind.¹³ Procoagulant microparticles can also express tissue factor, which might explain the propensity to cerebral venous sinus thrombosis in VITT; tissue factor appears to have a key role in thrombogenesis in the cerebral venous system.¹⁴

The pathophysiology of VITT closely resembles that of heparin-induced thrombocytopenia, which is also caused by anti-PF4 antibodies (figure 2). In classic heparin-induced thrombocytopenia, these antibodies recognise the ionic complex of positively charged PF4 and negatively charged heparin.¹⁵ Antibodies of heparin-induced thrombocytopenia induce a pan-cellular response, causing Fc γ receptor-dependent activation of monocytes (promoting tissue factor expression and thrombin generation) and neutrophils (inducing NETosis).^{16,17} Antibody binding to Fc γ RIII-A also contributes to platelet clearance and thrombocytopenia.¹⁶ There is evidence of complement activation as well, promoting cellular activation and adhesion of platelets to the endothelium.¹⁸ VITT antibodies probably similarly amplify thrombosis and thrombocytopenia.^{19,20} In most cases, heparin-induced thrombocytopenia is triggered by heparin exposure. However, in a rare subtype, known as autoimmune heparin-induced thrombocytopenia, heparin exposure is not implicated. In this condition, highly anionic molecules, such as pentosan polysulphate, chondroitin sulphate, and parts of the bacterial cell wall, take the place of heparin, forming complexes with PF4 and triggering antibody formation.¹⁵ The parallels between VITT and autoimmune heparin-induced thrombocytopenia extend beyond pathophysiology; their clinical characteristics and treatment strategies are similar as well. However, alanine scanning mutagenesis showed that binding of VITT antibodies is distinct from heparin-induced thrombocytopenia antibodies.²¹ The binding of anti-PF4 antibodies from five individuals with VITT was restricted to eight surface amino acids, all located within the heparin binding site of PF4. These findings could explain why, in most individuals with VITT, antibody binding in PF4 enzyme immunoassays is inhibited by heparin.³

The pathophysiology of VITT is still incompletely understood. A major area of uncertainty is how adenoviral

vector vaccines trigger this syndrome. Adenoviral vector vaccines might interact directly with PF4, priming an anti-PF4 response. This hypothesis has been explored by Greinacher and colleagues,¹³ who observed a direct interaction between AstraZeneca–Oxford and PF4 with transmission electron microscopy, and Baker and colleagues,²² who reported binding of PF4 to AstraZeneca–Oxford hexon proteins using computational simulations. The viral capsid of the AstraZeneca–Oxford vaccine might bind PF4, creating a novel antigen that is subsequently taken up by monocytes and trafficked to lymph nodes, where it stimulates proliferation of anti-PF4 memory B cells.¹³ Vaccine components, such as EDTA (edetic acid) or other human proteins in the vaccine, might promote a proinflammatory milieu that potentiates the immune response.^{13,23} This theory does not require heparin or any other anionic compound and is supported by the existence of preformed anti-PF4 memory B cells.

The adenoviral vector is a hypothesised trigger. Thrombocytopenia is a well recognised complication of many viral infections and can be rapidly induced in animal studies by intravenous administration of adenovirus, resulting in non-specific platelet destruction from deposition of circulating immune complexes, suppression of platelet production, and specific antiplatelet antibodies.²⁴ Some adenoviruses and adenoviral vectors are also capable of binding factor X, and adenoviruses can cause platelet aggregation and activation when added to platelet-rich plasma.^{25,26} The direct adenoviral trigger theory becomes less likely when one considers that thrombosis has not previously been associated with adenoviral infection or with other adenoviral vector vaccines (even when administered intravenously at high doses in animal studies).²⁴ Moreover, platelet and coagulation factor binding of adenoviruses occurs rapidly, whereas VITT presents more than 5 days after vaccination. Another hypothesis implicates trace amounts of spike splice variant transcripts (C-terminally deleted mRNAs).²⁷ The resultant alternative spike proteins could damage endothelial cells, triggering inflammation and platelet activation, causing PF4 release and thrombosis. However, variant transcripts and alternative spike proteins have not been detected following vaccination with adenoviral vector COVID-19 vaccines. Impurities in vaccine preparation are another theorised VITT trigger. The AstraZeneca–Oxford vaccine contains human and non-structural viral proteins, raising the concern that functional autoantibodies can form against them.²⁸ Some jurisdictions have reported higher frequencies of VITT than others; varying purity between vaccine batches could explain this.²⁹

Active COVID-19 infection is not a feature of VITT. COVID-19 can induce a hypercoagulable state, and anti-PF4 antibodies have been found in patients who have been admitted to hospital with COVID-19. However, it is unclear whether functionally active, clinically significant anti-PF4 antibodies are more common in patients who have been admitted to hospital with COVID-19

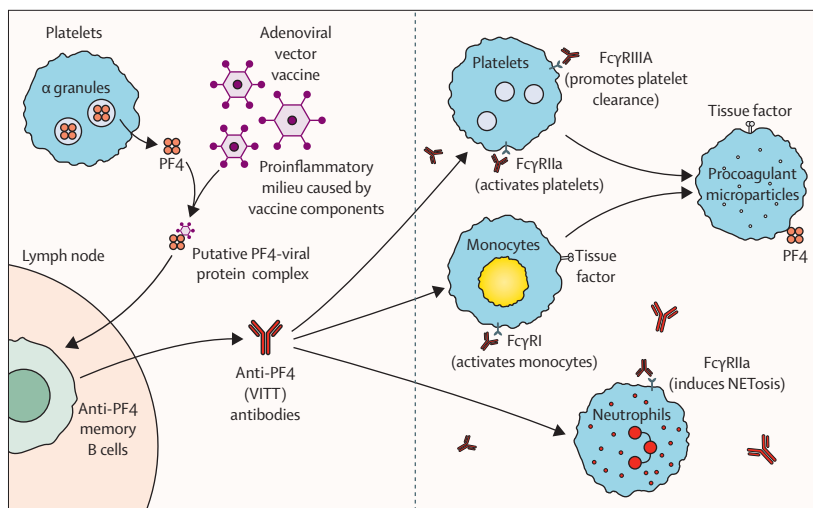


Figure 2: Proposed pathophysiology of vaccine-induced immune thrombotic thrombocytopenia
PF4=platelet factor 4.

than in other patients. Concomitant thrombosis and thrombocytopenia are also uncommon in COVID-19, and VITT antibodies do not appear to cross react with the SARS-CoV-2 spike protein.^{30,31} An association between the formation of anti-SARS-CoV-2 antibodies and the formation of anti-PF4 antibodies does not appear to exist, as illustrated in a study by Uzun and colleagues,³² which compared antibody titres in healthy vaccinated controls and individuals with VITT.

Clinical presentation and diagnosis

Clinical presentation

The presentation of thrombocytopenia and thrombosis, occurring 5–30 days after first vaccination against SARS-CoV-2 with the AstraZeneca–Oxford or Johnson & Johnson vaccine is suggestive for VITT.³³ In the UK cohort of 220 definite or probable VITT cases,⁹ median age was 48 years with a range of 18–78 years, 85% of individuals were <60 years, and 119 (54%) of 217 participants were women. The median time from the first AstraZeneca–Oxford vaccination to presentation was 14 days (IQR 10–16), with 97% of patients presenting between 5–30 days.⁹ The median platelet count at presentation was 47×10^9 cells per L (28–76) with only 11 individuals having a count of more than 150×10^9 cells per L; in all but two of these 11, the platelet count reduced to less than 150×10^9 cells per L following admission to hospital. D-dimer concentrations were considerably elevated (>4000 fibrinogen-equivalent units [FEU]). Venous thrombosis is often present at multiple sites and sometimes at unusual sites. Although the initial literature described a preponderance of cerebral vein thrombosis occurring predominantly in women younger than 60 years,^{3,5} it became clear that individuals also present with more common presentations of deep-vein thrombosis of the leg and pulmonary embolism. Individuals with splanchnic vein thrombosis, with localisation in the mesenteric, portal, hepatic, or splenic

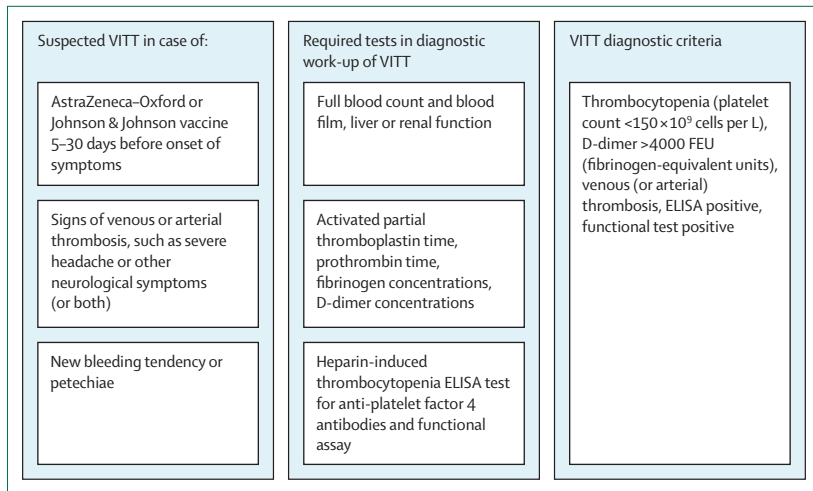


Figure 3: Overview of the diagnostic investigation of VITT

Functional assays might involve a functional heparin-induced platelet activation assay, a serotonin-release assay, or a flow-based platelet activation assay. FEU=fibrinogen-equivalent units. VITT=vaccine-induced immune thrombotic thrombocytopenia.

veins, have also been described. Cerebral venous sinus thrombosis was the most common thrombotic complication and was identified in 110 (50%) of 220 individuals from the UK; 40 (36%) of the 110 individuals had secondary intracerebral haemorrhage. Deep-vein thrombosis and pulmonary embolism were found in 82 (37%) of 220 people, splanchnic vein thrombosis (mostly portal vein) in 41 (19%), arterial thrombosis in 47 (21%), and 64 (29%) people had thrombosis affecting multiple beds.⁹ In a post-mortem study,¹⁹ involvement of large venous vessels was even more widespread and catastrophic than estimated with imaging tests, and microscopic findings showed vascular thrombotic occlusions occurring in the microcirculation of multiple organs.

Radiological diagnosis of thrombosis

Targeted urgent radiological investigation is required in all people with VITT. Standard imaging tests include CT or MR venography of the brain for suspected cerebral vein thrombosis,³⁴ CT pulmonary angiography for suspected pulmonary embolism,³⁵ compression ultrasonography for suspected deep-vein thrombosis,³⁶ and ultrasound or CT venography of the splanchnic veins for suspected splanchnic vein thrombosis.³⁷ Some experts have suggested that an abdominal ultrasound scan is recommended in all individuals with VITT to screen for asymptomatic portal vein thrombosis.³⁸

Differential diagnosis

The main syndromes to be distinguished from VITT are immune thrombocytopenic purpura, thrombotic thrombocytopenic purpura, and catastrophic antiphospholipid syndrome. In immune thrombocytopenic purpura, thrombosis does not manifest, whereas the D-dimer concentration and coagulation tests are normal.³⁹ In

thrombotic thrombocytopenic purpura, microvascular thrombosis is typical, rather than the presence of venous thromboembolism. Laboratory findings in thrombotic thrombocytopenic purpura include normal concentrations of fibrinogen and D-dimer, microangiopathic haemolytic anaemia with laboratory findings of haemolysis, schistocytes on the blood smear, and ADAMTS13 deficiency ($<10\%$).⁴⁰ Catastrophic antiphospholipid syndrome is excluded by the absence of antiphospholipid antibodies.

Laboratory diagnosis

Initial laboratory evaluation should include, full blood count with blood film, prothrombin time, activated partial thromboplastin time, D-dimer concentration, fibrinogen concentration, and liver and renal function.³³ In classical VITT, individuals present with thrombocytopenia, high D-dimer concentrations (often >5 – $10\,000$ FEU), moderately decreased fibrinogen concentrations, and normal or slightly elevated activated partial thromboplastin time and prothrombin time.

If a person presents with thrombocytopenia and thrombosis, an anti-PF4 heparin-induced thrombocytopenia ELISA should be done; if positive, this should ideally be confirmed by a functional heparin-induced platelet activation assay, serotonin-release assay or flow based platelet activation assay.^{41–43} ELISA heparin-induced thrombocytopenia assays have the most appropriate sensitivity for anti-PF4 antibodies in VITT, whereas assays have shown low sensitivity.^{44,45} Thus, in the appropriate clinical setting, VITT syndrome is strongly suggestive if the heparin-induced thrombocytopenia ELISA and heparin-induced platelet activation assay or serotonin-release assay test are positive. VITT is not excluded by a negative, rapid immunoassay against PF4, such as particle centrifugation assay and chemiluminescence immunoassay, because these tests can show false-negative results (figure 3).⁴⁵

Case definition

The UK Expert Haematology Panel considers five criteria in the definition of VITT: onset of symptoms 5–30 days (or 5–42 days if isolated deep-vein thrombosis or pulmonary embolism) after COVID-19 vaccination, presence of thrombosis, thrombocytopenia (platelet count $<150 \times 10^9$ cells per L), D-dimer concentration of more than 4000 FEU, and positive anti-PF4 ELISA assay. Diagnosis of VITT is considered definite if all five criteria are present and probable if one is missing.⁹

VITT without thrombosis

We and others have observed several individuals who present 5–30 days after AstraZeneca–Oxford vaccination with severe headache, thrombocytopenia, markedly increased D-dimer concentrations, strongly positive anti-PF4 antibodies, but no cerebral venous sinus thrombosis on cerebral vein thrombosis or MR venography imaging. In our view, these individuals form the spectrum of VITT

diagnosis and should be treated as such. These individuals should be differentiated from those with immune thrombocytopenia post-COVID-19 vaccination who have normal concentrations of D-dimer, who are negative for anti-PF4 antibodies, and in whom bleeding is common but thrombosis is extremely rare.

Treatment

Therapeutic management of VITT is based on three components: modulation of the autoimmune phenomenon, anticoagulation, and supportive care and management of complications (figure 4).

Modulation of the autoimmune phenomenon

VITT consensus documents and guidelines have widely extrapolated the treatment of autoimmune heparin-induced thrombocytopenia to VITT, and these recommendations have been supported by published VITT case reports and series.^{9,41,42,46,47} In autoimmune heparin-induced thrombocytopenia, intravenous immunoglobulin is important since heparin avoidance alone does not lead to a rapid de-escalation of heparin-induced thrombocytopenia hypercoagulability; heparin-independent antibodies can persist for days to weeks.^{48,49} In addition to antibody neutralisation, intravenous immunoglobulin inhibits VITT-mediated platelet activation.⁵⁰ The recommended dosing of intravenous immunoglobulin is 1 g/kg per day. Furthermore, plasma exchange might be considered in severe or therapy refractory disease; for example, in settings of severe thrombocytopenia or extensive thrombosis. During plasma exchange, the IgG antibodies triggering VITT are removed. Four of five Norwegian patients were treated with intravenous immunoglobulin (and prednisolone) early or later in the course of the disease; all four showed an increase in platelet count, whereas previous frequent platelet transfusions did not.⁵¹ The same effect of intravenous immunoglobulin was observed in Canada and the UK.^{9,52} Three individuals with anticoagulation, intravenous immunoglobulin, and steroid refractory VITT received plasma exchange and responded with increasing platelet counts and decreasing D-dimer concentrations; all three survived.⁵³ Avoiding heparin exposure and platelet transfusions are key aspects of basic VITT treatment. These therapies might further provoke autoimmunity or fuel coagulopathy (or both). Steroids and rituximab have also been used in the setting of severe or therapy refractory VITT; however, experience is scarce and treatment outcomes uncertain.^{9,51–53}

Anticoagulation

Patients with VITT should receive therapeutic-dose anticoagulants to prevent further thrombotic complications. Although it has not been fully established whether heparin exacerbates the clinical presentation, for now anticoagulation therapy should involve non-heparin-based therapies, such as direct oral anticoagulants,

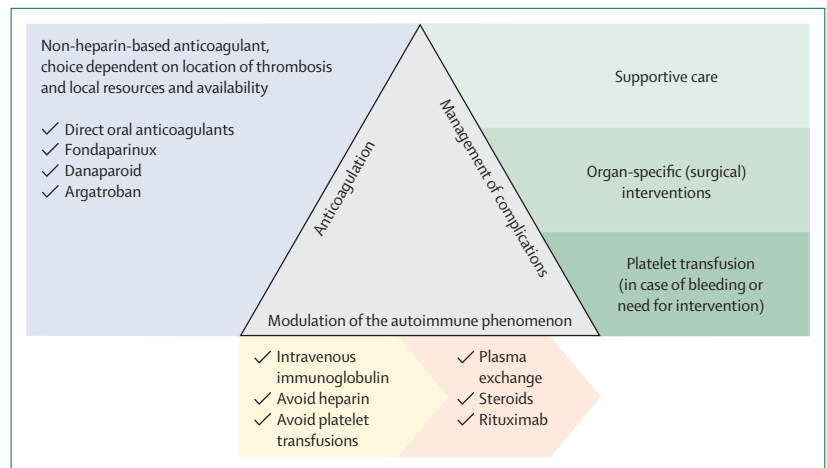


Figure 4: Overview of the therapeutic management of vaccine-induced immune thrombotic thrombocytopenia

fondaparinux, danaparoid, or argatroban. In individuals with thrombocytopenia and markedly elevated D-dimer concentrations, but without thrombosis (who are deemed not to have thrombotic thrombocytopenic purpura or immune thrombocytopenic purpura), non-heparin-based anticoagulation is the mainstay of treatment too.^{54,55} For cerebral venous sinus thrombosis and splanchnic vein thrombosis, endovascular treatment is not the standard-of-care but might be considered in select cases.⁸ As for the choice of anticoagulant drug class, considering insufficient evidence for direct oral anticoagulants in cerebral venous sinus thrombosis and splanchnic vein thrombosis, as well as the presence of thrombocytopenia and high risk of bleeding, initial treatment with a parenteral agent is preferred over apixaban or rivaroxaban in most cases; edoxaban and dabigatran should precede by a lead-in with a parenteral agent. Treatment can be switched to a direct oral anticoagulants in the subacute and chronic phase of the disease. The treatment of acute pulmonary embolism should be based on formal risk stratification, with reperfusion therapy reserved for those patients with high-risk pulmonary embolism.^{35,56}

Supportive care and management of complications

The most feared complication of initial treatment in VITT is major bleeding. In patients with splanchnic vein thrombosis or cerebral venous sinus thrombosis, major bleeding might be the presenting symptom. The anticoagulant dosing strategy might require alteration in individuals with active bleeding or with platelet counts less than 30×10^9 cells per L. In this setting, anticoagulant therapy at a lower intensity or following platelet transfusions (preferably after intravenous immunoglobulin is administered) might be considered, in addition to plasma exchange.^{8,33} Transfusion to correct relevant hypofibrinogenaemia is also recommended in those with a fibrinogen concentration of less than 1.5 g/L. Furthermore, in addition to anticoagulant treatment, management of

cerebral venous sinus thrombosis could require decompressive craniectomy if intracranial pressure is raised, and anticonvulsant agents if seizures have occurred.^{54,55} For these reasons, individuals with VITT-associated cerebral venous sinus thrombosis should be referred immediately to an expert centre for optimal multidisciplinary treatment.^{8,33} Additionally, for individuals with splanchnic vein thrombosis, surgical treatment might be indicated in those presenting with bleeding, shock, peritonitis, intestinal perforation, or infarction.^{57,58} Other reported complications of VITT that require dedicated management include adrenal haemorrhage, limb ischaemia, and acute coronary syndrome.

Outcomes

VITT was first described in March, 2021, therefore, data on outcomes and natural history are scarce. In the initial publications on VITT from Norway⁴ and Germany, and Austria,³ the mortality associated with VITT was 60% and 55%, respectively. In the UK cohort of definite and probable cases, 23% of the patients died at the time of reporting.⁹ These early fatality rates do not capture later mortality or morbidity, such as secondary to cerebral bleeding or amputations secondary to leg arterial thrombosis. A group of particular concern are those with cerebral venous sinus thrombosis with intracerebral haemorrhage and a platelet count of less than 30×10^9 cells per L, for whom a mortality rate of 47–73% was reported.^{9,59} Case fatality in more recent reports are lower than in the initial reports, possibly because less severe cases are being identified better or management has improved with increasing experience.⁶⁰

Follow-up post-hospital discharge

Although the natural history of VITT is unknown, early experience suggests that the anti-PF4 antibodies persist at least for several months in most individuals. Some people redeveloped thrombocytopenia after platelet count normalisation, possibly because the relatively short half-life of intravenous immunoglobulin meant its effect was lost. Some individuals have required retreatment with intravenous immunoglobulin and rituximab. Patients are suggested to be followed-up closely after discharge with measurement of platelet count, fibrinogen concentration, and D-dimer concentration every 2–3 days for 2 weeks. Anti-PF4 antibody measurements weekly for 4 weeks and then monthly for 6 months have been proposed.³³

Future perspectives

The most urgent questions that remain about VITT include the exact pathophysiological mechanism and the long-term management of those who survive VITT. It is uncertain what vaccine components trigger VITT, for example the adenovirus itself or the contaminants. This knowledge will have implications for future

manufacturing and application of adenovirus-based coronavirus vaccines. The other key unanswered question relates to the natural history of VITT. Individuals often have persistent high titres of antibodies to PF4 beyond the first months of treatment. Therefore, we treat individuals with VITT with anticoagulation for at least 3 months, also those without thrombosis, and continue this treatment thereafter until anti-PF4 ELISA tests return negative.³³ Results of the PF4-dependent platelet-activation assay were reported to become negative in 23 (66%) of 35 patients over a median of 11 weeks, accompanied by a 53% decrease in the median optical density on anti-PF4-heparin IgG ELISA. However, full seroreversion to a negative ELISA result was observed in only three (9%) of 35 individuals.⁶¹

The realisation that VITT was a serious adverse event led to restricted use of adenoviral vector vaccines in many jurisdictions. Where a first AstraZeneca–Oxford dose had already been given, some countries (such as the UK and Canada) permitted a second AstraZeneca–Oxford vaccine, whereas others offered a second dose with an mRNA vaccine. It appears that the use of mRNA vaccines in people with previous AstraZeneca–Oxford vaccination can lead to increased reactions;⁶² however, the resulting heterologous prime boosting also appears to yield improved immunity.⁶³

Individuals who have had an episode of VITT should avoid further adenoviral vector vaccinations. They might have concerns about subsequent vaccination, but as they are unlikely to have reached a high level of immunity after a single AstraZeneca–Oxford vaccine, they should be counselled and supported to have a second dose using mRNA technology. The safety of using mRNA vaccines in individuals with VITT is unproven but some early, unpublished experience is encouraging. It is prudent to proceed with a second-dose vaccination once the platelet count and D-dimer concentration are stable and within normal range, and the patient is fully anticoagulated. Some physicians might elect to repeat VITT testing before vaccination to ensure antibody titres are decreasing or repeat a full blood count in the week following vaccination (or both) to ensure the platelet count has not again dropped. If the VITT episode followed Johnson & Johnson vaccination, further vaccination against SARS-CoV-2 is not required.

Conclusion

Our understanding of VITT has progressed considerably since its initial recognition. Preclinical studies have shown directions to the underlying pathophysiology, diagnostic criteria have been widely endorsed, and dedicated laboratory tests have been developed and made available. The experience gained in the few hundred cases published in the literature has confirmed the initial thoughts that VITT should be managed as a heparin-induced thrombocytopenia-like syndrome with modulation of the autoimmune phenomenon and non-heparin

Search strategy and selection criteria

We searched PubMed, Embase, Cochrane library, Web of Science, WHO COVID-19 database, Academic Search Premier, Google Scholar, medRxiv and bioRxiv for studies published between July 6, 2021, and Sept 12, 2021. Search terms included "VITT", "vaccines", "COVID-19", AND "thrombocytopenia" (appendix). Only articles in English, Dutch, and French were included. The final reference list was generated on the basis of originality and relevance to the broad scope of this paper.

anticoagulation. Existing research efforts should focus on determining the optimal long-term management of survivors of VITT and further unravelling of its mechanism, which will enable optimal use of adenovirus-based coronavirus vaccines in the future.

Contributors

All authors contributed to the drafting of the manuscript, approved of its final version, and had final responsibility for the decision to submit for publication.

Declaration of interests

FAK reports research grants from Bayer, Bristol-Myers Squibb, The Netherlands Organisation for Health Research and Development, Actelion, the Dutch Heart foundation, and the Dutch Thrombosis association, outside the submitted work. MP reports personal fees from Pfizer, personal fees from Novartis, outside the submitted work. MVH reports research grants from Dutch Organisation for Health Research and Development, Dutch Heart Foundation, Bayer Health Care, Pfizer-BMS, and Leo Pharma, outside the submitted work. MM reports research support from Pfizer and Sanofi, outside the submitted work.

References

- Worldometer. COVID-19 coronavirus pandemic. <https://www.worldometers.info/coronavirus> (accessed Sept 12, 2021).
- Bloomberg. More than 6.5 billion shots given: covid-19 tracker. <https://www.bloomberg.com/graphics/covid-vaccine-tracker-global-distribution/> (accessed July 26, 2021).
- Greinacher A, Thiele T, Warkentin TE, Weisser K, Kyrle PA, Eichinger S. Thrombotic thrombocytopenia after ChAdOx1 nCoV-19 vaccination. *N Engl J Med* 2021; **384**: 2092–101.
- Schultz NH, Sorvoll IH, Michelsen AE, et al. Thrombosis and thrombocytopenia after ChAdOx1 nCoV-19 vaccination. *N Engl J Med* 2021; **384**: 2124–30.
- Scully M, Singh D, Lown R, et al. Pathologic antibodies to platelet factor 4 after ChAdOx1 nCoV-19 vaccination. *N Engl J Med* 2021; **384**: 2202–11.
- Medicines and Healthcare products Regulations Agency. Coronavirus vaccine—summary of Yellow Card. <https://tinyurl.com/uwx6jpih> (accessed July 26, 2021).
- See I, Su JR, Lale A, et al. US case reports of cerebral venous sinus thrombosis with thrombocytopenia after Ad26.COV2.S vaccination, March 2 to April 21, 2021. *JAMA* 2021; **325**: 2448–56.
- Makris M, Pavord S, Lester W, Scully M, Hunt B. Vaccine-induced immune thrombocytopenia and thrombosis (VITT). *Res Pract Thromb Haemost* 2021; **5**: e12529.
- Pavord S, Scully M, Hunt BJ, et al. Clinical features of vaccine-induced immune thrombocytopenia and thrombosis. *N Engl J Med* 2021; **385**: 1680–89.
- Sangli S, Virani A, Cheronis N, et al. Thrombosis with thrombocytopenia after the messenger RNA-1273 vaccine. *Ann Intern Med* 2021; published online June 29. <https://doi.org/10.7326/L21-0244>.
- Nguyen TH, Medvedev N, Delcea M, Greinacher A. Anti-platelet factor 4/polyanion antibodies mediate a new mechanism of autoimmunity. *Nat Commun* 2017; **8**: 14945.
- Krauel K, Schulze A, Jouni R, et al. Further insights into the anti-PF4/heparin IgM immune response. *Thromb Haemost* 2016; **115**: 752–61.
- Greinacher A, Selleng K, Palankar R. Insights in ChAdOx1 nCoV-19 vaccine-induced immune thrombotic thrombocytopenia (VITT). *Blood* 2021; published online Sept 29. <https://doi.org/10.1182/blood.2021013231>.
- Marchandot B, Carmona A, Trimaille A, Curtiaud A, Morel O. Procoagulant microparticles: a possible link between vaccine-induced immune thrombocytopenia (VITT) and cerebral sinus venous thrombosis. *J Thromb Thrombolysis* 2021; published online June 15. <https://doi.org/10.1007/s11239-021-02505-4>.
- Warkentin TE, Greinacher A. Spontaneous HIT syndrome: knee replacement, infection, and parallels with vaccine-induced immune thrombotic thrombocytopenia. *Thromb Res* 2021; **204**: 40–51.
- Rollin J, Pouplard C, Gruel Y. Risk factors for heparin-induced thrombocytopenia: focus on Fcγ receptors. *Thromb Haemost* 2016; **116**: 799–805.
- Perdomo J, Leung HHL, Ahmadi Z, et al. Neutrophil activation and NETosis are the major drivers of thrombosis in heparin-induced thrombocytopenia. *Nat Commun* 2019; **10**: 1322.
- Khandelwal S, Barnes A, Rauova L, et al. Complement mediates binding and procoagulant effects of ultra-large HIT immune complexes. *Blood* 2021; published online June 29. <https://doi.org/10.1182/blood.202009487>.
- Pomara C, Sessa F, Ciaccio M, et al. Post-mortem findings in vaccine-induced thrombotic thrombocytopenia. *Haematologica* 2021; **106**: 2291–93.
- Rodeghiero F, Balduini CL. A new enemy is emerging in the fight against the SARS-CoV-2 pandemic. *Haematologica* 2021; **106**: 2040–41.
- Huynh A, Kelton JG, Arnold DM, Daka M, Nazy I. Antibody epitopes in vaccine-induced immune thrombotic thrombocytopenia. *Nature* 2021; **596**: 565–69.
- Baker AT, Boyd RJ, Sarkar D, et al. The structure of ChAdOx1/AZD-1222 reveals interactions with CAR and PF4 with implications for vaccine-induced immune thrombotic thrombocytopenia. *bioRxiv* 2021; published May 24. <https://doi.org/10.1101/2021.05.19.444882> (preprint).
- McGonagle D, De Marco G, Bridgewood C. Mechanisms of immunothrombosis in vaccine-induced thrombotic thrombocytopenia (VITT) compared to natural SARS-CoV-2 infection. *J Autoimmun* 2021; **121**: 102662.
- Othman M, Labelle A, Mazzetti I, Elbatarny HS, Lillicrap D. Adenovirus-induced thrombocytopenia: the role of von Willebrand factor and P-selectin in mediating accelerated platelet clearance. *Blood* 2007; **109**: 2832–39.
- Alba R, Bradshaw AC, Parker AL, et al. Identification of coagulation factor (F)X binding sites on the adenovirus serotype 5 hexon: effect of mutagenesis on FX interactions and gene transfer. *Blood* 2009; **114**: 965–71.
- Gupalo E, Kuk C, Qadara M, Buriachkovskaia I, Othman M. Platelet-adenovirus vs inert particles interaction: effect on aggregation and the role of platelet membrane receptors. *Platelets* 2013; **24**: 383–91.
- Kowarz E, Krutzke L, Reis J, Bracharz S, Kochanek S, Marschalek R. "Vaccine-induced COVID-19 mimicry" syndrome: splice reactions within the SARS-CoV-2 spike open reading frame result in spike protein variants that may cause thromboembolic events in patients immunized with vector-based vaccines. *Research Square* 2021; published online May 26. <https://doi.org/10.21203/rs.3.rs-558954/v1>.
- Krutzke L, Roesler R, Wiese S, Kochanek S. Process-related impurities in the ChAdOx1 n-Cov-19 vaccine. *Res Sq* 2021; published May 4. <https://www.researchsquare.com/article/rs-477964/v1> (preprint).
- Chan B OA, Jüni P, et al. Risk of vaccine-induced thrombotic thrombocytopenia (VITT) following the AstraZeneca/COVISHIELD adenovirus vector COVID-19 vaccines. May 11, 2021. <https://covid19-sciencetable.ca/sciencebrief/risk-of-vaccine-induced-thrombotic-thrombocytopenia-vitt-following-the-astrazeneca-covishield-adenovirus-vector-covid-19-vaccines/> (accessed Sept 12, 2021).

See Online for appendix

- 30 Arepally GM, Ortel TL. Vaccine-induced immune thrombotic thrombocytopenia: what we know and do not know. *Blood* 2021; **138**: 293–98.
- 31 Greinacher A, Selleng K, Mayerle J, et al. Anti-platelet factor 4 antibodies causing VITT do not cross-react with SARS-CoV-2 spike protein. *Blood* 2021; **138**: 1269–77.
- 32 Uzun G, Althaus K, Bakchoul T. No Correlation between anti-PF4 and anti-SARS-CoV-2 antibodies after ChAdOx1 nCoV-19 vaccination. *N Engl J Med* 2021; **385**: 1334–36.
- 33 NICE. COVID-19 rapid guideline: vaccine-induced immune thrombocytopenia and thrombosis (VITT). <https://www.nice.org.uk/guidance/ng200/resources/fully-accessible-version-of-the-guideline-pdf-pdf-51036811744> (accessed Aug 8, 2021).
- 34 van Dam LF, van Walderveen MAA, Kroft LJM, et al. Current imaging modalities for diagnosing cerebral vein thrombosis—critical review. *Thromb Res* 2020; **189**: 132–39.
- 35 Huisman MV, Barco S, Cannegieter SC, et al. Pulmonary embolism. *Nat Rev Dis Primers* 2018; **4**: 18028.
- 36 Huisman MV, Klok FA. Diagnostic management of acute deep vein thrombosis and pulmonary embolism. *J Thromb Haemost* 2013; **11**: 412–22.
- 37 Ageno W, Dentali F, Squizzato A. How I treat splanchnic vein thrombosis. *Blood* 2014; **124**: 3685–91.
- 38 Expert Haematology Group. Guidance from the Expert Haematology Panel (EHP) on COVID-19 vaccine-induced immune thrombocytopenia and thrombosis (VITT). <https://b-s-h.org.uk/media/19718/guidance-v20-20210528-002.pdf> (accessed Aug 8, 2021).
- 39 Neunert C, Lim W, Crowther M, et al. The American Society of Hematology 2011 evidence-based practice guideline for immune thrombocytopenia. *Blood* 2011; **117**: 4190–207.
- 40 Zheng XL, Vesely SK, Cataland SR, et al. ISTH guidelines for treatment of thrombotic thrombocytopenic purpura. *J Thromb Haemost* 2020; **18**: 2496–502.
- 41 Nazy I, Sachs UJ, Arnold DM, et al. Recommendations for the clinical and laboratory diagnosis of VITT against COVID-19: communication from the ISTH SSC Subcommittee on Platelet Immunology. *J Thromb Haemost* 2021; **19**: 1585–88.
- 42 Oldenburg J, Klamroth R, Langer F, et al. Diagnosis and management of vaccine-related thrombosis following AstraZeneca COVID-19 vaccination: guidance statement from the GTH. *Hamostaseologie* 2021; **41**: 184–89.
- 43 Handtke S, Wolff M, Zaninetti C, et al. A flow cytometric assay to detect platelet-activating antibodies in VITT after ChAdOx1 nCov-19 vaccination. *Blood* 2021; **137**: 3656–59.
- 44 Franchini M, Liumbruno GM, Pezzo M. COVID-19 vaccine-associated immune thrombosis and thrombocytopenia (VITT): diagnostic and therapeutic recommendations for a new syndrome. *Eur J Haematol* 2021; **107**: 173–80.
- 45 Platton S, Bartlett A, MacCallum P, et al. Evaluation of laboratory assays for anti-platelet factor 4 antibodies after ChAdOx1 nCoV-19 vaccination. *J Thromb Haemost* 2021; **19**: 2007–13.
- 46 Jacobson BF, Schapkaite E, Mer M, et al. Recommendations for the diagnosis and management of vaccine-induced immune thrombotic thrombocytopenia. *S Afr Med J* 2021; **111**: 535–37.
- 47 Tiede A, Sachs UJ, Czwalińska A, et al. Prothrombotic immune thrombocytopenia after COVID-19 vaccination. *Blood* 2021; **138**: 350–53.
- 48 Warkentin TE. High-dose intravenous immunoglobulin for the treatment and prevention of heparin-induced thrombocytopenia: a review. *Expert Rev Hematol* 2019; **12**: 685–98.
- 49 Greinacher A. Clinical practice. Heparin-induced thrombocytopenia. *N Engl J Med* 2015; **373**: 252–61.
- 50 Uzun G, Althaus K, Singh A, et al. The use of intravenous immunoglobulin in the treatment of vaccine-induced immune thrombotic thrombocytopenia. *Blood* 2021; **138**: 992–96.
- 51 Schulz JB, Berlit P, Diener HC, et al. COVID-19 Vaccine-associated cerebral venous thrombosis in Germany. *Ann Neurol* 2021; **90**: 627–39.
- 52 Bourguignon A, Arnold DM, Warkentin TE, et al. Adjunct immune globulin for vaccine-induced immune thrombotic thrombocytopenia. *N Engl J Med* 2021; **385**: 720–28.
- 53 Patriquin CJ, Laroche V, Selby R, et al. Therapeutic plasma exchange in vaccine-induced immune thrombotic thrombocytopenia. *N Engl J Med* 2021; **385**: 857–59.
- 54 Ropper AH, Klein JP. Cerebral venous thrombosis. *N Engl J Med* 2021; **385**: 59–64.
- 55 Furie KL, Cushman M, Elkind MSV, Lyden PD, Saposnik G, American Heart Association/American Stroke Association Stroke Council L. Diagnosis and management of cerebral venous sinus thrombosis with vaccine-induced immune thrombotic thrombocytopenia. *Stroke* 2021; **52**: 2478–82.
- 56 Konstantinides SV, Meyer G, Becattini C, et al. 2019 ESC Guidelines for the diagnosis and management of acute pulmonary embolism developed in collaboration with the European Respiratory Society (ERS). *Eur Heart J* 2020; **41**: 543–603.
- 57 Di Nisio M, Valeriani E, Riva N, Schulman S, Beyer-Westendorf J, Ageno W. Anticoagulant therapy for splanchnic vein thrombosis: ISTH SSC Subcommittee Control of Anticoagulation. *J Thromb Haemost* 2020; **18**: 1562–68.
- 58 Simonetto DA, Singal AK, Garcia-Tsao G, Caldwell SH, Ahn J, Kamath PS. ACG Clinical guideline: disorders of the hepatic and mesenteric circulation. *Am J Gastroenterol* 2020; **115**: 18–40.
- 59 Perry RJ, Tamborska A, Singh B, et al. Cerebral venous thrombosis after vaccination against COVID-19 in the UK: a multicentre cohort study. *Lancet* 2021; **398**: 1147–56.
- 60 Favaloro EJ. Laboratory testing for suspected COVID-19 vaccine-induced (immune) thrombotic thrombocytopenia. *Int J Lab Hematol* 2021; **43**: 559–70.
- 61 Schonborn L, Thiele T, Kaderali L, Greinacher A. Decline in pathogenic antibodies over time in VITT. *N Engl J Med* 2021; published online Sept 8. <https://doi.org/10.1056/NEJMc2112760>.
- 62 Shaw RH, Stuart A, Greenland M, et al. Heterologous prime-boost COVID-19 vaccination: initial reactogenicity data. *Lancet* 2021; **397**: 2043–46.
- 63 Tenbusch M, Schumacher S, Vogel E, et al. Heterologous prime-boost vaccination with ChAdOx1 nCoV-19 and BNT162b2. *Lancet Infect Dis* 2021; **21**: 1212–13.

© 2021 Elsevier Ltd. All rights reserved.