

Abdominal cocoon

Binit Sureka, Mahesh Kumar Mittal, Mukul Sinha, Aliza Mittal, Brij Bhushan Thukral

Department of Radiodiagnosis and Imaging, Vardhman Mahavir Medical College and Safdarjung Hospital, New Delhi, India

Access this article online

Website: www.avicennajmed.com

DOI: 10.4103/2231-0770.120502

Quick Response Code:



ABSTRACT

Abdominal cocoon is an acquired benign condition in which there is encapsulation of bowel loops by a fibrous membrane. Pre-operative clinical diagnosis is usually difficult. Imaging plays a critical role in timely and accurate diagnosis. We present a brief discussion on this topic with relevant imaging findings.

Key words: Abdominal, cocoon, encapsulation, peritonitis

INTRODUCTION

Abdominal cocoon is a rare condition characterized by encapsulation of bowel loops by fibrocollagenous membrane. Previously in 1907, Owtschinnikow described it as “peritonitis chronica fibrosa incapsulata.”^[1] This entity is more common in females from tropical regions.^[2,3]

DISCUSSION

Abdominal cocoon also known as sclerosing encapsulating peritonitis was first described by Foo *et al.* in 1978.^[4] It is a benign condition in which there is encasement of the small bowel by a cocoon like sac. The sac is a fibrocollagenous membrane. Predisposing factors for abdominal cocoon formation are history of previous abdominal surgery, peritonitis, chronic ambulatory peritoneal dialysis, infections such as tuberculosis, prolonged use of practolol, liver transplant, biliary tract and gastrointestinal tract inflammation.^[5,6] When the cause is not known it is classified as primary (idiopathic). Clinical diagnostic clues are presentation in a young adolescent girl, non-tender soft mass and intermittent episodes of intestinal obstruction. Two clinical signs, which are important in diagnosing this entity are: “Fixed, asymmetrical distension of the abdomen and difference in the consistency of the abdominal wall to palpation.”^[7,8] The flat area is firm, due to the dense fibrous capsule and the distended area soft, due to the thin walled distended small intestine with no overlying fibrous layer.

Pathogenesis for abdominal cocoon formation is increased release of fibrogenic cytokines leading to fibrin like material deposition on the peritoneum.^[6]

On imaging, plain radiographs may show dilated bowel loops with air-fluid level clustered in the mid abdomen. Barium-meal follow through examination show classical clustering and conglomeration of bowel loops in the center of the abdomen, which remains in same location on delayed films [Figure 1]. Proximal bowel obstruction is usually seen [Figure 2]. Transit time is increased. Cauliflower appearance of bowel loops may be noted due to concertina arrangement of loops. On ultrasonography, echogenic mass of dilated small-bowel loops surrounded by a thick rim of hypoechoic fibrous membrane is seen. On computed tomography (CT), fibrous membrane surrounding the bowel loops is usually seen and is diagnostic [Figures 3 and 4]. This encapsulation may be partial or complete. Other signs on CT are obstruction, agglutination and the fixation of intestinal loops, mural thickening, ascites, localized fluid collections, peritoneal thickening and enhancement, peritoneal or mural calcifications and reactive adenopathy [Figure 5].^[2,5]

Differential diagnosis on CT includes congenial peritoneal encapsulation. It is usually asymptomatic, found in older patients and characterized by a thin accessory peritoneal sac surrounding the small bowel behind omentum. Differential diagnoses on Barium examination are adhesions, closed bowel loop, strangulation, hernia, carcinoid tumors,

Address for correspondence: Dr. Binit Sureka, Department of Radiodiagnosis and Imaging, Vardhman Mahavir Medical College and Safdarjung Hospital, New Delhi - 110 029, India. E-mail: binit sureka@hotmail.com

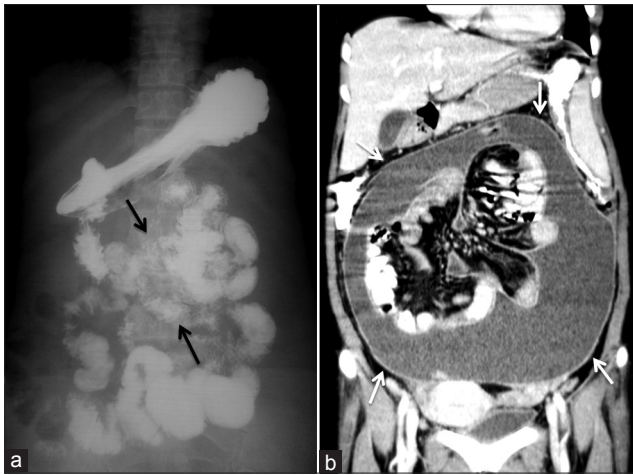

Figure 1: Abdominal cocoon in a 37-year-old male on dialysis. (a) Barium meal follow through spot image showing clustered fixed small bowel loops (arrows). (b) Coronal reformatted computed tomography image showing encapsulating membrane (arrows) with ascites and clustering of small bowel loops

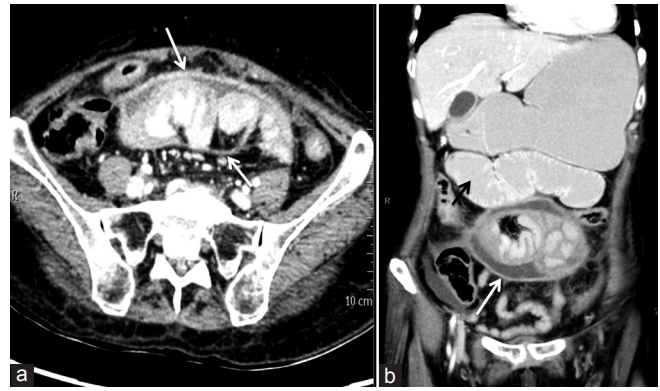


Figure 2: Abdominal cocoon formation in 30-year-old male with previous abdominal surgery. (a) Axial contrast-enhanced computed tomography scan showing clustering of bowel loops with fibrotic enhancing membrane (arrows). (b) Coronal reformatted image showing the encapsulation of ileal loops in a membrane (white arrow) with fluid collection within the sac and dilatation of proximal jejunum (black arrow)

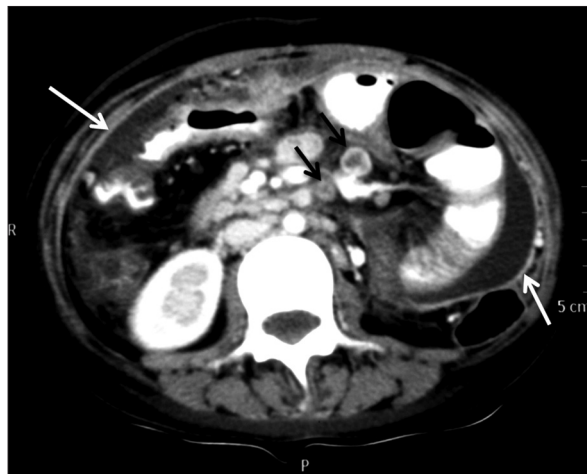

Figure 3: Abdominal cocoon due to tuberculosis in 35-year-old female - axial contrast-enhanced computed tomography showing enhancing fibrotic membrane (white arrows) with ascites and focal dilatation of jejunal loop and necrotic mesenteric lymph nodes (black arrow)

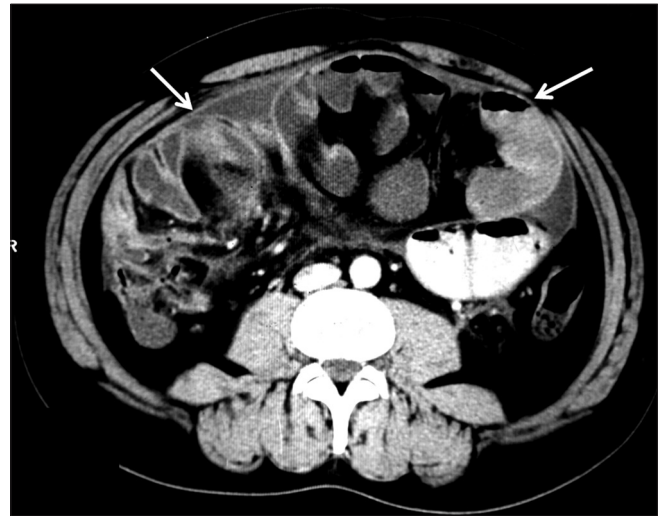


Figure 4: Idiopathic abdominal cocoon in a 24-year-old girl - axial contrast-enhanced computed tomography scan showing membrane (arrows) encapsulating the jejunal loops

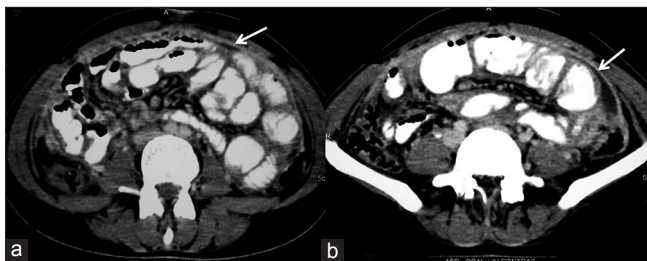


Figure 5: Abdominal cocoon in 40-year-old male due to previous abdominal surgery (a, b) axial contrast-enhanced computed tomography showing enhancing membrane (arrows) and focal dilatation of jejunal loop

lymphoma, peritoneal carcinomatosis, radiation enteropathy, bezoars and internal hernia.^[9]

This condition has a favorable outcome. Release and removal of the membrane and treating the underlying etiology is the treatment of choice.

REFERENCES

- Owtschinnikow PJ. Peritonitis chronica fibrosa incapsulata. Arch Klin Chir 1907;83:623-34.
- Sieck JO, Cowgill R, Larkworthy W. Peritoneal encapsulation and abdominal cocoon. Case reports and a review of the literature. Gastroenterology 1983;84:1597-601.
- Deeb LS, Mourad FH, El-Zein YR, Uthman SM. Abdominal cocoon in a man: Preoperative diagnosis and literature review. J Clin Gastroenterol 1998;26:148-50.
- Foo KT, Ng KC, Rauff A, Foong WC, Sinniah R. Unusual small intestinal obstruction in adolescent girls: The abdominal cocoon. Br J Surg 1978;65:427-30.
- Hur J, Kim KW, Park MS, Yu JS. Abdominal cocoon: Preoperative diagnostic clues from radiologic imaging with pathologic correlation. AJR Am J Roentgenol 2004;182:639-41.
- Gupta S, Shirahatti RG, Anand J. CT findings of an abdominal cocoon. AJR Am J Roentgenol 2004;183:1658-60.
- Naraynsingh V, Maharaj D, Singh M, Ramdass MJ. Peritoneal encapsulation: A preoperative diagnosis is possible. Postgrad Med J

2001;77:725-6.

8. Yip FW, Lee SH. The abdominal cocoon. *Aust N Z J Surg* 1992;62:638-42.
9. Demir MK, Akinci O, Onur E, Koksal N. Case 108: Sclerosing encapsulating peritonitis. *Radiology* 2007;242:937-9.

Cite this article as: Sureka B, Mittal MK, Sinha M, Mittal A, Thukral BB. Abdominal cocoon. *Avicenna J Med* 2013;3:103-5.

Source of Support: Nil, **Conflict of Interest:** None declared.

Author Help: Reference checking facility

The manuscript system (www.journalonweb.com) allows the authors to check and verify the accuracy and style of references. The tool checks the references with PubMed as per a predefined style. Authors are encouraged to use this facility, before submitting articles to the journal.

- The style as well as bibliographic elements should be 100% accurate, to help get the references verified from the system. Even a single spelling error or addition of issue number/month of publication will lead to an error when verifying the reference.
- Example of a correct style
Sheahan P, O'leary G, Lee G, Fitzgibbon J. Cystic cervical metastases: Incidence and diagnosis using fine needle aspiration biopsy. *Otolaryngol Head Neck Surg* 2002;127:294-8.
- Only the references from journals indexed in PubMed will be checked.
- Enter each reference in new line, without a serial number.
- Add up to a maximum of 15 references at a time.
- If the reference is correct for its bibliographic elements and punctuations, it will be shown as CORRECT and a link to the correct article in PubMed will be given.
- If any of the bibliographic elements are missing, incorrect or extra (such as issue number), it will be shown as INCORRECT and link to possible articles in PubMed will be given.