

---

# Tacrolimus-Induced Intestinal Angioedema: Diagnosis by Capsule Endoscopy

I. Zvidi E. Gal R. Rachamimov Y. Niv

Department of Gastroenterology, Rabin Medical Center, Beilinson Hospital, Tel Aviv University, Petach Tikva, Israel

## Key Words

Tacrolimus · Diarrhea · Transplantation · Capsule endoscopy

## Abstract

Small intestinal angioedema has been reported with angiotensin converting enzyme inhibitors therapy, but not in implanted patients treated with tacrolimus. We present a kidney transplanted patient, hospitalized with severe diarrhea, diagnosed with tacrolimus-induced intestinal angioedema with abdominal computerized tomography and capsule endoscopy. To the best of our knowledge this is the first described case of tacrolimus-induced small bowel angioedema diagnosed with capsule endoscopy.

## Introduction

Intestinal angioedema has been reported after angiotensin converting enzyme inhibitors (ACEI) treatment [1]. These patients present with abdominal pain, nausea or vomiting; in some cases there is no history of facial angioedema and C-1 esterase levels are normal. In most of the cases intestinal angioedema is diagnosed by computerized tomography (CT), ultrasound, or at surgery, and symptoms resolve after stopping the drugs. The main feature of the disease in these modalities is the demonstration of thickened small intestinal loops.

Tacrolimus is a calcineurin antagonist used for suppression of the immune system, preventing rejection of transplanted organs [2]. Tacrolimus can induce diarrhea in post-transplant patients [3]. In most of the cases tacrolimus-induced diarrhea is self limited and resolves after dose reduction. Lecture et al. described food allergies induced by tacrolimus that occur via passive transfer [4]. The prevalence of this phenomenon is 10–17% in children and 1.5% in adults [5, 6].

We present a kidney transplanted patient, hospitalized with severe diarrhea, who was diagnosed with tacrolimus-induced intestinal angioedema.

## Case History

A 19-year-old woman who had undergone orthotopic kidney transplantation in 2004 for membranoproliferative glomerulonephritis was hospitalized 2 years later because of severe, watery diarrhea, diffuse abdominal pain and fatigue. She was on immunomodulatory treatment with tacrolimus and prednisone. In addition her medication list included lercanidipine, enalapril, prolo, clonidine, omeprazole, furosemide and calcium. She had 10 bowel movements a day with a total volume of 800 ml. A fasting trial did not change her stool volume or frequency.

At presentation her vital signs were normal and she was afebrile. Physical examination revealed hypoactive bowel sounds and diffuse abdominal tenderness. She was treated by NPO (nothing per mouth) and got liquids and electrolytes intravenously. Laboratory tests demonstrated normal liver aminotransferases, bilirubin, alkaline phosphatase, amylase, lipase, and prothrombin time ([table 1](#)). Serum gastrin level, thyroid stimulating hormone (TSH) and C-reactive protein (CRP) were normal. Urine pregnancy test was negative. Serum albumin was 2.4 g/dl (normal 3.5–5.0 g/dl). Stool studies for leukocyte, bacterial or viral organisms, *Clostridium difficile* toxin, ova and parasites as well as cytomegalovirus antigenemia were negative. Serology tests for human immunodeficiency virus (HIV) and tissue transglutaminase were negative. Urine collection for 5-hydroxy indol acetic acid (5-HIAA) was normal. Blood and urine cultures were sterile.

Colonoscopy with random biopsies, esophago-gastro-duodenoscopy and small bowel series were normal. An abdominal CT scan showed markedly thickened loops of the proximal part of the small bowel ([fig. 1](#)). Capsule endoscopy (Pillcam SB, Given Imaging, Yotneam, Israel) revealed severe edema and congestion in several segments of the duodenum and proximal jejunum ([fig. 2](#)). Enteroscopy to the distal jejunum was normal, but small bowel biopsies revealed edema of the villi ([fig. 3](#)).

A diagnosis of small bowel angioedema was made, and tacrolimus and ACEI were discontinued. The diarrhea and abdominal pain resolved gradually and disappeared within 3 weeks. Serum albumin increased to 4.2 g/dl. A challenge with tacrolimus only, which is considered essential for prevention of rejection, caused an immediate bout of severe diarrhea. The drug was stopped and the diarrhea resolved within 48 h.

## Discussion

Diarrhea is common after solid organ transplantation with an incidence rate of 10–43% [7]. Infectious etiologies, including cytomegalovirus (CMV), *Clostridium difficile*, and occasional atypical intestinal infections, are the most common causes. Diarrhea is also a frequent side effect of immunosuppressive medications. To a variable extent, mycophenolate mofetil, cyclosporine A, tacrolimus, and sirolimus are all known to be associated with diarrhea. Rarely, graft-versus-host disease, lymphoproliferative disorder, de novo inflammatory bowel disease (IBD), or colon cancer may present with diarrhea.

Angioneurotic edema is a poorly understood and rare complication that occurs in approximately 0.1–0.5% of immunosuppressed patients receiving ACE inhibitors [8]. Immunosuppression may be responsible for the increased prevalence of ACEI peripheral angioedema, but drug-specific antibodies have not been previously detected [9]. Immunosuppression may, however, modulate ACEI angioedema by its effects on the control of inflammatory mediators and antigen-antibody interactions, possibly within the small intestine.

In our patient, both abdominal CT and capsule endoscopy show markedly thickened walls and mucosa of the distal part of the duodenum and proximal part of the jejunum. This characteristic imaging was previously reported on abdominal CT in cases treated

with ACEIs and developing intestinal angioedema [10–14]. This is the first description of intestinal angioedema on capsule endoscopy in the literature. Enteroscopy was negative probably because of air insufflation and bowel distention, but histology confirmed the diagnosis.

This is the first case of isolated visceral angioedema known to occur after solid-organ transplantation. Visceral angioedema was considered in this case to be the result of the temporal association of symptoms with initiation of an ACEI and the absence of an alternative diagnosis suggestive of ischemia, infection, mechanical obstruction, inflammatory bowel disease, and vasculitis, all of which may present similarly. The diagnosis of an immune-mediated inflammatory condition was believed to be unlikely because the patient was on immunosuppression with adequate therapeutic levels. The inadvertent rechallenge with tacrolimus precipitated recurrent symptoms, but after discontinuing the drug she has remained symptom-free and with excellent clinical status.

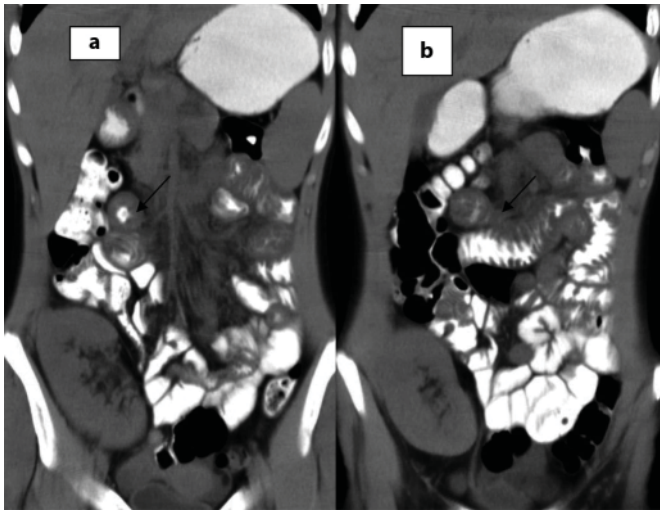
We conclude that visceral angioedema should be considered as a possible explanation for severe diarrhea and abdominal pain in transplanted patients taking tacrolimus. We hope that this report increases awareness of this under-diagnosed complication. Capsule endoscopy, a relatively new procedure for small bowel investigation, can be used for a positive diagnosis.

**Table 1.** Selected laboratory results

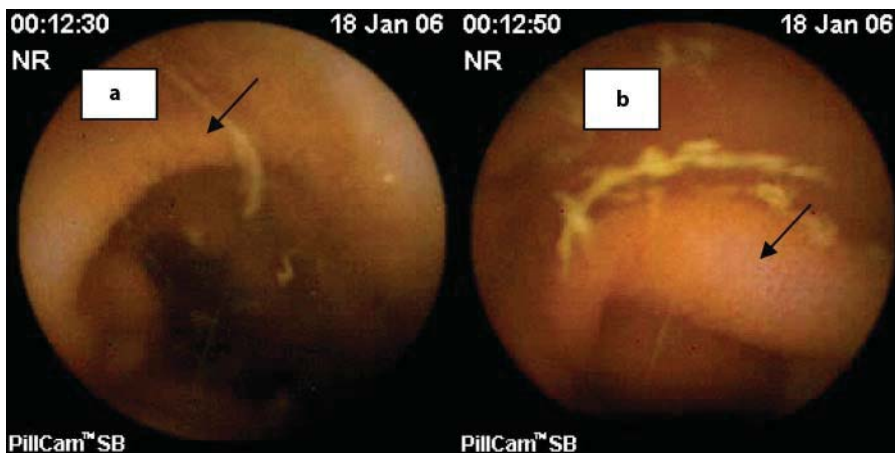
Test	Result	Normal range
WBC, K/dl	6.11	4.8–10.8
Hb, g/dl	11.8	14–17.5
PLT, K/dl	237	140–420
MCV, fl	81	80–96
MCH, %	29.4	26–32
Urea, ml/dl	71	10–50
Creatinine, mg/dl	1.87	0.7–1.2
Calcium, mg/dl	8.4	8.2–10.5
Total protein, g/dl	4.3	6–8.5

WBC = White blood cells; Hb = hemoglobin; PLT = platelets;  
MCV = mean corpuscular volume; MCH = mean corpuscular  
hemoglobin.

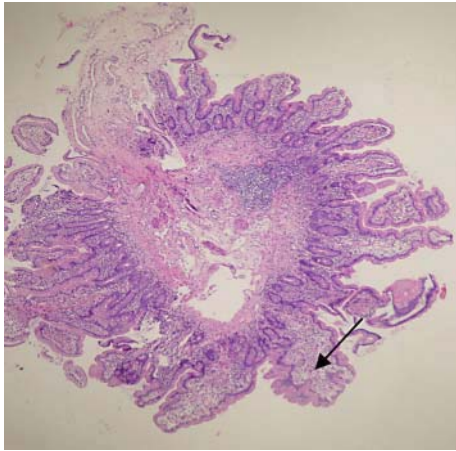
**Fig. 1.** Computerized tomography demonstrates small bowel edema.



**Fig. 2.** Capsule endoscopy demonstrates small bowel mucosal edema.



**Fig. 3.** Histology reveals villi edema.



## References

- 1 Rosenberg EI, Mishra G, Abdelmalek MF: Angiotensin-converting enzyme inhibitor-induced isolated visceral angioedema in a liver transplant recipient. *Transplantation* 2003;75:730–732.
- 2 Boswell A, Evans L, Rigg K, Shehata M: The safety and efficacy of early withdrawal of calcineurin inhibitors in kidney transplant recipients 6 months' posttransplant. *Transplant Proc* 2005;37:884–885.
- 3 Ringe B, Braun F, Schutz E, Fuzesi L, Lorf T, Canelo R, Oellerich M, Ramadori G: A novel management strategy of steroid-free immunosuppression after liver transplantation: efficacy and safety of tacrolimus and mycophenolate mofetil. *Transplantation* 2001;71:508–515.
- 4 Özdemir O, Arrey-Mensah A, Sorensen RU: Development of multiple food allergies in children taking tacrolimus after heart and liver transplantation. *Pediatr Transplant* 2006;10:380–383.
- 5 Mittal N, Thompson JF, Kato T, Tzakis AG: Tacrolimus and diarrhea: pathogenesis of altered metabolism. *Pediatr Transplant* 2001;5:75–79.
- 6 Morales JM, Andres A, Domiguez-Gil B, Arriola M, Gutierrez MJ, Hernandez E, Ortuno T, Praga M: Ten years of treatment with tacrolimus is related to an excellent renal function. *Transplant Proc* 2005;37:3738–3742.
- 7 Ginsburg PM, Thuluvath PJ: Diarrhea in liver transplant recipients: etiology and management. *Liver Transpl* 2005;11:881–890.
- 8 Israili ZH, Hall WD: Cough and angioneurotic edema associated with angiotensin-converting enzyme inhibitor therapy. A review of the literature and pathophysiology. *Ann Intern Med* 1992;117:234–242.
- 9 Abbosh J, Anderson JA, Levine AB, Kupin WL: Angiotensin converting enzyme inhibitor-induced angioedema more prevalent in transplant patients. *Ann Allergy Asthma Immunol* 1999;82:473–476.
- 10 Abdelmalek MF, Douglas DD: Lisinopril-induced isolated visceral angioedema: review of ACE-inhibitor-induced small bowel angioedema. *Dig Dis Sci* 1997;42:847–850.
- 11 Mullins RJ, Shanahan TM, Dobson RT: Visceral angioedema related to treatment with an ACE inhibitor. *Med J Aust* 1996;165:319–321.
- 12 Malcolm A, Prather CM: Intestinal angioedema mimicking Crohn's disease. *Med J Aust* 1999;171:418–420.
- 13 Jardine DL, Anderson JC, McClintock AD: Delayed diagnosis of recurrent visceral angioedema secondary to ACE inhibitor therapy. *Aust NZ J Med* 1999;29:377–378.
- 14 Byrne TJ, Douglas DD, Landis ME, Heppell JP: Isolated visceral angioedema: an underdiagnosed complication of ACE inhibitors? *Mayo Clin Proc* 2000;75:1202–1204.