

# Transfemoral snare–assisted placement of a left-sided defibrillator lead in the presence of a persistent left superior vena cava



Saif Ali, MD,\* Amber Mohammed, BS,<sup>†</sup> Michael Co, MD,\* Kamal Kotak, MD, FHRS,\* Ravi Mandapati, MD, FHRS,\* Tahmeed Contractor, MD\*

From the \*Department of Cardiology, Loma Linda University Medical Center, Loma Linda, California, and <sup>†</sup>College of Business Administration, University of Illinois at Chicago, Chicago, Illinois.

## Introduction

Persistent left superior vena cava (PLSVC) represents a rare venous anomaly that can make left-sided implantation of cardiac devices, especially implantable cardioverter-defibrillators (ICD), challenging. PLSVC is an embryologic remnant that connects the left subclavian vein to the coronary sinus (CS, [Supplemental Figure S1](#)) or sometimes drains directly into the left atrium.<sup>1</sup> Previously reported techniques for delivering left-sided leads into the right ventricle (RV) involved specially curved stylets or use of a communicating branch of the PLSVC.<sup>2–7</sup> As opposed to pacemaker leads, stylets are not as effective for redirecting ICD leads from the CS ostium toward the tricuspid annulus. In the absence of a communicating vein between the right-sided superior vena cava and PLSVC, right-sided implant may be required that is associated with higher defibrillation threshold (DFT).<sup>8</sup>

We report a case in which transfemoral snaring was utilized to deliver a defibrillator lead through a PLSVC into the RV after several failed attempts using curved stylets. Using a transfemoral multilobed snare within an Agilis sheath, the ICD lead tip was captured within the CS and steered toward the RV to allow successful left-sided ICD implantation in a patient with PLSVC.

## Case report

A 14-year-old male patient was admitted with sudden cardiac arrest due to ventricular fibrillation and he achieved full neurological recovery. Electrocardiogram was within normal limits. Transthoracic echo revealed mild left ventricular

**KEYWORDS** Implantable cardioverter-defibrillator; Long QT syndrome; Multilobed snare; Persistent left superior vena cava; Transfemoral snare (Heart Rhythm Case Reports 2021;7:558–561)

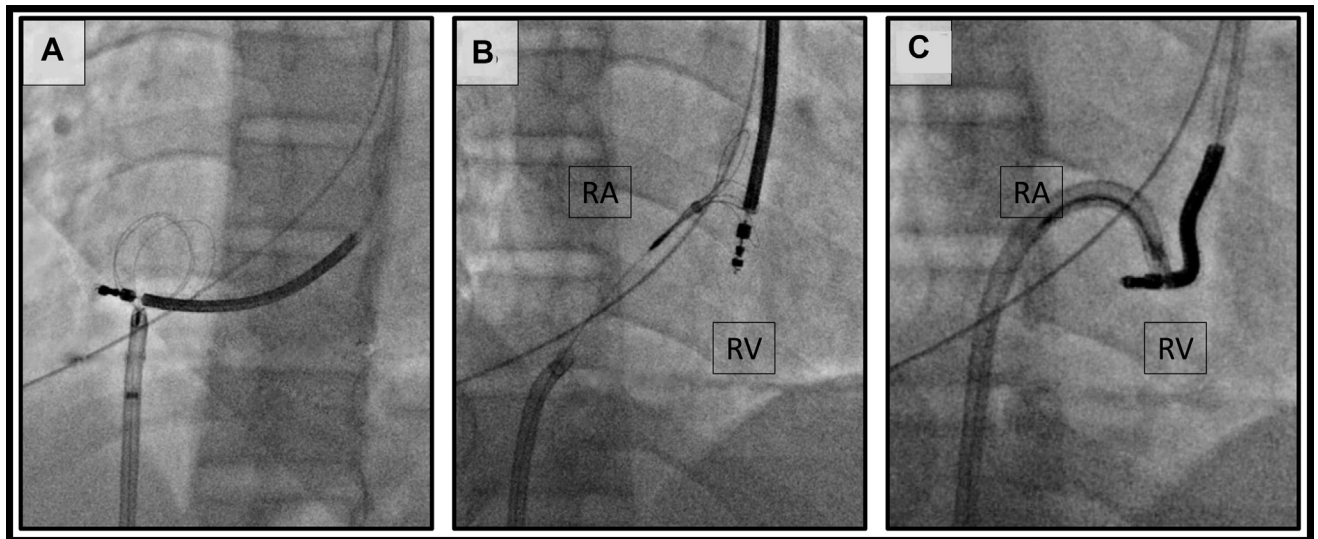
Conflict of interest statement: Tahmeed Contractor has received speaker's honorarium from Medtronic. Funding: This research did not receive any specific grant from funding agencies in the public, commercial, or not-for-profit sectors. **Address reprint requests and correspondence:** Dr Tahmeed Contractor, Loma Linda University Medical Center, 11234 Anderson St, Loma Linda, CA 92354. E-mail address: [tahmeedcontractor@gmail.com](mailto:tahmeedcontractor@gmail.com).

## KEY TEACHING POINTS

- Isolated persistent left superior vena cava is a rare venous anomaly that can make left-sided device implantation extremely challenging.
- Delivering a right ventricular lead from the left side in persistent left superior vena cava may be accomplished if a communicating vein is present or with the use of specially shaped stylets or delivery sheaths.
- A transfemoral snare within a steerable sheath can be used to navigate a right ventricular lead through the posteriorly directed coronary sinus, create an alpha loop in the right atrium, and direct the lead past the tricuspid valve.

hypertrophy and a dilated CS owing to the presence of a PLSVC ([Supplemental Figure S2A](#)). Cardiac magnetic resonance imaging ([Supplemental Figure S2B](#)) showed normal coronary artery take-offs and no communicating vein between the right and left superior vena cava. Electrophysiology study demonstrated epinephrine-induced paradoxical QT prolongation suggestive of long QT syndrome. Dual-chamber ICD implantation was pursued.

Options of care were considered in terms of site of ICD placement. The patient was right-handed and while a right-sided implant would have been technically easier given the absence of a communicating vein, it would have higher DFT and potential detrimental impact to quality of life given his handedness. We thus decided to attempt left-sided placement given our prior successful experiences with the use of manually curved stylets. An incision in the left pectoral area and axillary venous access were performed. A 9F 25 cm sheath (Pressure Product, Fort Worth, TX) was inserted over a guidewire. Several attempts at advancing a Medtronic



**Figure 1** Snaring of the defibrillator lead. **A:** Left anterior oblique view of the defibrillator lead passing through the coronary sinus and being pointed laterally in the right atrium. Also visualized is an Atrieve multilobed snare (Argon Medical Devices, Frisco, TX) advanced within an 8.5F medium curve Agilis NXT sheath (Abbott Inc, Abbott Park, IL). **B:** Right anterior oblique view of the defibrillator lead and the multilobed snare inside the coronary sinus permitting easy advancement of the defibrillator lead into 1 of the lobes of the snare. **C:** Right anterior oblique view of the defibrillator lead snared and pulled against the tip of the Agilis sheath. Careful antelexion of the Agilis sheath with counterclockwise torque allows for movement of defibrillator lead adjacent to the tricuspid annulus. RA = right atrium; RV = right ventricle.

6935 ICD lead (Medtronic Inc, Minneapolis, MN) into the RV with a variety of manually curved stylets proved difficult. Owing to severe angulation from the CS ostium toward the tricuspid annulus (Figure 1A), the lead either recoiled retrograde into the CS or looped within the RA. Despite the use of multiple manually shaped stylets, we could not point the distal aspect of the lead toward the tricuspid valve (TV) annulus to advance the ICD lead past the annulus. There was no curved delivery sheath available that was large enough to accommodate the lead. We elected to use a transfemoral snare to capture the lead within the right atrium (RA) and deliver it to the RV.

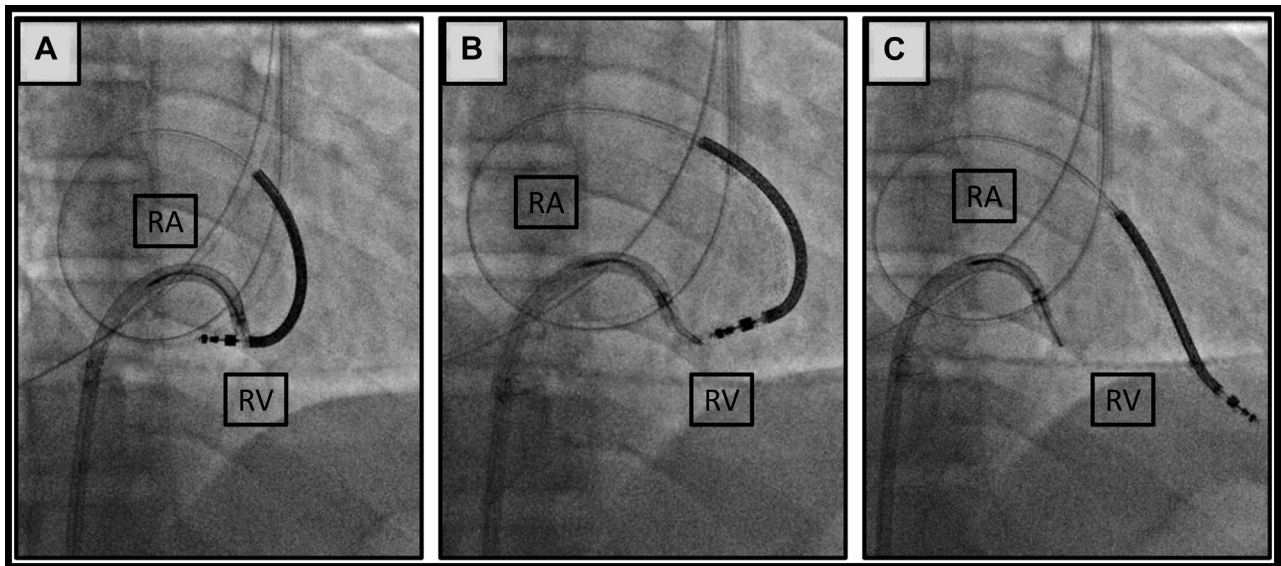
The right groin was sterilized, and ultrasound-guided femoral vein access was obtained. An 8.5F medium curve Agilis NXT sheath (Abbott Inc, Abbott Park, IL) was placed in the RA, through which an Atrieve multilobed snare (Argon Medical Devices, Frisco, TX) was advanced into the enlarged CS in an open position. The ICD lead was pulled back and advanced through the lobes, after which the snare sheath was advanced to secure the lead (Figure 1B). The snare was pulled back from the body to grip the tip of the lead. The Agilis sheath was retracted into the RA and carefully antelexed toward the tricuspid annulus with counterclockwise torque (Figure 1C). The distal end of the ICD lead was kept stationary near the tricuspid annulus while the proximal end was advanced until an “alpha curve” was achieved in the RA, which allowed the distal aspect of the lead (RV coil) to prolapse toward the annulus (Figure 2A). Once the tip was released from the snare (Figure 2B), the distal aspect of the lead, including the tip, advanced into the RV (Figure 2C). After advancing a stylet, the lead was actively fixed into the right ventricular apical septal area with excellent current of

injury, pacing, and sensing thresholds (8.5 mV R waves, 0.5 V at 0.4 ms, pacing impedance 437 ohms, high-voltage impedance 56 ohms). A right atrial lead and generator were implanted, and the incision was closed (Figure 3). We performed DFT testing, which resulted in adequate sensing of induced ventricular fibrillation and successful defibrillation using 20 joules with restoration of normal sinus rhythm.

## Discussion

Placement of a left-sided ICD lead in a patient with PLSVC in the absence of a communicating vein can be very challenging. We report a case where transfemoral snaring of an ICD lead was used to overcome the unfavorable anatomy of a PLSVC to implant a left-sided device in a young patient with ventricular fibrillation.

Transvenous leads entering the RA via the PLSVC and CS are directed posteriorly away from the tricuspid annulus, making it difficult to direct a lead across the TV annulus into the RV. There are several approaches that can be utilized for left-sided RV lead placement: (1) implantation via the communicating vein,<sup>5,6</sup> which was absent in our case; (2) use of J-tipped or manually shaped stylets with large curves,<sup>3,9</sup> although this technique can be particularly challenging with ICD leads compared to pacemaker leads and was unsuccessful in this particular case; and (3) use of a CS delivery sheath, which can be used to direct leads toward the RV.<sup>10,11</sup> While CS delivery sheaths from most vendors can be used for pacemaker lead implantation, larger-diameter sheaths for ICDs are not routinely available. Given the failure of traversing the tricuspid annulus despite trying manually shaped stylets, we resorted to a snare-assisted

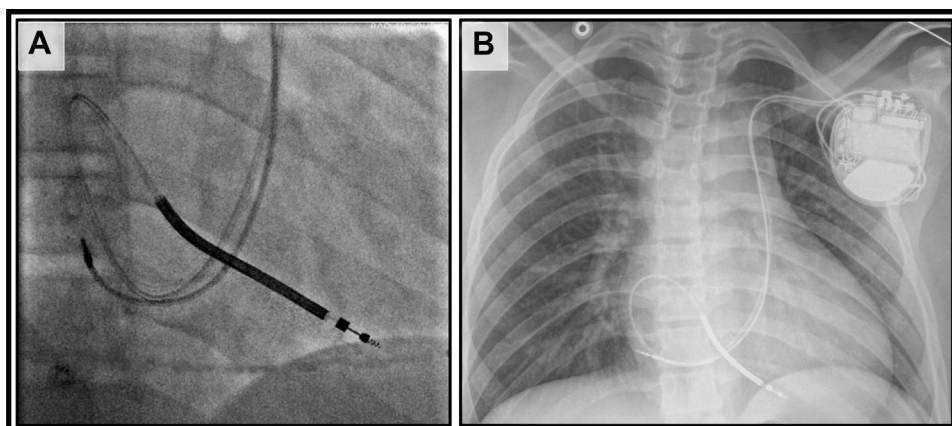


**Figure 2** Snare-assisted lead redirection. Right anterior oblique views showing redirection of defibrillator lead tip toward the right ventricle. **A:** While maintaining anteflexion and a counterclockwise tension on the 8.5F Agilis Nxt sheath (Abbott Inc, Abbott Park, IL), the defibrillator lead is advanced until the alpha curve is formed in the right atrium. **B:** The defibrillator lead is released into the right ventricle. **C:** The defibrillator lead is advanced into the distal right ventricular septum. RA = right atrium; RV = right ventricle.

ICD lead implantation. Other situations in which this implantation technique may be considered include right-sided venous obstruction or in the presence of a pre-existing left-sided device. Various options for snares are available, and while a needle-eye snare could be used in this situation, it would be much more challenging. In comparison, it is relatively easy to snare the lead tip with a multilobed snare within the tubular CS/PLSVC.

Benefits and limitations of different ICD implantation options in patients with PLSVC without a communicating vein are outlined in [Table 1](#). A right-sided implant may have been considered a priori in this patient; however, we were concerned about increased DFT.<sup>8</sup> While a recent study reported acceptable DFTs in patients with adult congenital heart disease undergoing right-sided ICD implantation, only 24% of the study patients underwent DFT testing.<sup>12</sup> Another

contemporary study showed that 14% of patients with right-sided implants had a DFT greater than 25 J (compared to none with left-sided ICDs), suggesting an unpredictably lower safety margin in some patients.<sup>13</sup> Additionally, in our young patient, a left-sided device would be less restrictive on his daily function and lifestyle, as he is right-handed. Use of subcutaneous ICD (S-ICD) has been reported in patients with PLSVC and could have been considered in this case.<sup>14</sup> An S-ICD might be favored in PLSVC owing to decreased risk of infection and technically easier lead extraction as compared to transvenous ICD. The risks of CS tear with use of powered sheaths, lack of data with bridge occlusion balloon (which may be undersized for the CS in PLSVC), and different sites of adhesions (left subclavian vein, PLSVC, CS, TV annulus), as well as the acute angulation of the RV lead as it turns toward the TV annulus, are all



**Figure 3** Final lead positions. **A:** Right anterior oblique projection of dual-chamber intracardiac cardioverter-defibrillator with right atrial and right ventricular lead. **B:** Anteroposterior chest radiograph showing final device and lead position with an alpha curve visible of the right ventricular lead.



**Table 1** Benefits and limitations of various defibrillator implantation approaches in persistent left superior vena cava without a communicating vein

Defibrillator type	Benefits	Limitations
Left-sided transvenous ICD	<ul style="list-style-type: none"> <li>• Avoids handedness issues for most patients</li> <li>• Lower DFTs</li> </ul>	<ul style="list-style-type: none"> <li>• Technically challenging implantation</li> <li>• Challenging lead extraction (if necessary)</li> </ul>
Right-sided transvenous ICD	<ul style="list-style-type: none"> <li>• Easier implantation of leads</li> </ul>	<ul style="list-style-type: none"> <li>• Higher incidence of DFTs &gt;25 J</li> <li>• Handedness issues in right-dominant patients</li> </ul>
Subcutaneous ICD	<ul style="list-style-type: none"> <li>• Technically easier implantation</li> <li>• Decreased risk for infection</li> <li>• Easier explantation</li> </ul>	<ul style="list-style-type: none"> <li>• Lacks pacing capability (relevant for bradycardia-related VF)</li> <li>• Inability to perform antitachycardia pacing for monomorphic VT</li> </ul>

DFT = defibrillation threshold testing; ICD = implantable cardioverter-defibrillator; VF = ventricular fibrillation; VT = ventricular tachycardia.

factors that can make extraction more challenging in patients with PLSVC with left-sided implants. However, there are several reported cases where lead extraction has been safely performed in this setting.<sup>15,16</sup> Because our patient was suspected to have long QT syndrome, a transvenous device was favored over S-ICD owing to pacing capability.

## Conclusion

In conclusion, PLSVC without a communicating branch can make left-sided device implantation extremely challenging. We present a novel solution to this technically difficult clinical entity whereby a defibrillator lead is directed toward the RV using a snare within a steerable Agilis sheath.

## Appendix Supplementary data

Supplementary data associated with this article can be found in the online version at <https://doi.org/10.1016/j.hrcr.2021.05.012>.

## References

1. Azizova A, Onder O, Arslan S, Ardali S, Hazirolan T. Persistent left superior vena cava: clinical importance and differential diagnoses. *Insights Imaging* 2020; 11:110.
2. Biffi M, Boriani G, Frabetti L, Bronzetti G, Branzi A. Left superior vena cava persistence in patients undergoing pacemaker or cardioverter-defibrillator implantation: a 10-year experience. *Chest* 2001;120:139–144.
3. Mora G. A novel method of placing right ventricular leads in patients with persistent left superior vena cava using a conventional j stylet. *Indian Pacing Electrophysiol J* 2014;14:65–74.
4. Andrikopoulos G, Tzeis S, Kounas S, et al. Implantation of a dual-chamber cardioverter defibrillator system in a patient with dilated cardiomyopathy, pulmonary hypertension and persistent left superior vena cava. *Hellenic J Cardiol* 2010;51:460–462.
5. Kumar V, Yoshida N, Yamada T. Successful implantable cardioverter-defibrillator implantation through a communicating branch of the persistent left superior vena cava. *J Arrhythm* 2015;31:331–332.
6. Ząbek A, Boczar K, Dębski M, Lelakowski J, Malecka B. Dual-chamber ICD implantation via a persistent left superior vena cava - use of an innominate vein for the placement of a right ventricular cardioverter-defibrillator lead implantation. *Kardiol Pol* 2017;75:181.
7. Guenther M, Kolschmann S, Rauwolf TP, et al. Implantable cardioverter defibrillator lead implantation in patients with a persistent left superior vena cava—feasibility, chances, and limitations: representative cases in adults. *Europace* 2013; 15:273–277.
8. Roberts PR, Allen S, Betts T, et al. Increased defibrillation threshold with right-sided active pectoral can. *J Interv Card Electrophysiol* 2000;4:245–249.
9. Vijayvergiya R, Shrivastava S, Kumar A, Otaal PS. Transvenous defibrillator implantation in a patient with persistent left superior vena cava. *World J Cardiol* 2013;5:109–111.
10. Sundhu M, Syed M, Gul S, Saqi B, Mosteller R. Pacemaker placement in persistent left superior vena cava. *Cureus* 2017;9:e1311.
11. Sasaki K, Tateishi S, Sawada C. Usefulness of a lead delivery system consisting of a fixed-shaped sheath and a lumenless bipolar lead in a patient with absent right and persistent left superior vena cava: a case report. *Indian Pacing Electrophysiol J* 2018;18:234–236.
12. Kawada S, Chakraborty P, Albertini L, et al. Safety and long-term outcomes of defibrillator therapy in patients with right-sided implantable cardiac devices in adults with congenital heart disease. *Can J Cardiol* 2021;37:407–416.
13. Varma N, Schaerf R, Kalbfleisch S, Pimentel R, Kroll MW, Oza A. Defibrillation thresholds with right pectoral implantable cardioverter defibrillators and impact of waveform tuning (the Tilt and Tune trial). *Europace* 2017; 19:1810–1817.
14. Calvagna GM, Patanè S, Romeo P. Transcatheter pacing system and leadless defibrillator: a solution in a complex case. A case report of a patient with previous device-related infection and persistent left-sided superior vena cava. *Heart-Rhythm Case Rep* 2021;7:12–15.
15. Tanawuttiwat T, Brinker J, Rickard J. Left persistent superior vena cava lead extraction using a femoral approach. *Europace* 2016;18:252.
16. Trenson S, Doering M, Hindricks G, Winnik S, Richter S. Transvenous lead extraction in a patient with persistent left superior vena cava. *HeartRhythm Case Rep* 2021;7:153–156.