

Received: 2013.12.30
Accepted: 2013.01.10
Published: 2014.04.26

ISSN 1941-5923
© Am J Case Rep, 2014; 15: 168-171
DOI: 10.12659/AJCR.890260

A case report of esophageal perforation: Complication of nasogastric tube placement

Authors' Contribution:
Study Design A
Data Collection B
Statistical Analysis C
Data Interpretation D
Manuscript Preparation E
Literature Search F
Funds Collection G

ABCDEF 1 **Arda Isik**
BCDF 1 **Deniz Firat**
ADEF 1 **Kemal Peker**
AEF 2 **Ilyas Sayar**
ADF 3 **Oguz Idiz**
BD 4 **Mehmet Soytürk**

1 Department of General Surgery, Erzincan University, Erzincan, Turkey
2 Department of Pathology, Erzincan University, Erzincan, Turkey
3 Department of General Surgery, Yunak State Hospital, Konya, Turkey
4 Department of Radiology, Erzincan University, Erzincan, Turkey

Corresponding Author: Arda Isik, e-mail: kararda@yahoo.com

Patient: Male, 70
Final Diagnosis: Esophageal perforation
Symptoms: Abdominal pain • nausea • vomiting
Medication: —
Clinical Procedure: —
Specialty: Surgery

Objective: Unusual clinical course

Background: Esophageal perforation is a well-defined and severe clinical condition. There are several etiologies of esophageal perforation.

Case Report: We report the case of a 70-year-old Caucasian man who underwent an emergency cholecystectomy due to acute cholecystitis. Two days after surgery, his condition deteriorated. Thorax computerized tomography revealed an esophageal perforation.

Conclusions: Esophageal perforation due to nasogastric application is relatively rare but the consequences are potentially serious. The anatomy of the upper gastrointestinal system should be understood by all healthcare professionals involved in the treatment.

Keywords: Emergency Surgery • Nasogastric Tube • Osephagus Perforation

Full-text PDF: <http://www.amjcaserep.com/download/index/idArt/890260>

 1072  1  4  19

Background

Esophageal perforation is a well-defined and severe clinical condition. The most common cause of esophageal perforation, accounting for 70% of the cases, is iatrogenic perforation. The majority of iatrogenic cases are due to endoscopic intervention. Spontaneous perforation, foreign bodies, and trauma are responsible for 15%, 8%, and 5%, respectively, of esophageal perforations [1–3].

The mortality rate associated with esophageal perforation is as high as 65% due to the complexity of accessing the esophagus, lack of a potent serosa, extraordinary blood flow in the organ, and close proximity of the esophagus to vital organs [2,3]. Vague symptoms and physician inexperience may delay diagnosis and subsequent therapy, further increasing the mortality risk [4].

Here, we present a case report describing the clinical presentation of a patient with an esophageal perforation, to help identify symptoms that suggest the presence of a perforation and ultimately trigger the proper and prompt diagnostic tests.

Case Report

A 70-year-old diabetic Caucasian man was admitted to the emergency department complaining of nausea, vomiting, and abdominal pain. Physical examination revealed a Murphy sign. Abdominal ultrasonography and computerized tomography (CT) revealed emphysematous acute cholecystitis. Both the complete blood count and blood biochemistry values were normal except for a white blood cell count of 18,000 cells/mm³. An emergency laparoscopic cholecystectomy was performed without perioperative complications. The perioperative insertion of an 18F nasogastric tube (NGT) was performed by the anesthesia team. The day after the operation, a physical examination revealed diminished breath sounds at the right lung base and a temperature of 38°C. An erect chest radiograph showed a small, right-sided pleural effusion. An initial diagnosis of pneumonia was made, and intravenous administration of antibiotics was initiated. The next morning, the patient's condition had deteriorated, and a repeat chest radiograph revealed an increase in the pleural effusion as well as pneumomediastinum. A CT scan with oral and intravenous contrast revealed a contrast in the right pleural cavity, suggesting a diagnosis of esophageal rupture (Figure 1). The patient was stabilized, and upper gastrointestinal endoscopy showed a perforation at the 28th cm from the incisor teeth (Figure 2). The patient was referred to a chest surgery center where he underwent thoracotomy and wash-out, esophageal repair, and insertion of a feeding jejunostomy. The jejunostomy was removed 1 month later. At a 6-month follow-up appointment, the patient had no

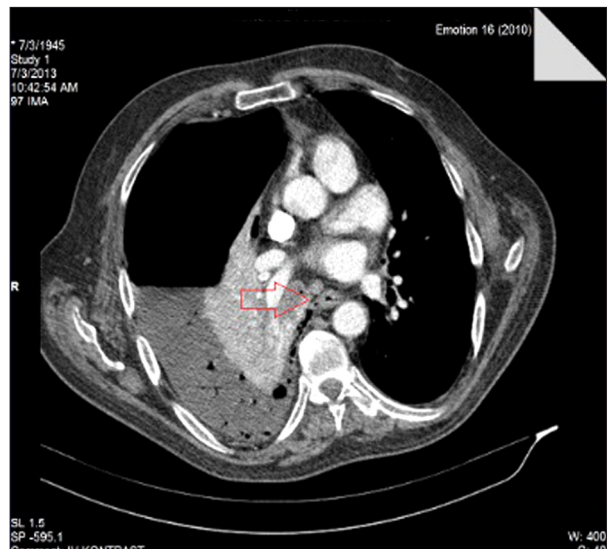

Figure 1. CT scan of esophageal rupture.

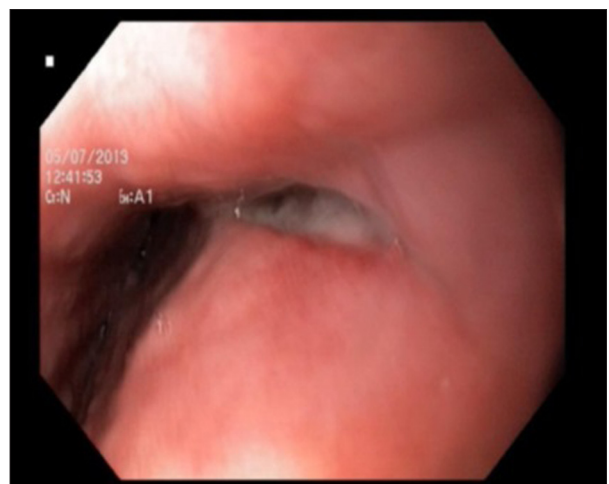


Figure 2. Upper gastrointestinal endoscopy of esophageal rupture.

complaints and a thorax CT scan indicated the absence of a perforation (Figure 3). At the time of the esophageal perforation diagnosis, we believed that the cause of perforation was NGT misplacement.

Discussion

NGT intubation is performed at hospitals to allow fluid administration or gastric decompression. Although it is considered a safe procedure, complications can arise due to NGT misplacement or trauma caused by the NGT itself or intubation. NGT misplacement is typically endotracheal or intracranial [5]. Misplacement within the upper gastrointestinal lumen is usually detected by a kink in the oropharynx or esophagus. During NGT insertion, traumatic complications such as epistaxis or a

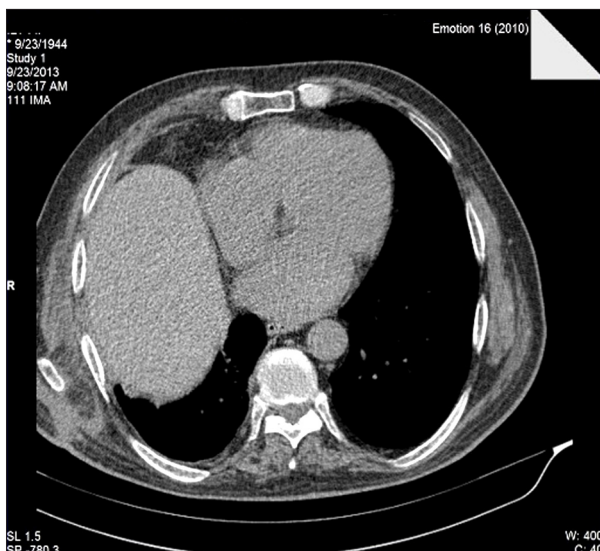


Figure 3. CT scan after treatment.

sore throat may occur. More catastrophic complications such as esophago-arterial fistulas and NGT syndrome caused by mucosal irritation or perforating injuries can occur, especially in long-term placements. Submucosal insertion may result in partial perforation; esophageal or gastric perforations may be complete. The subsequent complications are identified by the structure that is perforated (e.g., mediastinitis or pneumothorax). In situations such as recent mid-facial trauma or surgery, NGT insertion is contraindicated. When strictures or diverticula are present, NGT insertion is relatively contraindicated [6]. To assure correct NGT insertion, certain protocols must be followed. A specimen aspirate from the NGT must be tested using universal indicator paper (the use of litmus paper is contraindicated); a pH <5.5 specifies a gastric aspirate. If this test result is ambiguous, the location of the NGT tip should be determined by a chest radiograph; visualization of the tip below the diaphragm, removed from the bronchial tree, verifies appropriate placement. Auscultation of air insufflation over the stomach is not recommended [7]. Regardless of whether counteraction is perceived, the physician must be careful not to apply excessive force; soft, elastic, round-ended NGTs may also be helpful.

Unlike our case, studies by both Gruen and Fisman revealed perforations in the upper esophagus. On the 5th day after nasogastric application, 2 patients were diagnosed with left-sided perforations, treated medically, and discharged in Gruen's study, and 1 patient was diagnosed with a right-sided perforation and died following surgical treatment in Fisman's study [8,9] (Table 1). Manhal et al. described 33 cases of esophageal perforation between 1976 and 1991. Of the 33 cases, only 1 perforation was due to NGT insertion [10]. Jackson et al. reported a case of esophageal perforation caused by NGT insertion. They suggested that percutaneous endoscopic gastrostomy may be an alternative to nasogastric intubation for long-term enteral feeding. According to their report, if esophageal perforation is suspected, the tip of the tube must be visualized radiographically in the stomach prior to initiation of tube feeding. The outcome of surgical treatments is affected by the size and location of the perforation, degree of local tissue necrosis, and time elapsed since the perforation occurred. If more than 24 hours has elapsed, extensive tissue necrosis may occur, resulting in a higher risk of complications [11]. Kuo et al. described an esophageal perforation in a 47-year-old tracheostomized male patient with long-term NGT placement [12]. Tiller et al. reported that early recognition of an esophageal perforation after insertion of an NGT is the best prognostic indicator of outcome [13]. It is recommended that perioperative prophylactic NGT insertion be performed either by an anesthesiologist or under the supervision of an anesthesiologist to prevent unwanted complications such as perforation [14].

The current treatment of esophageal perforation is based on retrospective studies from a few institutions [2]; prospective randomized studies have not been performed. However, quick diagnosis and treatment will reduce the morbidity and mortality associated with esophageal perforation. The primary treatment strategy of esophageal perforation includes an antibiotic regimen to treat infection and prevent perpetuation of contamination, feeding support, and provision of the continuity of the digestive tract. Several treatment approaches can be used, depending on the choice of the surgeon and the center, amount of time elapsed since perforation, location or cause of the perforation, and presence of pathology in the esophagus (Figure 4) [15–19].

Table 1. Patients characteristics of three studies.

Studies	Number of patients	Treatment	Outcome	Location	Side	Elapsed time after NGT insertion (time on diagnosis of perforation)
Gruen	2 patients	Medical	Discharge	Upper-osephagus	Left	5 th day
Fisman	1 patient	Surgical	Ex	Upper-osephagus	Right	On the same day
Isik	1 patient	Surgical	Discharge	Distal osephagus	Right	2 nd day

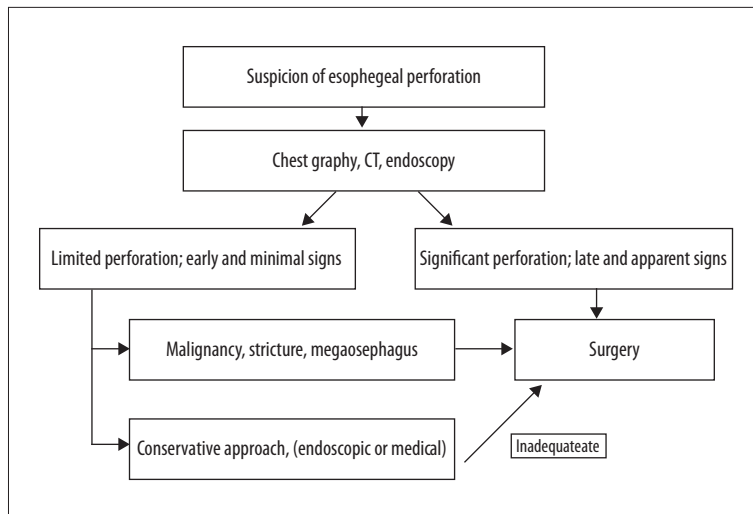


Figure 4. Treatment algorithm of esophageal perforation.

Conclusions

Complications of NGT insertion are uncommon; however, the consequences are potentially serious and the anatomy of the

upper gastrointestinal system should be understood by all who are involved in the treatment.

References:

1. Skinner DB, Little AG, DeMeester TR: Management of esophageal perforation. *Am J Surg*, 1980; 139: 760–64
2. Ryom P, Ravn JB, Penninga L et al: Aetiology, treatment and mortality after oesophageal perforation in Denmark. *Dan Med Bull*, 2011; 58: A4267
3. Vidarsdottir H, Blondal S, Alfredsson H et al: Oesophageal perforations in Iceland: a whole population study on incidence, aetiology and surgical outcome. *Thorac Cardiovasc Surg*, 2010; 58: 476–80
4. Onat S, Ulku R, Cigdem KM et al: Factors affecting the outcome of surgically treated non-iatrogenic traumatic cervical esophageal perforation: 28 years experience at a single center. *J Cardiothorac Surg*, 2010; 5: 46
5. Psarras K, Lalountas MA, Symeonidis NG et al: Inadvertent insertion of a nasogastric tube into the brain: case report and review of the literature. *Clin Imaging*, 2012; 36: 587–90
6. Ahmed A, Aggarwal M, Watson E: Esophageal perforation: a complication of nasogastric tube placement. *Am J Emerg Med*, 1998; 16: 64–66
7. National Patient Safety Agency. Reducing the harm caused by misplaced feeding tubes. London: NPSA; 2005. Interim advice for healthcare staff. www.npsa.nhs.uk
8. Gruen R, Cade R, Vellar D: Perforation during nasogastric and orogastric tube insertion. *Aust N Z J Surg*, 1998; 68: 809–11
9. Fisman DN, Ward ME: Intrapleural placement of a nasogastric tube: an unusual complication of nasotracheal intubation. *Can J Anaesth*, 1996; 43: 1252–56
10. Manhal J, Sequens R, Bouda J: Esophageal injuries. *Rozhl Chir*, 1993; 72: 100–2
11. Jackson RH, Payne DK, Bacon BR: Esophageal perforation due to nasogastric intubation. *Am J Gastroenterol*, 1990; 85: 439–42
12. Kuo YC, Wu CS: Endoscopy. Spontaneous intramural perforation of the esophagus: case report and review of the literature. 1989; 21: 153–54
13. Tiller HJ, Rhea WG Jr: Iatrogenic perforation of the esophagus by a nasogastric tube. *Am J Surg*, 1984; 147: 423–25
14. Lowham AS, Filipi CJ, Hinder RA et al: Mechanisms and avoidance of esophageal perforation by anesthesia personnel during laparoscopic foregut surgery. *Surg Endosc*, 1996; 10: 979–82
15. Sepesi B, Raymond DP, Peters JH: Esophageal perforation: surgical, endoscopic and medical management strategies. *Curr Opin Gastroenterol*, 2010; 26: 379–83
16. Chirica M, Champault A, Dray X et al: Esophageal perforations. *J Visc Surg*, 2010; 147: 117–28
17. Eroglu A, Turkyilmaz A, Aydin Y et al: Current management of esophageal perforation: 20 years experience. *Dis Esophagus*, 2009; 22: 374–80
18. Abbas G, Schuchert MJ, Pettiford BL et al: Contemporaneous management of esophageal perforation. *Surgery*, 2009; 146: 749–55; discussion 755–56
19. Elhanafi S, Othman M, Sunny J et al: Esophageal perforation post pneumatic dilatation for achalasia managed by esophageal stenting. *Am J Case Rep*, 2013; 14: 532–35