

# Missed Case of Pancreatogenic Diabetes Diagnosed Using Ultrasound

M. Deyananda Chakravarthy<sup>1</sup>, Prabha Thangaraj<sup>2</sup>, S. Saraswathi<sup>1\*</sup>

<sup>1</sup>Department of Radiology, Trichy SRM Medical College Hospital and Research Centre, Trichy, Tamil Nadu, India, <sup>2</sup>Department of Community Medicine, Trichy SRM Medical College Hospital and Research Centre, Trichy, Tamil Nadu, India

## Abstract

Nonalcoholic pancreatogenic diabetes mellitus (type 3c DM) is an often-misdiagnosed entity usually seen in young men of tropical countries. Although most of the patients present with abdominal pain and symptoms of exocrine pancreatic insufficiency, there is still a subset that does not present with these classical symptoms, which emphasizes the need for special diagnostic considerations. The significance of identifying this subset of diabetic lies not only in the change in management of the disease but also in early detection for pancreatic carcinoma that is more common among those patients. In our case, ultrasound with X-ray played a vital role in diagnosis, prompting us to consider it as an essential part of the investigation panel in all newly diagnosed nonobese diabetic individuals.

**Keywords:** Fibrocalculous pancreatic diabetes, nonalcoholic pancreatogenic diabetes mellitus, tropical pancreatic diabetes

## INTRODUCTION

Diabetes mellitus (DM) is a common entity encountered by physicians from all specialties and usually classified as either type 1 or 2. Pancreatic diabetes type 3c DM is also an important subtype that is often misdiagnosed or underdiagnosed.<sup>[1]</sup> It is characterized by the damage of pancreatic exocrine function due to acute relapsing or chronic pancreatitis (CP) of any etiology that eventually leads to impairment of pancreatic endocrine function causing DM. The occurrence of pancreatic DM is more common than was generally thought. Its early identification is very important to assess the need for some special diagnostic and treatment plan.<sup>[2]</sup> We present an unusual case of pancreatic DM that was initially diagnosed and treated as type 2 DM for more than 6 years.

## CASE REPORT

A 43-year-old nonalcoholic male, on treatment for type 2 diabetes for more than 6 years with oral hypoglycemic drugs, presented with worsening of glycemic control, weight loss (5 kg), and fatigability. However, due to these symptoms, he stopped all his medications about 6 months ago. The patient's body mass index was 19.5 kg/m<sup>2</sup> with HbA1c ~ 12. Other investigations

done showed that hemoglobin level, total leukocyte count, lipid profile, and renal function test were within normal limits except for mild elevation of liver function test (total bilirubin – 1.7; direct – 0.7; indirect – 1.0, and serum glutamic oxaloacetic transaminase – 54).

Since he was found to be a lean diabetic with no family history of type 2 DM, C-peptide level along with other routine investigations was done. Serum C-peptide at fasting (using chemiluminescence Immunoassay method) was 0.37 ng/ml (normal value: 0.8–3.5 ng/ml), so a possibility of autoimmune DM was thought and anti-insulin and anti-islet cell antibodies were tested which turned out to be negative. No excessive insulin resistance was noted as evidenced by HOMA-IR of 0.4. Further evaluation of pancreatic function revealed normal amylase and lipase levels. Deranged liver function prompted us to do an ultrasound abdomen to rule out the possibility of hepatic or gallbladder pathologies [Figure 1].

**Address for correspondence:** Dr. S. Saraswathi,  
Department of Radiology, Trichy SRM Medical College Hospital  
and Research Centre, Trichy - 621 105, Tamil Nadu, India.  
E-mail: drsaraswathi2k@gmail.com

Received: 14-09-2020 Revised: 10-11-2020 Accepted: 16-11-2020 Available Online: 09-01-2021

### Access this article online

Quick Response Code:



Website:  
www.jmuonline.org

DOI:  
10.4103/JMU.JMU\_138\_20

This is an open access journal, and articles are distributed under the terms of the Creative Commons Attribution-NonCommercial-ShareAlike 4.0 License, which allows others to remix, tweak, and build upon the work non-commercially, as long as appropriate credit is given and the new creations are licensed under the identical terms.

For reprints contact: WKHLRPMedknow\_reprints@wolterskluwer.com

**How to cite this article:** Chakravarthy MD, Thangaraj P, Saraswathi S. Missed case of pancreatogenic diabetes diagnosed using ultrasound. J Med Ultrasound 2021;29:218-20.

Surprisingly, ultrasound showed atrophic pancreas, multiple tiny hyperechogenic foci with postacoustic shadowing noted in the head and body of the pancreas (suggestive of calcifications). The main pancreatic duct appeared dilated with an intraductal calculus seen [Figure 2]. No peripancreatic fat stranding or fluid collection was seen. Computed tomography (CT) confirmed chronic calcific pancreatitis [Figures 3 and 4].

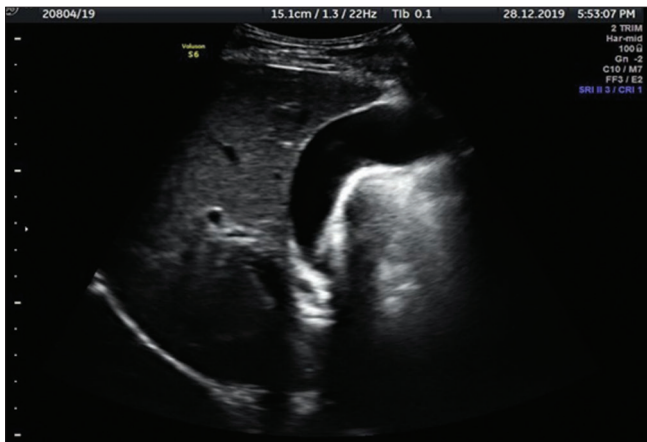
The expensiveness of fecal elastase for evaluation of the exocrine function of the pancreas precluded the patient from doing it. However, indirect tests of pancreatic functions showed low Vitamin D level (25-hydroxycholecalciferol), i.e., 10.1 ng/ml (normal: 30–100), slightly increased prothrombin time (an indirect measure of Vitamin K) ~14.5 s (normal 10–14), and marginally lower spectrum of triglyceride to high-density lipoprotein ratio ~ 1.1, indicating fat malabsorption.

There was an ambiguity in classifying him as type I or II, as his anti-insulin and anti-islet cell autoantibodies were negative and he also did not have evidence of insulin

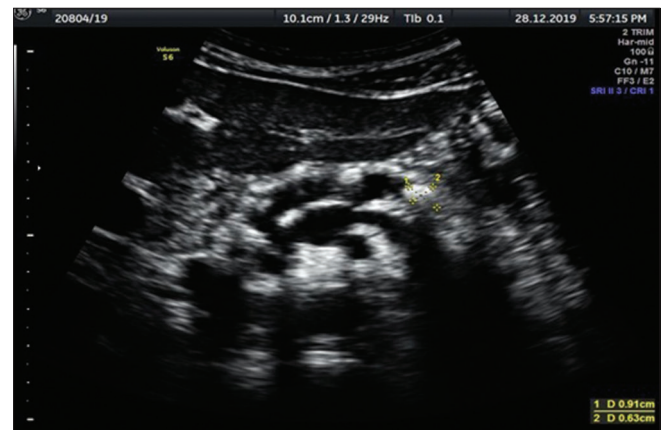
resistance. Identification of CP by ultrasound made the diagnosis of pancreatogenic DM-type 3c possible. Henceforth, the management protocol was modified with addition of insulin, withdrawing oral hypoglycemic agents. He was also started on a modified low carbohydrate diet with Vitamin D and omega-3 supplements. The patient's glycemic control improved (HbA1c ~ 6) and weight increased by 5 kg within the next 4 months. Further follow-up after 2 months showed sustained glycemic control and weight gain.

## DISCUSSION

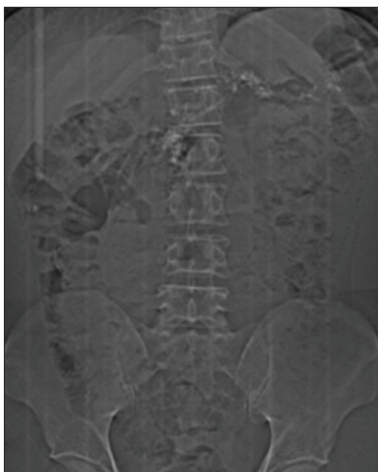
Pancreatogenic diabetes or type 3c DM refers to diabetes due to impairment in pancreatic endocrine function as a result of pancreatic exocrine damage of various causes such as acute, relapsing, or CP (of any etiology), cystic fibrosis, hemochromatosis, pancreatic cancer, as well as neonatal diabetes due to pancreatic agenesis.<sup>[3]</sup> Of these, chronic calcific pancreatitis is the most common cause of type 3c DM which is often misdiagnosed or underdiagnosed.<sup>[1,2,4]</sup>



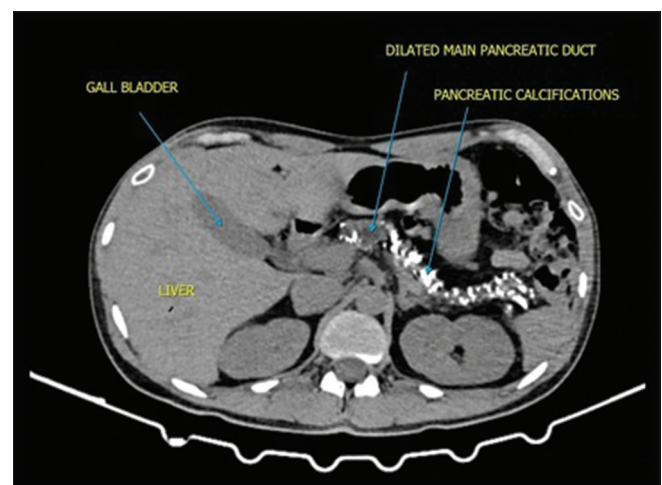
**Figure 1:** Ultrasound of the abdomen shows normal liver parenchyma with the distended gallbladder. No evidence of gallstones



**Figure 2:** Ultrasound of Abdomen shows dilated Main pancreatic duct with intraductal calculus



**Figure 3:** Scanogram of Abdomen shows multiple radio opacities (calcifications) in the region of pancreas. The calcifications are seen on either side of midline, arranged horizontally and are of varying sizes (predominantly large) at the level of L1 vertebra



**Figure 4:** Plain CT Abdomen shows multiple calcifications involving the head, body and tail of pancreatic parenchyma. The dilated main pancreatic duct is also seen

Patients suffering from pancreatic DM usually present with a history of pancreatitis in the past that causes abdominal pain, dyspepsia, steatorrhea, and symptoms of malabsorption. In our case report, the main reason for missed diagnosis was absence of typical clinical features of pancreatic DM such as intermittent abdominal pain and steatorrhea, but deficiency of fat-soluble vitamins and lower lipid level supported our diagnosis. A study done in Pune,<sup>[5]</sup> followed up individuals diagnosed with fibrocalculous pancreatic DM for 7 years, concluded that the two pathognomonic complaints (abdominal pain and steatorrhea) were not always present, which was the case in our patient. The biggest challenge in identifying type 3c DM is that there are no universally accepted diagnostic criteria.<sup>[4]</sup> The commonly known criteria proposed by Ewald and Bretzel<sup>[6]</sup> have disadvantage in developing countries due to the nonavailability and nonaffordability of recommended laboratory tests.

The risk factors for acquiring chronic calcific pancreatitis are alcohol, smoking, obstructive abnormality, genetic, or autoimmune. In our case, the possible cause could be a genetic or autoimmune pancreatitis. A review of literature says that 10%–30% of patients have no identifiable cause.<sup>[7]</sup> On the other side, it has been observed that 38% of patients suffering from CP develop diabetes within the next 1–2 years.<sup>[8]</sup> Hence, it becomes essential to diagnose cases of CP at the earliest to alter the natural course of the disease. However, biochemical studies are not helpful in definitive diagnosis during early stages.<sup>[9]</sup> A combination of clinical symptoms, pancreatic function tests, and radiological investigations is needed for the early diagnosis of CP in suspected patients.<sup>[10]</sup> Among the radiological investigation, endoscopic ultrasound with pancreatic function test (with intravenous synthetic secretin) is considered gold standard in the diagnosis of early exocrine insufficiency in CP. However, due to the invasive nature of the tests, CT and magnetic resonance imaging are preferred tests to detect CP at the earliest.<sup>[11]</sup> However, these tests are very expensive to be used for screening patients without any symptoms suggesting of CP. Ultrasound is a better cost-effective alternative to detect pancreatic atrophy or calcification.<sup>[12]</sup> Although it is operator dependent, standardization of technique can improve the sensitivity of the test to avoid misdiagnosis of type 3c DM.

Currently, there are no accepted guidelines regarding the treatment for type 3c DM, although this subset of people is known to require insulin. Pancreatic enzyme and fat-soluble vitamin (A, D, E, and K) supplements should be given. Occasionally, surgical treatment may be needed. Most importantly, type 3c DM is distinct from type 1 and type 2 DM, as it results from chronic inflammation of the pancreas with an increased risk of pancreatic carcinoma, thus requiring periodic evaluation of serum CA19-9 levels.<sup>[6,13]</sup>

## CONCLUSION

A simple ultrasound abdomen can play a vital role in diagnosing this small subset of people with type 3c DM. We suggest the need for further research studies to assess the feasibility of using ultrasound with/without X-ray as an essential diagnostic tool for all newly diagnosed nonobese diabetic.

## Declaration of patient consent

The authors certify that they have obtained all appropriate patient consent forms. In the form, the patient has given his consent for his images and other clinical information to be reported in the journal. The patient understands that name and initials will not be published and due efforts will be made to conceal identity, but anonymity cannot be guaranteed.

## Financial support and sponsorship

Nil.

## Conflicts of interest

There are no conflicts of interest.

## REFERENCES

1. Hardt PD, Brendel MD, Kloer HU, Bretzel RG. Is pancreatic diabetes (type 3c diabetes) underdiagnosed and misdiagnosed? *Diabetes Care* 2008;31 Suppl 2:S165-9.
2. Ewald N, Hardt PD. Diagnosis and treatment of diabetes mellitus in chronic pancreatitis. *World J Gastroenterol* 2013;19:7276-81.
3. American Diabetes Association. Diagnosis and classification of diabetes mellitus. *Diabetes Care* 2014;37:S81-90.
4. Hart PA, Bellin MD, Andersen DK, Bradley D, Cruz-Monserrate Z, Forsmark CE, *et al.* Type 3c (pancreatogenic) diabetes mellitus secondary to chronic pancreatitis and pancreatic cancer. *Lancet Gastroenterol Hepatol* 2016;1:226-37.
5. Yajnik CS, Shelgikar KM. Fibrocalculous pancreatic diabetes in Pune, India. Clinical features and follow-up for 7 yr. *Diabetes Care* 1993;16:916-21.
6. Ewald N, Bretzel RG. Diabetes mellitus secondary to pancreatic diseases (Type 3c)--are we neglecting an important disease? *Eur J Intern Med* 2013;24:203-6.
7. Lew D, Afghani E, Pandol S. Chronic pancreatitis: Current status and challenges for prevention and treatment. *Dig Dis Sci* 2017;62:1702-12.
8. Sasikala M, Talukdar R, Subramanyam C, Nageshwar Reddy D. The enigma of type 3c diabetes in chronic pancreatitis. *Pancreas Open J* 2016;1:19-21.
9. Czeyda-Pommersheim F, Kalb B, Martin D. Pancreatitis [Internet] Wiley-Blackwell; Imaging of chronic pancreatitis; 2017. p. 179–87.
10. Issa Y, Kempeneers MA, van Santvoort HC, Bollen TL, Bipat S, Boermeester MA. Diagnostic performance of imaging modalities in chronic pancreatitis: A systematic review and meta-analysis. *Eur Radiol* 2017;27:3820-44.
11. Kamat R, Gupta P, Rana S. Imaging in chronic pancreatitis: State of the art review. *Indian J Radiol Imaging* 2019;29:201-10.
12. Gupta S, Mittal A, Arion RK, Singal R. Comparative evaluation of ultrasonography and computed tomography in pancreatic lesions. *J Med* 2016;17:66-78.
13. Chakraborty PP, Dutta D, Biswas K, Sanyal T, Ghosh S, Mukhopadhyay S, *et al.* Pancreatic carcinoma in fibrocalculous pancreatic diabetes: An eastern India perspective. *Indian J Endocrinol Metab* 2012;16:S486-8.