

Anatomical limits in living donor liver transplantation

Kin Pan Au, Kenneth Siu Ho Chok

Department of Surgery, The University of Hong Kong, Hong Kong

Received May 4, 2022

Revised June 22, 2022

Accepted June 22, 2022

Corresponding author: Kenneth Siu Ho Chok
Department of Surgery, The University of
Hong Kong, Queen Mary Hospital,
102 Pokfulam Road, Hong Kong
Tel: +852-2255-3025
Fax: +852-2817-5475
E-mail: kennethchok@gmail.com

© The Korean Society for Transplantation
This is an Open Access article distributed
under the terms of the Creative Commons
Attribution Non-Commercial License
(<http://creativecommons.org/licenses/by-nc/4.0/>) which permits unrestricted
non-commercial use, distribution, and
reproduction in any medium, provided the
original work is properly cited.

We review the anatomical limits of living donor liver transplantation. Graft size is the fundamental challenge in partial liver transplantation. Insufficient graft size leads to small-for-size syndrome, graft failure, and graft loss. However, smaller grafts can be used safely with surgical techniques to optimize outflow and modulate inflow, thereby minimizing portal hyperperfusion. Meanwhile, anatomical variations are common in the vascular and biliary systems. These variants pose additional challenges for vascular and biliary reconstruction. Recognition and appropriate management of these variants ensure donor safety and reduce recipient morbidity. The ultimate principle of partial liver transplantation is to ensure a sufficient graft volume with unimpeded outflow and reconstructable vascular and biliary systems. On this basis, the anatomical limits of living donor liver transplantation can be safely expanded.

Keywords: Living donor liver transplantation; Small for size syndrome; Inflow modulation; Biliary reconstruction; Liver transplantation

INTRODUCTION

With the persistent shortage of deceased organ donations, living donor liver transplantation (LDLT) has become a legitimate alternative to deceased donor liver transplantation. LDLT is characterized by the technical complexity of transplanting a partial liver graft. Initial experiences with LDLT used the smaller left lobe and were restricted to diminutive recipients [1]. Subsequently, right-lobe LDLT was developed, which expanded the indications of LDLT to adult recipients [2,3]. The technique has been applied more liberally and the right lobe has now become the workhorse of adult LDLT [4]. Nevertheless, anatomical variations of the hepatic vasculature and biliary drainage are common in right liver grafts [5]. Recognition and management of these variations are critical for a successful transplant. In the following text, we will review the principles of designing a partial liver graft and explore the ana-

tomical limits of safe partial liver transplantation.

Institutional Review Board is not required as no patient management was affected for writing up this manuscript. Written consent has been obtained for the operative photo shown.

GRAFT SIZE

Graft size is the fundamental challenge in LDLT. The healthy liver has a large functional reserve, and a partial liver graft has a vast ability to regenerate. However, there is a limit to the minimal graft size to satisfy the initial metabolic demands of the recipient. When the graft size is insufficient, small-for-size syndrome (SFSS) occurs. It is characterized by the development of coagulopathy, prolonged cholestasis, and ascites, and is associated with

HIGHLIGHTS

- Graft size is the fundamental challenge to partial liver transplantation.
- Smaller grafts can be used safely with surgical techniques to optimize outflow and modulate inflow.
- Recognition and appropriate management of anatomical variations in the vascular and biliary systems ensure donor safety and reduce recipient morbidity.

increased mortality [6,7].

The minimal graft size for safe liver transplantation has evolved [8-16]. Graft size is expressed in terms of the graft-recipient weight ratio (GRWR) or percentage graft weight/estimated standard liver volume (GW/ESLV). In the 1990s, a GRWR of <1% and a GW/ESLV of <40% were identified as indicators of a small-for-size graft (SFSG). The pathophysiology of SFSS is related to portal hyperperfusion. A partial liver graft with half the recipient's standard liver volume receives three to four times the portal perfusion than that before its resection from the donor [17]. Extreme portal pressure compromises the graft function and regeneration. In animal models, reperfusion injuries are inversely proportional to graft size [18]. In sizable grafts, sinusoidal congestion is minimal; whereas in SFSG, se-

vere sinusoidal congestion, hemorrhage, endothelial damage and hepatocytic apoptosis result from increased perfusion pressure after implantation. To minimize portal hyperperfusion, the venous outflow must not be compromised [17]. The inflow can also be modulated with various surgical techniques. Unimpeded outflow and modulated inflow have allowed smaller grafts to be used safely (Table 1).

VASCULAR OUTFLOW

Vascular outflow is essential for proper graft function. The right hepatic vein (RHV) drains the right posterior section and part of the anterior section, particularly segment 8 [19]. The middle hepatic vein (MHV) drains most of the anterior section. A right liver graft without MHV drainage suffers congestion of the right anterior section. Such congestion could lead to reduced functional hepatocytes, graft dysfunction, and even septic complications with infarct and abscess formation [20].

In a standard right-lobe liver graft, the MHV is not included. Tributaries draining the right anterior section are reconstructed using autologous or synthetic vein grafts. Options for autologous vein grafts include the great saphenous vein and inferior mesenteric vein. The patency of

Table 1. Retrospective series reporting minimal graft sizes for living donor liver transplantation

Study	Region	Definition	SFSG	Non-SFSG	Portal flow modulation	SFSS (%)	Short-term survival	Long-term survival
Kiuchi et al. (1999) [8]	Japan	GRWR <0.8%	21	255	-	-	58% at 1 yr	-
Nishizaki et al. (2001) [9]	Japan	GW/ESLV ≤30%	5	28	Portocaval shunt	-	100% at median FU of 15 mo	-
Ikegami et al. (2009) [10]	Japan	GV/SLV <35%	33	87	Splenic artery ligation/ splenectomy	0	80.7% at 1 yr	64.2% at 5 yr
Moon et al. (2010) [11]	South Korea	GRWR <0.8%	35	392	-	5.7	87.8% at 1 yr	74.1% at 5 yr
Lee et al. (2014) [12]	South Korea	GRWR <0.7%	23	294	No	8	100% at 1 yr	91.7% at 3 yr
Au et al. (2015) [13]	Hong Kong	GW/ESLV ≤35%	21	212	Splenic artery ligation/ portocaval shunt	-	-	81.0% at 5 yr
Ikegami et al. (2016) [14]	Japan	GV/SLV <35%	88	119	Splenectomy	11.4	-	91.4% at 5 yr
Liu et al. (2016) [15]	China	GRWR <0.7%	26	220	Splenic artery ligation/ splenectomy	11	85.0% at 1 yr	73.2% at 5 yr
Wong et al. (2021) [16]	Hong Kong	GRWR <0.6%	39	506	Splenic artery ligation/ splenectomy	12.8	0% hospital mortality	85.4% at 5 yr

SFSG, small-for-size graft; SFSS, small-for-size syndrome; GRWR, graft-recipient weight ratio; GW/ESLV, graft weight/estimated standard liver volume; GV/SLV, graft volume/standard liver volume.

these interposition vein grafts is most critical in the first 2 weeks. With time, intrahepatic collaterals are expected to develop via the sinusoids, and the portal vein perfusing these segments also provides retrograde drainage [21]. Preserving the MHV to the donor reduces segment 4 congestion and minimizes donor morbidity. However, reconstruction could be complex when multiple venous tributaries are present. Variants of hepatic venous outflow are not uncommon (Fig. 1). In variants where dominant venous drainage to MHV is present for both S8 and S5, multiple reconstructions may be required, which can be performed with a Y-graft or with two vein grafts with end-to-side or end-to-end configurations.

In contrast, the extended right lobe graft includes the main trunk of the MHV [2]. Several advantages are associated with the extended right lobe graft. There is no need for graft reconstruction of the venous tributaries. The RHV and MHV are joined together in the back table into a single triangular orifice [22]. Venoplasty is technically simple, and the 3-point fixation expands the venous opening and maximizes outflow capacity (Fig. 2). The resultant single venous opening offers technical ease for anastomosis in the recipient. The native outflow reconstruction is also durable and patent in the long term. The extended right lobe graft appears to be a better option in donors with hepatic venous variants. However, harvesting the MHV increases segment 4 congestion in the donor. Nakamura and Tsuzuki [23] classified drainage of the segment 4 into three types: type I, mainly via the left hepatic vein (LHV); type II, equally into the MHV and LHV; and type III, pre-

dominantly via the MHV (Fig. 1). Types II and III anatomy are less favorable for procuring extended right lobe graft. When the root of the MHV is harvested, there is increased risk of segment 4 congestion. Donor hepatectomy can be modified to preserve the segment 4 hepatic vein (V4) [24] (Fig. 1). Transection of MHV distal to V4b usually adds no technical difficulty to the venoplasty. Preservation of V4b can also be considered in patients with marginal remnant volume to avoid compromising remnant liver function. The use of the extended right lobe graft with RHV/MHV venoplasty has lowered GRWR requirement to 0.6%, with a low incidence of SFSS and excellent outcomes [16].



Fig. 2. Venoplasty between the right hepatic vein (RHV) and middle hepatic vein (MHV) in an extended right lobe liver graft.

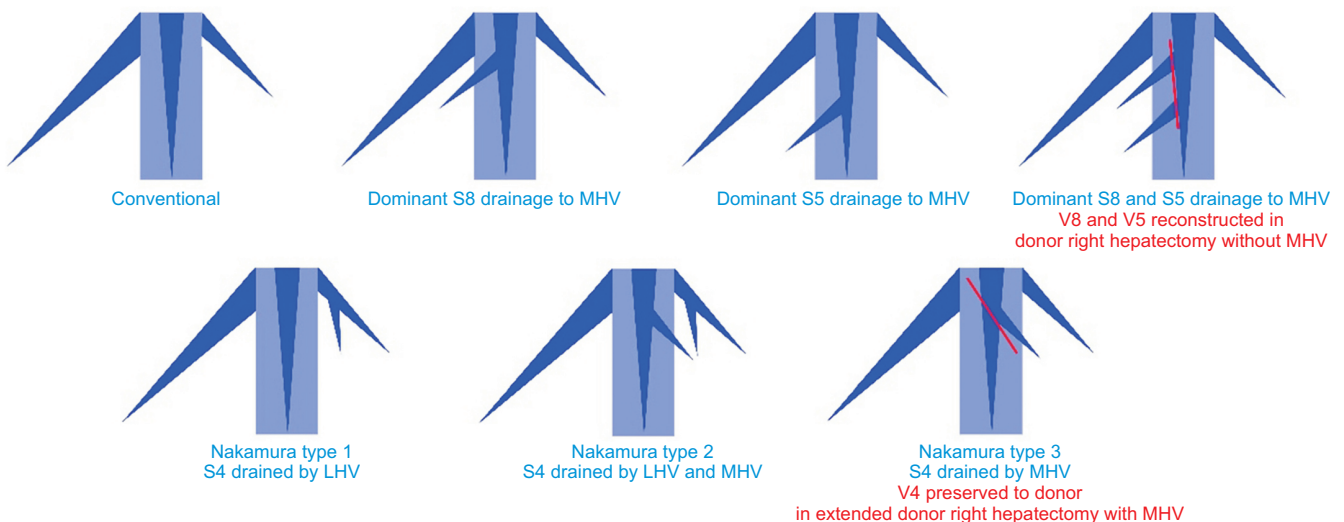


Fig. 1. Variants of the hepatic vein. MHV, middle hepatic vein; LHV, left hepatic vein.

INFLOW MODULATION

Liver graft with optimized outflow could tolerate portal inflow of up to 450 mL/min/100 g GW. Portal flow can be measured after implantation. When the inflow is higher than 250 mL/min/100 g, portal pressure can be obtained by cannulation of the inferior mesenteric vein. Portal modulation is considered if portal pressure exceeds 15 mmHg and can be done by splenic artery ligation or portocaval shunting [17]. Occlusion of the splenic artery reduces portal inflow from the splenic vein. It can result in reduction of the portal inflow by half [25], and the drop in portal pressure is particularly significant in patients with pre-existing portal hypertension, as evident by splenomegaly [26]. A portocaval or portomesenteric shunt can be constructed to divert mesenteric outflow [27,28]. In a porcine model, shunting reduced hepatocyte damage related to portal hyperperfusion [29].

The burden of SFSG is alleviated by experience [30]. The focus of SFSG is shifting from obtaining larger grafts to managing the use of smaller grafts with appropriate flow-modulatory measures [31]. The GRWR can be reduced to 0.6% at expert centers with careful patient selection [16]. Marginal-sized grafts are avoided for recipients with high model for end-stage liver disease scores [32] or when a difficult operation is expected, as in cases with multiple prior laparotomies and the presence of portal vein thrombosis. There is minimal occurrence of SFSS and hospital mortality [16]. A meta-analysis of pooled data indicated that SFSG use is associated with inferior medium-term, but not long-term graft survival [33]. Patients with SFSG who make it through the initial period enjoy long-term survival [13].

ANATOMICAL VARIANTS

Portal Inflow Variant

In the conventional anatomy, the main portal vein (MPV) bifurcates at the liver hilum into the left (LPV) and right portal vein (RPV), which then divides into the right anterior (RAPV) and right posterior portal vein (RPPV). Portal vein variants are frequent and occur in 20%–30% of the population [5,34–36]. Various classifications have been proposed [5,37] (Fig. 3). The most common variant is the portal vein trifurcation, in which the MPV divides into the LPV, RAPV, and RPPV at hilum without the RPV main trunk (i.e., Covey type II). The second most common variant is the division of MPV into RPPV and a common trunk, which then divides into LPV and RAPV (i.e., Covey type III). Both variants give rise to two venous openings when a right lobe graft is harvested. The two venous openings are wide apart in type III, which poses an additional challenge for vascular reconstruction. Donors with these variations were usually rejected due to the technical difficulty in vascular reconstruction. However, the modification of surgical techniques has recently allowed the use of right liver grafts from these donors with portal vein variants [38].

The RAPV and RPPV are usually divided separately to ensure donor safety. In type II, since the distance between the venous opening is close, they can be joined together at the back table with a venoplasty to form a single cuff. In type III, where the two portal vein openings are wide apart, venoplasty creates distortion and narrowing of both lumens. These grafts were once doubly anastomosed to the recipient LPV and RPV. Double anastomosis in the recipient is technically complex. Moreover, twisting occurs when the RAPV and RPPV, which have an antero-posterior

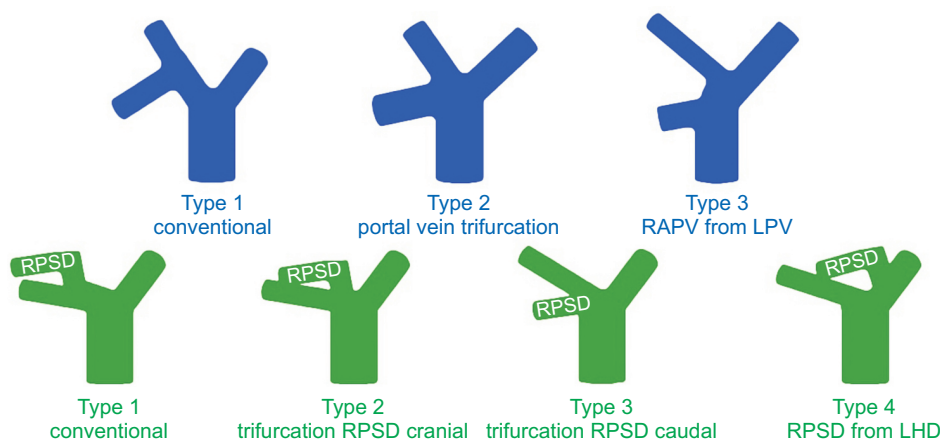


Fig. 3. Variants of the portal vein and biliary tree. RAPV, right anterior portal vein; LPV, left portal vein; RPSD, right posterior sectoral duct; LHD, left hepatic duct.

orientation, are anastomosed to the recipient LPV and RPV. The malalignment is further exacerbated by regeneration of the liver graft, creating turbulence and predisposing to thrombosis [38]. To reduce recipient complications, a discoid patch can be harvested to include both the RAPV and RPPV openings, which are subsequently closed with a vascular patch. However, this shifts the risk to the donor. When the defect is large, a buckling deformity occurs and turbulence results. In a series of five donors with a single graft portal vein cuff harvested for the type III variant, one donor suffered portal vein thrombosis, necessitating exploration and stenting [38].

The most promising results for portal vein variant reconstruction are offered by Y-graft reconstruction [37]. The RAPV and RPPV are anastomosed to the bifurcated ends of the graft at the back table. This allows an optimal inspection of the orientation and alignment of the anastomoses. This provides a lengthy portal vein with a single opening, which is ideal for reconstruction during implantation. The explant portal vein bifurcation provides an easily available autologous Y-graft with compatible size. In patients with existing portal vein thrombus, a cadaveric iliac vein graft can be used for the same purpose. Thayer et al. [37] and Lee et al. [38] reported five right lobe grafts with Y-graft reconstruction, and no vascular complications were noted in these recipients.

Biliary Variants

Bile duct variations have long been recognized. Nakamura et al. [5] classified anatomical variants based on the take-off of the right posterior sectoral duct (RPSD). In the conventional bile duct (i.e., type I), a single right hepatic duct is present (Fig. 2). Type II and type III represent bile duct trifurcations. In type II, the RPSD branches cranial to the right anterior sectoral duct take-off, and vice versa for type III. In type IV, the RPSD branches from the left hepatic duct. In the absence of a single right hepatic duct (types II-IV), two or more bile duct openings result when the right liver is harvested. When these openings are close to each other, they could be joined to form one single orifice by ductoplasty. When these openings are wide apart, they necessitate multiple anastomoses with hepaticojejunostomy or a combination with duct-to-duct anastomosis. Multiple biliary reconstruction is technically challenging, as these openings are usually small in caliber. When combined with vascular variant anatomy, both the donor risk and recipient complications are increased. When a vascular variant is identified, preoperative magnetic resonance

cholangiopancreatography can be performed to identify possible associations with biliary variants.

SPECIAL GRAFT TYPES

Right Posterior Sectional Graft

The right posterior sectional graft is an alternative in donors with a small left lobe, which is inadequate as either the remnant or as the implant. With the conventional vascular anatomy, the short and small stump of the hepatic artery (HA) and portal vein in donors with standard anatomy make reconstruction difficult. The most favorable anatomy is RAPV arising from the LPV, which provides a long single RPPV trunk (type 3) (Fig. 2). An early bifurcation of the right anterior and right posterior HA provides a long trunk for arterial anastomosis. The anatomical relationship between the bile duct and portal vein is also important. When the RPSD is posterior to the RPPV, biliary reconstruction is extremely difficult, if not impossible. A ventrally running bile duct is most favorable.

However, the incidence of biliary stricture remains high [39,40]. Dissection around the right posterior pedicle during donor hepatectomy causes devascularization and biliary injury. A small bile duct caliber also renders anastomosis technically difficult. A thorough understanding of the anatomical variations of the portal vein, HA, and bile duct on preoperative imaging is mandatory for the use of the right posterior sectional graft, because the standard bifurcation of the portal vein and posterior bile duct on the dorsal side of the RPPV is not suitable for the right posterior section graft.

Dual Graft

Dual-graft liver transplantation is indicated when a single donation is not sufficient in size, or the remnant volume is insufficient. Options include dual left lobe transplantation and right and left lobe dual-graft transplantation. The former was first performed [41]. The larger left liver is implanted in the orthotopic position, and the smaller graft is implanted in the heterotopic right position (Fig. 4). The rotation of the heterotopic graft rotates the hilar structures into a reversed position so that the bile duct is dorsal to the HA and portal vein. Therefore, the heterotopic right graft bile duct is anastomosed to the recipient bile duct before portal vein anastomosis. After completion of portal vein and HA anastomosis, the orthotopic left graft bile

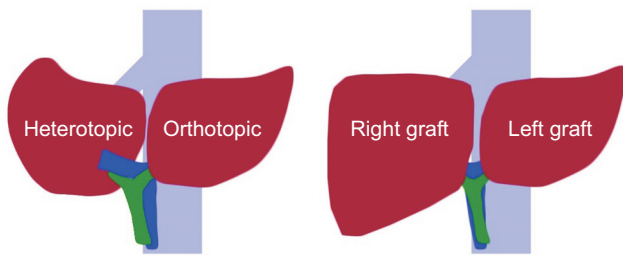


Fig. 4. Configuration of dual left lobe transplantation and dual left and right lobe liver transplantation.

duct is reconstructed with hepaticojejunostomy. A tissue expander is placed underneath the heterotopic graft to avoid graft rotation and subsequent kinking of vascular outflow.

In dual right and left lobe transplantation, both grafts are implanted orthotopically (Fig. 4). The right graft is implanted first starting with the hepatic vein anastomosis. The left liver is then engrafted with the outflow reconstructed. This is followed by sequential reconstruction of the portal vein and HA anastomosis and biliary reconstruction. Dual-graft liver transplantation is technically complex, and there are ethical concerns regarding the involvement of two living donors [42]. Dual-graft liver transplantation should be prudently performed when single donation is proven unacceptable and elaborate surgical planning is crucial. At expert centers, the recipient outcomes of dual-graft transplantation are comparable to those of single-donor LDLT [43].

CONCLUSIONS

Graft size is the fundamental challenge in partial liver transplantation. Insufficient graft size leads to SFSS, graft failure, and graft loss. However, smaller grafts can be used safely with surgical techniques to optimize outflow and modulate inflow, thereby minimizing portal hyperperfusion. Meanwhile, anatomical variations are common in the vascular and biliary systems. These variants pose additional challenges for vascular and biliary reconstruction. Recognition and appropriate management of these variants ensure donor safety and reduce recipient morbidity. The ultimate principle of partial liver transplantation is to ensure sufficient graft volume with unimpeded outflow and re-constructable vascular and biliary systems. On

this basis, the anatomical limits of LDLT can be safely expanded.

ACKNOWLEDGMENTS

Conflict of Interest

No potential conflict of interest relevant to this article was reported.

ORCID

Kin Pan Au <https://orcid.org/0000-0002-7138-9805>

Kenneth Siu Ho Chok

<https://orcid.org/0000-0001-7921-3807>

Author Contributions

Conceptualization: all authors. Data curation: KPA. Formal analysis: KPA. Methodology: KSHC. Project administration: KSHC. Visualization: KPA. Writing—original draft: all authors. Writing—review & editing: all authors.

REFERENCES

1. Strong RW, Lynch SV, Ong TH, Matsunami H, Koido Y, Balderson GA. Successful liver transplantation from a living donor to her son. *N Engl J Med* 1990;322:1505-7.
2. Lo CM, Fan ST, Liu CL, Wei WI, Lo RJ, Lai CL, et al. Adult-to-adult living donor liver transplantation using extended right lobe grafts. *Ann Surg* 1997;226:261-9.
3. Lo CM, Fan ST, Liu CL, Lo RJ, Lau GK, Wei WI, et al. Extending the limit on the size of adult recipient in living donor liver transplantation using extended right lobe graft. *Transplantation* 1997;63:1524-8.
4. Chan SC, Chan AC, Sharr WW, Chok KS, Cheung TT, Fan ST, et al. Perpetuating proficiency in donor right hepatectomy for living donor liver transplantation. *Asian J Surg* 2014;37:65-72.
5. Nakamura T, Tanaka K, Kiuchi T, Kasahara M, Oike F, Ueda M, et al. Anatomical variations and surgical strategies in right lobe living donor liver transplantation: lessons from 120 cases. *Transplantation* 2002;73:1896-903.
6. Shoreem H, Gad EH, Soliman H, Hegazy O, Saleh S, Zakaria H, et al. Small for size syndrome difficult dilem-

- ma: lessons from 10 years single centre experience in living donor liver transplantation. *World J Hepatol* 2017;9:930-44.
7. Dahm F, Georgiev P, Clavien PA. Small-for-size syndrome after partial liver transplantation: definition, mechanisms of disease and clinical implications. *Am J Transplant* 2005;5:2605-10.
8. Kiuchi T, Kasahara M, Uryuhara K, Inomata Y, Uemoto S, Asonuma K, et al. Impact of graft size mismatching on graft prognosis in liver transplantation from living donors. *Transplantation* 1999;67:321-7.
9. Nishizaki T, Ikegami T, Hiroshige S, Hashimoto K, Uchiyama H, Yoshizumi T, et al. Small graft for living donor liver transplantation. *Ann Surg* 2001;233:575-80.
10. Ikegami T, Masuda Y, Ohno Y, Mita A, Kobayashi A, Urata K, et al. Prognosis of adult patients transplanted with liver grafts < 35% of their standard liver volume. *Liver Transpl* 2009;15:1622-30.
11. Moon JI, Kwon CH, Joh JW, Jung GO, Choi GS, Park JB, et al. Safety of small-for-size grafts in adult-to-adult living donor liver transplantation using the right lobe. *Liver Transpl* 2010;16:864-9.
12. Lee SD, Kim SH, Kim YK, Lee SA, Park SJ. Graft-to-recipient weight ratio lower to 0.7% is safe without portal pressure modulation in right-lobe living donor liver transplantation with favorable conditions. *Hepatobiliary Pancreat Dis Int* 2014;13:18-24.
13. Au KP, Chan SC, Chok KS, Chan AC, Wong TC, Sharr WW, et al. Durability of small-for-size living donor allografts. *Liver Transpl* 2015;21:1374-82.
14. Ikegami T, Yoshizumi T, Sakata K, Uchiyama H, Harimoto N, Harada N, et al. Left lobe living donor liver transplantation in adults: what is the safety limit? *Liver Transpl* 2016;22:1666-75.
15. Liu C, Song JL, Lu WS, Yang JY, Jiang L, Yan LN, et al. Hepatic arterial buffer response maintains the homeostasis of graft hemodynamics in patient receiving living donor liver transplantation. *Dig Dis Sci* 2016;61:464-73.
16. Wong TC, Fung JY, Cui TY, Sin SL, Ma KW, She BW, et al. The risk of going small: lowering GRWR and overcoming small-for-size syndrome in adult living donor liver transplantation. *Ann Surg* 2021;274:e1260-8.
17. Chan SC, Lo CM, Chok KS, Sharr WW, Cheung TT, Tsang SH, et al. Modulation of graft vascular inflow guided by flowmetry and manometry in liver transplantation. *Hepatobiliary Pancreat Dis Int* 2011;10:649-56.
18. Kelly DM, Demetris AJ, Fung JJ, Marcos A, Zhu Y, Subbotin V, et al. Porcine partial liver transplantation: a novel model of the "small-for-size" liver graft. *Liver Transpl* 2004;10:253-63.
19. Nakamura S, Sakaguchi S, Hachiya T, Suzuki S, Nishiyama R, Konno H, et al. Significance of hepatic vein reconstruction in hepatectomy. *Surgery* 1993;114:59-64.
20. Lee SG, Park KM, Hwang S, Lee YJ, Kim KH, Ahn CS, et al. Adult-to-adult living donor liver transplantation at the Asan Medical Center, Korea. *Asian J Surg* 2002;25:277-84.
21. Pollard JJ, Nebesar RA. Altered hemodynamics in the Budd-Chiari syndrome demonstrated by selective hepatic and selective splenic angiography. *Radiology* 1967;89:236-43.
22. Liu CL, Zhao Y, Lo CM, Fan ST. Hepatic venoplasty in right lobe live donor liver transplantation. *Liver Transpl* 2003;9:1265-72.
23. Nakamura S, Tsuzuki T. Surgical anatomy of the hepatic veins and the inferior vena cava. *Surg Gynecol Obstet* 1981;152:43-50.
24. Chan SC, Lo CM, Liu CL, Wong Y, Fan ST, Wong J. Tailoring donor hepatectomy per segment 4 venous drainage in right lobe live donor liver transplantation. *Liver Transpl* 2004;10:755-62.
25. Del Guercio LR, Cohn JD, Kazarian KK, Kinkhabwalla M. A shunt equation for estimating the splenic component of portal hypertension. *Am J Surg* 1978;135:70-5.
26. Luca A, Miraglia R, Caruso S, Milazzo M, Gidelli B, Bosch J. Effects of splenic artery occlusion on portal pressure in patients with cirrhosis and portal hypertension. *Liver Transpl* 2006;12:1237-43.
27. Yoshizumi T, Mori M. Portal flow modulation in living donor liver transplantation: review with a focus on splenectomy. *Surg Today* 2020;50:21-9.
28. Boillot O, Delafosse B, Méchet I, Boucaud C, Pouyet M. Small-for-size partial liver graft in an adult recipient; a new transplant technique. *Lancet* 2002;359:406-7.
29. Iida T, Yagi S, Taniguchi K, Hori T, Uemoto S. Improvement of morphological changes after 70% hepatectomy with portocaval shunt: preclinical study in porcine model. *J Surg Res* 2007;143:238-46.
30. Chan SC, Lo CM, Ng KK, Fan ST. Alleviating the burden of small-for-size graft in right liver living donor liver transplantation through accumulation of experience. *Am J Transplant* 2010;10:859-67.

31. Yagi S, Uemoto S. Small-for-size syndrome in living donor liver transplantation. *Hepatobiliary Pancreat Dis Int* 2012;11:570-6.
32. Lei JY, Wang WT, Yan LN. Risk factors of SFSS in adult-to-adult living donor liver transplantation using the right liver: a single-center analysis of 217 cases. *Hepatogastroenterology* 2012;59:1491-7.
33. Ma KW, Wong KH, Chan AC, Cheung TT, Dai WC, Fung JY, et al. Impact of small-for-size liver grafts on medium-term and long-term graft survival in living donor liver transplantation: a meta-analysis. *World J Gastroenterol* 2019;25:5559-68.
34. Sureka B, Patidar Y, Bansal K, Rajesh S, Agrawal N, Arora A. Portal vein variations in 1000 patients: surgical and radiological importance. *Br J Radiol* 2015;88:20150326.
35. Schmidt S, Demartines N, Soler L, Schnyder P, Denys A. Portal vein normal anatomy and variants: implication for liver surgery and portal vein embolization. *Semin Intervent Radiol* 2008;25:86-91.
36. Covey AM, Brody LA, Getrajdman GI, Sofocleous CT, Brown KT. Incidence, patterns, and clinical relevance of variant portal vein anatomy. *AJR Am J Roentgenol* 2004;183:1055-64.
37. Thayer WP, Claridge JA, Pelletier SJ, Oh CK, Sanfey HA, Sawyer RG, et al. Portal vein reconstruction in right lobe living-donor liver transplantation. *J Am Coll Surg* 2002;194:96-8.
38. Lee SG, Hwang S, Kim KH, Ahn CS, Park KM, Lee YJ, et al. Approach to anatomic variations of the graft portal vein in right lobe living-donor liver transplantation. *Transplantation* 2003;75(3 Suppl):S28-32.
39. Yoshizumi T, Ikegami T, Kimura K, Uchiyama H, Ikeda T, Shirabe K, et al. Selection of a right posterior sector graft for living donor liver transplantation. *Liver Transpl* 2014;20:1089-96.
40. Hori T, Kirino I, Uemoto S. Right posterior segment graft in living donor liver transplantation. *Hepatol Res* 2015;45:1076-82.
41. Lee S, Hwang S, Park K, Lee Y, Choi D, Ahn C, et al. An adult-to-adult living donor liver transplant using dual left lobe grafts. *Surgery* 2001;129:647-50.
42. Lee SG, Moon DB. Dual-graft liver transplantation. In: Oniscu GC, Forsythe JL, Pomfret EA, eds. *Transplantation surgery*. Springer surgery atlas series. Berlin, Germany: Springer; 2019. p. 331-52.
43. Xu Y, Chen H, Yeh H, Wang H, Leng J, Dong J. Living donor liver transplantation using dual grafts: Experience and lessons learned from cases worldwide. *Liver Transpl* 2015;21:1438-48.