

Early clinical and radiographical results of keel-less and shallow keel cervical disc replacement

Ji Min Ling¹, Rajendra Tiruchelvarayan^{1,2,3}

¹Department of Neurosurgery, National Neuroscience Institute, 11 Jalan Tan Tock Seng, 308433 Singapore, ²Department of Neurosurgery, Singapore General Hospital, Academia, Level 5, 169865 Singapore, ³Spine Neuro Specialist Centre, Gleneagles Medical Centre, 258499 Singapore

ABSTRACT

Background: Cervical disc replacements has been shown to be as effective as fusions in the treatment of radiculopathy or myelopathy due to disc prolapse. Newer implants were designed to reduce the difficulty of end-plate preparation. Since 2010, the authors have started using Discocerv (Alphatec Spine, Carlsbad, USA) a keel-less implant and Activ-C (B. Braun, Sheffield, UK), a shallow keel implant.

Aim: The aim of this study was to compare the duration of surgery between cervical disc replacement and anterior cervical discectomy and fusion, and also to evaluate the functional outcome, complications, and radiographic outcome of cervical disc replacement.

Results: Fifty patients were included (20 disc replacement and 30 fusion). This was a single surgeon retrospective study, with all surgery performed by the senior author (RT). The mean operation duration for single-level disc replacement was 2.6 h, and for single-level fusion was 2.4 h ($P = 0.4684$). For 2-levels surgery, the result was 3.5 h for 2-level hybrid surgery (one level disc replacement and one level fusion) and 3.4 h for fusion ($P = 0.4489$). Disc replacement resulted in preservation of an average of 67% of the angle of motion at the sagittal plane (FFflexion-extension). The average range of motion after disc replacement was 6.1°. The median clinical follow-up duration was 2 years (average 1.8 years). There was no incidence of major complications or significant neurovascular injury in this series of patients. A significant improvement in short form-36 scores was seen as early as 3 months postoperative (from 58 preoperative to 92 at 3 months). The improvement was sustained up to the fourth year of follow-up.

Conclusion: Cervical arthroplasty with keel-less and shallow keel implants are safe and relatively easy to perform. The surgical time for disc replacement is not significantly longer than standard fusion surgery. There is reasonably good preservation of motion. The short-term functional improvement is good, and we await further long-term outcome results. The authors felt that cervical disc replacement will have an important role in the treatment of cervical degenerative disc disease in the future.

Key words: Activ-C, cervical arthroplasty, cervical disc replacement, Discocerv, motion preservation

Introduction

Cervical disc replacement has been shown to be as effective as fusion in the treatment of radiculopathy or myelopathy due to disc prolapse, at least in the short-term.^[1-4] The success of

cervical disc replacement surgery depends on patient selection, surgeons' skill and design of the implant. While controversies still exist regarding the long-term functional benefit of cervical arthroplasty, there is an on-going effort to improve on the design of the implant.

An ideal implant should possess the following features. The technique for its insertion should be as simple as possible, thus reducing the chance of technical error leading to implant failure. Once inserted, it should remain in a stable position over the remaining lifespan of the patient. Most importantly, it should preserve the physiological movement of the instrumented level. The prosthesis is subjected to regular motion. One of the challenges in designing a cervical disc implant is to create a strong bond between the implant and the vertebral body in order to overcome translational forces. If this fails, the implant could potentially migrate anteriorly, laterally, or posteriorly resulting in neurovascular damage.

Access this article online	
Quick Response Code:	Website: www.asianjns.org
	DOI: 10.4103/1793-5482.151501

Address for correspondence:

Dr. Rajendra Tiruchelvarayan, Spine Neuro Specialist Centre, Gleneagles Medical Centre #08-08, 6 Napier Road, 258499 Singapore. E-mail: rajspineclinic@gmail.com

The early designs employ anchoring rails, e.g. Prestige LP (Medtronic, Memphis, USA), anchoring central keels, e.g. ProDisc (DePuy Synthes, Raynham, USA) and fixation teeth, e.g. DISCOVER (DePuy Synthes, Raynham, USA) to improve the stability of the implant. The preparation of end-plates is arguably the most difficult step in cervical disc replacement. It requires accurate drilling and milling of the end-plates to fit the shape of the implant and also the positions of its keels or rails. Ill-fitting implants are prone to migration.^[5] Sagittal splits in the vertebral bodies have also been reported with the use of keeled prostheses.^[6] Newer implants were designed to reduce the difficulty of end-plate preparation. Since 2010, our department has started using Discocerv (Alphatec Spine, Carlsbad, USA) a keel-less implant, and Activ-C (B. Braun, Sheffield, UK), a shallow keel implant.

Discocerv (Alphatec Spine, Carlsbad, USA) is a constrained device with ball-and-socket joint and cranial geometric center.^[7] The end-plates are made from a combination of pure titanium and titanium alloy, and the joint consists of ceramic-on-ceramic bearing surface. The end-plates are designed with an anatomical profile characterized by convexity in the sagittal plane for the upper plate and convexity in the frontal plane for the lower plate. Two footprints are available, one 13 mm × 17 mm and the other 15 mm × 20 mm; the height ranges from 5 mm to 8 mm. The implant is shown in Figure 1a.

Activ-C (B. Braun, Sheffield, UK) consists of two components: A superior prosthesis plate with spikes for anchoring in the vertebral body, and an inferior prosthesis plate with integrated polyethylene inlay and central anchoring fin for fixation in the vertebral body. The prosthesis plates and the polyethylene inlay together form a ball and socket joint. The polyethylene inlay is anchored to form-fit in the inferior prosthesis plate. It has Cobalt chrome end-plates with a plasmapore (titanium) coating to facilitate bone growth.^[8] The implant is shown in Figure 1b.

We hypothesized that due to the reduced time in end-plate preparation, the newer generation of implants can be



Figure 1: (a) Anterior oblique view of Discocerv. The end-plates are designed with an anatomical profile characterized by convexity in the sagittal plane for the upper plate and convexity in the frontal plane for the lower plate. (b) Anterior oblique view of Activ-C implant. It consists of a superior prosthesis plate with spikes for anchoring in the vertebral body, and an inferior prosthesis plate with integrated polyethylene inlay and central anchoring fin for fixation in the vertebral body

inserted as quickly as the standard fusion procedure with cage and plate. We, therefore, conducted a retrospective study to compare the duration of surgery of cervical disc replacements (Discocerv and Activ-C) and anterior cervical discectomy and fusion (ACDF). The study also evaluated the functional outcome, complications, and radiographic outcome of cervical disc replacement.

Materials and Methods

This was a single surgeon retrospective study, with all surgery performed by the senior author (RT). The study was approved by the SingHealth Central Institutional Review Board. Patients who underwent cervical disc replacement from January 2010 to March 2014 in the department of neurosurgery, Singapore General Hospital were included.

Patients who were relatively younger (less than 60 years old) were selected for disc replacement. They possessed relatively good range of motion of the functional spinal unit (FSU) at the discectomy level on preoperative dynamic X-rays. We did not perform disc replacement for patients whose preoperative dynamic X-rays showed evidence of instability or presence of significant anterior degenerative osteophytes. The implants used were either Discocerv or Activ-C.

For the purpose of comparison of duration of surgery, a matched group of patients who underwent ACDF during the same period were included ($N = 30$). The duration of surgery was timed from the beginning of incision until the completion of wound closure.

The angle of motion of the FSU were analyzed from preoperative and postoperative flexion-extension lateral cervical X-ray. The latest postoperative X-rays with flexion and extension views were analyzed (average 10 months postoperative). The Cobb's angles of the FSU were measured at flexion and extension. The Cobb's angle of neutral position was taken as midway between the extreme of flexion and extension. A kyphotic angle (flexion) was arbitrarily given a positive (+) value, and a lordotic angle (extension) was given a negative (-) value. The range of sagittal motion was derived from the difference of Cobb's angle measured at extreme flexion and extension positions. The preservation of motion was expressed as a percentage (%) where the nominator was the range of motion after instrumentation, and the denominator was the range of motion after before instrumentation.

The functional outcomes were analyzed from the short form (SF-36) score and Neck Disability Index (NDI) of patients assessed preoperatively, at 3 months postoperative, 1-year postoperative, and yearly thereafter (up to 4-years post-op in this series). The patients were asked to do the evaluation at each clinic visit. For patients who were illiterate or not fluent with English, the evaluations were done with the assistance of the clinician.

Statistical analysis

T-test was used to determine the significance of the difference in mean between operative time, percentage of preservation of motion and lordosis of the FSU postoperatively. The difference is considered significant if $P < 0.05$. Paired *t*-test was used when the numbers of subjects of the two groups being compared are identical, while unpaired *t*-test was used when the numbers of subjects of the two groups being compared are not identical.

Results

Fifty patients were included (20 disc replacement and 30 fusion) from January 2010 to March 2014 (4 years 3 months). The mean ages of patients who underwent disc replacement and fusion group were 47 and 62 years respectively. The percentage of male in disc replacement group was 75% and in the fusion group was 77%.

The mean operation duration for single-level disc replacement was 2.6 h, and for single-level fusion was 2.4 h ($P = 0.4684$, unpaired *t*-test). For 2-levels surgery, the result was 3.5 h for 2-level hybrid surgery (one level disc replacement and one level fusion) and 3.4 h for fusion ($P = 0.4489$, unpaired *t*-test). The results were shown in Table 1. There was no significant difference in the duration of surgery between disc replacement and fusion surgery.

Postoperative dynamic X-rays were available for all patients who underwent disc replacement. Disc replacement resulted in preservation of an average of 67% of the angle of motion at the sagittal plane (flexion-extension). When analysed separately, the average angle of motion preserved by Discocerv and Activ-C were 69% and 64% respectively ($P=0.8023$, unpaired *t*-test). The average range of motion after disc replacement was 6.1° . When analysed separately, the average range of

motion after disc replacement for Discocerv and Activ-C were 5.9° and 6.3° respectively ($P=0.8164$, unpaired *t*-test). The Cobb's angle of the FSU at neutral position became more lordotic after insertion of Discocerv (pre-op -1.2° , post-op -6.3° , $P=0.0001$ paired *t*-test). The same was observed in Activ-C, but the difference did not achieve statistical significance (preoperative -0.7° , postoperative -2.6° , $P = 0.2393$ paired *t*-test). The results of motion preservation and spinal curvatures were shown in Table 2. The positions of all implants were found to be satisfactory. In particular, there was no subsidence or migration of implants.

The median clinical follow-up duration was 2 years (average 1.8 years). There was no incidence of major complications or significant neurovascular injury in this series of patients. There were no cases of wound infection or postoperative hematomas. The functional outcomes were assessed by SF-36 score and NDI.

A significant improvement in SF-36 scores was seen as early as 3 months postoperative (from the average of 57 preoperative to 92 at 3 months). The improvement was sustained up to year 4 [Figure 2]. Similar improvement was also observed in the NDI, dropping from preoperative average of 16% to 3% at 3 months postoperative. The improvement was also sustained up to the fourth year of follow-up [Figure 3].

Discussion

Our study showed that insertion of a shallow keel or keel-less cervical artificial disc were almost as fast as insertion of a cage and plate for fusion. There was no significant difference in the duration of surgery as shown in Table 1. The implants were designed to circumvent the cumbersome steps of drilling the end-plate at a specific lordotic angle, as well as preparation of the grooves to match the keels and rails of the implant. Discocerv took advantage of the concavity of the end-plates to secure the implant, which was made with a matching dome shape.

Almost all patients who underwent disc replacement have a good preoperative range of motion at the instrumented level (average 10°) owing to stringent selection criteria. Both implants preserved the range of sagittal motion at an average of 67%. However, it ranged from 15% to 160% (standard deviation 39%). We postulated that patients with preservation of motion $<50\%$ might have less favorable outcome compared to those with $>50\%$ preservation. However, analysis of our results nullified the above hypothesis. According to results

Table 1: Comparison of duration of surgery between cervical disc replacement and ACDF

	Average operation duration (h)	Number of patients	T-test
Single-level ACDF	2.4	15	$P=0.4684$
Single-level disc replacement	2.6	11	
Two-level ACDF	3.4	15	$P=0.4489$
Hybrid two-level surgery*	3.5	9	

*One level disc replacement+one level ACDF. ACDF – Anterior cervical discectomy and fusion

Table 2: The results of assessment of the preoperative and postoperative dynamic radiographs showing (%) preservation of motion at the FSU and increase in lordosis at the FSU

Type of implant	Number of cases	Average preoperative Cobb's angle				Average postoperative Cobb's angle				Preservation of motion (%)
		Flex	Neut	Ext	Motion	Flex	Neut	Ext	Motion	
Discocerv	13	3.5	-1.2	-5.9	9.4	-3.3	-6.3	-9.2	5.9	69
Activ C	7	4.7	-0.7	-6.0	10.7	0.5	-2.6	-5.8	6.3	64

Flex – Flexion; Neut – Neutral; Ext – Extension; FSU – Functional spinal unit

shown in Table 3, the patients with <50% preservation of motion did just as well as those with >50% preservation. The data seemed to suggest that improvement of the short-term outcome is contributed mainly by the effect of decompression and not preservation of motion. However, owing to the small sample size, we were unable to draw a firm conclusion about this.

Our study showed that the Discocerv implant restored the cervical lordosis at the neutral position, more so than the Activ-C implant. This is likely due to its design where the superior surface is convex and lordotic, as shown in Figure 4. However, we were unsure if the restoration of lordosis would be translated into improved long-term outcome. In a study by Kim *et al.*,^[9] no definite clinical deterioration was observed due to kyphogenesis of the FSU after insertion of Bryan Disc (Medtronic Sofamor Danek Inc, Memphis, TN). Results of long-term outcome are awaited.

Cervical disc replacement has been established as a viable alternative to fusion for selected patients who require discectomy.^[10] The ability to maintain or restore physiological movement is attractive. However, it has yet to become the standard of care. In most circumstances, access to cervical artificial disc is limited by the high cost of implant, especially if it is not reimbursable. Second, the lack of surgeon's experience due to limited caseload also served to reduce the adoption of disc replacement. Despite these factors, we felt that disc replacement still has the capacity to grow and the reasons are explained below.

The cost of an artificial disc is much higher^[11] if compared with fusion with iliac bone graft (virtually zero implant cost, not counting the cost of harvesting the graft and potential donor site complications). However, most surgeons nowadays would use a cage and plate, and some would use additional allograft bone as such demineralized bone matrix to augment the fusion rate, whenever patients can afford the cost. The cost of fusion could end up equal to, if not more than disc replacement surgery.^[12] With the cost being comparable, it is reasonable to believe that more patients would be inclined to choose disc replacement that preserves physiological motion, rather than fusion. A recent study by Qureshi *et al.* showed that cervical disc replacement is as cost-effective as fusion if the artificial disc could remain functional for at least 14 years.^[13]

Table 3: Comparison of the functional outcome between patients with <50% and >50% preservation of sagittal motion

Preservation of sagittal motion %	Average 3 months SF-36
<50	89
>50	94
<i>P</i> =0.1594 (<i>t</i> -test)	

SF – Short form

There is, traditionally, a steep learning curve in mastering the technique of cervical disc replacement, and different types

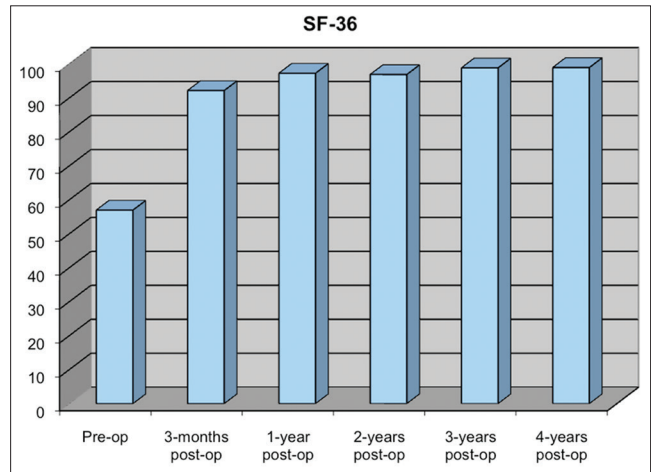


Figure 2: Average short form-36 for patients who underwent cervical disc replacement from preoperative to 2 years postoperative

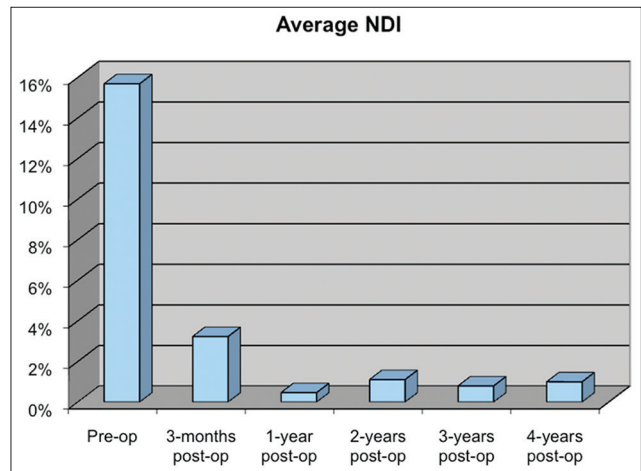


Figure 3: Average Neck Disability Index for patients who underwent cervical disc replacement from preoperative to 2 years postoperative



Figure 4: Side view (top image) and front view (bottom image) of the Discocerv implant showing that the superior plane is convex and lordotic, mimicking the normal anatomy

of implants require different techniques.^[14] Unfortunately, the number of patients suitable for disc replacement is very limited due to the strict selection criteria.^[15] Therefore, it may take a few years for surgeons with low to normal volume to perform enough cases to get pass the learning curve. However, newer implants have been designed to simplify the insertion technique, and thus reduced the steepness of the learning curve. As a result, more surgeons may convert to adopt disc replacement as the workhorse instead of fusion.

The long-term outcome of cervical disc replacement is still limited, especially those with >10 years follow-up. However, the authors felt that a conclusion should not be drawn solely from the first batch of result because there was a continuous improvement in design of implant, surgeon's skill and patient profile over the last decade. With the increasing availability of magnetic resonance imaging and increase in public's awareness of cervical spondylosis, cervical disc disease will likely be diagnosed at an earlier age as well as at an earlier stage. In other words, more patients may qualify for disc replacement in the future. The authors believe that cervical disc disease could be diagnosed early and treated with artificial disc replacement to preserve motion, while the facet joints, ligaments and muscles are still functioning.

Conclusion

The authors reported their experience with two relatively new implants, that is, Discocerv, a keel-less implant and Activ-C with a shallow keel. The duration of disc replacement surgery was not statistically longer compared with that of a fusion surgery. Disc replacement resulted in preservation of an average of 67% of the angle of motion at the sagittal plane (flexion-extension). A significant improvement in SF-36 scores was seen as early as 3 months postoperative (from 57 preoperative to 92 at 3-months). The improvement was sustained up to 4 years. Similar improvement was also observed in the NDI, dropping from preoperative average of 16–3% at 3 months postoperative. The improvement was also sustained up to the fourth year of follow-up. The authors feel that cervical disc replacement will have an important role in the treatment of cervical degenerative disc disease in the future.

References

1. Mummaneni PV, Burkus JK, Haid RW, Traynelis VC, Zdeblick TA. Clinical and radiographic analysis of cervical disc arthroplasty

- compared with allograft fusion: A randomized controlled clinical trial. *J Neurosurg Spine* 2007;6:198-209.
2. Nabhan A, Ahlhelm F, Pitzen T, Steudel WI, Jung J, Shariat K, *et al.* Disc replacement using Pro-Disc C versus fusion: A prospective randomised and controlled radiographic and clinical study. *Eur Spine J* 2007;16:423-30.
3. Pimenta L, McAfee PC, Cappuccino A, Cunningham BW, Diaz R, Coutinho E. Superiority of multilevel cervical arthroplasty outcomes versus single-level outcomes: 229 consecutive PCM prostheses. *Spine (Phila Pa 1976)* 2007;32:1337-44.
4. McAfee PC, Reah C, Gilder K, Eisermann L, Cunningham B. A meta-analysis of comparative outcomes following cervical arthroplasty or anterior cervical fusion: Results from 4 prospective multicenter randomized clinical trials and up to 1226 patients. *Spine (Phila Pa 1976)* 2012;37:943-52.
5. Goffin J, van Loon J, Van Calenbergh F, Lipscomb B. A clinical analysis of 4- and 6-year follow-up results after cervical disc replacement surgery using the Bryan Cervical Disc Prosthesis. *J Neurosurg Spine* 2010;12:261-9.
6. Datta JC, Janssen ME, Beckham R, Ponce C. Sagittal split fractures in multilevel cervical arthroplasty using a keeled prosthesis. *J Spinal Disord Tech* 2007;20:89-92.
7. Barrey C, Champain S, Campana S, Ramadan A, Perrin G, Skalli W. Sagittal alignment and kinematics at instrumented and adjacent levels after total disc replacement in the cervical spine. *Eur Spine J* 2012;21:1648-59.
8. McGonagle L, Cadman S, Chitgopkar SD, Canavan L, O'Malley M, Shackelford IM. Activ C cervical disc replacement for myelopathy. *J Craniovertebr Junction Spine* 2011;2:82-5.
9. Kim SW, Shin JH, Arbatin JJ, Park MS, Chung YK, McAfee PC. Effects of a cervical disc prosthesis on maintaining sagittal alignment of the functional spinal unit and overall sagittal balance of the cervical spine. *Eur Spine J* 2008;17:20-9.
10. Qureshi S, Goz V, McAnany S, Cho SK, Hecht AC, Delamarer RB, *et al.* Health state utility of patients with single-level cervical degenerative disc disease: Comparison of anterior cervical discectomy and fusion with cervical disc arthroplasty. *J Neurosurg Spine* 2014;20:475-9.
11. Singh K, Vaccaro AR, Albert TJ. Assessing the potential impact of total disc arthroplasty on surgeon practice patterns in North America. *Spine J* 2004;4 6 Suppl:195S-201.
12. Warren D, Hoelscher C, Ricart-Hoffiz P, Bendo J, Goldstein J. Cost-utility analysis of anterior cervical discectomy and fusion versus cervical disc arthroplasty. *Evid Based Spine Care J* 2011;2:57-8.
13. Qureshi SA, McAnany S, Goz V, Koehler SM, Hecht AC. Cost-effectiveness analysis: Comparing single-level cervical disc replacement and single-level anterior cervical discectomy and fusion: Clinical article. *J Neurosurg Spine* 2013;19:546-54.
14. Sethi R, Wood KB, Daley J, Herndon JH. Spinal arthroplasty: Indications and early results. What will the future hold? *Orthop J Harv Med Sch* 2005:113-5.
15. Cason GW, Herkowitz HN. Cervical intervertebral disc replacement. *J Bone Joint Surg Am* 2013;95:279-85.

How to cite this article: Ling JM, Tiruchelvarayan R. Early clinical and radiographical results of keel-less and shallow keel cervical disc replacement. *Asian J Neurosurg* 2015;10:5-9.

Source of Support: Nil, **Conflict of Interest:** None declared.