

CASE REPORT

Coil Embolisation for Endovascular Treatment of Proper Hepatic Artery Aneurysm Using the Balloon Occlusion Technique

Junetsu Akasaka ^{a,*}, Toru Saguchi ^b, Norifumi Kennoki ^b, Shunya Shindo ^a

^a Division of Cardiovascular Surgery, Tokyo Medical University Hachioji Medical Centre, Tokyo, Japan

^b Division of Radiology, Tokyo Medical University, Tokyo, Japan

Introduction: Endovascular repair (ER) as a minimally invasive approach can be effective for treating hepatic artery aneurysm (HAA) with gratifying results. Microcoil embolisation is the main technique used in ER. However, the coil embolisation of a large proper HAA (PHAA) with a very wide neck tends to be extremely troublesome owing to the limited length of the inflow and outflow artery. Moreover, it is difficult because of rapid blood flow in the proper hepatic artery (PHA) and the difficulty in preserving its branch flow. Microcoil embolisation of the inflow and outflow of a PHAA with the balloon occlusion technique through an originally developed single guiding sheath system was performed successfully.

Report: A 73 year old woman was diagnosed with large PHAA (65 mm) by computed tomography examination. The PHAA was successfully treated by endovascular embolisation with microcoils using the balloon occlusion technique through a single guiding sheath system.

Discussion: This method is safe and effective for the treatment of a large PHAA.

© 2018 The Authors. Published by Elsevier Ltd on behalf of European Society for Vascular Surgery. This is an open access article under the CC BY-NC-ND license (<http://creativecommons.org/licenses/by-nc-nd/4.0/>).

Article history: Received 22 June 2018, Revised 12 September 2018, Accepted 13 September 2018,

Keywords: Balloon occlusion technique, Endovascular repair, Hepatic artery aneurysm, Short neck patient

INTRODUCTION

Repair of hepatic artery aneurysm (HAA) is recommended when the aneurysm reaches 2 cm in diameter because of the increased rupture risk and an associated 70–100% morbidity following rupture. Open repair has morbidity rates as high as 70%,¹ therefore, endovascular therapy may become more common in HAA treatment. In this report, a case of proper HAA (PHAA) treated by transcatheter arterial microcoil embolisation is presented. The PHAA was 65 mm in diameter and was located very close to the origin of the gastroduodenal artery (GDA) at the inflow site, and the junction of the right and left hepatic arteries at the outflow site. The distal balloon occlusion technique was adopted to tighten and make more compact the embolisation of both the right (RHA) and left hepatic artery (LHA) to prevent occlusion of any branches, which could compromise the intrahepatic collateral circulation. The proximal balloon occlusion technique was also adopted to control the blood flow to perform coil embolisation without microcoil migration into the aneurysm.² Moreover, the uniqueness of the double axial catheter

method inserted through an originally developed single catheter was demonstrated. This method has been reported for brain artery aneurysm repair,³ however, this is the first case report to show the successful use of the technique in PHAA repair.

CASE REPORT

A 73 year old woman was referred with a large PHAA. The asymptomatic aneurysm was found incidentally during pre-operative evaluation for osteoarthritis treatment. A palpable abdominal mass was seen and the diagnosis was confirmed by abdominal ultrasound. The patient had a medical history of acute lymphocytic leukaemia. Chemotherapy was performed according to the JALSG-ALL97 protocol as previously reported,⁴ and whole brain irradiation therapy was added to prevent central nervous system involvement by the leukaemia, which the patient had had six years previously. The patient was in remission from leukaemia and did not receive any treatment. There was no medical history of trauma, abdominal surgery, or pancreatitis. Blood tests were normal and there was no evidence of inflammation or infection. Contrast enhanced abdominal computed tomography (CT) and coeliac artery angiography confirmed the diagnosis of PHAA, which had a diameter of 65 mm (Fig. 1a and b). No other aneurysm was identified. Coeliac artery angiography through the right femoral artery showed that the PHAA was located 11 mm distal to the origin of the GDA proximally, and 7 mm from the junction of the

* Corresponding author. Division of Cardiovascular Surgery, Tokyo Medical University Hachioji Medical Centre, 1163 Tate-machi, Hachioji, Tokyo 193-0998, Japan.

E-mail address: june_ak@hotmail.com (Junetsu Akasaka).

2405-6553/© 2018 The Authors. Published by Elsevier Ltd on behalf of European Society for Vascular Surgery. This is an open access article under the CC BY-NC-ND license (<http://creativecommons.org/licenses/by-nc-nd/4.0/>).

<https://doi.org/10.1016/j.ejvssr.2018.09.001>

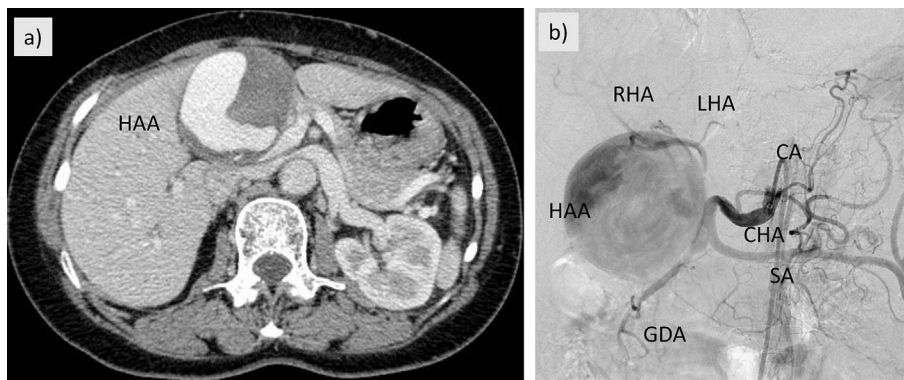


Figure 1. (a) Contrast enhanced computed tomography revealed a huge aneurysm of the common hepatic artery. (b) Coeliac angiography demonstrated a saccular aneurysm 11 mm distal to the origin of the proper hepatic artery and 7 mm proximal to the junction of the left and right hepatic artery. *Note.* CA = coeliac artery; CHA = common hepatic artery; SA = splenic artery; GDA = gastroduodenal artery; LHA = left hepatic artery; RHA = right hepatic artery; HAA = hepatic artery aneurysm.

right and left hepatic arteries distally (Fig. 1b). Through an originally developed 4.5 Fr guiding sheath (Parent Plus 45: shepherd hook type) in collaboration with Medikit Co. Ltd. (Tokyo, Japan), which is large enough to carry a 2.7 Fr high flow microcatheter (Renegade HI-Flo; Boston Scientific, Boston, MA, USA) and Logos Micro Balloon (Pilorax Medical Co., Yokohama, Japan). A 1.9 Fr microcatheter (MARVEL, Tokai Medical, Kasugai, Japan) was inserted into the 2.7 Fr high flow microcatheter in the form of a dual coaxial system.²

First, the RHA was successfully embolised using the distal balloon occlusion technique (Fig. 2a) with two microcoils (Orbit Galaxy; Cerenovus, Irvine, CA, USA) (Fig. 2b). Second, the LHA was embolised using two microcoils in the same manner as the RHA, and an additional microcoil was placed at the junction between the right and left hepatic arteries (Ruby coil; Penumbra, Inc., Alameda, CA, USA) (Fig. 2c and d). Next, the proper hepatic artery was successfully embolised using the proximal balloon occlusion technique (Fig. 2e) with three

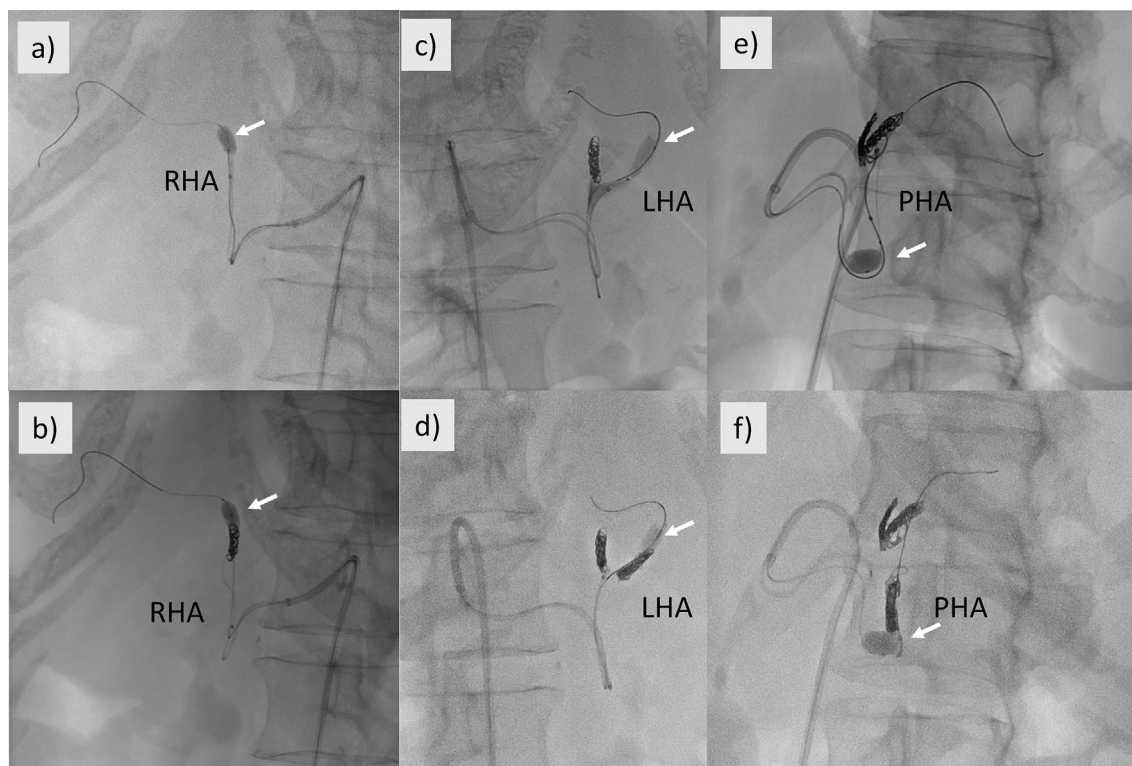


Figure 2. Coil embolisation using the distal balloon occlusion technique. (a) Angiography during catheterisation shows a microcatheter inserted into the right hepatic artery (RHA) under distal balloon occlusion (white arrow) in the RHA. (b) Angiography during coil embolisation shows a tight and compact coil. (c, d) Similar to the left hepatic artery (LHA). (e, f) Under proximal balloon occlusion in the proper hepatic artery.

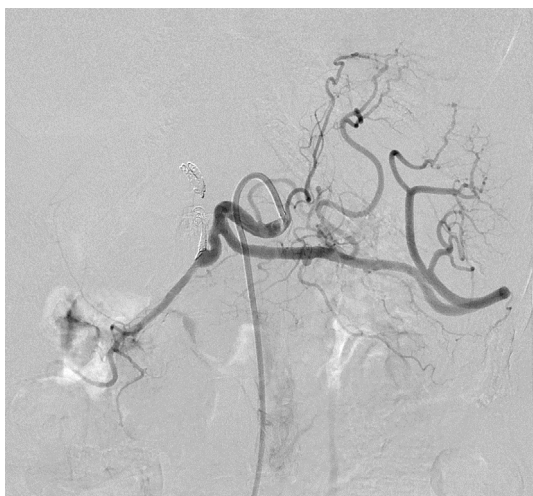

Figure 3. Angiography of the coeliac artery after embolisation.

microcoils (two Orbit Galaxy coils and a Ruby coil) distal to the origin of the GDA, without occluding it (Fig. 2f). Coeliac angiography after embolisation showed the completely occluded aneurysm (Fig. 3).

The patient recovered fully without any complications. Enhanced abdominal CT examination one year after treatment revealed no exacerbation of the PHAA sac, and aneurysm shrinkage to 3 cm (Fig. 4a).

DISCUSSION

Although rare, HAA is the second most common type of visceral aneurysm after splenic artery aneurysm. The incidence of HAA is 0.01% in routine autopsy reports.¹ This very rare disease requires determination of the best treatment, weighing open surgery against the endovascular therapy. Although open surgical repair of HAA remains the gold standard, it is technically difficult and carries a potentially increased morbidity risk. As such, minimally invasive endoluminal techniques may offer a distinct advantage over conventional repair.

Coil embolisation is an alternative to open repair and has become increasingly popular. Technical difficulty arises from the short coil embolisation site, as in this case. The balloon occlusion technique was adopted. When microcoil embolisation of PHA, RHA and LHA is performed, the distal balloon occlusion technique is used. Therefore, the microcoils can be placed accurately and over as short a segment as possible without migration. This method can embolise the target artery more tightly and compactly than the proximal balloon occlusion technique.⁵ As a result, it also prevented occlusion of the collateral branch that supplies blood flow distally.² Also, the original 4.5 Fr guiding sheath system was used, so only a single approach via the right femoral artery was required. Usually with microcoil embolisation under balloon occlusion, the microcatheter and microballoon catheter have to be placed for each microcatheter via the right and left femoral arteries.² In this case, an original 4.5 Fr guiding sheath system was developed, and therefore only a single sheath was inserted via the right femoral artery. This is apparently the first case report using the system to treat PHAA.

The risk of hepatic necrosis was proven to be small in this case, but collateral circulation via the right inferior phrenic artery and subcostal arteries does not always restore arterial blood flow after ligation of HAAs distal to the GDA.⁶ In the present case, there was a collateral artery from the GDA and a small mesenteric artery to the LHA, which was shown by enhanced CT (Fig. 4b). However, when microcoil embolisation of the PHA was performed, only the proximal balloon occlusion technique was used for control of blood flow to prevent migration of microcoils.

In conclusion, transcatheter arterial microcoil embolisation to treat a PHAA using the proximal and distal balloon occlusion technique with an originally developed 4.5 Fr guiding single sheath system was performed. This technique is an effective and minimally invasive treatment in patients with PHAA, using the isolation technique under balloon occlusion with a 4.5 Fr guiding sheath via single groin access. Although the PHAA diameter shrank to three cm, the diameter remains large. The patient will be followed carefully.

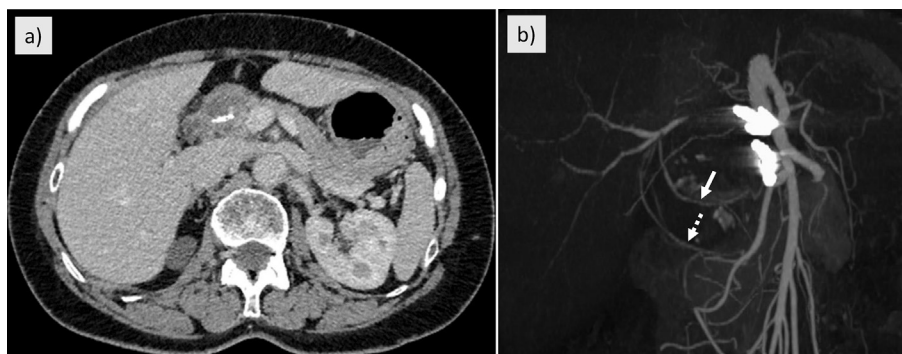


Figure 4. (a) Abdominal enhanced computed tomography one year after treatment showing the hepatic artery aneurysm diameter reduced to 3 cm. (b) The white arrow shows the collateral artery from the superior mesenteric artery, and the white dotted arrow shows the collateral artery from the gastroduodenal artery to the right hepatic artery.

CONFLICTS OF INTEREST

None.

FUNDING

None.

REFERENCES

- 1 Erben Y, De Martino RR, Bjarnason H, Duncan AA, Kalra M, Oderich GS, et al. Operative management of hepatic artery aneurysms. *J Vasc Surg* 2015;**62**:610–5.
- 2 Takasaka I, Kawai N, Sato M, Tanihata H, Sonomura T, Minamiguchi H, et al. Preoperative microcoil embolization of the common hepatic artery for pancreatic body cancer. *World J Gastroenterol* 2012;**16**:1940–5.
- 3 Jeon HJ, Kim BM, Kim DJ, Park KY, Kim JW, Kim DI. Combination of multicatheter plus stent or balloon for treatment of complex aneurysms. *Am J Neuroradiol* 2016;**37**:311–6.
- 4 Jinnai I, Sakura T, Tsuzuki M, Maeda Y, Usui N, Kato M, et al. Intensified consolidation therapy with dose-escalated doxorubicin did not improve the prognosis of adults with acute lymphoblastic leukemia: the JALSG-ALL97 study. *Int J Hematol* 2010;**92**:490–502.
- 5 Yunaiyama D, Saguchi T, Moriya T, Shirota N, Otaka J, Tokuyue K, et al. Short-segment coil embolization using a double-balloon technique in an experimental vascular model. *Cardiovasc Interv Radiol* 2017;**40**:1255–60.
- 6 Angiletta D, Marinazzo D, Pulli R, Regina G. Management of a large hepatic artery. *J Vasc Surg Cases* 2015;**1**:97–9.