

Increased signal intensity of spinal cord on T2W magnetic resonance imaging for cervical spondylotic myelopathy patients

Risk factors and prognosis (a STROBE-compliant article)

Li-qiang Yin, MD*, Jian Zhang, MD, Yong-gui Wu, MD, Jin-hui Li, MD, Qing Yang, MD

Abstract

To investigate the risk factors for progression of increased signal intensity (ISI) on T2W magnetic resonance imaging (MRI) and its prognostic value in patients with cervical spondylotic myelopathy (CSM).

A total of 109 patients with CSM were included in this study. All the patients were treated with anterior cervical discectomy and fusion. MRI was performed for all 109 patients preoperatively and at the final follow-up. Radiological evaluation included ISI, anterior compression (AC) of dural and spinal cord, hyperintensity region (HR) at the involved level. Clinical data including Japanese Orthopedic Association (JOA) score, Neck Disability Index (NDI) score, and Visual Analogue Scale were collected and evaluated. Patients were divided into 2 groups according to ISI grades (Group A: no hyper-intensity; Group B: presence of ISI). Then all patients presented with ISI were divided into 2 subgroups based on the range of HR (Group B1: hyper-intensity diameter accounts for less than half of the spinal cord diameter at the involved level; Group B2, hyper-intensity diameter accounts for more than half of the spinal cord diameter at the involved level). AC, disease duration, age, and gender were analyzed as potential risk factors.

Significantly better JOA and NDI scores were observed in Group A preoperatively and at the final follow-up, compared to Group B ($P < .05$). Disease duration was found significantly longer in patients with ISI ($P < .05$). Notably better JOA and NDI scores were noticed in Group B1 rather than Group B2 ($P < .05$). Logistical regression showed that disease duration was the only factor that significantly correlated with the progress of ISI ($P < .001$).

CSM patients with ISI on T2W MR images had poorer surgical outcomes compared to others, while the increased range of HR may deteriorate preoperative neurological function. Moreover, patients with longer disease duration had greater risk of ISI in spinal cord.

Abbreviations: AC = anterior compression, ACDF = anterior cervical discectomy and fusion, ASIA = American Spinal Injury Association, CSM = cervical spondylotic myelopathy, HR = hyper-intensity region, ISI = increased signal intensity, JOA = Japanese Orthopedic Association, MRI = magnetic resonance imaging, NDI = Neck Disability Index, VAS = Visual Analogue Scale.

Keywords: cervical spondylotic myelopathy, magnetic resonance imaging, retrospective

1. Introduction

Cervical spondylotic myelopathy (CSM) is the most common cause of spinal cord dysfunction in adults. Magnetic resonance imaging (MRI) is an invaluable examination tool in patients with

compressive cervical myelopathy.^[1] MRI can not only depict the degree of spinal cord compression, but also reflect the pathological changes in the spinal cord.^[2] The increased signal intensity (ISI) of spinal cord on axial T2W MR images, also known as “snake-eye appearance,” is often observed in CSM patients.

The significance of signal intensity change of spinal cord has been well documented. It has been widely accepted that low-intensity signal change on T1W MR images is a prognostic factor for poor outcomes after surgery for CSM.^[3–5] However, based on our clinical observation, very few CSM patients presented with both low-intensity signal change on T1W MR images and ISI on T2W MR images. Furthermore, poor outcomes were observed in substantial numbers of CSM patients presented with ISI on T2W MR images without low-intensity signal change on T1W MR images, which indicates ISI on T2W MR images may be one independent risk factor in CSM patients. Besides, the prognostic value of ISI on T2W MR images remains controversial in literature. Some research revealed that CSM patients presented with ISI preoperatively have poor outcomes after surgery,^[6–8] while others reported no correlation between prognosis and preoperative ISI.^[3,4,9] In 2010, Zhang et al^[7] reported that CSM patients with low signal intensity ratio on T2 images who were younger and had shorter duration of disease may achieve good surgical outcomes. Furthermore, different types of ISI changes

Editor: Neeraj Lalwani.

The authors have no conflicts of interest to disclose.

The datasets generated during and/or analyzed during the current study are available from the corresponding author on reasonable request.

Second Department of Orthopedics, Jincheng People's Hospital, Jincheng City, Shanxi Province, China.

* Correspondence: Li-qiang Yin, No. 456 Wenchang East Street, Jincheng City, Shanxi Province 048026, China (e-mail: yinliqiang2019@163.com).

Copyright © 2020 the Author(s). Published by Wolters Kluwer Health, Inc. This is an open access article distributed under the terms of the Creative Commons Attribution-Non Commercial License 4.0 (CCBY-NC), where it is permissible to download, share, remix, transform, and buildup the work provided it is properly cited. The work cannot be used commercially without permission from the journal.

How to cite this article: Yin Lq, Zhang J, Wu Yg, Li Jh, Yang Q. Increased signal intensity of spinal cord on T2W magnetic resonance imaging for cervical spondylotic myelopathy patients: risk factors and prognosis (a STROBE-compliant article). *Medicine* 2020;99:49(e23098).

Received: 28 February 2020 / Received in final form: 8 October 2020 / Accepted: 12 October 2020

<http://dx.doi.org/10.1097/MD.00000000000023098>

were considered another factor affecting prognosis of these patients.^[8] However, the previous studies did not control for surgical procedures like laminoplasty, laminectomy, or anterior cervical discectomy and fusion (ACDF), which have an independent effect on the outcomes. Also, to the best of our knowledge, few studies have looked at the potential risk factors for ISI. Thus, the purpose of this study was to investigate the predictive value of ISI in CSM patients that underwent ACDF, with a further analysis of the possible cause of ISI in CSM patients.

2. Materials and methods

2.1. Subjects

After the Institutional IRB approval, consecutive CSM patients who underwent ACDF at our institution between May 2014 and April 2017 were retrospectively reviewed. The inclusion criteria were: CSM patients with age >18 years; underwent one- or multilevel ACDF for spinal canal stenosis or spinal cord compression; and with a minimum 2-year follow-up. Patients with cervical spine fracture, dislocation, and previous cervical spine surgery were excluded. Finally, a total of 109 CSM patients meet the inclusion criteria. Patient demographic data including age, gender, duration of disease, involved levels, and follow-up time were gathered from the medical record.

2.2. Radiological evaluation

Radiological findings on MRI images included: increase in the signal intensity of the involved level (ISI); anterior compression (AC) of dural and spinal cord; hyper-intensity region (HR) at the involved level. The ISI was ranked as grades 0 to 1: grade 0, as dark as or slightly more bright than cerebrospinal fluid at C7/T1 level; grade 1, markedly more bright than cerebrospinal fluid at C7/T1 level. The patients were then divided into 2 groups according to the presence of hyper intense signal on T2W MRI images: group A, CSM patients with grade 0 ISI; group B, CSM patients with grade 1 ISI. The AC was ranked as grades from 0 to 2: grade 0, compression on less than one-third of spinal cord; grade 1, compression on more than one-third of spinal cord; grade 2, compression on more than two-thirds of spinal cord. The HR was defined as grades from 0 to 2: grade 0, no hyper-intensity at the involved level; grade 1, hyper-intensity diameter accounts for less than half of the spinal cord diameter at the involved level; grade 2, hyper-intensity diameter accounts for more than half of the spinal cord diameter at the involved level. Patients were then divided into 2 subgroups according to the HR: group B1: patients with grade 1 HR; group B2: patients with grade 2 HR (Table 1). At the final follow-up, the HR of all group B patients were reassessed. The MRI scanning was performed before surgery and at 24-months follow-up. Images were independently read by 2

senior residents, and the inconsistent results were examined by another senior attending.

2.3. Clinical evaluation

Clinical data including American Spinal Injury Association (ASIA) grade, Japanese Orthopedic Association (JOA) score, Neck Disability Index (NDI) score, and Visual Analogue Scale (VAS) were collected and evaluated preoperatively and at 3, 6, 9 and the final follow-up.

2.4. Statistics

All the data analysis was performed using SPSS 14.0 statistical software (SPSS 14.0, Chicago, IL). A paired sample *t* test was performed to compare preoperative and final follow-up data. The independent sample *t* test was applied to determine the difference of radiological and clinical outcomes between the 2 groups and 2 subgroups. Logistic regression analysis was performed to identify correlations between ISI and AC, duration, age and gender. Significance was defined as a $P < .05$.

3. Results

A total of 109 patients were included in this study. There were 62 males and 47 females. The average patient age at presentation was 48.3 years (range, 29–64 years) and the mean follow-up duration was 25.9 months (range, 24–61 months). The mean disease duration was 11.2 months and ranged between 1–48 months.

Of these 109 patients, 65 with grade 0 ISI were assigned into group A, with a mean age of 47.5 years (range, 29–64 years). Forty-four patients with grade 1 ISI were assigned into group B (Fig. 1), with an average age of 49.1 years (range, 32–60 years). The mean involved levels of CSM were 1.8 in group A and 1.9 in group B, with no significant difference between the 2 groups. The average duration of CSM was 9.9 months in group A, which is apparently shorter than 14.1 months of group B ($P < .05$). Regarding ASIA scores, more than half of group A patients presented with neurologic dysfunction as ASIA D, while most group B patients were classified as ASIA C. The AC of spinal cord was: grade 0 in 44 patients, grade 1 in 13 patients, and grade 2 in 8 patients in group A; grade 0 in 21 patients, grade 1 in 18 patients, and grade 2 in 5 patients in group B. In group B, 31 patients presented with grade 1 hyper-intensity region, while the other 13 presented with grade 2. Detailed data were listed in Table 2.

All the clinical data, including JOA, NDI, VAS scores, were notably improved after surgery. Generally, the mean JOA score was improved from 11.1 preoperatively to 13.9 after surgery ($P < .05$). The average NDI and VAS were changed from 40.2 to 27.8 and from 2.9 to 2.1, respectively ($P < .05$). At the final follow-up, the mean JOA, NDI, and VAS scores were 14.1, 21.3, and 2.0, respectively. Significant differences of preoperative JOA and NDI were observed comparing the clinical data between groups A and B. At the final follow-up, apparently worse JOA and NDI scores were observed in group B patients (Fig. 2). The change of ASIA grades of group A and B patients was presented in Table 3. Fifty-nine patients in group A achieved at least 1 grade improvement of ASIA, while 15 patients in group B remained unchanged at the final follow-up. In patients presented with hyper-intensity spinal cord, there were 31 patients with HR

Table 1
Demonstration of groups.

| Group A | Group B |
|-------------------------------|-----------------------------------|
| CSM patients with grade 0 ISI | CSM patients with grade 1 ISI |
| | Group B1 patients with grade 1 HR |
| | Group B2 patients with grade 2 HR |

CSM = cervical spondylotic myelopathy, ISI = increased signal intensity.

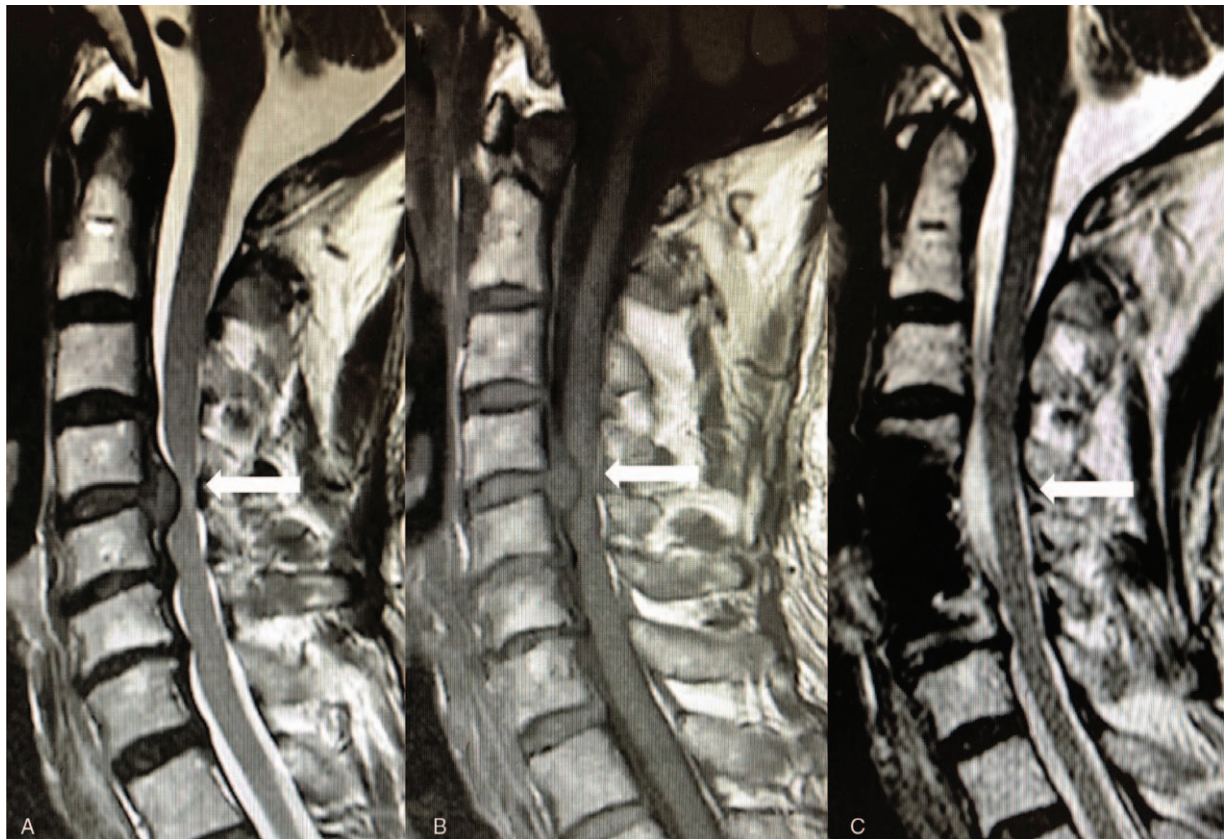

Figure 1. A 53-year-old male CSM patient with anterior compression at C4/5 and C5/6 (A). Duration of symptoms was 14 months at the initial visit. ISI was observed at C4/5 level on T2W MR images (a, white arrow). No sign of decreased signal intensity was found on T1W MR images (B). At the final follow-up (25-month post operation), remaining ISI was noticed on T2W MR images (c, white arrow). CSM = cervical spondylotic myelopathy, ISI = increased signal intensity.

| | Group A | Group B |
|----------------------|-------------|--------------|
| No. | 65 | 44 |
| Age (Y) | 47.5 ± 17.1 | 49.1 ± 16.5 |
| Gender (M/F) | 36/29 | 26/18 |
| Disease duration (M) | 9.3 ± 5.1 | 14.1 ± 5.5* |
| Involved levels | 1.8 ± 0.8 | 1.9 ± 0.8 |
| Follow-up time (M) | 26.5 ± 8.1 | 25.3 ± 7.5 |
| JOA | 12.4 ± 3.2 | 9.9 ± 3.4* |
| NDI (%) | 37.2 ± 18.1 | 46.9 ± 17.2* |
| VAS | 2.8 ± 1.1 | 3.3 ± 1.0 |
| ASIA (No.) | | |
| A | 0 | 0 |
| B | 3 | 4 |
| C | 27 | 25 |
| D | 35 | 15 |
| E | 0 | 0 |
| AC (No.) | | |
| Grade 0 | 44 | 21 |
| Grade 1 | 13 | 18 |
| Grade 2 | 8 | 5 |
| HR (No.) | | |
| Grade 0 | 65 | 0 |
| Grade 1 | 0 | 31 |
| Grade 2 | 0 | 13 |

JOA = Japanese Orthopedic Association, NDI = Neck Disability Index.

*Mean values are presented as the mean ± SE.

*Indicates a statistically significant difference between the 2 groups.

affected less than half of the spinal cord diameter (group B1), and 13 with HR accounted more than half of the spinal cord diameter (group B2). At the final follow-up, 12 patients from group B1 and 1 patient from group B2 showed no sign of ISI, while 19 patients from group B1 and 12 patients from group B2 had decreased range of ISI (Table 4). Comparing the clinical data between groups B1 and B2, statistically worse preoperative JOA and NDI scores were noted in group B2. At the final follow-up, no significant difference was observed (Fig. 3).

Two-level logistic regression analysis was used to identify predictors of ISI presence (Table 5). It was found that disease duration was the only significant independent factor affecting the appearance of ISI ($P < .001$). No association was found between the presence of ISI and other factors like AC ($P = .055$), age ($P = .643$), and gender ($P = .701$). Logistic regression was performed for ISI patients with different grades of HR using AC, duration of symptoms, age, and gender. Disease duration was determined as the only variable that significantly affected the HR grades ($P < .001$).

4. Discussion

Cervical spondylosis is a progressive disease that frequently causes cervical myelopathy in individuals. Nerve involvement in CSM is embodied in the progressive neurological deterioration. Spinal cord injury may occur due to mechanical compression and vascular compromise, with resultant lesions in the dorsal and lateral columns and degeneration of the ascending and descend-

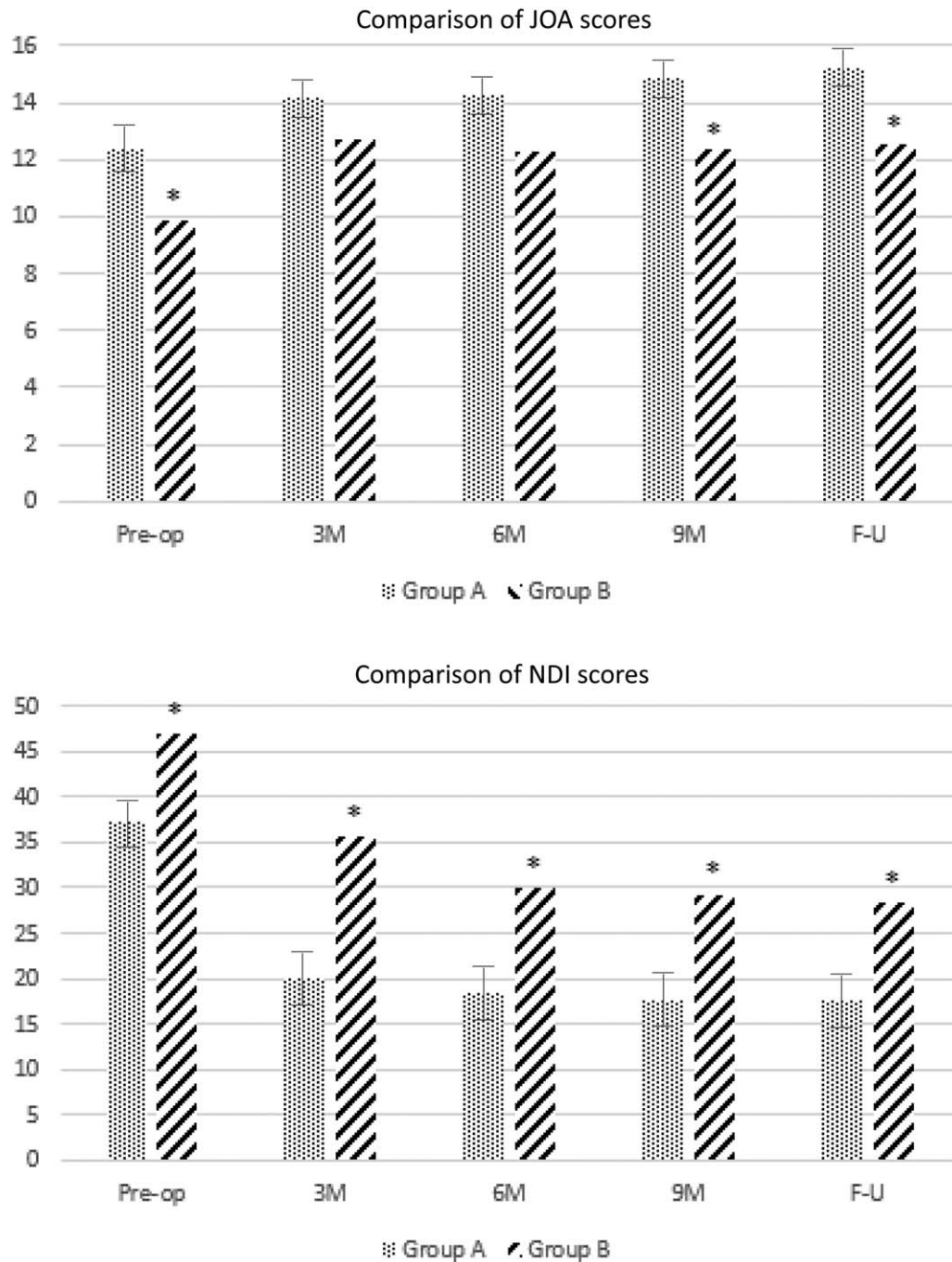


Figure 2. Comparison of preoperative and follow-up JOA and NDI scores between groups A and B. * Indicates a significant difference between the 2 groups. F-U: final follow-up. JOA = Japanese Orthopedic Association, NDI = Neck Disability Index.

ing tracts.^[6,10] In the late stages of this disease, spinal cord decompression surgery is imperative to expand the narrow spinal canal and release the compressed cord.

The neurological outcome of decompression surgery is influenced by several factors. Many authors have reported intramedullary signal intensity changes on MR images in CSM patients.^[2-4,6,11] Such signal intensity changes are considered myelomalacia or cord gliosis due to a long-term, continuous compressive effect on the spinal cord.^[11] It has been consistent that low-intensity signal change on T1W MRI is a predictor for poor outcome after decompression surgery.^[6,7] To our best

knowledge, the MRI findings of ISI in CSM patients were first reported by Takahashi et al^[12] in 1987. The significance of ISI has been investigated ever since, with conflicting results of its

Table 3
Change of ASIA grades of groups A and B at the final follow-up.

| | Unchanged | One grade | Two grades | Three grades |
|---------------|-----------|-----------|------------|--------------|
| Group A (No.) | 6 | 48 | 9 | 2 |
| Group B (No.) | 15 | 22 | 5 | 2 |

Table 4
The change of HR grades at the final follow-up.

| | Group B1 | | Group B2 | |
|---------------|----------|-----|----------|-----|
| | Preop | F-U | Preop | F-U |
| Grade 0 (No.) | 0 | 12 | 0 | 1 |
| Grade 1 (No.) | 31 | 19 | 0 | 12 |
| Grade 2 (No.) | 0 | 0 | 13 | 0 |

F-U = final follow-up, preop = preoperative.

predictive value. Some authors found that patients with ISI have poor prognosis after surgery.^[6-8] Nevertheless, others reported that no association was found between ISI and surgical outcomes.^[3,4,9] Zhang et al^[7] compared the clinical outcomes

of CSM patients with different ranks of signal intensity ratio. They concluded that CSM patients with high signal intensity ratio and pyramidal had poor prognosis after surgery. In 2011, Vedantam et al^[8] reported that sharp ISI changes on T2W MR images predicted a decreased likelihood of cure in patients with CSM or OPLL. Pathological study of the hyper-intensity district in CSM patients has demonstrated the destruction of the gray matter and significant neuronal loss in the anterior horn of spinal cord, suggesting that ISI is an unfavorable prognostic factor for recovery of neurological dysfunction.^[13] However, the previous studies included various surgical procedures with different surgical approaches, which may affect the outcomes of surgical treatment. Given the facts above, it is still uncertain the predictive value of ISI under control of surgical strategies in CSM patients. Besides, the few previous studies have reported the risk factors of

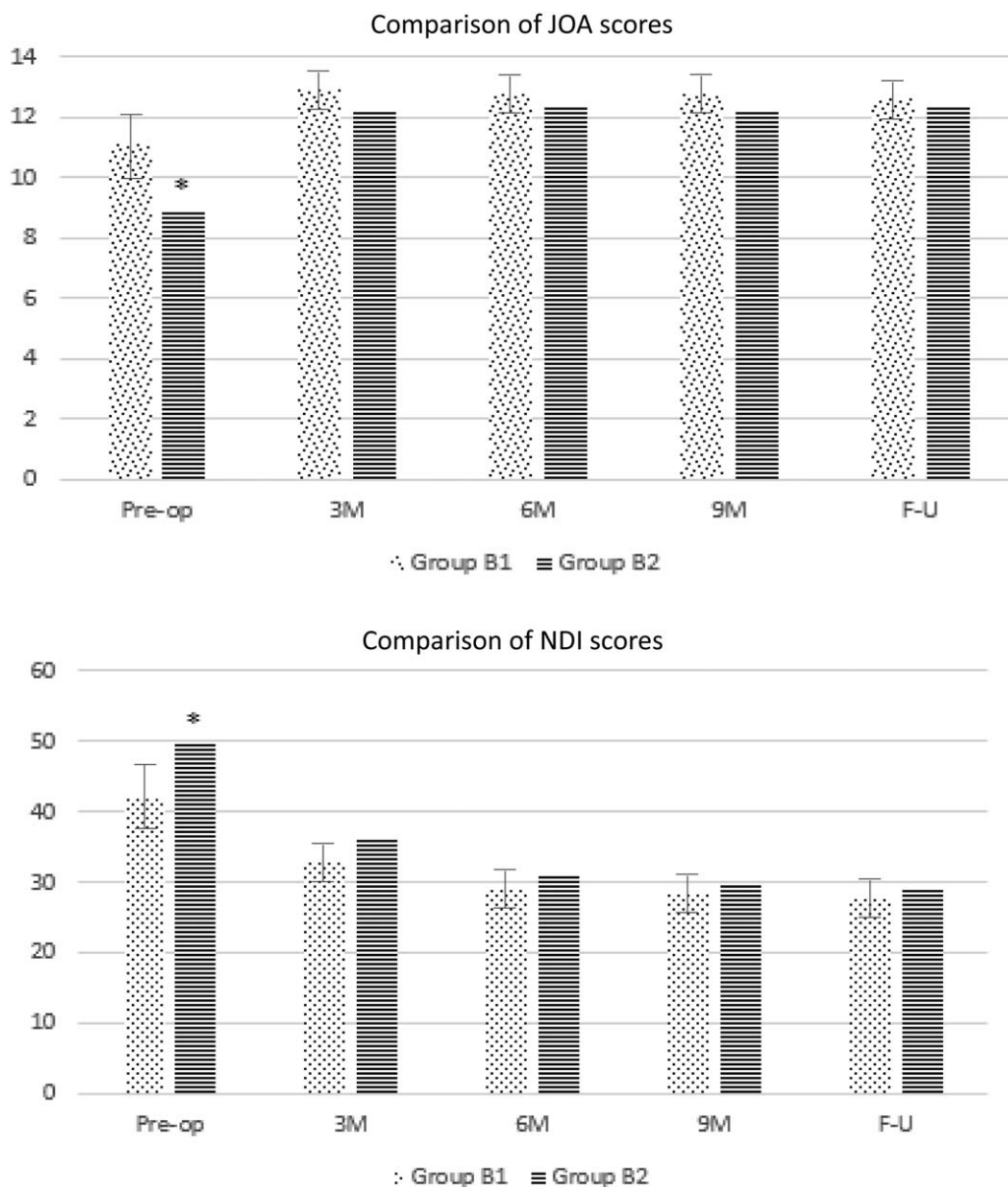


Figure 3. Comparison of preoperative and follow-up JOA and NDI scores between groups B1 and B2. * Indicates a significant difference between the 2 groups. F-U = final follow-up.

Table 5
Logistic regression analysis for factors predicting ISI and HR.

| Variables | ISI grades (0 or 1) | | | HR grades (1 or 2) | | |
|------------------|---------------------|-------|-----|--------------------|-------|----|
| | P | r | df | P | r | df |
| AC | .055 | 0.35 | 108 | .061 | 0.57 | 43 |
| Disease duration | <.001* | 0.50 | 108 | <.001* | 0.78 | 43 |
| Age | .643 | 0.14 | 108 | .587 | -0.30 | 43 |
| Gender | .701 | -0.40 | 108 | .064 | 0.45 | 43 |

* $P < .05$.

ISI in CSM patients. Thus, the current study was designed to evaluate the prognostic value of ISI in CSM patients who underwent ACDF, with a further investigation of possible cause of ISI.

Generally, all the 109 patients included in this study achieved notable improvement of neurological function after surgery. Significantly worse preoperative JOA and NDI scores were observed in group B patients, compared with group A. This result was in accordance with others in previous studies,^[6,7,11] which indicate that patients with ISI had greater neurological dysfunction before surgical treatment. At the final follow-up, the JOA and NDI scores were apparently improved compared to preoperative data, but still remained significantly different between the 2 groups. That means patients with ISI tend to experience lower recovery rate even after total decompression of the stenosis level, which is consistent with literature.^[6-8] Based on our observation, except for the ratio and type of ISI, the range of ISI on sagittal T2W MR images also varied from patients to patients. Our results revealed that patients with grade 2 HR presented with poorer preoperative JOA and NDI scores, but no significant difference was observed at the final follow-up. Given the decreased HR at the final follow-up, we considered that the increased HR may affect the neurological function, but it did not contribute to poor prognosis of patients with ISI.

A previous clinicopathological study of patients with CSM has revealed that there might be a common pattern of lesion progression.^[14] In other words, the ISI of spinal cord on T2W MR images was considered to include a wide range of compressive myelopathy pathologies and reflects various spinal cord recuperative potentials.^[14] Previous studies mainly focused on the predictive value of ISI in prognosis of CSM patients, but few had paid attention to the potential risk factors of ISI itself. Thus, based on our observation and previous studies, we selected AC, disease duration, age, and gender for analysis.^[15] Results of the current study showed that disease duration was the only factor that had an effect on the occurrence of ISI and the range of HR. That means, CSM patients with longer duration of disease may suffer higher risk of ISI of spinal cord and increased range of HR, which may contribute to poor surgical outcomes. However, no association was found between ISI progression and AC, age, gender, although nearly statistically significant correlation was observed between ISI and AC. Given the above results, we may conclude that degeneration of spinal cord and poor prognosis in CSM patients correlates more with the duration of spinal cord compression, instead of compression degree, age, or gender.

There were some limitations of our study. This is a retrospective study and we did not control for the disease-involved segments, which could affect surgical outcomes. Moreover, we did not have multicenter database to support our conclusion. Besides, the follow-up time was still too short.

Further multicenter study with long-term follow-up is needed to confirm the conclusions of the current study.

To our best knowledge, this is the first study that reported the potential risk factors for ISI in CSM patients. Our results demonstrated that CSM patients with ISI on T2W MR images had poorer surgical outcomes after ACDF compared to others. Increased range of hyper-intensity area could lead to greater preoperative neurological dysfunction, but had no effect on surgical outcomes. Furthermore, patients with longer duration of disease may suffer greater risk of occurrence of ISI of spinal cord.

5. Conclusion

In conclusion, CSM patients with ISI on T2W MR images had poorer surgical outcomes compared to others, while the increased range of HR may deteriorate preoperative neurological function. Moreover, patients with longer disease duration had greater risk of ISI in spinal cord.

Author contributions

Conceptualization: Liqiang Yin, Jian Zhang.

Data curation: Jian Zhang, Yonggui Wu.

Methodology: Yonggui Wu.

Resources: Yonggui Wu, Jinhui Li.

Software: Jinhui Li.

Supervision: Jinhui Li.

Validation: Qing Yang.

Visualization: Qing Yang.

Writing – original draft: Liqiang Yin.

Writing – review & editing: Liqiang Yin, Qing Yang.

References

- Zhang YZ, Wang LF, Shen Y, et al. The effects of MRI signal intensity changes and clinical manifestations on prognosis after surgical intervention for cervical spondylotic myelopathy. *Orthop Surg* 2009;1:101–6.
- Ohshio I, Hatayama A, Kaneda K, et al. Correlation between histopathologic features and magnetic resonance images of spinal cord lesions. *Spine (Phila Pa 1976)* 1993;18:1140–9.
- Alafifi T, Kern R, Fehlings M. Clinical and MRI predictors of outcome after surgical intervention for cervical spondylotic myelopathy. *J Neuroimag* 2007;17:315–22.
- Mastronardi L, Elawaf A, Roperto R, et al. Prognostic relevance of the postoperative evolution of intramedullary spinal cord changes in signal intensity on magnetic resonance imaging after anterior decompression for cervical spondylotic myelopathy. *J Neurosurg Spine* 2007;7:615–22.
- Matsuyama Y, Kawakami N, Yanase M, et al. Cervical myelopathy due to OPLL: clinical evaluation by MRI and intraoperative spinal sonography. *J Spinal Disord Tech* 2004;17:401–4.
- Wang LF, Zhang YZ, Shen Y, et al. Using the T2-weighted magnetic resonance imaging signal intensity ratio and clinical manifestations to assess the prognosis of patients with cervical ossification of the posterior longitudinal ligament. *J Neurosurg Spine* 2010;13:319–23.
- Zhang YZ, Shen Y, Wang LF, et al. Magnetic resonance T2 image signal intensity ratio and clinical manifestation predict prognosis after surgical intervention for cervical spondylotic myelopathy. *Spine (Phila Pa 1976)* 2010;35:E396–9.
- Vedantam A, Jonathan A, Rajshekhar V. Association of magnetic resonance imaging signal changes and outcome prediction after surgery for cervical spondylotic myelopathy. *J Neurosurg Spine* 2011; 15:660–6.
- Mehalic TF, Pezzuti RT, Applebaum BI. Magnetic resonance imaging and cervical spondylotic myelopathy. *Neurosurg* 1990;26:217–26.
- Morishita Y, Hida S, Naito M, et al. Evaluation of cervical spondylotic myelopathy using somatosensory-evoked potentials. *Int Orthop* 2005; 29:343–6.

- [11] Chatley A, Kumar R, Jain VK, et al. Effect of spinal cord signal intensity changes on clinical outcome after surgery for cervical spondylotic myelopathy. *J Neurosurg Spine* 2009;11:562–7.
- [12] Takahashi M, Sakamoto Y, Miyawaki M, et al. Increased MR signal intensity secondary to chronic cervical cord compression. *Neurorad* 1987;29:550–6.
- [13] Mizuno J, Nakagawa HT, Hashizume Y. Clinicopathological study of “snake-eye appearance” in compressive myelopathy of the cervical spinal cord. *J Neurosurg Spine* 2003;99(2 suppl):162–8.
- [14] Itoh T. Cervical spondylotic myelopathy. Clinicopathological study on the progression pattern and thin myelinated fibers of the lesions of seven patients examined during complete autopsy. *Spine (Phila Pa 1976)* 1996;21:827–33.
- [15] Daimon K, Fujiwara H, Nishiwaki Y, et al. A 20-year prospective longitudinal study of degeneration of the cervical spine in a volunteer cohort assessed using MRI. *J Bone J Surg* 2018;100:843–9.