

# Cryoablation of an atrioventricular nodal reentrant tachycardia in a patient with an implanted deep brain stimulator



Melanie Gunawardene, MD, Christian Meyer (Professor, MD) Stephan Willems (Professor, MD)  
Boris Alexander Hoffmann, MD

*From the University Heart Center Hamburg, Hamburg, Germany.*

## Introduction

Atrioventricular nodal reentrant tachycardia (AVNRT) is the most frequent paroxysmal supraventricular tachycardia (SVT), with an incidence of 5 cases per 1000 people. Ablation utilizing a radiofrequency current (RFC) energy source is currently the standard treatment. Success rates range between 94% and 100% and complication rates are low, especially with respect to total atrioventricular (AV) block.<sup>1,2</sup>

Implantation of bilateral deep brain stimulators (DBS) is an established treatment for severe, pharmacotherapy-refractive Parkinson disease (PD).<sup>3,4</sup> Acceptance of this therapy has increased over the past fifteen years, leading to higher implantation rates; therefore, the incidence of patients with DBS has increased.<sup>3</sup>

So far, one case report, published by Kanagaratnam et al.,<sup>5</sup> demonstrated the performance of a safe and successful RFC ablation in a patient with DBS suffering from AVNRT without device or patient complications.

However, the use of an RFC energy source in patients treated with DBS can be dangerous. The electrodes and generators used are generally known to have several interactions, including those with radiofrequency (RF) energy.<sup>6</sup> Nutt et al.<sup>6</sup> reported a disastrous outcome of a patient with implanted DBS who was treated by a form of RF energy after an oral surgery, leading to severe brain injury.

Furthermore, DBS can cause significant artifacts in electrocardiographic recordings.<sup>7</sup> As a result, catheter ablation of cardiac arrhythmias in patients with PD and implanted stimulators can be challenging, specifically as RFC is the standard energy source used to create ablation lesions.

However, catheter ablation of SVT utilizing cryoenergy has become an alternative to RFC ablations.<sup>1,8</sup>

To our knowledge, no study has reported on performing catheter ablation with cryoenergy in patients undergoing DBS.

## Case report

A 66-year-old man suffering from PD treated with DBS was admitted to our outpatient clinic with palpitations from symptomatic SVT.

The patient had been suffering from PD for 5 years. Owing to progressing tremor and rigidity, a DBS was implanted in September 2013 (Activa PC; Medtronic Inc, Minneapolis, MN). While he was still undergoing treatment with levodopa, carbidopa, ropinirole, and entacapone, his neurologic symptoms had nearly disappeared and subjectively his quality of life had improved.

However, over the last five years he had also been suffering from intermittent paroxysmal tachycardia with a duration of 2–4 hours, typical “on-off” phenomenon, and palpitations. Termination of the tachycardia in the past had been achieved either with administration of adenosine or by vagal maneuvers. Medication with metoprolol had reduced the frequency of tachycardia; however, he still suffered from highly symptomatic episodes.

A typical electrophysiological (EP) study with the use of RF energy, however, did not seem feasible in a DBS patient. We consulted with our neurosurgery department and the DBS system engineers; they stated that interactions with the DBS system, leading to heat generation and possibly severe central nervous system damage, even in an off-state stimulator, could not be excluded.

We therefore performed an EP study using cryoenergy (Figure 1) (Arctic Frezor®MAX; Medtronic Inc, Minneapolis, MN). Before we commenced the EP study, the DBS device was first interrogated. The electrocardiogram (ECG) showed no artifacts with a stimulator frequency output of 125 Hz. Atrial and ventricular stimulations were performed according to standard protocols. During ventricular pacing a retrograde jump was detected (drive chain 370 ms, jump of 60 ms from S2 = 300 ms to S2 = 290 ms). The clinical

---

**KEYWORDS** Cryoablation; Supraventricular tachycardia; Atrioventricular nodal reentrant tachycardia; Deep brain stimulation; Ablation; Parkinson disease (Heart Rhythm Case Reports 2016;2:258–260)

---

**Address reprints and correspondence:** Dr Melanie Gunawardene, Department of Cardiology – Electrophysiology, University Heart Center Hamburg, Martinistrasse 52, 20251 Hamburg, Germany. E-mail address: m.gunawardene@uke.de.

## KEY TEACHING POINTS

- Cryoablation of atrioventricular nodal reentrant tachycardia by slow pathway modulation in patients with implanted deep brain stimulator (DBS) seems safe and feasible. It does not cause interactions with DBS systems.
- Tachyarrhythmias are frequent and increase in aging patients. Thus, the use of cryoenergy instead of radiofrequency current energy in patients with DBS represents a safe and reasonable alternative.
- In the future, cryoenergy is not only a possibility to treat atrioventricular nodal-dependent tachyarrhythmias, but could also be used to perform pulmonary vein isolation with the cryoballoon in DBS patients suffering from atrial fibrillation.

tachycardia started spontaneously and was confirmed to be a typical AVNRT (Figure 2).

After the required ablation criteria were determined, slow pathway modulation was performed over two cryoenergy freezes. The first freeze started with a so-called “mapping mode” at  $-30^{\circ}\text{C}$  to mark the ablation site without causing durable AV node damage in case of misplacement, as reported elsewhere.<sup>1</sup> Over the course of the first application a minimal temperature of  $-79^{\circ}\text{C}$  could be reached (Figure 3). After a short warm-up phase the second freeze was applied, reaching  $-80^{\circ}\text{C}$ . Post ablation, the tachycardia was no longer inducible and no retrograde jump was detected.

During the postprocedural in-patient stay at our clinic, no complication occurred. Pericardial effusion was excluded by echocardiography, there were no inguinal hematomas on either side, no neurologic symptoms occurred, and post-procedural interrogation of the DBS device showed no dysfunction of the system. The patient was discharged the next day in stable sinus rhythm. An 8-month follow-up of the patient showed no recurrence.

## Discussion

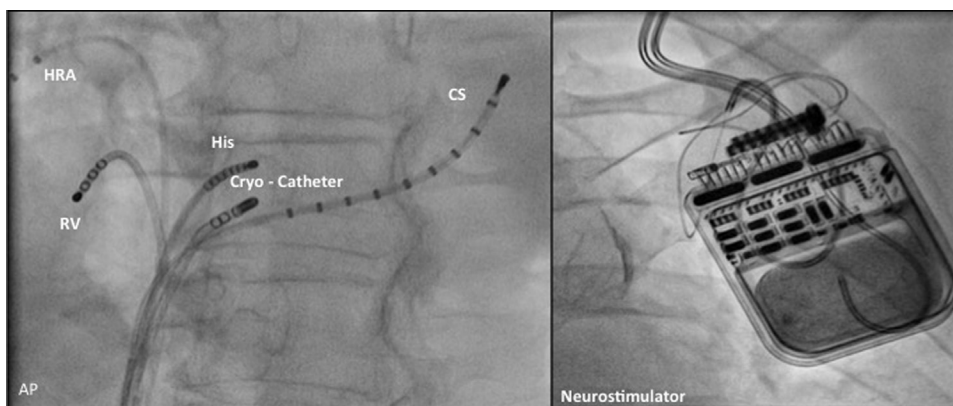
Implantation of DBS has become a common treatment for a variety of neurologic diseases.<sup>9</sup> Tachyarrhythmias are frequent and increase in aging patients; for example, the prevalence of atrial fibrillation increases 5%–15% at 80 years.<sup>10</sup> Thus, a safe alternate ablation treatment for patients with implanted devices needing catheter ablation of cardiac arrhythmias is required.

Severe central nervous system damage around the DBS electrodes was reported in a patient after undergoing a form of RF energy treatment to hasten recovery (pulse-modulated RF diathermy) after oral surgery.<sup>6</sup> In this specific case the patient could not be aroused at the end of the RF energy treatment. He had small pupils and had no response to pain. A magnetic resonance imaging scan 3 days after the RF energy treatment showed a severe, bilateral brain injury. One month after his RF energy treatment the patient still could not vocalize and needed percutaneous endoscopic gastrostomy.<sup>6</sup>

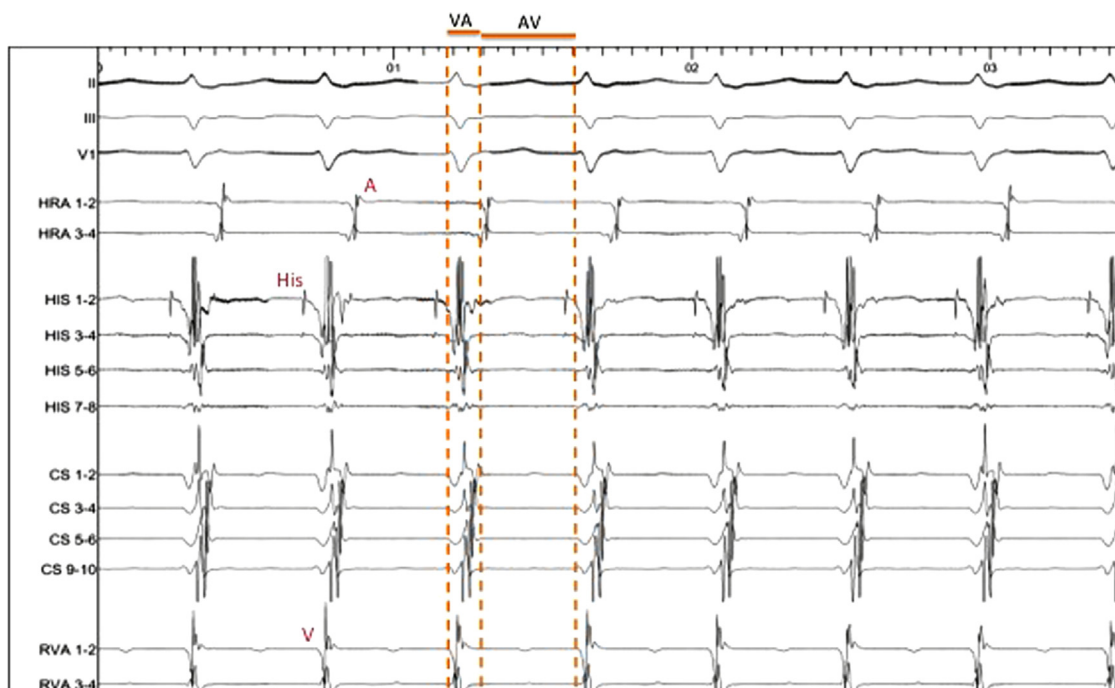However, Kanagaratnam et al<sup>5</sup> performed a successful and uncomplicated RFC energy ablation in a patient with DBS. They were able to reduce ECG artifacts by programming the DBS from a unipolar to a bipolar mode, as well as by reducing the system’s frequency output.<sup>5</sup>

In our patient no ECG artifacts appeared and adjustments to the program settings were not necessary. Furthermore, Kanagaratnam et al<sup>5</sup> report that RFC energy application did not interact with the DBS and no central nervous system damage occurred. However, this is the only case reported, and it does not solve the underlying problem of technically possible interactions. Further, the use of RFC catheters for ablation of cardiac arrhythmias is not advised by the DBS manufacturer.

Cryoenergy is generated by refrigerant  $\text{N}_2\text{O}$  undergoing a liquid-to-gas phase change. This change results in cooling down to approximately  $-80^{\circ}\text{C}$ . In general, the use of cryoenergy for slow pathway modulation shows similar acute success rates compared to RFC as the underlying energy source (94%–97% vs 94%–100%). The general complication rate, especially with respect to total AV block, is low.<sup>1,2,11</sup> Cryoablation, however, is limited by a slightly lower long-term clinical efficacy when compared to RFC ablation (2%–19.8% cryoablation vs 1%–9% RFC



**Figure 1** Fluoroscopic view of the ablation setting. **Left:** Positioning the cryocatheter at the location of the slow pathway in the Koch triangle with the different diagnostic catheters positioned at the high right atrium (HRA), right ventricle (RV), His bundle (His), and coronary sinus (CS). **Right:** Neurostimulator implanted in the left upper chest.



**Figure 2** Intracardiac electrogram showing the patient’s clinical tachycardia as a typical slow–fast atrioventricular nodal reentrant tachycardia (133 beats/min, cycle length 450 ms). A = atrial signal; H = signal of the His bundle; V = ventricular signal.

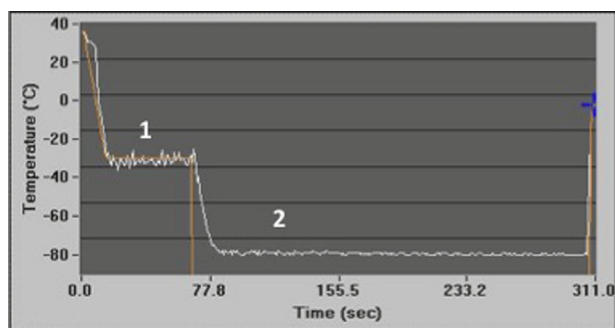
recurrence rates).<sup>1</sup> Overall, the use of cryoenergy instead of RFC in patients with DBS represents a safe and reasonable alternative. In the future, cryoenergy is not only a possibility to treat AV nodal–dependent tachyarrhythmias, but it could also be used to perform pulmonary vein isolation with the cryoballoon in DBS patients suffering from atrial fibrillation.

**Conclusion**

Cryoablation of AVNRT by slow pathway modulation in patients with implanted DBS seems safe and feasible, and does not cause interactions with DBS systems.

**References**

1. De Sisti A, Tonet J. Cryoablation of atrioventricular nodal reentrant tachycardia: a clinical review. *Pacing Clin Electrophysiol* 2012;35(2):233–240.
2. Hoffmann B, Brachmann J, Andresen D, et al. Ablation of atrioventricular nodal reentrant tachycardia in the elderly: results from the German Ablation Registry. *Heart Rhythm* 2011;8(7):981–987.
3. Weaver FM, Follett K, Stern M, et al. Bilateral deep brain stimulation vs best medical therapy for patients with advanced Parkinson disease. *JAMA* 2009;301(1):63–73.
4. Deuschl G, Schade-Brittinger C, Krack P, et al. A randomized trial of deep-brain stimulation for Parkinson’s disease. *N Engl J Med* 2006;355:896–908.
5. Kanagaratnam L, Lee A, Whalley D, Figtree G. Overcoming artifacts and fears: electrophysiology study and radiofrequency ablation in a Parkinsonian patient with supraventricular tachycardia and a brain neurostimulator. *Pacing Clin Electrophysiol* 2013;36(1):e1–e3.
6. Nutt JG, Anderson VC, Peacock JH, Hammerstad JP, Burchiel KJ. DBS and diathermy interaction induces severe CNS damage. *Neurology* 2001;56:1384–1386.
7. Constantoyannis C, Heilbron B, Honey C. Electrocardiogram artifacts caused by deep brain stimulation. *Can J Neurol Sci* 2004;31(3):343–346.
8. Santangeli Proietti R, Di Biase L, Bai R, Natale A. Cryoablation versus radiofrequency ablation of atrioventricular nodal reentrant tachycardia. *J Interv Card Electrophysiol* 2014;39(2):111–119.
9. Nuttin B, Wu H, Mayberg H, et al. Consensus on guidelines for stereotactic neurosurgery for psychiatric disorders. *J Neurol Neurosurg Psychiatry* 2014;85:1003–1008.
10. Camm AJ, Kirchhof P, Lip GYH, et al. Guidelines for the management of atrial fibrillation: the Task Force for the Management of Atrial Fibrillation of the European Society of Cardiology (ESC). *Eur Heart J* 2010;31(19):2369–2429.
11. Steven D, Rostock T, Hoffmann BA, Servatius H, Drewitz I, Müllerleile K, Klemm H, Melchert C, Wegscheider K, Meinertz T, Willems S. Favorable outcome using an abbreviated procedure for catheter ablation of AVNRT: results from a prospective randomized trial. *J Cardiovasc Electrophysiol* 2009;20(5):522–525.



**Figure 3** Temperature curve of the first cryoablation application showing the mapping mode at –30°C (1) and the actual ablation with a minimum temperature of –79°C (2).