

## Teaching Case

# Lymphangioliomyomatosis: A new relative contraindication for breast conservation therapy

Matthew L. Mallory MD, Melissa P. Mitchell MD, PhD \*

*Department of Radiation Oncology at The Kansas University Medical Center, Kansas City, Kansas*

Received 2 June 2017; received in revised form 29 September 2017; accepted 3 October 2017

## Introduction

Evidence is overwhelming that breast conservation, which consists of lumpectomy and radiation, is equivalent to mastectomy for patients with early stage breast cancer. These 2 local therapy options are presented to patients with early stage breast cancer, and decisions are a personal choice after weighing the risks and benefits of both approaches. However, for some patients, breast conservation is not an option due to contraindications for radiation.

Radiation oncology residents are taught to quickly cite the standard contraindications for breast conservation, including Li-Fraumeni syndrome and scleroderma, which are both rare syndromes. The U.S. registry of Li-Fraumeni patients includes only 400 patients, and the prevalence of scleroderma has been estimated at 276 cases per million population. Radiation for Li-Fraumeni syndrome is discouraged due to the high risk of secondary cancers in this population.<sup>1</sup> Radiation in the setting of scleroderma can cause exaggerated fibrosis that extends to underlying viscera outside of the radiation portal with risk of treatment-related mortality, although reports vary with regard to the degree of radiation toxicity.<sup>2-4</sup>

Another rare syndrome that nearly exclusively affects women is lymphangioliomyomatosis (LAM), with a prevalence of approximately 9 patients per million population. This rare multisystem disease can affect the lungs and cause lung cysts and spontaneous pneumothorax.<sup>5</sup> We performed a thorough literature search and were not able to identify any studies or reports on the use of breast conser-

vation treatment in a patient with LAM; thus, we herein present the first case report on this topic.

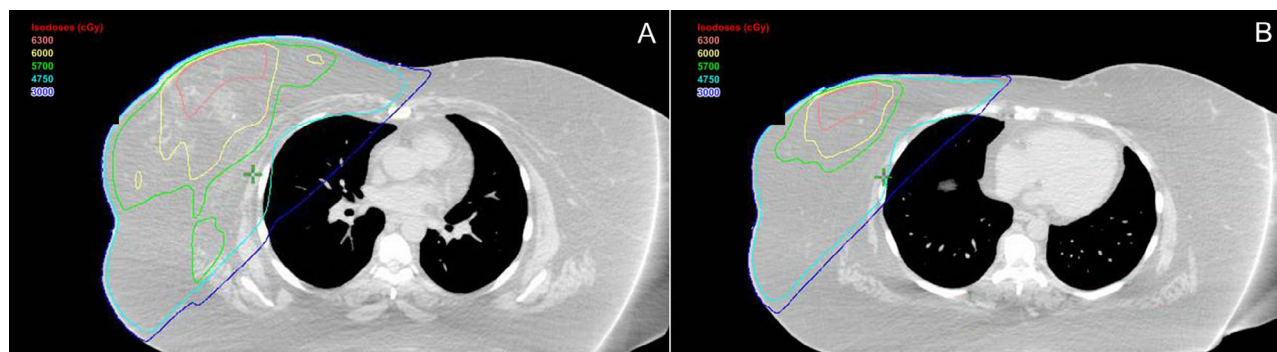
## Case report

A 49-year-old female patient with multiple medical comorbidities was treated with radiation at our clinic as part of breast conservation therapy. She was initially diagnosed after a screening mammogram identified a 2 cm spiculated mass in the lower inner quadrant of the right breast, which was biopsied and found to be histologic grade 2, invasive ductal carcinoma, ER 100%, PR 4%, her-2/neu 1+, Ki-67 14%. The patient then underwent lumpectomy and axillary lymph node dissection at our institution. With a 1.9 cm primary and 8 of 24 positive lymph nodes, her disease was pathologically staged as T1cN2, stage IIIA. A pathologic review also showed lymphovascular space invasion and extracapsular extension. Margins were widely negative.

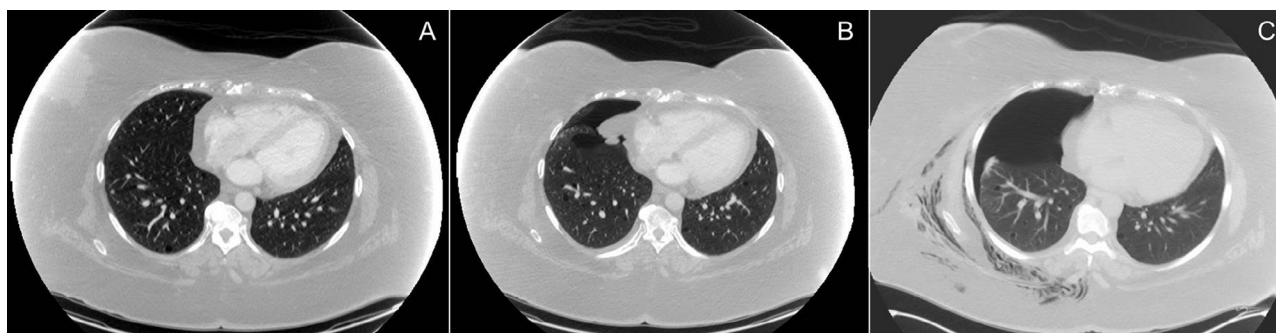Breast medical oncology deemed this patient a poor candidate for chemotherapy due to multiple comorbidities including Factor V Leiden, a history of pulmonary embolism and deep venous thrombosis, poorly controlled diabetes, and chronic thrombocytopenia. Given her medical history and moderate Oncotype score of 19, anastrozole was recommended instead of chemotherapy. The patient had definite indications for comprehensive radiation to the breast and undissected draining lymphatics in the setting of breast conservation therapy and 8 positive nodes.<sup>6,7</sup> Thus, she received radiation to the right whole breast and undissected lymphatics, including the right supraclavicular fossa and internal mammary nodes, to a dose of 50 Gy in 25 fractions with 3-dimensional conformal fields, including partially wide tangents. Representative axial slices from the treatment with corresponding isodose lines are shown in [Figure 1](#).

\* Corresponding author. Division of Radiation Oncology, Kansas University Medical Center, 3901 Rainbow Blvd., Mailstop 4033, Kansas City, KS 66160.

E-mail address: [mmitchell2@kumc.edu](mailto:mmitchell2@kumc.edu) (M.P. Mitchell).



**Figure 1** Representative axial slices from the partially wide tangent treatment showing A) increased coverage of the lungs in the tangent in the region of the internal mammary nodes and B) the inferior portion of the tangent field with less coverage of the normal lung tissue.



**Figure 2** Serial computed tomography imaging of the thorax. A) Image at 1 month postlumpectomy shows seroma in the lumpectomy bed and several small lung cysts, without evidence of pneumothorax. B) Four months postradiation, there is spontaneous pneumothorax in the region of the tangent radiation, and persistent lung cysts can be observed bilaterally. C) Eight months postradiation, there is repeat pneumothorax, partially loculated and subcutaneous emphysema is noted as well. Lung cysts persist bilaterally.

After comprehensive radiation to the breast and nodes, the lumpectomy bed was treated with an additional 10 Gy boost. A lung dose-volume histogram for the composite plan was reviewed, with ipsilateral V20 of 35% and total lung V20 of 20%. Ipsilateral V5 was 62%, and ipsilateral V10 was 45%. The maximum lung dose was 51 Gy. These lung doses are within our institutional constraints and meet variation acceptable criteria of current national protocols on comprehensive radiation.<sup>8,9</sup> Priority was placed on adequate target coverage in the setting of aggressive disease and inability to undergo chemotherapy. The patient tolerated treatment well without unexpected acute toxicity.

Four months after the end of radiation treatment, the patient had a routine follow-up computed tomography (CT) scan of the chest, abdomen, and pelvis, which revealed a spontaneous pneumothorax in the region of the prior radiation (Fig 2). She was asymptomatic but was admitted briefly for observation, and the pneumothorax resolved without intervention. On review of the patient's pretreatment CT scan as well as earlier scans, scattered thin-walled cysts compatible with LAM were noted.

Approximately 1 month later, the patient presented to the emergency department with dyspnea and was found to have a recurrent pneumothorax that did not improve with

chest tube placement. She was admitted and underwent right-sided pleurodesis and apical pleurectomy and intraoperatively was noted to have moderate-to-severe LAM. Three months later, the patient was readmitted for recurrent pneumothorax and required 2 repeat pleurodeses. She was ultimately started on sirolimus for management of her lung disease and continues to follow up with the pulmonary department as well as our clinic.

## Discussion and conclusion

LAM is a relatively rare chronic disease that affects women almost exclusively. LAM is often associated with tuberous sclerosis complex (TSC) but can also arise spontaneously. The average age at diagnosis is mid-30s, and LAM is often diagnosed after spontaneous pneumothorax. Inactivation of the TSC1 or TSC2 genes leads to disruption of mTOR signaling and affects the pathways responsible for cell proliferation, survival, and motility. The resultant smooth muscle-like cells (LAM cells) tend to behave in a neoplastic fashion and metastasize to the lungs, where they cluster along lymphatics and form thin-walled cysts. Eventually, the lungs become expanded, with

multiple large cysts throughout. mTOR inhibitors such as sirolimus are the mainstay of treatment, with lung transplant reserved as a final option.<sup>3</sup>

Our patient was evaluated by CT surgery, which believed that she was predisposed to pneumothorax due to significant cystic disease on the surface of the lung, as observed during a diagnostic video-assisted thoracoscopic surgery procedure. Given the development of the recurrent spontaneous pneumothoraces in the region of the treatment field within 3 to 6 months after completion of whole breast radiation therapy, it is theorized that radiation may have weakened the wall of the existing cysts and led to rupture.

Pneumothorax occurs at some point in approximately 70% of women with LAM and is usually recurrent, so our patient may have experienced pneumothorax even without radiation treatment. However, recurrent pneumothoraces represent significant morbidity for patients with LAM and the potential of triggering an initial pneumothorax with radiation is an important consideration.

To our knowledge, this case report represents the first description of pneumothorax after breast radiation in a patient with LAM. Based on our experience, we believe it would be reasonable to discuss pneumothorax as a potential complication in patients with a known diagnosis of LAM. This relative contraindication could be incorporated into the decision making for patients contemplating breast conservation or for patients with a node-positive N1 mastectomy who may receive less benefit from radiation. For patients who do opt for radiation as a component of their care, every effort should be made to minimize lung exposure when designing the radiation fields. Further-

more, physicians should consider the possibility of LAM in a woman who presents with a spontaneous pneumothorax after breast or thoracic radiation.

## References

1. Hisada M, Garber JE, Fung CY, Fraumeni JF Jr, Li FP. Multiple primary cancers in families with Li-Fraumeni syndrome. *J Natl Cancer Inst.* 1998;90:606-611.
2. Varga J, Hausteil UF, Creech RH, Dwyer JP, Jimenez SA. Exaggerated radiation-induced fibrosis in patients with systemic sclerosis. *JAMA.* 1991;265:3292-3295.
3. Chen A, Obedian E, Haffty BG. Breast-conserving therapy in the setting of collagen vascular disease. *Cancer J.* 2001;7:480-491.
4. Gold D, Miller R, Petersen I, Osborn T. Radiotherapy for malignancy in patients with scleroderma: The Mayo Clinic experience. *Int J Radiat Oncol Biol Phys.* 2007;67:559-567.
5. Johnson SR, Taveira-DaSilva AM, Moss J. Lymphangiomyomatosis. *Clin Chest Med.* 2016;37:389-403.
6. Fisher B, Anderson S, Bryant J, et al. Twenty-year follow-up of a randomized trial comparing total mastectomy, lumpectomy and lumpectomy plus irradiation for the treatment of invasive breast cancer. *N Engl J Med.* 2002;347:1233-1241.
7. Taylor ME, Haffty BG, Rabinovitch R, et al. ACR appropriateness criteria on postmastectomy radiotherapy expert panel on radiation oncology-breast. *Int J Radiat Oncol Biol Phys.* 2009;73:997-1002.
8. National Cancer Institute. Standard or comprehensive radiation therapy in treating patients with early-stage breast cancer previously treated with chemotherapy and surgery. Available at: <http://www.cancer.gov/clinicaltrials/search/view?cdrid=750327&version=HealthProfessional>. Accessed September 16, 2017.
9. National Cancer Institute. Comparison of axillary lymph node dissection with axillary radiation for patients with node-positive breast cancer treated with chemotherapy. Available at: <http://www.cancer.gov/clinicaltrials/search/view?cdrid=751211&version=HealthProfessional>. Accessed September 16, 2017.