

Prevention, treatment, and rehabilitation of anterior cruciate ligament injuries in children

Pamela J Lang^{1,2}

Dai Sugimoto¹⁻³

Lyle J Micheli¹⁻³

¹Division of Sports Medicine, Department of Orthopedics, Boston Children's Hospital, ²Department of Orthopaedic Surgery, Harvard Medical School, Boston, MA, ³The Micheli Center for Sports Injury Prevention, Waltham, MA, USA

Abstract: As more children and adolescents participate in competitive organized sports, there has been an increase in the reported incidence of anterior cruciate ligament (ACL) injuries in these age groups. ACL injuries in skeletally immature athletes present a challenge, as reconstruction must preserve the physis of the distal femur and of the proximal tibia to avoid growth disturbances. Historically, a skeletally immature athlete with an ACL injury was treated with a brace and activity modification until skeletal maturity, with ACL reconstruction being performed at that time in the “non-copers” who experienced instability. More recently, evidence has shown that delayed reconstruction may lead to increased damage to the meniscus and articular cartilage. As a result, early reconstruction is favored to protect the meniscus and allow continued physical activity. While adolescents at or those near skeletal maturity may be treated with standard reconstruction techniques, they may result in growth disturbances in younger athletes with significant growth remaining. In response to the growing need for ACL reconstruction techniques in skeletally immature individuals, physal-sparing and physal-respecting reconstruction techniques have been developed. In addition to the advancements in surgical technique, ACL injury prevention has also gained attention. This growing interest in ACL prevention is in part related to the high risk of ACL re-tear, either of the ACL graft or of the contralateral ACL, in children and adolescents. Recent reports indicate that well-designed neuromuscular training programs may reduce the risk of primary and subsequent ACL injuries.

Keywords: skeletally immature, neuromuscular training, surgical techniques, physal-sparing

Introduction

Historically, tibial eminence fractures were considered to be the child's version of an anterior cruciate ligament (ACL) rupture. Recently, this notion has been challenged as the number of intrasubstance ACL injuries diagnosed in young patients has increased dramatically. In a study of young athletes presenting with knee hemarthrosis after an acute injury, 47% of pre-adolescents and 65% of adolescents were ultimately found to have an ACL rupture.¹ Over the past 20 years, the number of ACL injuries among children and adolescents aged 6–18 years has increased by 2.3% per year, with the peak incidence during high school.²

In comparison to the management of a tibial eminence avulsion, treatment of an ACL rupture in skeletally immature patients presents a unique challenge. While non-operative treatment may be successful for some patients with partial ACL injuries,³ it has been associated with persistent instability and subsequent meniscus and chondral

Correspondence: Lyle J Micheli
Division of Sports Medicine, Department of Orthopedics, Boston Children's Hospital, 319 Longwood Avenue, Boston, MA 02115, USA
Tel +1 617 355 6970
Fax +1 617 730 0178
Email Lyle.Micheli@childrens.harvard.edu

injuries in complete ACL rupture.⁴⁻⁹ For this reason, surgical techniques in pediatric and adolescent ACL reconstruction have gained popularity and the number of skeletally immature patients undergoing ACL reconstruction has increased. Between 1994 and 2006, the number of ACL reconstructions performed in patients younger than 15 years increased by 924%.¹⁰

Common mechanisms of injury

Injuries to the ACL can be classified as occurring by their mechanisms of occurrence: direct contact, indirect contact, or noncontact. In a direct contact ACL injury, an external force is applied to the knee, resulting in injury.^{11,12} Contact is more likely to come from other players rather than balls, sticks, or stable objects.¹³⁻¹⁵ Indirect contact ACL injuries occur when an external force applied to a body part other than the knee results in ACL injury.^{11,12} For instance, external force applied to the trunk or lateral thigh during cutting or pivoting can cause an athlete to land with decreased hip and knee flexion.^{11,12,16} This resultant stiff landing can result in ACL injury.^{11,12,16} Similarly, a force applied to the anterior thigh can cause the knee to hyperextend, leading to anterior tibial translation and excessive rotation, which may translate to greater strain on the ACL and result in an ACL tear.¹⁷

The third mechanism of ACL injury is noncontact in nature. Noncontact mechanisms are responsible for 60–70% of ACL injuries.^{11,18-21} In a study of ACL injuries in skeletally immature patients, 71% of the cases with known mechanism of injury were noncontact injuries.²² Sex differences in noncontact ACL injury have consistently been found.^{18,19,23-27} In a study of collegiate athletes, female soccer and basketball players had a 2.7 times higher incidence of ACL injury compared to that in their male counterparts.¹⁹ Overall, the prevalence of noncontact ACL injuries in female athletes is ~10–20% higher than that in male athletes.^{18,19,23,24} The risk of ACL injury in female athletes seems to increase significantly during the mid teenage years.²⁵ A recent epidemiologic study found a significantly higher incidence of ACL injuries among girls 6–16 years of age than boys of the same age.²

Based on the available evidence, noncontact ACL rupture is a resultant product of biomechanical and neuromuscular events during dynamic movements. The development of neuromuscular control and movement patterns among children is not well understood.^{28,29} Padua et al³⁰ measured preseason baseline neuromuscular control using the Landing Error Scoring System (LESS) in a group of elite youth soccer players. Higher scores on the LESS correlated with ACL injury during the season.³⁰

Given the high incidence of noncontact ACL injury among female athletes, they are the subject of much of the existing literature about neuromuscular control and biomechanical factors contributing to ACL injury. Using a prospective cohort study design, Hewett et al³¹ discovered biomechanical differences between female high school athletes who sustained ACL injuries and those who did not. The observed biomechanical risk factors in the ACL-injured female athletes included elevated knee valgus angles, decreased knee flexion angles, excessive ground reaction force, and asymmetric landing during execution of a drop vertical jump task.³¹ Prepubescent girls do not seem to show these landing mechanics.³² It appears that with increasing maturity, the landing patterns between males and females change, with adolescent females showing increasing knee valgus angles during a jump-landing task.²⁶⁻²⁸

In addition to landing mechanics associated with noncontact ACL injuries, recent studies report the influence of neuromuscular control and trunk and hip strength on ACL injury.^{16,33,34} A three-year prospective study reported that future ACL injuries were predicted with 91% accuracy in female athletes using trunk displacements, proprioception, and a history of low back pain as indicators of future ACL injury.³³ However, the same model for predicting ACL injury was not applicable to male athletes.³³ Similarly, a video analysis study of both National Basketball Association (NBA) and Women's National Basketball Association (WNBA) players reported that lateral trunk flexion and knee abduction (valgus) angles were significantly greater in female basketball players who sustained ACL injuries compared to male players and female players who did not injure their ACLs.¹⁶ Furthermore, hip external rotator and hip abductor weakness have also been reported to be significant neuromuscular risk factors for future noncontact ACL injury for both males and females.³⁴

Although little is known about the development of neuromuscular control in children, Hutchinson et al³² showed that pre-adolescent children perform worse on balance skills than college-aged individuals. In their study, children were found to develop balance and jump landing skills similar to young adults by 12–13 years of age, with girls maturing earlier than boys.³²

Risk factors for noncontact ACL injuries are summarized in Box 1.

Prevention of ACL injury

Younger age and higher level activity have been shown to be strong risk factors for ACL graft tear and contralateral ACL tear following ACL reconstruction.³⁵ Furthermore, a recent review suggests that the risk of contralateral ACL tear seems

Box I Risk factors for noncontact ACL injury**Risk factors for ACL injury**Genetics (*COL1A1*, *COL5A1*, *COL12A1*)³⁷Female gender³⁷Variation in female sex hormone concentration³⁷Increased knee joint laxity³⁸Decreased intercondylar notch width^{22,73–79}Increased posterior tibial slope^{38,75,80,81}Neurocognitive factors (slower reaction time and processing speed)^{37,82}Decreased hamstring to quadriceps ratio^{70,71,83}Neuromuscular factors^{16,33,38}Prior ACL injury^{37,84}Extrinsic factors (playing surface, footwear, etc.)³⁷**Abbreviation:** ACL, anterior cruciate ligament.

to exceed the risk of ACL graft tear.³⁶ Thus, prevention of ACL injury in young athletes is gaining attention.

Previously studied risk factors for ACL injury include extrinsic factors (playing surface and conditions, footwear),³⁷ genetic factors (familial predisposition, collagen polymorphisms),³⁷ anatomic factors (narrow notch width, increased tibial slope),³⁸ hormonal factors,³⁷ and biomechanical/neuromuscular factors (jump-landing mechanics, trunk displacements).³⁸ Prevention of ACL injuries starts with identifying the modifiable risk factors for injury in the individual athlete. As such, biomechanical and neuromuscular risk factors associated with ACL injury have become key targets for ACL prevention programs. The modifiable risk factors for ACL injury in younger children are not well understood, and therefore, existing literature has focused primarily on ACL prevention in adolescent and adult patients.²⁹

Key components of ACL injury preventative neuromuscular training

There are four key factors to consider when developing an ACL prevention program: age at which to institute the intervention, dosage to be prescribed, exercises to be included, and feedback to be given to the athlete.³⁹ Evidence has shown that younger athletes respond better to neuromuscular training (NMT) than older athletes.⁴⁰ In a study by Myer et al,⁴⁰ fewer ACL injuries were documented in younger athletes who performed NMT compared to older athletes. When NMT was instituted in a group of female athletes, risk reduction was found to be 72% in those 14–18 years of age and 52% in those 19–20 years of age.⁴⁰

The duration and frequency of NMT seem to be important factors to the effectiveness of ACL prevention, although the optimal volume of NMT is unknown. In a study conducted by Sugimoto et al,⁴¹ NMT was categorized as low volume (up to 15 minutes per week), moderate volume (15–30 minutes per week), and high volume (>30 minutes per week). An inverse,

dose–response relationship between NMT and ACL injury was found. Those who spent the most time doing NMT each week had the fewest ACL injuries. No universal guidelines exist for the duration and frequency of NMT, but based on their findings, Sugimoto et al⁴¹ recommend 20 minutes of NMT several times per week during both preseason and while in season to prevent ACL injury.

There is no consensus on the exercises that should be incorporated into an ACL prevention program, but it appears that multimodal approaches may be the most effective. Utilizing multiple exercise modes, a 68% ACL risk reduction has been shown,⁴² in contrast to no reduction in ACL risk when just a single exercise mode was included.^{43,44} Not only do the exercise modes have an influence on the effectiveness of an ACL prevention program, but feedback given during the course of the program also seems to have an effect. Feedback can include simple cues to improve knee alignment during NMT, such as “knee over the toe” and “don’t let knees cave inward”.^{16,25,45,46} Parsons and Alexander⁴⁷ investigated the effect of feedback on movement patterns in female volleyball players. The findings indicate improvement of lower limb biomechanics in response to both verbal and video cues, resulting in movement patterns that are protective against ACL injury.⁴⁷ Furthermore, females who received NMT with verbal feedback were able to decrease knee valgus angles significantly more than those who received NMT alone.⁴²

Effectiveness of NMT on prevention of ACL injury

NMT seems to be effective in the prevention of ACL injury.^{42,48,49} A recent meta-analysis found an average 56% ACL injury risk reduction in female athletes following injury prevention programs incorporating NMT, which was a significantly greater reduction than that in those who did not do NMT.⁴² Sugimoto et al³⁹ analyzed the combinatory effects of the four components of an ACL prevention program – age, dosage, exercise modes, and feedback – in a group of young female athletes. When an NMT program optimized just one of the four key components of a prevention program (younger age, high volume, multiple exercise modes, or feedback), a 17–18% ACL injury risk reduction was observed.³⁹ Moksnes and Grindem reviewed the existing literature on prevention of ACL injury in skeletally immature patients, and although they noted evidence for the effectiveness of prevention programs in girls as young as 12 years old, these findings have not yet been found in younger children.²⁹ Additionally, the ideal timing, frequency, and duration of such interventions in children and adolescents are unknown.

Treatment

The management of a complete ACL rupture in a skeletally immature patient presents a unique challenge. Nonoperative treatment has been associated with persistent instability and subsequent meniscus and chondral injuries in cases of complete ACL rupture in young patients.^{4-9,50} In order to prevent meniscal and chondral injuries that may accelerate degenerative changes in the knee, early reconstruction in cases of ACL injury in children and adolescents is recommended. Surgical techniques for ACL reconstruction in children and adolescents include physeal-sparing, physeal-respecting, and transphyseal ACL reconstruction.⁵¹⁻⁵⁵

Skeletal age is an important consideration when determining which technique to use for ACL reconstruction in young patients. Therefore, preoperative evaluation should include an assessment of bone age. A single anteroposterior (AP) radiograph of the left hand and wrist is performed preoperatively to allow assessment of bone age, most commonly by using the Greulich and Pyle atlas.⁵⁶ Tanner stage is also a consideration, although more challenging to assess in an orthopedic clinic. A treatment algorithm is presented in Figure 1.

There are two common physeal-sparing ACL reconstruction techniques: all-epiphyseal utilizing a soft tissue graft and combined extra-articular and intra-articular reconstruction utilizing the iliotibial band. The all-epiphyseal ACL reconstruction as described by Anderson utilizes the anatomic femoral

and tibial ACL attachments and therefore is considered anatomic reconstruction. All-epiphyseal femoral and tibial tunnels are drilled using fluoroscopic guidance to avoid injuring the physis. This technique can be technically demanding, given the need to drill parallel to the physis. Tibial tunnels may be short or shallow as a result of the need to stay within the epiphysis.⁵³

The extra-articular and intra-articular reconstructions as described by Micheli et al⁵¹ and Kocher et al⁵² utilize the iliotibial band. These are nonanatomic reconstructions that do not require drilling tunnels. The central portion of the iliotibial band is released proximally, leaving it attached at Gerdy's tubercle. The iliotibial band is passed posteriorly around the lateral femoral condyle and into the knee in the over the top position. The extra-articular reconstruction is completed as the graft is secured to periosteum of the lateral femoral condyle. The intra-articular reconstruction is completed as the graft is passed through the intercondylar notch and along the course of the ACL, passing under the intermeniscal ligament before exiting the knee. The graft is then secured to the periosteum of the anteromedial tibial metaphysis.

Both physeal-sparing techniques seem to be effective in restoring stability to the knee. Anderson⁵³ reported the results of 103 patients who underwent all-epiphyseal ACL reconstruction with hamstring autograft. The rate of ACL graft tear during the follow-up period was 10.7%. During the

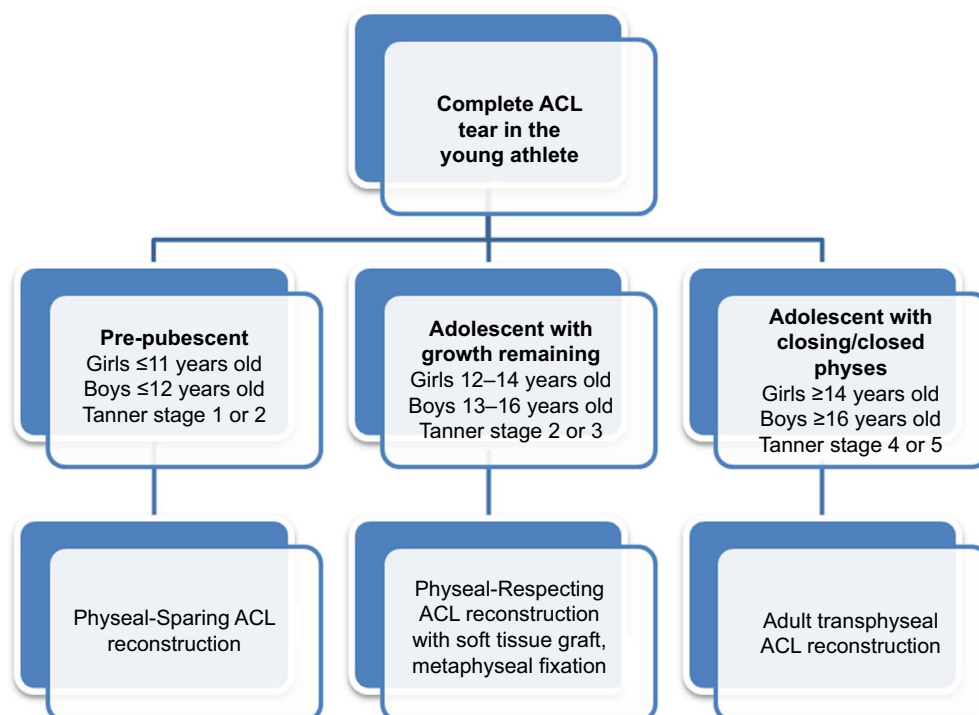


Figure 1 Algorithm for ACL reconstruction in young patients.
Abbreviation: ACL, anterior cruciate ligament.

same time period, 2.9% of patients sustained meniscus tears. Leg length discrepancy was reported in one patient, although it was <1 cm and therefore did not require any intervention.⁵³ The graft tear rate was 10.7%.⁵³ During the follow-up period, 2.9% of patients sustained subsequent meniscus tears.⁵³ Micheli et al⁵¹ and Kocher et al⁵² reported their results with the physeal-sparing extra-articular and intra-articular ACL reconstructions utilizing iliotibial band autograft. The rate of ACL graft failure was 4.5%, and no growth disturbances were reported.^{51,52} Willimon et al⁵⁷ described similar low graft failure rates with no growth disturbances, adding that patients were successful at return to sports after iliotibial band ACL

reconstruction. Despite being a nonanatomic reconstruction, biomechanical studies have shown that it best replicates the intact ACL.^{58,59} Given the safety and efficacy of the physeal-sparing ACL reconstruction using iliotibial band autograft, this technique is the authors' preferred technique for ACL reconstruction in skeletally immature children with significant growth remaining and is summarized in Figure 2A–H.

In physeal-respecting ACL reconstruction, soft tissue grafts are utilized. As shown in animal studies, premature closure of an injured area of the physis is less likely to occur if soft tissue is interposed at the site of injury.⁶⁰ Tibial and femoral tunnels can be drilled slightly more vertically to

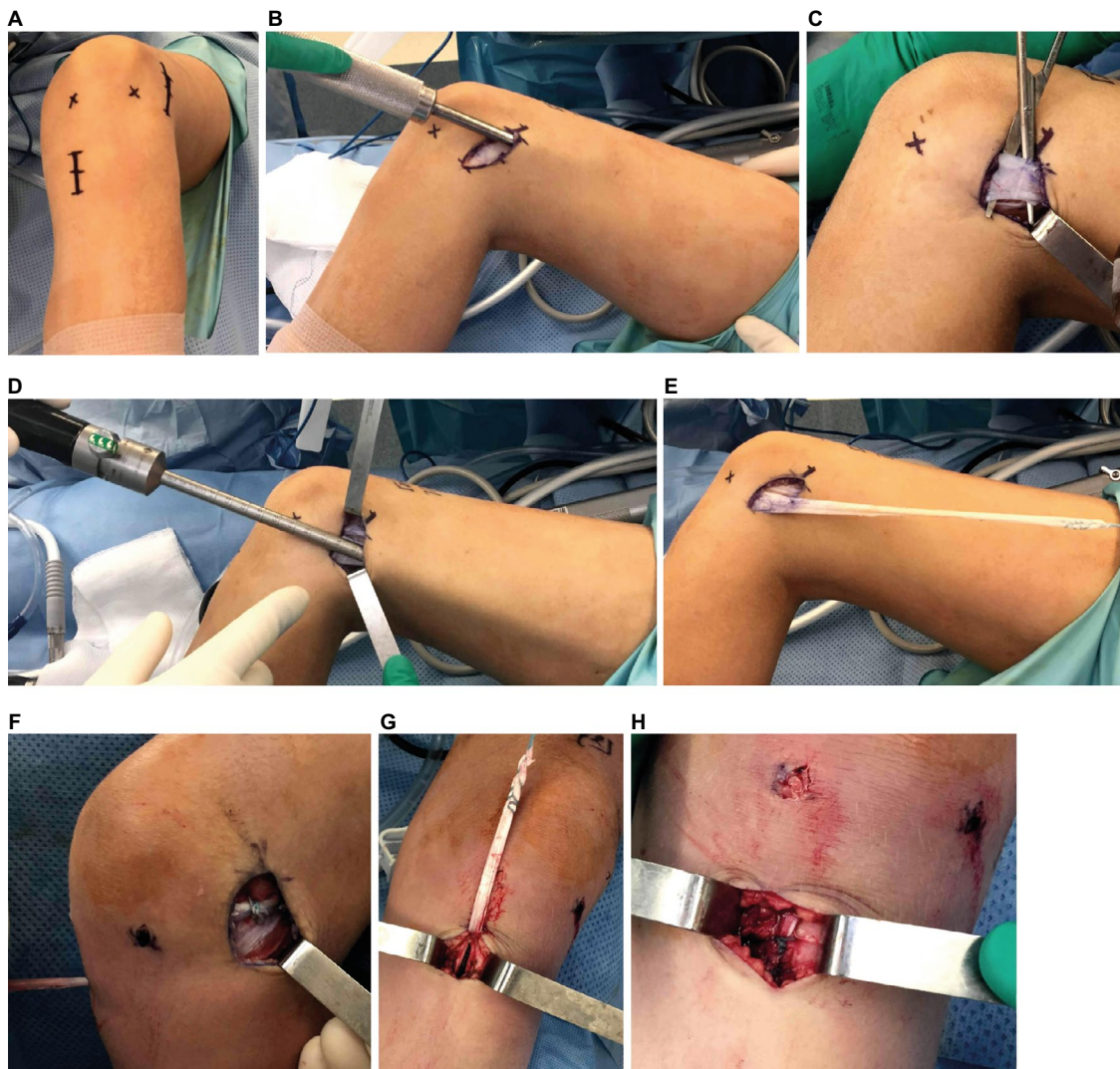

Figure 2 Physeal-sparing ACL reconstruction with iliotibial band autograft.

Notes: (A) Iliotibial band harvest is performed through a 3–4 cm incision from the lateral joint line to the anterior third of the iliotibial band. A second incision over the medial proximal tibia is utilized for graft fixation to the tibia. (B) A Cobb elevator is used to elevate subcutaneous fat from the iliotibial band. (C) The central 15–20 mm of iliotibial band is identified and elevated from the underlying vastus lateralis. (D) A meniscal knife or cutting tendon stripper is passed proximally to extend the anterior and posterior iliotibial band cuts and release the graft at the proximal end. (E) The free end of the graft is tubularized with a whipstitch. A graft of 150 mm is desirable. (F) The free end of the iliotibial band graft is passed around the back of the lateral femoral condyle in the “over the top” position. With the knee flexed to 90° and the leg in neutral rotation, tension is applied to the free end of the graft, while the graft is sewn to the lateral femoral periosteum. (G and H) The tibial periosteum is incised, and the graft is secured to the periosteum of the medial proximal tibia.

Abbreviation: ACL, anterior cruciate ligament.

produce a smaller area of physeal injury. It is recommended that <7% of the physis should be violated to prevent growth disturbance.¹⁰ Additionally, fixation of the graft is positioned in the metaphysis and away from the distal femoral and proximal tibial physes. Studies have shown good functional results and no growth disturbances using this physeal-respecting technique in adolescent patients with growth remaining.^{61,62} Despite this, the risk of graft tear in this group has been reported to be 11% with a 24% incidence of reoperation.^{61,63}

In contrast to the technique used in adolescents with growth remaining, the transphyseal technique used in skeletally mature and nearly mature adolescents can utilize either a soft tissue graft or a graft with bone plugs without concern for location of fixation. This transphyseal technique used in these older, more mature patients replicates that used for ACL reconstruction in adults.

The use of autograft versus allograft for ACL reconstruction in younger individuals has been investigated. The Multicenter Orthopaedic Outcomes Network (MOON) study showed that while individuals 10–19 years of age had the highest rate of graft failure, this rate was four times greater when allograft was used compared to autograft.⁶⁴ Therefore, autograft tissue should be considered the gold standard for ACL reconstruction in young athletes.

In summary, various techniques exist for ACL reconstruction in children and adolescents. The choice of technique to use should be individualized based on the patient's maturity and growth remaining. In a pre-pubescent patient with open physes and significant growth remaining, physeal-sparing ACL reconstruction is the most appropriate technique. For the pubescent patient with growth remaining, physeal-respecting ACL reconstruction is appropriate. In adolescent patients with minimal or no growth remaining, a transphyseal ACL reconstruction technique can be performed.

Rehabilitation

Following ACL reconstruction, adequate rehabilitation is considered vital in order for an athlete to regain adequate motion, strength, proprioception, and neuromuscular control to allow him or her to return to sports. As noted in a recent review, rehabilitation following ACL reconstruction in children is not well described.²⁹ Rehabilitation should be supervised, and functional milestones should be used to help guide therapy progression.²⁹ It is ideal to have a therapist with experience working with younger patients, as techniques to engage and motivate children are different from those used with adults. Fostering self-directed activity and compliance with activity restrictions can be a challenge in younger

patients. Additionally, different cues need to be given based on developmental stages of children and adolescents.⁶⁵

Early physical therapy should focus on regaining range of motion, patellar mobilization, and muscle activation. Full extension, isometric strengthening, and early weight bearing are encouraged in the first 1–2 weeks following surgery.^{66,67} Additionally, as they attain those early rehabilitative goals, closed chain strengthening exercises, balance, and neuromuscular retraining should be a subsequent focus of the rehabilitation. Jogging and plyometrics are generally allowed at 3 months postoperatively with sport-specific exercises beginning at 6 months postoperatively.

According to a recent report, 96% of young patients (≤ 14 years) return to sports at the same level following ACL reconstruction.⁶⁸ In a retrospective review of skeletally immature patients, the median time for return to sport was 9 months and 85% were able to return to sports at 1 year.⁶⁸ Criteria for determining readiness for return to play after ACL reconstruction are controversial and not well studied in pediatric patients. Recently, objective measures and criteria have been used to determine when an athlete is ready for return to sport. For example, Limb Symmetry Index (LSI) is used to determine the relative performance of the operative limb compared to the uninjured limb.⁶⁶ Though an LSI of >90% has been used to suggest safe return to sports, it has been recommended that an LSI of 100% be used for return to cutting and pivoting sports.⁶⁶ Although the LSI is typically used to compare the strength of the injured limb to uninjured limb, it is suggested that return to play decision-making should take into consideration a diverse battery of functional tests rather than strength alone. In addition to strength tests, balance tests, hop tests, and agility tests have been used to determine readiness to return to sports.⁶⁶ Additionally, when evaluating an athlete's strength, the ratio of hamstrings to quadriceps strength has been shown to be an important consideration for return to play decision-making.⁶⁹ A prospective study of National Collegiate Athletic Association (NCAA) Division III women's basketball and soccer players found that a hamstring to quadriceps ratio <0.6 was associated with noncontact leg injuries.^{70,71} Optimizing strength and movement patterns as well as the strength balance between the hamstring and the quadriceps may be important for preventing subsequent injury upon return to sport.

It remains controversial as to whether or not a functional brace should be used upon return to sport postoperatively. The risk of graft injury is significantly higher in young patients, with the greatest risk coming in those aged 10–19 years.⁶⁴ Up to 29.5% of young athletes sustain a second ACL injury within the first 2 years after returning to sports.¹⁰ A systematic

review of functional brace use for return to activity following ACL reconstruction found a lack of conclusive evidence for or against the use of functional bracing to prevent reinjury.⁷² The review did find that functional braces may improve an athlete's confidence upon return to sport and supported the use of functional bracing for the first 6–12 months following return to sport. Dai et al⁷³ evaluated the effect of functional bracing on knee kinetics at 6 months following ACL reconstruction and found that limb asymmetries between the operative and nonoperative limbs persisted despite functional bracing. Wright and Fetzer⁷⁴ studied the effect of an ACL brace following ACL reconstruction. In their series, which consisted of primarily adult patients, bracing had no significant impact on preventing injury.⁷⁴ However, because younger athletes also display greater risk-taking behavior, Wright and Fetzer⁷⁴ did recommend the use of postoperative ACL braces in children and adolescents.

Conclusion

ACL injuries are increasingly more common among children and adolescents. Given the high activity level of these patients and the high risk of meniscus and chondral injuries associated with ACL deficiency, early reconstruction is recommended to preserve the health of the knee. Techniques to spare and respect the physis have been developed and shown to be safe and effective. While rehabilitation following ACL reconstruction is important for effective and safe return to sport, early NMT and optimization of movement patterns may be effective in preventing ACL injuries among pediatric and adolescent athletes.

Disclosure

The authors report no conflicts of interest in this work.

References

1. Stanitski CL, Harvell JC, Fu F. Observations on acute knee hemarthrosis in children and adolescents. *J Pediatr Orthop*. 1993;13(4):506–510.
2. Beck NA, Lawrence JT, Nordin JD, DeFor TA, Tompkins M. ACL tears in school-aged children and adolescents over 20 years. *Pediatrics*. 2017;139(3):e20161877.
3. Kocher MS, Micheli LJ, Zurakowski D, Luke A. Partial tears of the anterior cruciate ligament in children and adolescents. *Am J Sports Med*. 2002;30(5):697–703.
4. Graf BK, Lange RH, Fujisaki CK, Landry GL, Saluja R. Anterior cruciate ligament tears in skeletally immature patients: meniscal pathology at presentation and after attempted conservative treatment. *Arthroscopy*. 1992;8(2):229–233.
5. McCarroll JR, Shelbourne KD, Patel D. Anterior cruciate ligament injuries in young athletes. Recommendations for treatment and rehabilitation. *Sports Med*. 1995;20(2):117–127.
6. Janarv PM, Nyström A, Werner S, Hirsch G. Anterior cruciate ligament injuries in skeletally immature patients. *J Pediatr Orthop*. 1996;16(5):673–677.
7. Pressman AE, Letts RM, Jarvis J. Anterior cruciate ligament tears in children: an analysis of operative versus nonoperative treatment. *J Pediatr Orthop*. 1997;17(4):505–511.
8. Aichroth PM, Patel DV, Zorrilla P. The natural history and treatment of rupture of the anterior cruciate ligament in children and adolescents. A prospective review. *J Bone Joint Surg Br*. 2002;84(1):38–41.
9. Finlayson CJ, Nasreddine A, Kocher MS. Current concepts of diagnosis and management of ACL injuries in skeletally immature athletes. *Phys Sportsmed*. 2010;38(2):90–101.
10. Dekker TJ, Rush JK, Schmitz MR. What's new in pediatric and adolescent anterior cruciate ligament injuries? *J Pediatr Orthop*. Epub 2016 Jun 2.
11. Boden BP, Dean GS, Feagin JA Jr, Garrett WJ. Mechanisms of anterior cruciate ligament injury. *Orthopedics*. 2000;23(6):573–578.
12. Hewett TE. An introduction to understanding and preventing ACL injury. In: Hewett TE, Schultz SJ, Griffin L, editors. *Understanding and Preventing Non-Contact ACL Injury*. Champaign, IL: Human Kinetics; 2007:xxi–xxviii.
13. Hootman JM, Dick R, Agel J. Epidemiology of collegiate injuries for 15 sports: summary and recommendations for injury prevention initiatives. *J Athl Train*. 2007;42(2):311–319.
14. Dick R, Putukian M, Agel J, Evans TA, Marshall S. Descriptive epidemiology of collegiate women's soccer injuries: National Collegiate Athletic Association Injury Surveillance System, 1988-1989 through 2002-2003. *J Athl Train*. 2007;42(2):278–285.
15. Agel J, Olson DE, Dick R, Arendt EA, Marshall SW, Sikka R. Descriptive epidemiology of collegiate women's basketball injuries: National Collegiate Athletic Association Injury Surveillance System, 1988-1989 through 2003-2004. *J Athl Train*. 2007;42(2):202–210.
16. Hewett TE, Torg JS, Boden B. Video analysis of trunk and knee motion during non-contact anterior cruciate ligament injury in female athletes: lateral trunk and knee abduction motion are combined components of the injury mechanism. *Br J Sports Med*. 2009;43(6):417–422.
17. Quatman CE, Kiapour A, Myer GD, et al. Cartilage pressure distributions provide a footprint to define female anterior cruciate ligament injury mechanisms. *Am J Sports Med*. 2011;39(8):1706–1713.
18. Arendt E, Dick R. Knee injury patterns among men and women in collegiate basketball and soccer. NCAA data and review of literature. *Am J Sports Med*. 1995;23(6):694–701.
19. Agel J, Arendt EA, Bershadsky B. Anterior cruciate ligament injury in national collegiate athletic association basketball and soccer: a 13-year review. *Am J Sports Med*. 2005;33(4):524–530.
20. Myklebust G, Maehlum S, Engebretsen L, Strand T, Solheim E. Registration of cruciate ligament injuries in Norwegian top level team handball. A prospective study covering two seasons. *Scand J Med Sci Sports*. 1997;7(5):289–292.
21. Waldén M, Häggglund M, Magnusson H, Ekstrand J. Anterior cruciate ligament injury in elite football: a prospective three-cohort study. *Knee Surg Sports Traumatol Arthrosc*. 2011;19(1):11–19.
22. Domzalski M, Grzelak P, Gabos P. Risk factors for anterior cruciate ligament injury in skeletally immature patients: analysis of intercondylar notch width using magnetic resonance imaging. *Int Orthop*. 2010;34(5):703–707.
23. Lindenfeld TN, Schmitt DJ, Hendy MP, Mangine RE, Noyes F. Incidence of injury in indoor soccer. *Am J Sports Med*. 1994;22(3):364–371.
24. Harmon KG, Ireland M. Gender differences in noncontact anterior cruciate ligament injuries. *Clin Sports Med*. 2000;19(2):287–302.
25. LaBella CR, Hennrikus W, Hewett TE, Council on Sports Medicine and Fitness, Section on Orthopaedics. Anterior cruciate ligament injuries: diagnosis, treatment, and prevention. *Pediatrics*. 2014;133(5):e1437–e1450.
26. Malinzak RA, Colby SM, Kirkendall DT, Yu B, Garrett W. A comparison of knee joint motion patterns between men and women in selected athletic tasks. *Clin Biomech*. 2001;16(5):438–445.
27. Griffin LY, Albohm MJ, Arendt EA, et al. Understanding and preventing noncontact anterior cruciate ligament injuries: a review of the Hunt Valley II meeting, January 2005. *Am J Sports Med*. 2006;34(9):1512–1532.

28. Holden S, Boreham C, Delahunt E. Sex differences in landing biomechanics and postural stability during adolescence: a systematic review with meta-analyses. *Sports Med.* 2016;46(2):241–253.
29. Moksnes H, Grindem H. Prevention and rehabilitation of paediatric anterior cruciate ligament injuries. *Knee Surg Sports Traumatol Arthrosc.* 2016;24(3):730–736.
30. Padua DA, DiStefano LJ, Beutler AI, De La Motte SJ, DiStefano MJ, Marshall SW. The landing error scoring system as a screening tool for an anterior cruciate ligament injury-prevention program in elite-youth soccer athletes. *J Athl Train.* 2015;50(6):589–595.
31. Hewett TE, Myer GD, Ford KR, et al. Biomechanical measures of neuromuscular control and valgus loading of the knee predict anterior cruciate ligament injury risk in female athletes: a prospective study. *Am J Sports Med.* 2005;33(4):492–501.
32. Hutchinson AB, Yao P, Hutchinson MR. Single-leg balance and core motor control in children: when does the risk for ACL injury occur? *BMJ Open Sports Exerc Med.* 2016;2(1):e000135.
33. Zazulak BT, Hewett TE, Reeves NP, Goldberg B, Cholewicki J. Deficits in neuromuscular control of the trunk predict knee injury risk: a prospective biomechanical-epidemiologic study. *Am J Sports Med.* 2007;35(7):1123–1130.
34. Khayambashi K, Ghodossi N, Straub RK, Powers CM. Hip muscle strength predicts noncontact anterior cruciate ligament injury in male and female athletes: a prospective study. *Am J Sports Med.* 2016;44(2):355–361.
35. Kaeding CC, Pedroza AD, Reinke EK, Huston LJ, MOON Consortium, Spindler KP. Risk factors and predictors of subsequent ACL injury in either knee after ACL reconstruction: prospective analysis of 2488 primary ACL reconstructions from the MOON cohort. *Am J Sports Med.* 2015;43(7):1583–1590.
36. Magnussen RA, Meschbach NT, Kaeding CC, Wright RW, Spindler K. ACL graft and contralateral ACL tear risk within ten years following reconstruction: a systematic review. *JBJS Rev.* 2015;3(1):00052.
37. Smith HC, Vacek P, Johnson RJ, et al. Risk factors for anterior cruciate ligament injury: a review of the literature – part 2: hormonal, genetic, cognitive function, previous injury, and extrinsic risk factors. *Sports Heal A Multidiscip Approach.* 2012;4(2):155–161.
38. Smith HC, Vacek P, Johnson RJ, et al. Risk factors for anterior cruciate ligament injury: a review of the literature – part 1: neuromuscular and anatomic risk. *Sports Health.* 2012;4(1):69–78.
39. Sugimoto D, Myer GD, Barber Foss KD, Pepin MJ, Micheli LJ, Hewett T. Critical components of neuromuscular training to reduce ACL injury risk in female athletes: meta-regression analysis. *Br J Sports Med.* 2016;50(20):1259–1266.
40. Myer GD, Sugimoto D, Thomas S, Hewett T. The influence of age on the effectiveness of neuromuscular training to reduce anterior cruciate ligament injury in female athletes: a meta-analysis. *Am J Sports Med.* 2013;41(1):203–215.
41. Sugimoto D, Myer GD, Foss KD, Hewett TE. Dosage effects of neuromuscular training intervention to reduce anterior cruciate ligament injuries in female athletes: meta- and sub-group analyses. *Sports Med.* 2014;44(4):551–562.
42. Sugimoto D, Myer GD, Foss KD, Hewett T. Specific exercise effects of preventive neuromuscular training intervention on anterior cruciate ligament injury risk reduction in young females: meta-analysis and subgroup analysis. *Br J Sports Med.* 2015;49(5):282–289.
43. Pfeiffer RP, Shea KG, Roberts D, Grandstrand S, Bond L. Lack of effect of a knee ligament injury prevention program on the incidence of noncontact anterior cruciate ligament injury. *J Bone Jt Surg Am.* 2006;88(8):1769–1774.
44. Söderman K, Werner S, Pietilä T, Engström B, Alfredson H. Balance board training: prevention of traumatic injuries of the lower extremities in female soccer players? A prospective randomized intervention study. *Knee Surg Sports Traumatol Arthrosc.* 2000;8(6):356–363.
45. Olsen OE, Myklebust G, Engebretsen L, Holme I, Bahr R. Exercises to prevent lower limb injuries in youth sports: cluster randomised controlled trial. *Br Med J.* 2005;330(7489):449.
46. Petersen W, Braun C, Bock W, et al. A controlled prospective case control study of a prevention training program in female team handball players: the German experience. *Arch Orthop Trauma Surg.* 2005;125(9):614–621.
47. Parsons JL, Alexander M. Modifying spike jump landing biomechanics in female adolescent volleyball athletes using video and verbal feedback. *J Strength Cond Res.* 2012;26(4):1076–1084.
48. Sadoghi P, von Keudell A, Vavken P. Effectiveness of anterior cruciate ligament injury prevention training programs. *J Bone Jt Surg Am.* 2012;94(9):769–776.
49. Gagnier JJ, Morgenstern H, Chess L. Interventions designed to prevent anterior cruciate ligament injuries in adolescents and adults: a systematic review and meta-analysis. *Am J Sports Med.* 2013;41(8):1952–1962.
50. Millett PJ, Willis AA, Warren R. Associated injuries in pediatric and adolescent anterior cruciate ligament tears: does a delay in treatment increase the risk of meniscal tear? *Arthroscopy.* 2002;18(9):955–959.
51. Micheli LJ, Rask B, Gerberg L. Anterior cruciate ligament reconstruction in patients who are prepubescent. *Clin Orthop Relat Res.* 1999; (364):40–47.
52. Kocher MS, Garg S, Micheli L. Physseal sparing reconstruction of the anterior cruciate ligament in skeletally immature prepubescent children and adolescents. *J Bone Jt Surg Am.* 2005;87(11):2371–2379.
53. Anderson AF. Transepiphyseal replacement of the anterior cruciate ligament in skeletally immature patients: a preliminary report. *J Bone Jt Surg Am.* 2003;85(7):1255–1263.
54. Pierce TP, Issa K, Festa A, Scillia AJ, McInerney VK. Pediatric anterior cruciate ligament reconstruction a systematic review of transphyseal versus physseal-sparing techniques. *Am J Sports Med.* 2017;45(2):488–494.
55. Cruz AI, Fabricant PD, McGraw M, Rozell JC, Ganley TJ, Wells L. All-epiphyseal ACL reconstruction in children: review of safety and early complications. *J Pediatr Orthop.* 2017;37(3):204–209.
56. Greulich WW, Pyle S. *Radiographic Atlas of Skeletal Development of the Hand and Wrist.* 2nd ed. Stanford, CA: Stanford University Press; 1959.
57. Willimon SC, Jones CR, Herzog MM, May KH, Leake MJ, Busch MT. Micheli anterior cruciate ligament reconstruction in skeletally immature youths: a retrospective case series with a mean 3-year follow-up. *Am J Sports Med.* 2015;43(12):2974–2981.
58. Kennedy A, Coughlin DG, Metzger MF, et al. Biomechanical evaluation of pediatric anterior cruciate ligament reconstruction techniques. *Am J Sports Med.* 2011;39(5):964–971.
59. McCarthy MM, Tucker S, Nguyen JT, Green DW, Imhauser CW, Cordasco FA. Contact stress and kinematic analysis of all-epiphyseal and over-the-top pediatric reconstruction techniques for the anterior cruciate ligament. *Am J Sports Med.* 2013;41(6):1330–1339.
60. Stadelmaier DM, Arnoczky SP, Dodds J, Ross H. The effect of drilling and soft tissue grafting across open growth plates. A histologic study. *Am J Sports Med.* 1995;23(4):431–435.
61. Calvo R, Figueroa D, Gili F, et al. Transphyseal anterior cruciate ligament reconstruction in patients with open physes: 10-year follow-up study. *Am J Sports Med.* 2015;43(2):289–294.
62. Hui C, Roe J, Ferguson D, Waller A, Salmon L, Pinczewski L. Outcome of anatomic transphyseal anterior cruciate ligament reconstruction in Tanner stage 1 and 2 patients with open physes. *Am J Sports Med.* 2012;40(5):1093–1098.
63. Reid D, Leigh W, Wilkins S, Willis R, Twaddle B, Walsh S. A 10-year retrospective review of functional outcomes of adolescent anterior cruciate ligament reconstruction. *J Pediatr Orthop.* 2017;37(2):133–137.
64. Kaeding CC, Aros B, Pedroza A, et al. Allograft versus autograft anterior cruciate ligament reconstruction: predictors of failure from a MOON prospective longitudinal cohort. *Sports Health.* 2011;3(1):73–81.
65. Kushner AM, Kiefer AW, Lesnick S, Faigenbaum AD, Kashikar-Zuck S, Myer GD. Training the developing brain part II: cognitive considerations for youth instruction and feedback. *Curr Sports Med Rep.* 2015;14(3):235–243.
66. van Melick N, van Cingel REH, Brooijmans F, et al. Evidence-based clinical practice update: practice guidelines for anterior cruciate ligament rehabilitation based on a systematic review and multidisciplinary consensus. *Br J Sports Med.* 2016;50(24):1506–1515.

67. Wilk KE, Arrigo C. Rehabilitation principles of the anterior cruciate ligament reconstructed knee: twelve steps for successful progression and return to play. *Clin Sports Med.* 2017;36(1):189–232.
68. Chicorelli AM, Micheli LJ, Kelly M, Zurakowski D, Macdougall R. Return to sport after anterior cruciate ligament reconstruction in the skeletally immature athlete. *Clin J Sports Med.* 2016;26(4):266–271.
69. Kyritsis P, Bahr R, Landreau P, Miladi R, Witvrouw E. Likelihood of ACL graft rupture: not meeting six clinical discharge criteria before return to sport is associated with a four times greater risk of rupture. *Br J Sports Med.* 2016;50(15):946–951.
70. Kim D, Hong J. Hamstring to quadriceps strength ratio and noncontact leg injuries: a prospective study during one season. *Isokinet Exerc Sci.* 2011;19(1):1–6.
71. Myer GD, Ford KR, Barber Foss KD, Liu C, Nick TG, Hewett T. The relationship of hamstrings and quadriceps strength to anterior cruciate ligament injury in female athletes. *Clin J Sports Med.* 2009;19(1):3–8.
72. Lowe WR, Warth RJ, Davis EP, Bailey L. Functional bracing after anterior cruciate ligament reconstruction. *J Am Acad Orthop Surg.* 2017;25(3):239–249.
73. Dai B, Butler RJ, Garrett WE, Queen R. Anterior cruciate ligament reconstruction in adolescent patients: limb asymmetry and functional knee bracing. *Am J Sports Med.* 2012;40(12):2756–2763.
74. Wright RW, Fetzer G. Bracing after ACL reconstruction: a systematic review. *Clin Orthop Relat Res.* 2007;455:162–168.
75. Simon RA, Everhart JS, Nagaraja HN, Chaudhari AM. A case-control study of anterior cruciate ligament volume, tibial plateau slopes and intercondylar notch dimensions in ACL-injured knees. *J Biomech.* 2010;43(9):1702–1707.
76. Davis TJ, Shelbourne KD, Klootwyk TE. Correlation of the intercondylar notch width of the femur to the width of the anterior and posterior cruciate ligaments. *Knee Surg Sports Traumatol Arthrosc.* 1999;7(4):209–214.
77. Fernandez-Jaen T, Lopez-Alcorocho JM, Rodriguez-Inigo E, Castellan F, Hernandez JC, Guillen-Garcia P. The importance of the intercondylar notch in anterior cruciate ligament tears. *Orthop J Sports Med.* 2015;3(8):2325967115597882.
78. Souryal TO, Freeman TR. Intercondylar notch size and anterior cruciate ligament injuries in athletes. A prospective study. *Am J Sports Med.* 1993;21(4):535–539.
79. Kocher MS, Mandiga R, Klingele K, Bley L, Micheli LJ. Anterior cruciate ligament injury versus tibial spine fracture in the skeletally immature knee. *J Pediatr Orthop.* 2004;24(2):185–188.
80. Brandon ML, Haynes PT, Bonamo JR, Flynn MI, Barrett GR, Sherman MF. The association between posterior-inferior tibial slope and anterior cruciate ligament insufficiency. *Arthroscopy.* 2006;22(8):894–899.
81. Dare DM, Fabricant PD, McCarthy MM, et al. Increased lateral tibial slope is a risk factor for pediatric anterior cruciate ligament injury: an MRI-based case-control study of 152 patients. *Am J Sports Med.* 2015;43(7):1632–1639.
82. Swanik CB, Covassin T, Stearne DJ, Schatz P. The relationship between neurocognitive function and noncontact anterior cruciate ligament injuries. *Am J Sports Med.* 2007;35(6):943–948.
83. Aagaard P, Simonsen EB, Magnusson SP, Larsson B, Dyhre-Poulsen P. A new concept for isokinetic hamstring: quadriceps muscle strength ratio. *Am J Sports Med.* 1998;26(2):231–237.
84. Waldén M, Häggglund M, Ekstrand J. High risk of new knee injury in elite footballers with previous anterior cruciate ligament injury. *Br J Sports Med.* 2006;40(2):158–162.

Open Access Journal of Sports Medicine

Publish your work in this journal

The Open Access Journal of Sports Medicine is an international, peer-reviewed, open access journal publishing original research, reports, reviews and commentaries on all areas of sports medicine. The journal is included on PubMed. The manuscript management system is completely online and includes a very quick and fair

Submit your manuscript here: <http://www.dovepress.com/open-access-journal-of-sports-medicine-journal>

peer-review system. Visit <http://www.dovepress.com/testimonials.php> to read real quotes from published authors.

Dovepress