

Iatrogenic Combined Bile Duct and Right Hepatic Artery Injury During Single Incision Laparoscopic Cholecystectomy

Amareshwar Chiruvella, MD, Juan M. Sarmiento, MD, John F. Sweeney, MD,
Edward Lin, DO, Steven Scott Davis Jr, MD

ABSTRACT

Background: Numerous recent reports describe the performance of laparoscopic procedures through a single incision. Although the feasibility of this approach for a variety of procedures is currently being established, little data are available regarding safety.

Case Report: A 65-year-old female patient who was transferred from an outside institution had undergone a single incision laparoscopic cholecystectomy that resulted in biliary tract and vascular injuries.

Methods: The patient was transferred with a known bile duct injury on the first postoperative day following single incision laparoscopic cholecystectomy. Review of her magnetic resonance imaging and percutaneous transhepatic cholangiogram studies showed a Bismuth type 3 bile duct injury. Hepatic angiogram demonstrated an occlusion of the right hepatic artery with collateralization from the left hepatic artery. She was initially managed conservatively with a right-sided external biliary drain, followed 6 weeks later by a Hepp-Couinaud procedure to reconstruct the biliary tract.

Conclusion: As new techniques evolve, it is imperative that safety, or potential side effects, or both safety and side effects, be monitored, because no learning curve is established for these new techniques. In these initial stages, surgeons should have a low threshold to add additional ports when necessary to ensure that procedures are completed safely.

Key Words: Single incision surgery, Single port cholecystectomy, Iatrogenic bile duct injury, Combined iatrogenic biliary tract and vascular injury.

Department of Surgery, Emory University Hospital, Atlanta, Georgia, USA (all authors).

Address correspondence to: Amareshwar Chiruvella, Department of Surgery, Suite H-124, Emory University Hospital, 1364 Clifton Road NE, Atlanta, GA 30322, USA. Telephone: (404) 727-1540, Fax: (404) 712-2739, E-mail: amares@mac.com

DOI: 10.4293/108680810X12785289144593

© 2010 by JLS, *Journal of the Society of Laparoendoscopic Surgeons*. Published by the Society of Laparoendoscopic Surgeons, Inc.

INTRODUCTION

The first video-laparoscopic cholecystectomy was performed by Phillippe Mouret in 1987,¹ and laparoscopic cholecystectomy (LC) has become the gold-standard procedure for gallbladder surgery since 1992. Numerous reports have evidenced a lower incidence of postoperative pain, shorter recovery times, and significantly lower mortality and morbidity rates after LC compared with open procedures.²⁻⁵ The incidence of bile duct injury following LC is about 0.6%, which remains approximately twice that of its open counterpart.⁶⁻⁸ Injury to the hepatic artery has been reported in 12% to 32% of patients with LC related biliary tract injuries.^{8,9-12} Chapman et al¹¹ demonstrated a 13.8% incidence of combined hepatic artery injury in patients with biliary tract injury following open cholecystectomy. This case report is the first documentation of a combined bile duct and right hepatic artery injury during single incision laparoscopic (SILS) cholecystectomy.

CASE REPORT

A 65-year-old female patient was referred to our institution for definitive treatment of a recognized bile duct injury on postoperative day (POD) 1 after a SILS cholecystectomy. Her past medical and surgical history was significant for hypertension, for which she was on metoprolol, peptic ulcer disease, and tubal ligation. Contrast enhanced magnetic resonance imaging (MRI) showed a normal hepatic morphology with a moderate to severe heterogeneous pattern of perfusion during the arterial phase sequence (not shown). Marked intrahepatic bile duct dilation with narrowing at the confluence of the right and left hepatic ducts is evident (**Figure 1**). The common hepatic duct was not seen on the magnetic resonance cholangiopancreatography images, consistent with a Bismuth type 3 injury. A small amount of soft tissue thickening was seen at the site of the narrowing. The gallbladder was absent.

Serological evaluation showed a low potassium level of 3.1mmol/L, mildly elevated liver function tests (ALT: 1.16 mcKat/L, AST: 1.26 mcKat/L), increased total bilirubin at 106.2 mcmol/L, and a low albumin level at 29 g/L. A PTC was done on POD 3 with the placement of an external

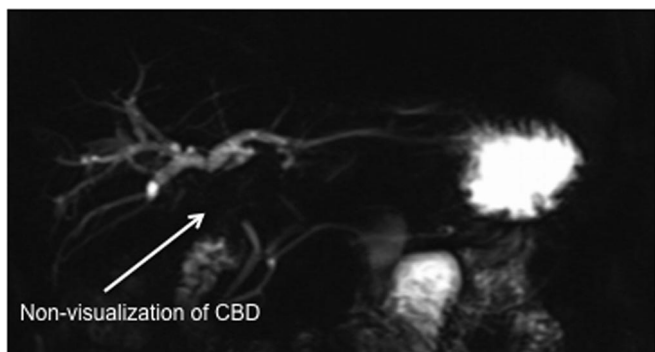


Figure 1. Magnetic resonance cholangiopancreatography showing Bismuth Type III injury. Arrow points to the nonvisualization of the common bile duct. CBD=Common Bile Duct.

biliary drainage catheter. It confirmed the presence of a bile duct injury with nonvisualization beyond the right and left hepatic duct confluence (**Figure 2**). There was no filling of the common bile duct, and there was associated moderate dilation of the intrahepatic ducts. No bile leakage was observed. Due to the heterogeneous perfusion of the right lobe on arterial phases (MRI) and the presence of multiple surgical clips, a hepatic angiogram was done on POD 10 to rule out associated vascular injury. It demonstrated an occlusion of the right hepatic artery at the point of the bifurcation from the proper hepatic artery (**Figure 3**). The presence of a cross-circulation from the left to the right hepatic artery was also noted.

A percutaneous gastrostomy tube was placed on POD 11, because the patient was malnourished, and bile-refeeding therapy was instituted. The patient was discharged home

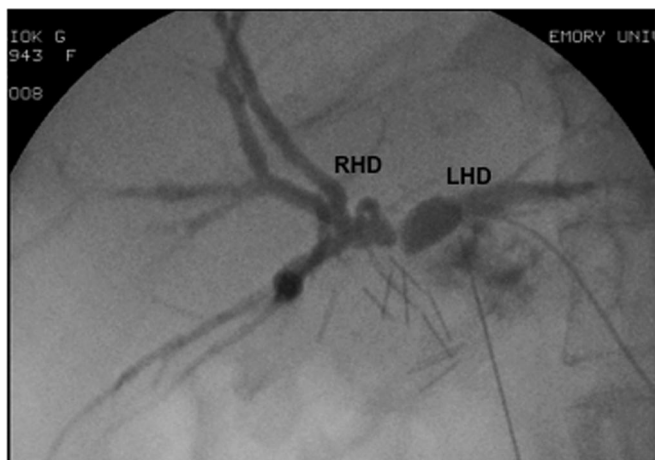


Figure 2. Percutaneous transhepatic cholangiogram showing Bismuth Type III injury. RHD=Right Hepatic Duct, LHD=Left Hepatic Duct.

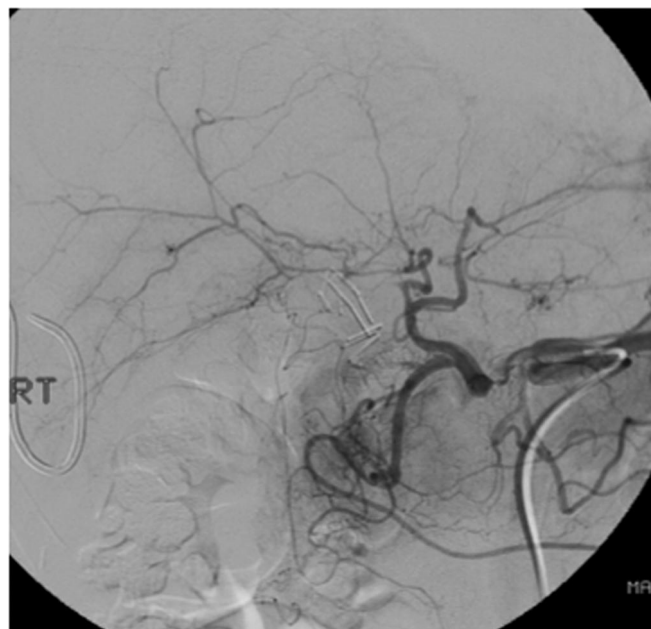

Figure 3. Angiogram showing right hepatic artery injury. Note the presence of a left hepatic artery that bifurcates into lateral and medial branches with the latter creating an anastomosis to supply the right lobe. Note the stump of the original right hepatic artery. Clips in the place corresponding to the take-off of the right hepatic artery.

on oral antibiotics with appropriate instructions about refeeding her bile.

After 6 weeks, a Roux-en-Y hepaticojejunostomy was performed, also known as a Hepp-Couinaud procedure. The patient was discharged on POD 5. She exhibited excellent progress in her postoperative follow-up. Postoperative computed tomography scan showed expected postsurgical changes, and a postoperative cholangiogram via the existing drainage catheter demonstrated a patent anastomosis with no ductal dilation or leak (**Figure 4**). The drain was removed at this time and the patient's laboratory tests showed complete normalization.

DISCUSSION

Several techniques have been described to enable reliable ductal identification during LC so as to decrease the incidence of bile duct injury.^{13,14} A few of them being the “infundibular” technique, the “critical view” technique, recognition of the cystic and the common bile duct junction, and intraoperative cholangiography. Most commonly described and cited in operative notes is the “critical view of safety” technique, first described by Strasberg in 1995.¹⁵ As it delineates the anatomical structures in Calot's triangle

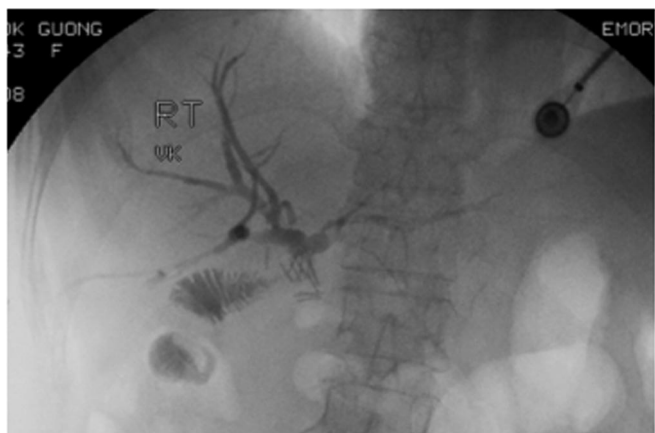

Figure 4. Postoperative percutaneous transhepatic cholangiogram showing patency of the new bilioenteric anastomosis.

and protects against bile duct injuries, it has been routinely applied in LCs.

Schmidt et al¹⁶ reported that the outcome of biliary tract reconstruction was worse in patients with concomitant vascular injuries and recommended the assessment of patients with major biliary tract injuries for additional vascular injuries. They also stated that further studies would be necessary to evaluate the importance of early hepatic artery reconstruction, to the long-term outcome of biliary tract reconstruction. Li et al¹² commented that combined bile duct and hepatic artery injury during LC led to a complicated clinical course with a high mortality rate. Because the level of biliary tract injury is more proximal following LC than following an open cholecystectomy, a higher incidence of concomitant hepatic artery injury can be anticipated.^{15,16} According to Bilge et al,¹⁷ the frequency of high-level biliary injury was increased in patients with concomitant hepatic artery injury compared with those with an isolated iatrogenic biliary tract injury. However, there was no effect on the mortality and medium-term outcome of biliary reconstruction. The lack of evidence of an increase in mortality was reiterated in a review by Tzovaras et al¹⁸ who also stated that combined injuries may cause increased morbidity and jeopardize the long-term results of biliary reconstruction by delayed anastomotic strictures.

Single incision approaches were developed to reduce the number of incisions needed on traditional laparoscopic surgery. Authors have reported the feasibility of the SILS approach in commonly performed abdominal procedures, such as cholecystectomy,¹⁹ appendectomy,^{20,21} urologic procedures,²²⁻²⁴ bariatric procedures,^{25,26} adrenalectomy.²⁷ These early reports describe preliminary re-

sults in case series, but safety and the learning curve have not been studied. Tacchino et al² discussed the need to avoid conflict between the operative instruments and the camera and added that new technology might be helpful for this goal. We agree that these cases can be accomplished with current instrumentation but concede that there is a loss of triangulation and diminished retracting abilities, which may lead to suboptimal exposure. Published reports do not describe any degradation of the “critical view”; however, this would need to be measured objectively. Leaking pneumoperitoneum with existing instruments is another potential problem. Navarra et al¹⁹ reported no significant difference in the postoperative pain or cost effectiveness between SILS and standard LC with a considerably longer average procedure time. So far, a systematic objective assessment of postprocedural pain as well as procedure-related complications is lacking and obviously needed. Cugura et al²⁸ stated that the benefits of transition from the standard laparoscopic approach to SILS will not be as obvious as was the transition from open cholecystectomy to LC. The use of SILS for cholecystitis is less understood. According to Hodgett et al,²⁹ single-site cholecystectomy is feasible for uncomplicated biliary pathology and biliary anatomy not distorted by inflammation. On the other hand, Tacchino et al² have reported that neither cholecystitis nor body mass index >30 are to be considered as contraindications to SILS cholecystectomy. Of 21 SILS cholecystectomies done by Merchant et al,²⁵ all except 2 patients were reported to have biliary colic, and 1 of the 2 who had acute cholecystitis required placement of an accessory port to achieve safe dissection.

CONCLUSION

These techniques likely represent a significant advancement in minimally invasive surgery and an integral part of surgical practice in the future. With advances in surgical instrumentation and technology, these techniques will be applicable to the surgical treatment of an increasing number of diseases. We feel that, at present, care must be taken to ensure that these techniques uphold patient safety and that demand for these procedures does in fact come from patients.

References:

1. Kaiser AM, Corman ML. History of laparoscopy. *Surg Oncol Clin N Am.* 2001;10(3):483-492.
2. Tacchino R, Greco F, Matera D. Single-incision laparoscopic cholecystectomy: surgery without a visible scar. *Surg Endosc.* 2009;23(4):896-899.

3. Hannan EL, Imperato PJ, Nenner RP, Starr H. Laparoscopic and open cholecystectomy in New York State: mortality, complications, and choice of procedure. *Surgery*. 1999;125(2):223-231.
4. Holohan TV. Laparoscopic cholecystectomy. *Lancet*. 1991; 338(8770):801-803.
5. Orlando R 3rd, Russell JC, Lynch J, Mattie A. Laparoscopic cholecystectomy. A statewide experience. The Connecticut Laparoscopic Cholecystectomy Registry. *Arch Surg*. 1993;128(5): 494-498; discussion 498-499.
6. Fletcher DR, Hobbs MS, Tan P, et al. Complications of cholecystectomy: risks of the laparoscopic approach and protective effects of operative cholangiography: a population-based study. *Ann Surg*. 1999;229(4):449-457.
7. McMahon AJ, Russell IT, Baxter JN, et al. Laparoscopic versus minilaparotomy cholecystectomy: a randomised trial. *Lancet*. 1994;343(8890):135-138.
8. Deziel DJ, Millikan KW, Economou SG, Doolas A, Ko ST, Airan MC. Complications of laparoscopic cholecystectomy: a national survey of 4,292 hospitals and an analysis of 77,604 cases. *Am J Surg*. 1993;165(1):9-14.
9. Mathisen O, Soreide O, Bergan A. Laparoscopic cholecystectomy: bile duct and vascular injuries: management and outcome. *Scand J Gastroenterol*. 2002;37(4):476-481.
10. Stewart L, Robinson TN, Lee CM, Liu K, Whang K, Way LW. Right hepatic artery injury associated with laparoscopic bile duct injury: incidence, mechanism, and consequences. *J Gastrointest Surg*. 2004;8(5):523-530; discussion 530-521.
11. Chapman WC, Halevy A, Blumgart LH, Benjamin IS. Post-cholecystectomy bile duct strictures. Management and outcome in 130 patients. *Arch Surg*. 1995;130(6):597-602; discussion 602-594.
12. Li J, Frilling A, Nadalin S, Paul A, Malago M, Broelsch CE. Management of concomitant hepatic artery injury in patients with iatrogenic major bile duct injury after laparoscopic cholecystectomy. *Br J Surg*. 2008;95(4):460-465.
13. Strasberg SM. Biliary injury in laparoscopic surgery: part 1. Processes used in determination of standard of care in misidentification injuries. *J Am Coll Surg*. 2005;201(4):598-603.
14. Strasberg SM, Eagon CJ, Drebin JA. The "hidden cystic duct" syndrome and the infundibular technique of laparoscopic cholecystectomy—the danger of the false infundibulum. *J Am Coll Surg*. 2000;191(6):661-667.
15. Strasberg SM, Hertl M, Soper NJ. An analysis of the problem of biliary injury during laparoscopic cholecystectomy. *J Am Coll Surg*. 1995;180(1):101-125.
16. Schmidt SC, Settmacher U, Langrehr JM, Neuhaus P. Management and outcome of patients with combined bile duct and hepatic arterial injuries after laparoscopic cholecystectomy. *Surgery*. 2004;135(6):613-618.
17. Bilge O, Bozkiran S, Ozden I, et al. The effect of concomitant vascular disruption in patients with iatrogenic biliary injuries. *Langenbecks Arch Surg*. 2003;388(4):265-269.
18. Tzovaras G, Dervenis C. Vascular injuries in laparoscopic cholecystectomy: an underestimated problem. *Dig Surg*. 2006; 23(5-6):370-374.
19. Navarra G, Pozza E, Occhionorelli S, Carcoforo P, Donini I. One-wound laparoscopic cholecystectomy. *Br J Surg*. 1997; 84(5):695.
20. Pelosi MA, Pelosi MA 3rd. Laparoscopic appendectomy using a single umbilical puncture (minilaparoscopy). *J Reprod Med*. 1992;37(7):588-594.
21. Varshney S, Sewkani A, Vyas S, et al. Single-port transumbilical laparoscopic-assisted appendectomy. *Indian J Gastroenterol*. 2007;26(4):192.
22. Desai MM, Rao PP, Aron M, et al. Scarless single port transumbilical nephrectomy and pyeloplasty: first clinical report. *BJU Int*. 2008;101(1):83-88.
23. Kaouk JH, Goel RK, Haber GP, Crouzet S, Desai MM, Gill IS. Single-port laparoscopic radical prostatectomy. *Urology*. 2008; 72(6):1190-1193.
24. Kaouk JH, Haber GP, Goel RK, et al. Single-port laparoscopic surgery in urology: initial experience. *Urology*. 2008; 71(1):3-6.
25. Merchant AM, Cook MW, White BC, Davis SS, Sweeney JF, Lin E. Transumbilical Gelport access technique for performing single incision laparoscopic surgery (SILS). *J Gastrointest Surg*. 2009;13(1):159-162.
26. Saber AA, Elgamal MH, Itawi EA, Rao AJ. Single incision laparoscopic sleeve gastrectomy (SILS): a novel technique. *Obes Surg*. 2008;18(10):1338-1342.
27. Hirano D, Minei S, Yamaguchi K, et al. Retroperitoneoscopic adrenalectomy for adrenal tumors via a single large port. *J Endourol*. 2005;19(7):788-792.
28. Cugura JF, Jankovic J, Kulis T, Kirac I, Beslin MB. Single incision laparoscopic surgery (SILS) cholecystectomy: where are we?. *Acta Clin Croat*. 2008;47(4):245-248.
29. Hodgett SE, Hernandez JM, Morton CA, Ross SB, Albrink M, Rosemurgy AS. Laparoendoscopic single site (LESS) cholecystectomy. *J Gastrointest Surg*. 2009;13(2):188-192.