

Trocar-site hernia after gynecological laparoscopic surgery: a 20-year, single-center experience

Ya-Pei Zhu, Shuo Liang, Lan Zhu, Zhi-Jing Sun, Jing-He Lang

Department of Obstetrics and Gynecology, Peking Union Medical College Hospital, Chinese Academy of Medical Sciences and Peking Union Medical College, Beijing 100730, China.

Abstract

Background: Trocar-site hernia (TSH) is a serious complication after laparoscopic procedures. Although it is a rare entity, it can have life-threatening consequences. This study aimed to retrospectively analyze the potential associated factors for TSH following gynecologic laparoscopy and summarize prevention strategies based on our experience.

Methods: We searched for gynecological laparoscopic surgeries in the medical records system of Peking Union Medical College Hospital (PUMCH) from August 1998 to July 2018 and further sifted through the results for cases involving TSH. All included patients were divided into different groups according to patient characteristics, and the rate of TSH was compared among groups. Moreover, the detailed information of all patients with TSH was recorded and analyzed. Statistical analyses were performed with GraphPad Prism 6.

Results: The approximate total rate of post-operative TSH among gynecologic laparoscopy procedures performed at PUMCH in the last 20 years was 0.016% (9/55,244). The rate of TSH was significantly higher in elder patients (≥ 60 years old; 3/2686, 0.112%) than in younger patients (< 60 years old, 6/52,558; 0.011%, $P = 0.008$). Moreover, the approximate rate of TSH was significantly higher after single-incision laparoscopic surgery (SILS, 2/534, 0.357%) than conventional laparoscopic surgery (7/54,710, 0.013%, $P = 0.003$). The average age of patients with TSH was 53.4 years (range, 35.0–79.0 years). Two of the nine patients had late-onset TSH following SILS; the other seven had early-onset TSH following conventional laparoscopy. Five TSH cases occurred at right lateral port sites, and the remaining three occurred at the umbilical port site. All patients underwent repair surgery, and one required small bowel resection.

Conclusion: Older age and SILS are potential associated factors for TSH development, while reducing excessive manipulation and improving suturing skills, especially at the umbilical trocar site following SILS and the right lateral trocar site, can avoid herniation.

Keywords: Prevention; Risk-factors; Single-incision laparoscopic surgery; Trocar-site hernia

Introduction

Laparoscopic surgery has been routinely used for gynecological diagnosis and treatment since the 1990s.^[1] Compared with laparotomy, laparoscopy is advantageous due to the need for smaller incisions, shorter hospitalizations, and decreased complication rate.^[2,3] With the rapid increase in the use of laparoscopic surgery, concerns have been raised regarding the risk of trocar-site hernia (TSH) after laparoscopic manipulation.

The first TSH was reported by Fear in 1968 as part of his large case series of gynecologic laparoscopies.^[4] Although TSH is a relatively uncommon complication, with an estimated incidence ranging between 0% and 5.2%,^[5] it can cause severe small bowel obstruction, which can lead to emergency surgery. Therefore, more efforts should be made to understand the pathophysiology of TSH forma-

tion and, consequently, reduce its incidence through prevention. Most studies of TSH have reported cases following digestive laparoscopic surgery, while cases following gynecologic laparoscopy are sparse.

In this regard, we conducted the present retrospective study to evaluate the rate of TSH that occurred after gynecological laparoscopic surgeries performed at Peking Union Medical College Hospital (PUMCH) in the past 20 years and explore potential associated factors for this complication.

Methods

This study was approved by the PUMCH Ethics Committee. All participants provided written informed consent.

Access this article online

Quick Response Code:



Website:
www.cmj.org

DOI:
10.1097/CM9.0000000000000510

Correspondence to: Prof. Jing-He Lang, Department of Obstetrics and Gynecology, Peking Union Medical College Hospital, Chinese Academy of Medical Sciences and Peking Union Medical College, Beijing 100730, China
E-Mail: langjh@hotmail.com

Copyright © 2019 The Chinese Medical Association, produced by Wolters Kluwer, Inc. under the CC-BY-NC-ND license. This is an open access article distributed under the terms of the Creative Commons Attribution-Non Commercial-No Derivatives License 4.0 (CCBY-NC-ND), where it is permissible to download and share the work provided it is properly cited. The work cannot be changed in any way or used commercially without permission from the journal.

Chinese Medical Journal 2019;132(22)

Received: 29-05-2019 Edited by: Li-Min Chen

Study design and population

The study was conducted at PUMCH, a tertiary medical center as the pioneering gynecology and obstetrics institution in Beijing, China. All patients who underwent gynecological laparoscopic surgeries between August 1998 and July 2018 were enrolled in the study and their records were retrospectively reviewed. Exclusion criteria included: laparoscopy for non-gynecological reasons, pre-existing umbilical hernia, any immunodeficiency disorder, conversion to laparotomy, re-operation due to a complication of gynecological laparoscopy (other than TSH), and pre-herniation occurred in the open abdominal incision.

All enrolled patients were grouped by age (<60 and ≥60 years old), type of laparoscopy (conventional laparoscopic surgery and single-incision laparoscopic surgery [SILS]), date of operation (first decade: August 1998–July 2008, second decade: August 2008–July 2018) and original procedures (hysterectomy, adnexal operation, myomectomy, and the other operation). According to the different original procedures, the four groups were defined as: (1) hysterectomy conducted for pelvic organ prolapse, uterine fibroids, uterine adenomyosis, endometrial cancer, and cervical lesions; (2) adnexal operation including accessory resection, ovarian cystectomy, salpingectomy, salpingostomy and pelvic adhesiolysis for benign ovarian tumors, tubal pregnancy, endometriosis, and secondary infertility; (3) myomectomy for 2- to 10-cm uterine fibroids and multiple fibroids; and (4) the other operation included laparoscopy for a diagnosis of infertility, tension-free vaginal tape for urine incontinence, etc.

Diagnostic standards for TSH

We further sifted through the enrolled patients for cases involving TSH according to the following diagnostic standards: (1) history of laparoscopic surgery; (2) resembling symptoms and signs of abdominal wall hernia in the trocar site, including nausea, vomiting, abdominal pain, lack of exhaust and defecation and abdominal mass or apophysis at the trocar incision site; and (3) an imaging examination, such as ultrasound, computerized tomography (CT) scan, or magnetic resonance imaging, revealed herniation of the small bowel or omentum through a fascia defect in the trocar site.

According to Tonouchi *et al*^[6] and Velasco *et al*,^[7] TSH can be classified into three types. The early-onset type indicates dehiscence of the anterior fascial plane, posterior fascial plane, and peritoneum and is recognized in many case reports as beginning to develop within 2 weeks after surgery, often presenting as small-bowel obstruction. In the late-onset type, there is dehiscence of the anterior fascial plane and posterior fascial plane, and the hernia sac is the peritoneum, which manifests as asymptomatic swelling in the late stages several months after surgery. The third, special type involves dehiscence of the whole abdominal wall, which is recognized as a protrusion of the intestine and other tissue (eg, the greater omentum).

The characteristics of the identified patients with TSH were reviewed, and the following information was recorded:

patient age, body mass index (BMI), original procedure, pre-operative diagnosis, clinical manifestations, interval to onset symptoms, site and content of herniation, herniation type, and final outcome.

Statistical analysis

Patients' clinical characteristics were analyzed and reported. The continuous variables with non-normal distribution were presented as median (range). Categorical variables were presented as numbers and proportions. The rate of TSH was compared according to patient age, the original procedure, different time periods, and single or multiple-incision laparoscopic surgery using the Fisher exact test. Statistical analyses were performed using GraphPad Prism 6 (Graphpad Software, Inc., La Jolla, CA, USA). A $P < 0.05$ was considered statistically significant.

Results

Total rate of TSH following gynecological laparoscopic surgery

PUMCH, as the pioneering gynecology and obstetrics institution in China, introduced the first gynecologic laparoscopy in China in 1983. Hereafter, the number of gynecological laparoscopic surgeries has increased yearly, from several cases per year to more than 4000 cases per year in the department of gynecology and obstetrics of PUMCH [Figure 1].

During the study period, 55,244 patients received gynecological laparoscopies and were initially enrolled in the study at PUMCH. Their demographic data and other characteristics are shown in Table 1. Among these, nine patients with TSH were identified, making the approximate total rate of TSH more than one per 6138 cases (0.016%).

Univariate analysis identified age ≥60 years old and SILS as the potential associated factors to this complication

As displayed in Table 1, among the 55,244 enrolled patients, the rate of TSH was significant higher in elderly patients (≥60 years old; 3/2686, 0.112%) than in younger

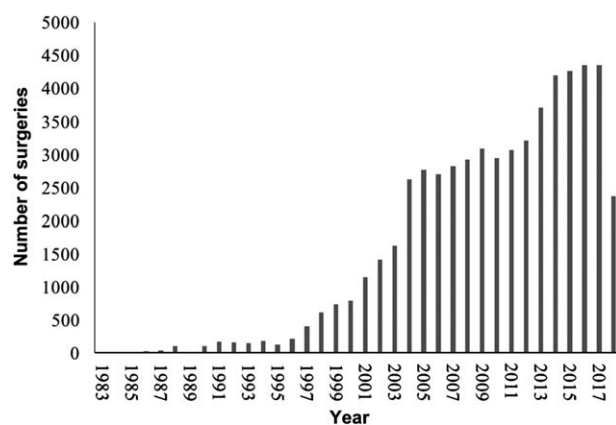


Figure 1: The number of gynecology laparoscopies performed each year at the Peking Union Medical College Hospital.

patients (<60 years old, 6/52,558; 0.011%; $P = 0.008$) [Table 1], in line with the findings of a previous study. Moreover, the approximate rate of TSH was significantly higher after SILS (2/534, 0.357%) than after conventional laparoscopic surgery (7/54,710, 0.013%; $P = 0.003$) [Table 1]. Although laparoscopic hysterectomy (3/10,252, 0.029%) is associated with a slightly higher rate of TSH than other original procedures, the difference in the rate of TSH among different procedure groups was not significant ($P = 0.626$) [Table 1]. Moreover, we also compared the rate of TSH between the first and second decades of the past 20 years among gynecological laparoscopic surgeries. The rate of TSH was higher in the second decade (8/36,769, 0.022%) than in the first decade (1/18,475, 0.005%), but this difference was not significant ($P = 0.288$) [Table 1].

The distributions of patient ages and procedures in each of the two decades are shown in Table 2. These findings indicate that the proportions of elderly patients, cases who

conducted SILS and cases who underwent laparoscopic hysterectomy in the second decade were both significantly higher than the corresponding findings in the first decade (all $P < 0.0001$).

Clinical features of nine patients with post-operative TSH following gynecological laparoscopic surgery

The detailed characteristics of the nine patients with TSH after gynecological laparoscopic surgery are shown in Table 3. There were seven early-onset cases and two late-onset cases in our series of cases. The average patient age and BMI were 53.4 years old (range, 35–79 years old) and 25.1 kg/m² (range, 17.6–34.0 kg/m²). The original laparoscopic procedures included total laparoscopic hysterectomy with bilateral salpingo-oophorectomy in two patients, cytoreductive surgery in one patient, left salpingo-oophorectomy in one patient, ovarian cystectomy in four patients (two bilateral, one left, and one right), myomectomy in two patients, and adhesiolysis in three patients. Except for three patients who underwent laparoscopic hysterectomy, the other six patients required specimen removal through the right lateral (four conventional laparoscopies) or umbilical (two SILSs) port site; this information is not shown in Table 3.

Of the nine TSH cases, five occurred at the 10 mm port site, and two occurred at the 5 mm port site. It is worth mentioning that herniations occurred after two SILSs in which the port sizes were 40 and 25 mm; both of these cases were late-onset type. Five TSH cases occurred at right lateral port sites, and the remaining four were at the umbilical port site. The content of the hernia sac included small bowel (six cases) or omentum (three cases). Among the nine patients, five patients presented with symptoms related to intestinal obstruction, such as vomiting, abdominal pain, lack of exhaust, and defecation; while the other four patients showed an abdominal mass or abdominal apophysis when coughing. Patient No. 7 had no subjective symptoms after first laparoscopic surgery and came to the hospital for second laparoscopic surgery due to myoma 2 years later; the TSH in this patient was accidentally discovered in a clinical examination. The

Table 1: The rate of TSH after gynecological laparoscopic surgery according to different characteristics.

Characteristics	Results, n/N (%)	P
Age		0.008
<60 years	6/52,558 (0.011)	
≥60 years	3/2686 (0.112)	
Type of laparoscopy		0.003
Conventional laparoscopy	7/54,710 (0.013)	
SILS	2/534 (0.357)	
Original procedure		0.626
Hysterectomy	3/10,252 (0.029)	
Adnexal operation	4/31,778 (0.013)	
Myomectomy	2/10,819 (0.018)	
Others	0/2395 (0)	
Date of operation		0.288
First decade (1998.08–2008.07)	1/18,475 (0.005)	
Second decade (2008.08–2018.07)	8/36,769 (0.022)	

TSH: Trocar-site hernia; SILS: Single-incision laparoscopic surgery.

Table 2: Characteristic distribution of the patients underwent gynecological laparoscopic surgery in the past two decades, n (%).

Characteristics	First decade (n = 18,476)	Second decade (n = 36,769)	χ ²	P
Age			212.6	<0.01
<60 years	17,926 (97.023)	34,633 (94.191)		
≥60 years	550 (2.977)	2136 (5.809)		
Type of laparoscopy			270.9	<0.01
Conventional laparoscopy	18,476 (100.000)	36,235 (98.548)		
SILS	0	534 (1.452)		
Original procedure			2189.0	<0.01
Hysterectomy	1879 (10.170)	8373 (22.771)		
Adnexal operation	12,435 (67.303)	19,343 (52.607)		
Myomectomy	2874 (15.556)	7946 (21.611)		
Others	1288 (6.971)	1107 (3.011)		

SILS: Single-incision laparoscopic surgery.

Table 3: The clinical characteristics of trocar-site hernia after gynecological laparoscopic surgery.

Case No.	Age (years)	BMI (kg/m ²)	Original procedure	Pre-operative diagnosis	Clinical manifestation	Method of diagnosis	Interval to onset (days)	Herniation site	Trocar size (mm)	Herniation contents	Surgical repair	Type
1	56	27.2	LH + BSO	Myoma	Small bowel obstruction	US	2	Umbilical	10	Small bowel	LAP	Early-onset
2	75	17.6	LH + BSO	Right ovary cyst, myoma	Small bowel obstruction	CT	9	Right lateral	5	Small bowel	LAP, SBR	Early-onset
3	35	22.6	Myomectomy + LOC + adhesiolysis	Pelvic mass	Small bowel obstruction	CT	6	Right lateral	10	Small bowel	LAP	Early-onset
4	63	25.1	CRS	Endometrial cancer	Abdominal mass	CT	5	Right lateral	5	Small bowel	LAP	Early-onset
5	79	25.2	LSO + adhesiolysis	Pelvic mass	Small bowel obstruction	CT	3	Right lateral	10	Small bowel	LAP	Early-onset
6	41	26.7	BOC	Pelvic endometriosis, ovary cyst	Abdominal mass	Clinical	5	Umbilical	10	Omentum	LAP, PRO	Early-onset
7	43	34.0	BOC (SILS)	Ovary cyst	Abdominal mass	Clinical	730	Umbilical	40	Omentum	LSC	Late-onset
8	37	21.5	ROC (SILS)	Ovary cyst	Abdominal mass	Clinical	240	Umbilical	25	Omentum	LAP	Late-onset
9	52	26.0	Myomectomy + adhesiolysis	Myoma	Small bowel obstruction	CT	4	Right lateral	10	Small bowel	LAP	Early-onset

BMI: Body mass index; LH: Laparoscopic hysterectomy; BSO: Bilateral salpingo-oophorectomy; LOC/ROC/BOC: Left/right/bilateral ovarian cystectomy; CRS: Cytoreductive surgery; LSO: Left salpingo-oophorectomy; SILS: Single-incision laparoscopic surgery; US: Ultrasonography; CT: Computed tomography; LAP: Laparotomy; SBR: Small bowel resection; PRO: Partial resection of omentum; LSC: Laparoscopy.

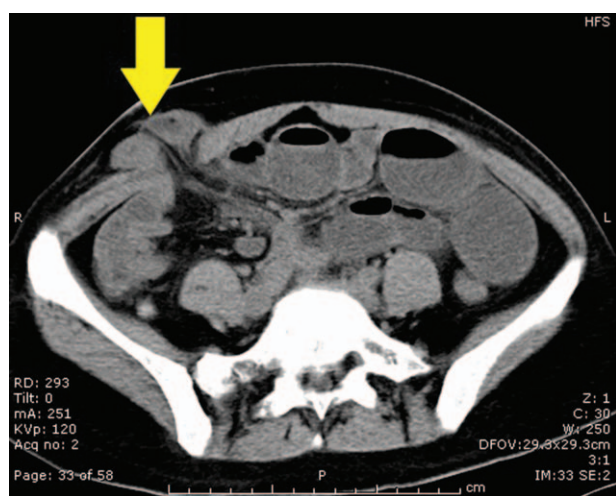


Figure 2: Abdominal CT scan of small bowel loops above the fascia in a patient with herniation (arrow) through a 10-mm right lateral trocar site (patient No. 3 from Table 3). CT: Computed tomography.

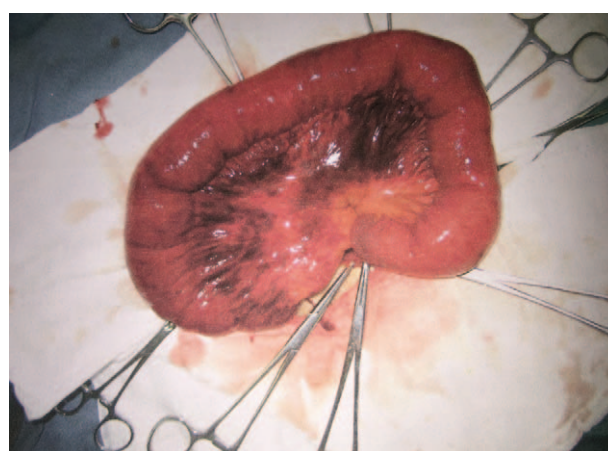


Figure 3: Discovery of necrosis of the small bowel that entrapped a fascia defect at the right lateral trocar site via exploratory laparotomy (patient No. 2 from Table 3).

interval between the original surgery and the onset of symptoms ranged from 2 days to 2 years.

TSH was diagnosed by CT scan in five patients, by ultrasonography in one patient and by clinical examination in three patients. A CT scan image revealed herniation of the small bowel or omentum through a fascia defect [Figure 2].

The herniation was repaired by a laparotomy in eight patients and by a second laparoscopy in one patient. The type of incision used in the second procedure is not shown in Table 3 and was an expansion of the original herniation incision. Only one patient required small bowel resection because the intestinal segment presented as purple-black, indicating a loss of vitality [Figure 3]. It is worth mentioning that patients No. 1, No. 2, and No. 5 were initially observed for a few days, but their conditions did

not improve and even worsened, and these patients ultimately required emergency laparotomy.

Discussion

TSH is a serious complication defined as an incisional hernia occurring after laparoscopic procedures at the trocar incision site,^[8] as it can lead to life-threatening complications, such as bowel obstruction and strangulation.

The clinical presentation of TSH is nausea, vomiting, abdominal pain, lack of exhaust and defecation, and abdominal mass or apophysis. The onset of these symptoms can range from a few days to several months after intervention, although they generally occur within a few days after the operation.^[9,10] If TSH is suspected, an abdominal CT scan or ultrasonography can be helpful for diagnosis, especially abdominal CT scan, which can not only find the herniation site but can also define its classification.^[5]

In the present study, we retrospectively reviewed the records of all patients who underwent gynecological laparoscopic surgery between August 1998 and July 2018, to (1) evaluate the rate of TSH and (2) explore predisposing factors for the development of TSH. The rate of TSH in the current series from PUMCH was 0.016%. The first large-scale study of TSH after gynecological laparoscopic surgery was published by the American Association of Gynecologic Laparoscopists in 1994. In that series of 4,385,000 patients, the incidence of TSH was 0.021%, which was higher than the rate of TSH reported in our study.^[11] In a large systematic review by Swank *et al*^[5] in 2012, which included twenty-two articles, an even higher incidence of TSH after laparoscopic surgery with a median pooled estimate of 0.5% (range 0–5.2%) was reported. However, the true rate in our series might be much higher than the reported figure as an unknown percentage of patients who are asymptomatic (eg, patient No. 6) may not seek medical attention. Extended follow-up could reveal the asymptomatic population, but not all of these patients need treatment. Therefore, a cost-effect analysis regarding whether it is necessary to extend follow-up procedure is worth considering.

According to previous studies, the risk factors for TSH have been extensively explored and can be categorized according to their relationships with patients and surgeries. The patient-related risk factors included BMI >28 kg/m², age >60 years, post-operative port site infection, uncontrolled diabetes mellitus, previous abdominal surgery, and smoking status. The surgery-related risk factors are a prolonged surgical duration, excessive manipulation of the trocar site, the size of the trocar incision, the site of trocar placement (umbilical sites are more prone to hernias), non-closure of the fascia at the trocar site, and the type of trocar tip (bladed, non-bladed, or radially expanding).^[4,6,12-17] However, not all of these risk factors were certain.

In the current retrospective study, we focused on the potential associated factors in which we were interested. The marked improvements in medical technology and healthcare, lead to an increasing number of elderly patients to take advantage of complex surgical procedures including laparoscopic surgery. In our study, it indicated that older patients (≥60 years old) were more likely than younger to develop TSH after gynecological laparoscopic surgery, which is in line with the previous studies.^[5,11,18]

With the development of laparoscopic surgery, SILS has been proposed to further minimize surgical trauma.^[19] SILS refers to a laparoscopic surgery performed through a single incision using a multiport device or two to four conventional ports introduced through a single 2 to 4 cm incision, usually in the umbilicus.^[20] An obvious advantage of SILS is cosmetic appearance because the procedure involves only a single incision. However, the risk of TSH following SILS is potentially higher than conventional laparoscopic surgery,^[21,22] which is also verified in our present study. Antoniou *et al*^[23] conducted a meta-analysis to evaluate the incidence of TSH following SILS and conventional laparoscopic surgery and included studies that were randomized control trials. A total of 1705 patients were included and randomized to single-incision

(*n* = 851) or conventional laparoscopic surgery (*n* = 849), and all the types of surgery were digestive surgery. Their results indicated that SILS was associated with a slightly higher risk of TSH than conventional laparoscopy was (odds ratio 2.26, 95% confidence interval 1.00–5.08, *P* = 0.05). In 2018, Antoniou *et al*^[24] updated this meta-analysis by including more high-quality studies to compare the risk of TSH following single-incision (*n* = 1239) and conventional laparoscopic surgery (*n* = 1232). This new analysis provides robust evidence to confirm their results (odds ratio 2.37, 95% confidence interval 1.25–4.50, *P* = 0.008).

To the best of our knowledge, in China, this is the first study performed to report cases of TSH following gynecological SILS. The Department of Gynecology and Obstetrics at PUMCH began conducting SILS in 2015. To date, 534 SILSs have been conducted, and two cases were reported to lead to late-onset TSH. The approximate rate of TSH is much higher than that of conventional laparoscopic surgery. Although the results shed an unfavorable light on SILS, this conclusion is of uncertain clinical significance. Patient perception and surgeon and patient priorities need to be considered when the operation strategy is selected. Moreover, the method and techniques used to suture the single incision should be improved and standardized to reduce the occurrence of TSH while maintaining the advantages of SILS.

Although the incidence of TSH after different original procedures was not significantly different, it is likely that more extensive surgeries have a higher incidence of hernias because hysterectomy results in the highest incidence of hernia while diagnosis-only laparoscopy rarely leads to it.

While the number of laparoscopic surgeries performed in the second decade was two-fold higher than that conducted in the first decade, the incidence of TSH after laparoscopy was higher in the second decade than in the first decade, which was unexpected. In theory, with the widespread use of laparoscopy, the occurrence of herniation should have decreased because of improved equipment and more skilled gynecologists. This opposite result indicates that the occurrence of TSH may not be simply justified by the improved equipment and skill. It may instead be associated with the increasing proportion of elderly individuals in the population and the fact that more cases underwent SILS or hysterectomy through laparoscopy, which are risk factors for TSH, as mentioned above.

With regard for our series, several more findings are worth noting. First, it is apparent that herniation frequently occurs at the right lateral or umbilical port sites, and the right lateral sites seem to be more predisposed than other sites to herniation. Second, the content of the hernia sacs at the right lateral sites are inclined to be small bowel, and the symptoms of small bowel obstruction (even small bowel necrosis) are more likely to occur in these cases. We infer that the surgeon often stands by the right side of the patient and that the specimen must be removed through the port site, resulting in excessive manipulation of the right lateral port sites. Third, early-onset TSH frequently occurs after conventional laparoscopy, while late-onset TSH often

occurs after SILS. We suspect that the patients who underwent SILS were younger than those who underwent conventional laparoscopic surgery and that full-thickness closure of the incision port for SILS was employed due to the wider incision port, making its peritoneum stronger than the incision ports used in conventional laparoscopic surgery. Therefore, the patients who underwent SILS had a relatively late onset of TSH. Fourth, straining during bowel movements or severe coughing within several days after the operation can induce TSH because of the sudden increase in abdominal pressure, especially in elderly patients whose fascia are vulnerable, such as patient No. 2.

Moreover, it is worth mentioning that a weakened abdominal wall resulting from vascular damage is also a high-risk factor for TSH. Therefore, it is important to identify a safe introduction technique for ancillary trocars to avoid vascular damage, especially in inferior epigastric artery, to further reduce the risk of TSH. Despite the various techniques adopted by the surgical community, it has not yet been determined which is the correct access route in all patients.^[25,26] Vitale *et al*^[27] reported that among the different techniques, the identification of the “yellow island” as an anatomical landmark seems to be a useful aid for the safe introduction of ancillary trocars in gynecological surgery. This particular landmark is identified by taking the lateral third of the line between the anterior superior iliac spine and the umbilicus as reference points and finding a subperitoneal accumulation of adipose tissue located in that area. In addition, Tinelli *et al*^[28] proposed two simple steps; they called the first the “yellow island” port entry and the second the trocar “tip entry guided” site, which is located by a suction cannula to avoid iatrogenic injuries to vessels.

Once TSH occurs, it cannot spontaneously heal and, on the contrary, tends to deteriorate, as was observed in patients No. 1 and No. 4. Repair surgery is the only treatment method. However, in some asymptomatic cases, follow-up observation is enough. Therefore, after combining the severity of the symptoms of the patient and/or the dangerous conditions related to herniation after assessment, immediate surgery should be conducted as soon as possible to prevent small bowel obstructions from developing necrosis.

Nevertheless, the prevention of TSH is the most important goal. According to the risk factors summarized above, several recommendations can be made: (1) Choose the trocar with the smallest size possible if conditions permit. (2) Choose the “yellow island” as the trocar site entry to avoid vascular damage. (3) Reduce manipulation due to repeated access to the trocar site. (4) Fascial closure is generally recommended for all trocars ≥ 10 mm^[29]; however, the right lateral port site should also undergo fascial closure regardless of the trocar size, according to our series. (5) Avoid activities that increase abdominal pressure, such as coughing and excessive strain during bowel movement, within 2 weeks after surgery; this is particularly important in elderly patients.

Although the high number of included patients was a strength of our study, it also had some limitations. First,

the study has a retrospective design which limits its credibility. Moreover, the large number of cases restricted the feasibility of follow-up of all the patients. We might have lost some patients with TSH who accessed another hospital for treatment. Therefore, the incidence of TSH in our hospital is likely to have been underestimated. Meanwhile, the cases with TSH is too little to conduct multivariate analysis, we just performed univariate analysis to explore the potential associated factors of development of TSH after gynecological laparoscopic surgery instead of risk factors. To systematically analyze risk factors, it is necessary to design a prospective study and expend more effort in conducting rigorous follow-up.

In conclusion, although it is a relatively uncommon complication of gynecologic laparoscopy, TSH should be given attention due to the risk of emergency surgery. Older age and SILS are potential associated factors for TSH development, while reducing excessive manipulation and improving suturing skills, especially at the umbilical trocar site following SILS and the right lateral trocar site, can avoid herniation. More severe problems, such as small bowel necrosis, can be prevented by early detection and early treatment.

Funding

This study was supported by a grant from the Chinese Academy of Medical Sciences Initiative for Innovative Medicine (No. CAMS-2017-I2 M1-002).

Conflicts of interest

None.

References

1. Duron JJ, Hay JM, Msika S, Gaschard D, Domergue J, Gainan A, *et al*. Prevalence and mechanisms of small intestinal obstruction following laparoscopic abdominal surgery: a retrospective multicenter study. French association for surgical research. *Arch Surg* 2000;135:208–212. doi: 10.1001/archsurg.135.2.208.
2. Yang H, Li XC, Yao C, Lang JH, Jin HM, Xi MR, *et al*. Proportion of uterine malignant tumors in patients with laparoscopic myomectomy: a national multicenter study in China. *Chin Med J* 2017;130:2661–2665. doi: 10.4103/0366-6999.218008.
3. Yang QY, Tang JY. Application of robot-assisted laparoscopic pelvic exenteration in treating gynecologic malignancies. *Chin Med J* 2019;132:976–979. doi: 10.1097/CM9.0000000000000202.
4. Fear RE. Laparoscopy: a valuable aid in gynecologic diagnosis. *Obstet Gynecol* 1968;31:297–309. doi: 10.1097/00006250-196803000-00001.
5. Swank HA, Mulder IM, la Chapelle CF, Reitsma JB, Lange JF, Bemelman WA. Systematic review of trocar-site hernia. *Br J Surg* 2012;99:315–323. doi: 10.1002/bjs.7836.
6. Tonouchi H, Ohmori Y, Kobayashi M, Kusunoki M. Trocar site hernia. *Arch Surg* 2004;139:1248–1256. doi: 10.1001/archsurg.139.11.1248.
7. Velasco JM, Vallina VL, Bonomo SR, Hieken TJ. Post laparoscopic small bowel obstruction: rethinking its management. *Surg Endosc* 1998;12:1043–1045. doi: 10.1007/s004649900777.
8. Rebibo L, Dhahri A, Chivot C, Cyril C, Yzet T, Regimbeau JM. Trocar site hernia after laparoscopic sleeve gastrectomy using a specific open laparoscopy technique. *Surg Obes Relat Dis* 2015;11:791–796. doi: 10.1016/j.soard.2014.11.028.
9. Moreaux G, Estrade-Huchon S, Bader G, Guyot B, Heitz D, Fauconnier A, *et al*. Five-millimeter trocar site small bowel eviscerations after gynecologic laparoscopic surgery. *J Minim Invasive Gynecol* 2009;16:643–645. doi: 10.1016/j.jmig.2009.05.014.

10. Seamon L, Backes F, Resnick K, Cohn D. Robotic trocar site small bowel evisceration after gynecologic cancer surgery. *Obstet Gynecol* 2008;112:462–464. doi: 10.1097/AOG.0b013e3181719ba8.
11. Montz FJ, Holschneider CH, Munro MG. Incisional hernia following laparoscopy: a survey of the American Association of Gynecologic Laparoscopists. *Obstet Gynecol* 1994;84:881–884. doi: 10.1016/s1074-3804(05)80946-6.
12. Pereira N, Hutchinson AP, Irani M, Chung ER, Lekovich JP, Chung PF, *et al.* 5-millimeter trocar-site hernias after laparoscopy requiring surgical repair. *J Minim Invasive Gynecol* 2016;23:505–511. doi: 10.1016/j.jmig.2016.03.001.
13. Caglia P, Tracia A, Borzi L, Amodeo L, Tracia L, Veroux M, *et al.* Incisional hernia in the elderly: risk factors and clinical considerations. *Int J Surg* 2014;12 (Suppl 2):S164–S169. doi: 10.1016/j.ijsu.2014.08.357.
14. Pilone V, Di Micco R, Hasani A, Celentano G, Monda A, Vitiello A, *et al.* Trocar site hernia after bariatric surgery: our experience without fascial closure. *Int J Surg* 2014;12:S83–S86. doi: 10.1016/j.ijsu.2014.05.047.
15. Helgstrand F, Rosenberg J, Bisgaard T. Trocar site hernia after laparoscopic surgery: a qualitative systematic review. *Hernia* 2011;15:113–121. doi: 10.1007/s10029-010-0757-x.
16. Nezhat C, Nezhat F, Seidman DS, Nezhat C. Incisional hernias after operative laparoscopy. *J Laparoendosc Adv Surg Tech A* 1997;7:111–115. doi: 10.1089/lap.1997.7.111.
17. Margaux JK, Mazdak M, Konstantin Z, Linus C, Monica P. Case report five-millimeter balloon trocar site herniation: report of two cases and review of literature. *J Minim Invasive Gynecol* 2013;20:723–726. doi: 10.1016/j.jmig.2013.04.012.
18. Wang SY, Yin L, Guan XM, Xiao BB, Zhang Y, Delgado A. Single port transumbilical laparoscopic surgery versus conventional laparoscopic surgery for benign adnexal masses: a retrospective study of feasibility and safety. *Chin Med J* 2016;129:1305–1310. doi: 10.4103/0366-6999.182829.
19. Karampinis I, Lion E, Grilli M. Trocar site hernias in bariatric surgery—an underestimated issue: a qualitative systematic review and meta-analysis. *Obes Surg* 2019;29:1049–1057. doi: 10.1007/s11695-018-03687-2.
20. Salamah K, Abuzaid M, Abu-Zaid A. Single-incision laparoscopic surgery in gynecologic surgery: a single-institutional experience from Saudi Arabia. *F1000Res* 2017;6:1657. doi: 10.12688/f1000research.12545.1.
21. Hoyuela M, Juvany S, Guillaumes J, Ardid M, Trias I, Bachero A, *et al.* Long-term incisional hernia rate after single-incision laparoscopic cholecystectomy is significantly higher than that after standard three-port laparoscopy: a cohort study. *C. Hernia* 2019. doi: 10.1007/s10029-019-01969-x.
22. Moulton L, Jernigan AM, Carr C. Single-port laparoscopy in gynecologic oncology: seven years of experience at a single institution. *Am J Obstet Gynecol* 2017;217:610.e1–610.e8. doi: 10.1016/j.ajog.2017.06.008.
23. Antoniou SA, Morales-Conde S, Antoniou GA, Grandrath FA, Berrevoet F, Muysoms FE, *et al.* Single-incision laparoscopic surgery through the umbilicus is associated with a higher incidence of trocar-site hernia than conventional laparoscopy: a meta-analysis of randomized controlled trials. *Hernia* 2016;20:1–10. doi: 10.1007/s10029-015-1371-8.
24. Antoniou SA, Garcia-Alamino JM, Hajibandeh S, Hajibandeh S, Weitzendorfer M, Muysoms FE, *et al.* Single-incision surgery trocar-site hernia: an updated systematic review meta-analysis with trial sequential analysis by the minimally invasive surgery synthesis of interventions outcomes network (mission). *Surg Endosc* 2018;32:14–23. doi: 10.1007/s00464-017-5717-4.
25. Iranmanesh P, Rivera AR, Bajwa KS, Alibhai M, Snyder BE, Wilson TD, *et al.* Trocar site closure with a novel anchor-based (neoClose[®]) system versus standard suture closure: a prospective randomized controlled trial. *Surg Endosc* 2019. doi: 10.1007/s00464-019-06891-y.
26. Ahmad G, Baker J, Finnerty J, Phillips K, Watson A. Laparoscopic entry techniques. *Cochrane Database Syst Rev* 2019;18:CD006583. doi: 10.1002/14651858.CD006583.pub5.
27. Vitale SG, Gasbarro N, Lagana AS, Sapia F, Rapisarda AMC, Valenti G, *et al.* Safe introduction of ancillary trocar in gynecological surgery: the “yellow island” anatomical landmark. *Ann Ital Chir* 2016;87:608–611. doi: 10.1007/s11605-018-3757-2.
28. Tinelli A, Gasbarro N, Lupo P, Malvasi A, Tsin DA, Davila F, *et al.* Safe introduction of ancillary trocar. *J Soc Lapa Surg* 2012;16:276–279. doi: 10.4293/108680812X13427982376464.
29. Owens M, Barry M, Janjua AZ, Winter DC. A systematic review of laparoscopic port site hernias in gastrointestinal surgery. *Surgeon* 2011;9:218–224. doi: 10.1016/j.surge.2011.01.003.

How to cite this article: Zhu YP, Liang S, Zhu L, Sun ZJ, Lang JH. Trocar-site hernia after gynecological laparoscopic surgery: a 20-year, single-center experience. *Chin Med J* 2019;132:2677–2683. doi: 10.1097/CM9.0000000000000510