

## Case Report

# Autogenous wisdom tooth transplantation: A case series with 6-9 months follow-up

Tatjana Nimčenko<sup>1</sup>, Gražvydas Omerca<sup>1</sup>, Ennio Bramanti<sup>2</sup>, Gabriele Cervino<sup>2</sup>, Luigi Laino<sup>3</sup>, Marco Ciccù<sup>4</sup>

<sup>1</sup>Department of Maxillofacial Surgery, Lithuanian University of Health Sciences, Lithuania, <sup>2</sup>Departments of Odontostomatology and <sup>4</sup>Human Pathology, School of Dentistry, University of Messina, Messina, <sup>3</sup>Department of Odontostomatology, School of Dentistry, University of Foggia, Foggia, Italy

## ABSTRACT

Tooth transplantation can be considered a valid and predictable treatment option for rehabilitating young patients with permanent teeth loss. This study presents several cases of successful autogenous tooth transplantation with a 6-9 months follow-up. Tooth auto-transplantation can be considered a reasonable option for replacing missing teeth when a donor tooth is available. The auto-transplantation of a right mandibular third molar with compromised function and esthetics to replace the residual roots resulting from coronal destruction due to extensive carious lesion of the second molar in the same quadrant as shown in the presented cases can result a viable treatment alternative especially in a young patient that cannot undergo dental implant therapy. Transplantation of mature third molar seems to be a promising method for replacing a lost permanent molar tooth and restoring esthetics and function. This clinical procedure showed excellent functional and esthetical long-term results in the analyzed cases.

**Key Words:** Auto-transplantation, Molar, tooth

Received: October 2013  
Accepted: December 2013

**Address for correspondence:**  
Dr Marco Ciccù,  
Department of Human  
Pathology, Dental School,  
Messina University, Via  
Consolare Valeria 98100,  
Messina, Italy.  
E-mail: acromarco@yahoo.it

## INTRODUCTION

First permanent molars are most prone to caries in the permanent dentition as a result of its early exposure to the oral environment.<sup>[1]</sup> It is known that due to relatively high organic content of newly erupted, immature tooth enamel is more permeable and therefore more susceptible to caries.<sup>[2]</sup> Consequently, more than 50% of children over 11 years have caries in mentioned teeth. Heavily restored such teeth due to poor condition and unfavorable long-term prognosis may need to be extracted in later life<sup>[3]</sup> thus leading to unfavorable occlusal changes if spaces are left unrestored. Due to young age and still continuing development of the jaws, these patients cannot

be treated with permanent restorations (implants, prosthetic bridges) and the orthodontic treatment of the gap that emerged after extraction to close is often time demanding. Therefore, we came to the decision that these clinical cases may be resolved using biological treatment methods such as autogenous tooth transplantation that would develop along with neighboring structures without any disturbance. This treatment thereby would act as prevention of malocclusion in young patients. In our article, "Tooth auto-transplantation as an alternative treatment option: A literature review,"<sup>[4]</sup> we discussed tooth auto-transplantation treatment method reviewing latest data on indications, criteria for this procedure and its success rate. Continuing this topic in this article, we present cases of tooth auto-transplantation performed in 2012-2013 where surgical skills, knowledge and acquired information for successful transplantation was applied in clinical practice.

A total of 15 cases with performed auto-transplantations of wisdom teeth germs transplants from 14 patients (6 males, 8 females) were included in this study. All operations were performed by the

Access this article online



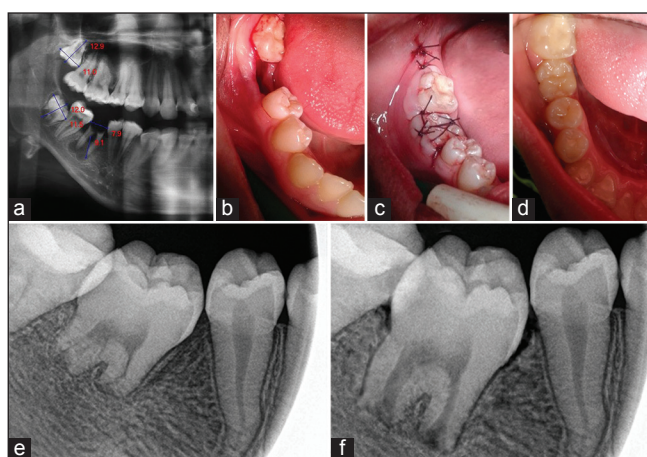
Website: <http://drj.mui.ac.ir>

same operator in the Oral and Maxillofacial Surgery Department at Hospital of Lithuanian University of Health Sciences in Clinics of Kaunas, Lithuania, after the Ethical Committee approval.

All patients were in good health and a routine examination found no systematic or local contraindications for surgical treatment. Indications for auto-transplantation were severe caries destruction, fractures of the teeth, inadequate root canal treatment and apical periodontitis. The average age of the patients at the time of transplantation was 18.1 years (15-20 years, standard deviation: 1.7). In all 15 cases indication for transplantation was non-repairable first lower (13 cases) or upper (2 cases) molar. Wisdom teeth<sup>[5]</sup> were removed and used to replace first molar in the same jaw [Figure 1 and Table 1].

The criteria for successful auto-transplantation in this study were:

1. Physiologic tooth mobility in 4 weeks post-operation after splint removal;
2. Clinically, no discomfort and normal function;
3. Normal periodontal probing, tight gingival margin without signs of inflammation;
4. Positive sensitivity test to cold in 6 months post-operation;
5. Radiographically normal healing of recipient alveolus in 3 months post-operation, no root resorption and continuous root formation in 6-9 months post-operation.



**Figure 1:** (a) Panoramic radiograph underline the clinical status of the molars (b) recipient site preparation 3 weeks after extraction (c) transplanted tooth fixated with sutures and wire-resin splint (d) 1 month post-operation clinical evaluation (e) radiograph 3 months post-operation (f) radiograph 9 months post-operation

The sequels of the procedure includes clinical and radiographic examination, diagnosis, treatment planning, surgical procedure (one-stage or two-stage when periapical lesion is present) and follow-up.

### Examination and diagnosis

All patients were examined clinically evaluating damaged permanent molar, surrounding soft-tissue, and oral hygiene. Radiographic examination included panoramic X-ray, which was used to assess possible periapical lesion in the recipient site, stage of wisdom tooth root development, mesio-distal width of the crown and length of the donor tooth roots matching with recipient site.

### Treatment planning

Damaged tooth extraction depends on the clinical situation: In cases of periapical lesion, the tooth is extracted 2-4 weeks prior to auto-transplantation and meticulous socket cleaning from inflammatory granulation tissue is necessary. Immediate auto-transplantation is preferable when no lesion in the recipient site is detected and enough gingival tissue to close around the donor tooth is expected.

Auto-transplantation timing is based on donor tooth rhizogenesis stage as it is a significant factor. According to the Moorrees *et al.* classification system for stages of root development,<sup>[6]</sup> the key stages for auto-transplantation are  $\frac{1}{2}$  to  $\frac{3}{4}$  of root formed;<sup>[7]</sup> therefore, extraction is performed without harming Hertwig's epithelial sheath of such germs. Nevertheless, some authors suggest that donor teeth should be at a development level higher than three-fourth of root's length.<sup>[8]</sup> The best result can be anticipated with a transplant tooth that has a full length developed roots, but with potential for pulp regeneration (apex opening  $>1$  mm radiographically).

For best esthetic and occlusal results, it is necessary to transplant donor tooth from the same jaw and the same site (e.g., damaged first right molar is best to be replaced with third right wisdom tooth). Therefore, after successful transplantation, there would be no

**Table 1: The number of transplanted teeth distributed according to recipient site**

Transplanted tooth	Recipient sites			
	No. 16	No. 26	No. 36	No. 46
No. 18	—	—	—	1
No. 28	—	2	2	—
No. 38	—	—	4	—
No. 48	—	—	—	6

need for additional restorative treatment. In cases of mandibular recipient site narrowing (as a result of long-lasting crownless damaged tooth), donor tooth from the opposite jaw (as its parameters are often smaller) or additional trimming may be a better choice.

## CASE REPORTS

To introduce this surgical technique we present four clinical cases.

In general, patients for wisdom tooth germ auto-transplantation were chosen according to favorable characteristics: Co-operative young patient (preferably 15-20 years), no contributory systematic disease, permanent molar tooth with severe caries destruction that is considered to be extracted, third molars with incomplete rhizogenesis.

### Case 1

This is a 15-year-old female patient presented with severe destruction of the crown of tooth no. 46. Panoramic radiograph revealed periapical lesion in the region of tooth no. 46 and an impacted tooth no. 48 with radiographically formed bifurcation and roots developed  $\frac{1}{2}$  of the total length. After clinical and radiographic examination it was decided that tooth no. 48 is suitable for transplantation. Tooth no. 46 was extracted and the lesion was meticulously cleaned. 3 weeks after extraction tooth no. 48 was transplanted.

### Case 2

An 18-year-old male patient was referred to the Oral and Maxillofacial Surgery Department for a possible transplantation of a wisdom tooth replacing extraction due to fracture of tooth no. 46. After examination of 3 weeks post-extraction socket, it was discovered that bony walls were intact, no signs of inflammation of surrounding tissue or periapical lesion was found. Patient had a donor tooth no. 48 with  $\frac{3}{4}$  of root length developed and suitable for transplantation.

### Case 3

An 18-year-old female with severe caries destruction of the crown in tooth no. 26 was referred. Clinical examination revealed pain with vertical percussion of the damaged tooth. Panoramic radiograph showed periapical lesion. According to radiographic and clinical data, it was decided to extract tooth no. 26 and immediately replace it with a transplant. After evaluation of the recipient site and measurements of possible transplants, tooth no. 18 was chosen for transplantation.

### Case 4

A 15-year-old female patient was referred to a surgeon for extraction of roots of tooth no. 36. Radiographic and clinical examination revealed favorable clinical situation for immediate transplantation of tooth no. 38.

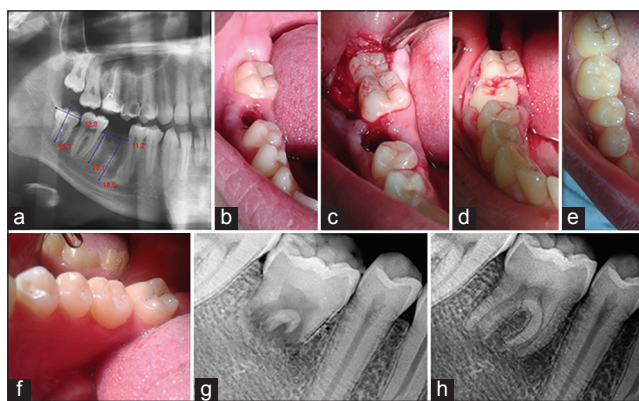
All auto-transplantation procedures were performed following established surgical protocol. Prior to operation sufficient local anesthesia and a mouth-rinse of chlorhexidine 0.02% for at least 1 min were obtained. The tooth at the recipient site is then sectioned with a bur and extracted preserving alveolar bone. Recipient socket is prepared considering measurements of donor tooth germ from panoramic radiograph, — removal of the inter-radicular septum, trimming of neighboring teeth crowns in case of the recipient site narrowing is performed. Next, the donor tooth is carefully removed. In cases of total impaction, flap elevation, bone removal, tooth germ careful removal with the follicle around the crown is performed. When a donor tooth is erupted, careful circumcising around the tooth is made before luxation and gentle extraction preserving as much periodontal ligament (PDL) as possible, as it is imperative for tooth integration at the recipient site. [9] Once removed, donor tooth is stored in its original socket until further adjustment of recipient socket are performed. A donor tooth should be handled as little as possible with a minimal delay between extraction and transplantation in order to ensure periodontal membrane vitality.

After transplanted tooth is in its final position, it is stabilized with a criss-cross suture and it is fixed to adjacent teeth with light polymerizing resin and wire splint in slight infra-occlusion. A proper vertical position of the tooth is essential to allow it to erupt and fit into occlusion over the next few months. The transplanted tooth should not contact with opposing teeth during 1<sup>st</sup> month until it acquires physiological mobility. When donor tooth is positioned in occlusal level during operation (due to root full length development) a temporal bite raise using light cured resin on neighboring teeth is needed to secure transplanted tooth immobility.

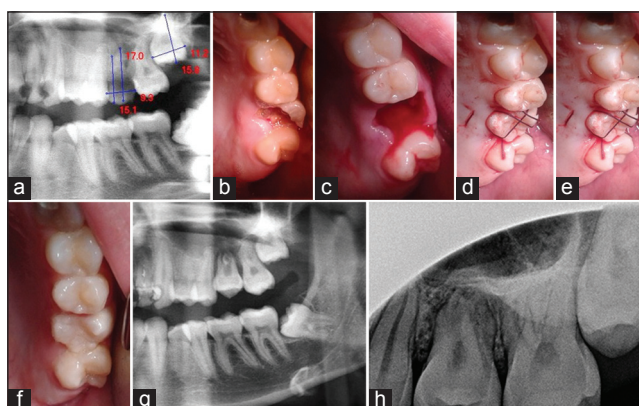
After operation, antibiotics (amoxicillinum 0.5 × 3/day), analgesia and anti-inflammatory drugs (nimesulidum 0.1 × 1/day) as well as soft food diet and hygiene recommendations are prescribed. First follow-up is carried out in 2 weeks for suture removal and in 4

weeks splint removal, periodontal probing, marginal gingiva and tooth mobility assessment was done. Tooth mobility was classified as grade I — slightly more than normal, grade II — moderately more than normal, grade III — severe mobility facio-lingually and mesio-distally combined with vertical displacement.<sup>[10]</sup> Radiographic examination is done in 1, 3 and 6 months and additional sensitivity test to cold in 6 months post-operation.

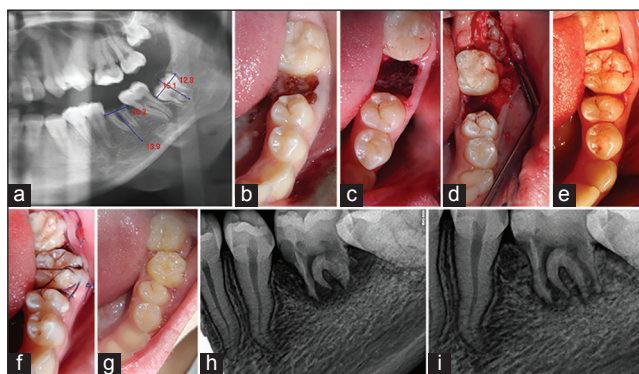
The survival rate was 87% because two patients had lost their transplants. One failure occurred, 2 weeks after operation, due to loss of initial sutures that ensure tight gingival contact with a tooth, stability and prevent bacterial invasion into the blood clot between the tooth and socket. Another case was lost due to persisting infection in peri-apical tissue during transplantation resulting in fistula formation 1 month post-operation. Other 12 transplants showed moderately more than normal (grade II) tooth mobility 1 month post-operation with the surrounding gingiva similar to that of the adjacent teeth and normal probing depth; therefore, the splints were removed. Whereas, in one case tooth mobility was grade II-III with a slightly deeper pocket (5 mm) buccally during this follow-up. This tooth was left splinted for two more weeks. At 3 months post-operation, radiographic examination showed normal healing of recipient alveolus without tooth resorption signs in all 12 cases. 6 months after transplantation, all transplants were slightly more mobile than normal (grade I). On radiographs, a physiological periodontal space around the transplanted teeth and continuous root development was present. Tooth sensitivity to cold was similar to neighboring teeth. In 9 months follow-up, patients had no discomfort or any complaints about their transplants. Objectively, teeth that were positioned in occlusal level during operation (with root development  $\frac{3}{4}$  or full length [Figure 2]) were fully functional with correct contacts when checked with marking paper in 1 month post-operation after splint and temporal bite-raise on neighboring teeth were removed. Teeth that were positioned in slight infra-occlusion during operation had minimal contacts with opposing tooth in 3 and fully contacted in 6 months post-operation [Figures 3-4]. Transplants that were deeply positioned in the recipient site due to incomplete root development ( $\frac{1}{2}$  of full root length) were still below occlusal line in 9 months post-operation, but with the presence of continuing root development [Table 2].



**Figure 2:** (a) Panoramic radiograph pre operation (b) recipient site 3 weeks after extraction (c) socket preparation and donor tooth extraction (d) donor tooth positioning (e) 1 month post-operation lingual and occlusal view (f) 1 month post-op lingual and occlusal view (g) radiograph 3 months post-operation (h) radiograph 9 months post-operation



**Figure 3:** (a) Panoramic radiograph (b) severely damaged 26 tooth (c) recipient site after extraction (d) donor tooth positioning (e) transplanted tooth fixation with sutures and wire-resin splint (f) 1 month post-operation (g) radiograph 3 months post-operation (h) radiograph 6 months post-operation



**Figure 4:** (a) Panoramic radiograph (b) roots of tooth (c) recipient site after extraction and preparation (d) donor tooth extraction (e) donor tooth positioning (f) transplanted tooth fixation (g) clinical situation 1 month post-operation (h) radiograph 3 months post-operation (i) radiograph 9 months post-operation

**Table 2: Donor teeth root development stage at the time of transplantation**

Root development level (of a total length)	1/2	3/4	1
Number	2	7	6

## DISCUSSION

After analyzing our cases that failed and literature data, we came to the conclusion that the main post-operation factor for success is stability of a transplant. Although, according to some authors rigid splinting and complete immobilization of the tooth stimulates tooth resorption,<sup>[5]</sup> in our cases, we used rigid splinting in order to protect transplant from undesirable movement during chewing and trauma. Splinting was kept within oral cavity until donor tooth stabilization showing moderately more mobility than physiological but not until complete immobilization, which could be a favorable factor influencing procedure success.<sup>[11-13]</sup> Moreover, in radiographs following 9 months post-operation, in all cases, a continuous periodontal space without any ankylosis or root resorption was present. From a failed case, we learned that initial suturing securing tight gingival contact with a tooth is of great importance as well. Considering the timing, it may be concluded that the best situation for transplantation is transplants with almost full root development and open apices. In these cases, the tooth is positioned in occlusal level. Though it causes some inconvenience for the patient during tooth stabilization due to temporal bite-raise, no additional restorative or orthodontic treatment is needed after its final healing. The period of proper root development stage should be evaluated strictly considering donor tooth radiographic data since patients age is an inadequate indicator. Another crucial factor for transplantation is the recipient site thorough investigation. On one hand, transplantation should be performed within 2-6 weeks after tooth extraction in the recipient site due to extensive bone resorption that occurs 6 weeks after extraction.<sup>[8]</sup> On the other hand, incomplete cleaning of periapical lesion after tooth extraction may lead to persisting infection in the recipient site even in 2 weeks post-extraction. We concluded that this was the possible reason of fistula formation and transplant loss in one of our cases. Therefore, it is imperative to evaluate periapical tissue and possible lesion presence before extraction, apply thorough cleaning and curettage of granulation tissue of the recipient site and even

consider possible antibiotic prescription after extraction in cases of severe inflammation and bone destruction due to infection.

In general, according to our results, it is clear that tooth auto-transplantation is a proper therapeutic option that can be carried out appropriately with best results and it is not more technique demanding than widely acceptable osseointegrated implants used to replace missing teeth. Since both treatment methods have high prognosis, transplants are recommended to those who have appropriate donor teeth and may have limited financial capabilities. Nevertheless, post-surgical restorative options are generally much simpler for transplanted teeth.<sup>[8]</sup>

It is determined that young patients with missing teeth can be treated using dental implants only after growth has ceased. Otherwise, osseointegrated implant would not erupt with adjacent teeth and it would result in infraocclusion causing functional and esthetic problems. It may even disturb jaw growth causing skeletal discrepancies. Meanwhile, transplants erupt gradually with neighboring teeth inducing subsequent bone formation in transplanted area. In cases of unrestorable teeth requiring extraction with an appropriate donor tooth present, tooth auto-transplantation may be a better choice compared with implantation. Such patients acquire a new tooth immediately after transplantation avoiding esthetical defect. Moreover, a transplant is more esthetical than any restoration due to natural enamel beauty and maintained emergence profile. Regarding osteoinducing properties of transplanted teeth, bony defect regeneration around it without additional grafting materials<sup>[8]</sup> as well as normal interdental papilla formation is obtained after procedure. In addition, compared to implants, it is a significantly time and cost reducing procedure. Moreover, many studies indicate that esthetic results for single implant replacement in the anterior region is often suboptimal.<sup>[13]</sup> Therefore, in such cases, auto-transplantation may be an easier method for obtaining ideal marginal contour and perfect esthetic result. Tooth transplantation may be also considered as a temporary measure. The transplant would immediately replace the missing tooth, therefore, preventing neighboring teeth from tilting toward edentulous space and preserving bone until implantation is possible (due to physiological or economic reasons).

Regarding all the benefits of tooth transplantation,

each case should be evaluated individually to assess if transplantation is the best choice. It is necessary to emphasize that auto-transplantation should be considered as tooth replacement treatment method for patients with appropriate donor teeth. Adult patients with fully developed teeth would need root canal treatment and a sequential crown restoration after transplantation as revascularization and pulp revitalization through closed root apices is hardly possible.<sup>[14]</sup> Ultimately, improper choice of patients for tooth auto-transplantation would be even more time and cost demanding treatment than other alternatives (implants, prosthetic bridges, dentures).

## CONCLUSION

All our cases of transplantation with a follow-up period of 9 and more months are considered as success, but still need to be followed for some time. Considering the bone induction, PDL maintenance with following pressure sensitivity properties and tooth vitality, tooth auto-transplantation is a technique and timing sensitive operation that should be provided for only carefully selected patient to ensure perfect results and all possible benefits. Therefore, tooth auto-transplantation can be considered as a possible treatment choice for children over 16 years old and as a supplementary treatment method for young adults.

## REFERENCES

1. Baseggio W, Naufel FS, Davidoff DC, Nahsan FP, Flury S, Rodrigues JA. Caries-preventive efficacy and retention of a resin-modified glass ionomer cement and a resin-based fissure sealant: A 3-year split-mouth randomised clinical trial. *Oral Health Prev Dent* 2010;8:261-8.
2. Bolin AK, Bolin A, Jansson L, Calltorp J. Children's dental health in Europe. *Swed Dent J* 1997;21:25-40.
3. Gill DS, Lee RT, Tredwin CJ. Treatment planning for the loss of first permanent molars. *Dent Update* 2001;28:304-8.
4. Nimčenko T, Omerca G, Varinauskas V, Bramanti E, Signorino F, Cicciù M. Tooth auto-transplantation as an alternative treatment option: A literature review. *Dent Res J (Isfahan)* 2013;10:1-6.
5. Ogawa R, Saito C, Jung HS, Ohshima H. Capacity of dental pulp differentiation after tooth transplantation. *Cell Tissue Res* 2006;326:715-24.
6. Moorrees CF, Fanning EA, Hunt EE Jr. Age variation of formation stages for ten permanent teeth. *J Dent Res* 1963;42:1490-502.
7. Schmidt SK, Cleverly DG. Tooth autotransplantation: An overview and case study. *Northwest Dent* 2012;91:29-33.
8. Tsukiboshi M. Autotransplantation of teeth: Requirements for predictable success. *Dent Traumatol* 2002;18:157-80.
9. Nethander G. Periodontal conditions of teeth autogenously transplanted by a two-stage technique. *J Periodontal Res* 1994;29:250-8.
10. Vilhjálmsson VH, Knudsen GC, Grung B, Bårdsen A. Dental auto-transplantation to anterior maxillary sites. *Dent Traumatol* 2011;27:23-9.
11. Kawanami M, Sugaya T, Gama H, Tsukuda N, Tanaka S, Kato H. Periodontal healing after replantation of intentionally rotated teeth with healthy and denuded root surfaces. *Dent Traumatol* 2001;17:127-33.
12. Kallu R, Vinckier F, Politis C, Mwalili S, Willems G. Tooth transplantations: A descriptive retrospective study. *Int J Oral Maxillofac Surg* 2005;34:745-55.
13. Burbridge L, Cole BO, Hobson RS, Welbury RR. Auto-transplantation in the restorative management of traumatized anterior teeth: A case report. *Dent Update* 2005;32:529-30, 532.
14. Czochrowska EM, Stenvik A, Bjercke B, Zachrisson BU. Outcome of tooth transplantation: Survival and success rates 17-41 years posttreatment. *Am J Orthod Dentofacial Orthop* 2002;121:110-9.

**How to cite this article:** Nimcenko T, Omerca G, Bramanti E, Cervino G, Laino L, Cicciù M. Autogenous wisdom tooth transplantation: A case series with 6-9 months follow-up. *Dent Res J* 2014;11:705-10.

**Source of Support:** Nil. **Conflict of Interest:** None declared.