



Use of a Head-Tilting Baseplate During Tomotherapy to Shorten the Irradiation Time and Protect the Hippocampus and Lens in Hippocampal Sparing-Whole Brain Radiotherapy

Technology in Cancer Research & Treatment
Volume 20: 1-5
© The Author(s) 2021
Article reuse guidelines:
sagepub.com/journals-permissions
DOI: 10.1177/1533033820986824
journals.sagepub.com/home/tct


Kosei Miura, MD^{1,2}, Hiromasa Kurosaki, MD, PhD¹ ,
Nobuko Utsumi, MD, PhD¹, and Hideyuki Sakurai, MD, PhD²

Abstract

Purpose: The aim of this study is to comparatively examine the possibility of reducing the exposure dose to organs at risk, such as the hippocampus and lens, and improving the dose distribution of the planned target volume with and without the use of a head-tilting base plate in hippocampal-sparing whole-brain radiotherapy using tomotherapy. **Methods:** Five paired images of planned head computed tomography without and with tilt were analyzed. The hippocampus and planning target volume were contoured according to the RTOG 0933 contouring atlas protocol. The hippocampal zone to be avoided was delineated using a 5-mm margin. The prescribed radiation dose was 30 Gy in 10 fractions. The absorbed dose to planning target volume dose, absorbed dose to the organ at risk, and irradiation time were evaluated. The paired t-test was used to analyze the differences between hippocampal-sparing whole-brain radiotherapy with head tilts and without head tilts. **Results:** Hippocampal-sparing whole-brain radiotherapy with tilt was not superior in planning target volume doses using the homogeneity index than that without tilt; however, it showed better values, and for D_{mean} and $D_{2\%}$, the values were closer to 30 Gy. Regarding the hippocampus, dose reduction with tilt was significantly greater at D_{max} , D_{mean} , and D_{min} , whereas regarding the lens, it was significantly greater at D_{max} and D_{min} . The irradiation time was also predominantly shorter. **Conclusion:** In our study, a tilted hippocampal-sparing whole-brain radiotherapy reduced the irradiation time by >10%. Therefore, our study indicated that hippocampal-sparing whole-brain radiotherapy with tomotherapy should be performed with a tilt. The head-tilting technique might be useful during hippocampal-sparing whole-brain radiotherapy. This method could decrease the radiation exposure time, while sparing healthy organs, including the hippocampus and lens.

Keywords

tomotherapy, hippocampal sparing, whole brain radiotherapy, brain metastases

Abbreviations

CT, Computed tomography; DIR, Deformable image registration; D_x , Dose covering X% of the volume; HI, Homogeneity index; HS-WBRT, Hippocampal-sparing whole-brain radiotherapy; IMRT, Intensity-modulated radiotherapy; NCR, Non-coplanar radiation; OAR, Organ at risk; PTV, Planning target volume; VMAT, Volumetric modulated arc therapy; WBRT, Whole-brain radiotherapy

Received: August 13, 2020; Revised: November 10, 2020; Accepted: December 14, 2020.

¹ Department of Radiation Therapy, JCHO Tokyo Shinjuku Medical Center, Tokyo, Japan

² Department of Radiation Oncology and Proton Medical Research Center, University of Tsukuba, Ibaraki, Japan

Corresponding Author:

Hiromasa Kurosaki, Department of Radiation Therapy, JCHO Tokyo Shinjuku Medical Center, Tokyo 1628764, Japan.

Email: kuro@hmsk.org






Figure 1. Images of the base plate: (A) without tilt and (B) with tilt.

Introduction

The use of whole-brain radiotherapy (WBRT) for treating multiple brain metastases gives rise to the concern that WBRT may result in advanced brain dysfunction. Owing to the recent advances in molecularly targeted drug therapies and stereotactic irradiation, a policy of withholding whole-brain irradiation until the time of relapse, has been implemented on a case-by-case basis. In contrast, recent advances in radiation therapy have allowed the application of intensity-modulated radiation therapy (IMRT) in clinical practice, with the hippocampal-sparing WBRT (HS-WBRT) trial (RTOG0933) being conducted. The use of IMRT reportedly resulted in a reduction of advanced functional impairment compared to the use of normal WBRT.¹ In the NRG Oncology CC001 trial with memantine, HS-WBRT was also reported to have a lower risk of memory loss and to impair the executive function and learning ability than regular WBRT.²

Initially, it was proposed that HS-WBRT be performed using the linac-based IMRT in 9-field irradiation or helical tomotherapy.³ Notably, the method of performing IMRT is also evolving, and the main technique is changing from multi-irradiation IMRT to volumetric modulated arc therapy (VMAT). VMAT can be used to enhance HS-WBRT similar to both the IMRT modalities.^{4,5}

Recently, it has been reported that VMAT HS-WBRT with tilt results in improved dose distribution as well as lowered doses in the organs at risk (OARs), such as the hippocampus and lens, than those without tilt.⁶ In this study, we investigated whether the line distribution in the planning target volume (PTV) dose distribution map could be improved, whether the dose to the OARs could be lowered, and whether there are other benefits such as reduction in the irradiation time when performing HS-WBRT with a head tilt, which have not been previously established in the literature.

Materials and Methods

The radiotherapy equipment used was TomoHDA (Accuray Incorporated, CA, USA), and the radiotherapy planning equipment was TomoTherapy Planning Station (Accuray

Incorporated). The contouring and deformable image registration (DIR) software used was RayStation (DIR algorithm: Hybrid intensity and structure-based, Ray Research Laboratories, Stockholm, Sweden). For the tilt-type head and neck fixture for radiotherapy, MT2013CF with a carbon fiber tilting baseplate (CIVCO Radiotherapy, IA, USA) was used, and for treatment-planning computed tomography (CT), Aquarion LB (Toshiba, Nasushiobara, Japan) was used. Images of the base plate with and without tilt are shown in Figure 1.

Five paired images of planned head CT performed on the same day without and with tilt, following magnetic resonance imaging (MRI), were obtained in this study. We obtained CT images of 1-mm slice thickness and 1-mm axial MRI scans of the brain with T2-weighted and gadolinium contrast-enhanced T1-weighted sequence acquisitions. The angles of these 5 paired images were 26.4°, 29.6°, 39.8°, 40.8°, and 48.7°, respectively, and were unrelated to the angle of the base plate.

OARs, including the hippocampus, optic nerve, optic chiasm, eye, and lens, were contoured by an experienced radiation oncologist. The hippocampus and PTV were contoured according to the RTOG 0933 contouring atlas protocol. The hippocampal zone to be avoided was delineated with a 5-mm margin. Contouring was performed with MRI scans using the RayStation software, which was then converted to CT images, owing to which, we replicated the same PTV and OAR with/without tilt on CT images. Optimization was done with TomoTherapy Planning Station, as given in Table 1. The jaw size was calculated to be 1 cm with the modulation factor = 3.0 and pitch = 0.200 cm.

The prescribed radiation dose was 30 Gy in 10 fractions and was normalized at the isodose line, covering 95% of the PTV. We reviewed whether the dose constraints (Table 2) presented in RTOG0933 were followed, and accordingly, the absorbed dose to PTV, absorbed dose to OAR, and irradiation time were evaluated. The homogeneity index (HI) was defined as follows: $HI = (D_{2\%} - D_{98\%}) / D_{50\%}$ according to ICRU83.

The paired t-test was used to analyze the differences between HS-WBRT with and without tilts. A p-value < 0.05

Table 1. Optimization Constraints.

	Block type	Max dose	DVH volume/dose	Importance and penalty
Hippocampus	Unblocked	15Gy	D _{50%} = 8.0 Gy	200
Lenses	Directional	2.5Gy	D _{70%} = 1.5 Gy	40
Eyes	Directional	3.0Gy	D _{50%} = 2.0 Gy	20
Optic chiasm	Unblocked	30Gy	D _{50%} = 30 Gy	20
Optic nerves	Unblocked	30Gy	D _{50%} = 25 Gy	20
External	Unblocked	30Gy	D _{10%} = 5.0 Gy	1

D_{95%} = 30 Gy in 10 fractions.
 Jaw size: 1 cm, modulation factor = 3.0, pitch = 0.200 cm.
 DVH, dose–volume histogram.

Table 2. Dose Constraint.

	RTOG0933 protocol
Planning target volume	D _{98%} ≥ 25 Gy D _{2%} ≤ 37.5 Gy
Hippocampus	D _{min} ≤ 9 Gy
Optic nerves and chiasm	D _{max} ≤ 16 Gy D _{max} ≤ 37.5 Gy

Table 3. Comparison of Dosimetric and Radiation Time Parameters Without and With Head Tilt.

Structure	Index	Without tilt	With tilt	P value
Planning target volume	D _{98%}	26.77 ± 0.51 Gy	27.04 ± 0.88 Gy	0.26
	D _{mean}	31.16 ± 0.48 Gy	30.51 ± 0.14 Gy	0.02
	D _{2%}	32.68 ± 0.40 Gy	31.88 ± 0.21 Gy	0.006
	Homogeneity index	0.19 ± 0.02	0.16 ± 0.03	0.06
Hippocampus	D _{min}	6.65 ± 0.27 Gy	5.90 ± 0.09 Gy	0.002
	D _{mean}	8.85 ± 0.35 Gy	7.97 ± 0.24 Gy	0.004
	D _{max}	15.06 ± 0.66 Gy	13.95 ± 0.33 Gy	0.03
Lens	D _{min}	2.25 ± 0.22 Gy	1.45 ± 0.08 Gy	0.002
	D _{max}	2.71 ± 0.26 Gy	1.80 ± 0.19 Gy	0.002
Irradiation time		1517 ± 86 s	1328 ± 89 s	0.002

was considered statistically significant. All statistical analyses were performed using Microsoft Excel 2019 software package (Microsoft, WA, USA).

Results

Both plans, with and without tilt, adhered to the dose constraints, as displayed in Table 3, and showed good target coverage and hippocampal sparing, as demonstrated in Figure 2. An example of the dose–volume histogram is shown in Figure 3. Significant differences were noted in D_{mean} and D_{2%}. In terms of the PTV dose, better values were obtained for HI in HS-WBRT with tilt but no significant differences were seen. Thus, HS-WBRT with tilt was judged to have a superior dose distribution in PTV than HS-WBRT without tilt. Regarding the hippocampus, dose reduction with tilt was significantly greater at D_{max} (p = 0.03), D_{mean} (p = 0.004), and D_{min} (p = 0.002), whereas regarding the lens, both at D_{max} (p = 0.002) and D_{min} (p = 0.002), dose reduction was significantly less in HS-WBRT with tilt than in that without tilt.

As for the irradiation time, HS-WBRT with tilt was significantly shorter than that without tilt (Table 4). A comparison between the pairs showed that the irradiation time was shortened by 8–18% in all pairs.

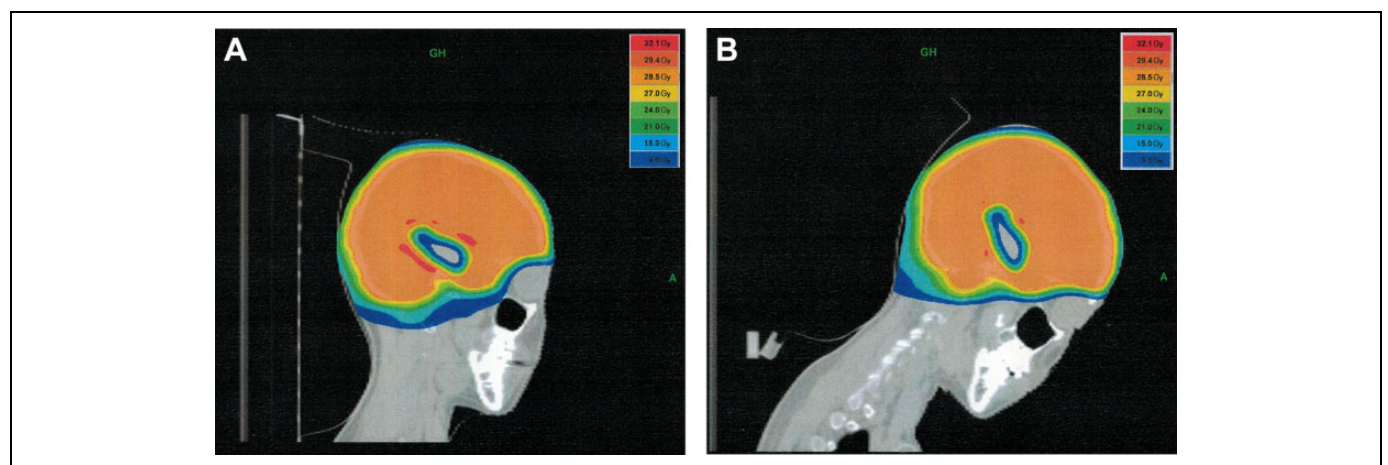


Figure 2. Representation of dose distribution in the sagittal view (Case 2). (A) without tilt and (B) with tilt.

Discussion

For HS-WBRT, we followed the RTOG0933 protocol, with the 9-field non-coplanar IMRT technique proposed by Gondi et al, or performed helical tomotherapy.³ IMRT with a couch angle results in irradiation in non-coplanar radiation (NCR). This would increase the irradiated volume but would provide a better dose distribution for PTV and OAR. Tomotherapy has a fixed gantry. It is also a dedicated

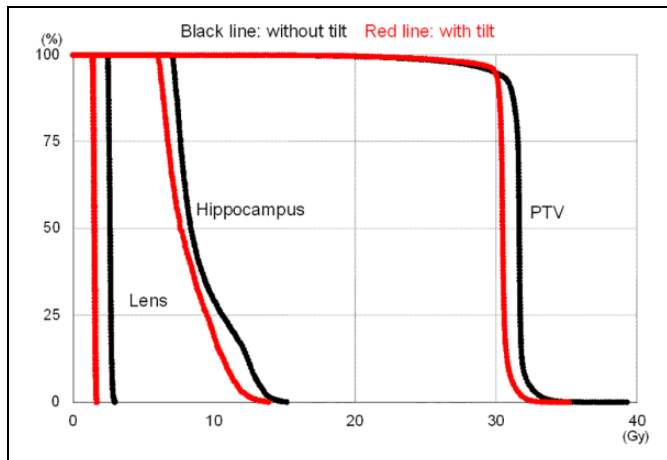


Figure 3. Example of a dose–volume histogram (case 3).

Table 4. Irradiation Time for Each Pair.

Case	Angle	Without tilt	With tilt	Time with tilt/time without tilt
1	26.4°	1639 s	1502 s	0.92
2	29.6°	1375 s	1260 s	0.92
3	39.8°	1492 s	1297 s	0.87
4	40.8°	1549 s	1268 s	0.82
5	48.6°	1530 s	1316 s	0.86

Angle: With and without tilt calculated using RayStation.

helical IMRT modality for coplanar irradiation, which is delivered in an axial cross-sectional view at the time of treatment-planning CT. Yuasa and Kurosaki has studied the basics of NCR with tomotherapy using a head and neck patient fixator with a tilt mechanism and DIR.⁷

Lee et al reported that patient setup is not only important for the reproducibility of all radiation therapy treatment plans but also affects dose distribution.⁴ Oh et al had previously reported a lower lens dose in VMAT with tilt.⁶ In our study, the same results were obtained for tomotherapy. This is thought to be because the tilt allows the lens to be placed outside the irradiated volume.

During the evaluation of PTV, there was no significant difference in $D_{98\%}$ and HI, but D_{mean} and $D_{2\%}$ showed better results with the tilt. This is because without the tilt, the hippocampus and the eye are at the same level, and the IMRT plan must be calculated such that the dose distribution is balanced in both the regions. In contrast, the tilt plan provided a better dose distribution because the hippocampus and eyeballs were located at different cross-sections.

Gondi et al reported that, on average, helical tomotherapy offered greater hippocampal sparing than linac-based IMRT in terms of D_{mean} , D_{median} , and D_{max} . They also reported the benefit of tomotherapy for linac-based IMRT.³ Lee et al compared between linac-based IMRT and VMAT⁴ and reported sufficient control of the dose to the hippocampal area on both IMRT and VMAT; however, better uniformity was achieved with VMAT.

To the best of our knowledge, there has been no study on the direct comparison of tomotherapy with VMAT. The data of previous reports and our report are summarized in Table 5.^{3-6,8-10} For PTV, Shen et al reported an HI of 0.30 for HS-WBRT with VMAT,⁸ and Sood et al reported an HI of 0.179 for HS-WBRT without tilt and 0.167 for that with tilt.⁵ These values are consistent with those in our study, i.e. 0.18 without tilt and 0.16 with tilt. Previous reports about hippocampus D_{max} dose indicate an approximate dose of 15 Gy and a D_{min} of 8–9 Gy, while in tomotherapy with tilt, the dose distribution was better at a D_{max} of 13.95 Gy and a D_{min} of 5.90 Gy. Normal brain cells have a

Table 5. Report of Hippocampal Dose in Hippocampal Sparing-Whole Brain Radiotherapy.

	Tilting	Dmin	Dmean	Dmax
Volumetric modulated arc therapy				
Sood (n = 10)		8.4 ± 0.3 Gy		15.6 ± 0.4 Gy
Shen (n = 20)		8.5 ± 0.2 Gy		15.7 ± 0.3 Gy
Prokic (n = 10)*			7.15 ± 0.58 Gy	
Oh (n = 20)	Without tile		10.36 ± 0.29 Gy	15.21 ± 0.67 Gy
	With tile		9.91 ± 0.30 Gy	15.12 ± 0.74 Gy
Lee (n = 3)		9.6 ± 0.3 Gy	14.0 ± 0.8 Gy	20.7 ± 0.8 Gy
Jiang (n = 10)		8.3 ± 0.4 Gy	10.0 ± 0.6 Gy	15.8 ± 0.7 Gy
Tomotherapy				
Gondi (n = 5)			5.5 Gy	12.8 Gy
Jiang (n = 10)		7.6 ± 0.7 Gy	10.0 ± 0.7 Gy	15.5 ± 0.9 Gy
Our study (n = 5)	Without	6.65 ± 0.27 Gy	8.85 ± 0.35 Gy	15.06 ± 0.66 Gy
	With	5.90 ± 0.09 Gy	7.97 ± 0.24 Gy	13.95 ± 0.33 Gy

*Prokic calculated at 30 Gy/12 fr.

smaller α/β ratio and, thus, greater radiosensitivity is seen with high-dose radiation. With the α/β ratio equaling 2.1 at the D50 set in the hippocampus, the biological effective dose and the equivalent dose in the 2-Gy fraction were 12.6 and 6.44 Gy and 11.0 and 5.63 Gy for the non-tilted and tilted groups, respectively. Regarding the lenses, Oh et al reported a D_{\max} of 7.78–8.08 Gy without tilt and 3.81–3.92 Gy with tilt.⁶ However, these values are higher than those in our study, i.e. 2.79 ± 0.13 Gy and 1.89 ± 0.19 Gy, respectively, indicating that the dose distribution for PTV does not change, but for the hippocampus and lens, tomotherapy is more useful than VMAT.

The small sample size of 5 can be considered as a limitation of this study; hence, a larger cohort would need to be examined. However, our study used 2 pairs of CT images taken on the same day to construct a common PTV and OAR using the RayStation software, which not only has a useful DIR algorithm¹¹ but also can evaluate 2 CT images.⁷

The tilting technique enables not only improved dose distribution but also reduced irradiation time. This is possibly affected by the tilting technique by situating the lenses away from the irradiated area. Thus, the treatment plan was optimized. Furthermore, the long irradiation time of HS-WBRT by tomotherapy has been a long-standing problem. Gutiérrez et al reported that the irradiation time was 21.8 ± 1.8 minutes for HS-WBRT carried out by tomotherapy with a simultaneously integrated boost (fraction dose = 2.15 Gy, boost dose = 4.2 or 4.72 Gy).¹² However, Shen et al using VMAT reported 121 seconds⁸ and Sood et al reported 2.3 minutes.⁵ Thus, VMAT has an overwhelming advantage in this respect compared with tomotherapy, which takes more than 20 minutes. Gutiérrez et al reported that using a 2.5-cm jaw cuts the exposure time in half.¹² In the future, it is hoped that HS-WBRT with a tilt will be examined with 2.5- and 5-cm jaws.

Conclusion

In our study, a tilted HS-WBRT reduced the irradiation time by >10%. Therefore, our study indicated that when performing HS-WBRT with tomotherapy, it should be performed with a tilt. The head-tilting technique might be useful for HS-WBRT planning with not only VMAT but also tomotherapy. This method could decrease the radiation time while sparing healthy organs, including the hippocampus and lens.

Acknowledgments

We would like to acknowledge the help of Mr. Akihiko Ishibashi, BS at the Department of Radiology, JCHO Funabashi Central Hospital. We would like to thank Editage (www.editage.com) for English language editing.


Declaration of Conflicting Interests

The author(s) declared no potential conflicts of interest with respect to the research, authorship, and/or publication of this article.

Funding

The author(s) received no financial support for the research, authorship, and/or publication of this article.

ORCID iD

Hiromasa Kurosaki  <https://orcid.org/0000-0003-4295-6118>

References

- Gondi V, Pugh SL, Tome WA, et al. Preservation of memory with conformal avoidance of the hippocampal neural stem-cell compartment during whole-brain radiotherapy for brain metastases (RTOG 0933): a phase II multi-institutional trial. *J Clin Oncol*. 2014;32(34):3810-3816. doi:10.1200/JCO.2014.57.2909
- Brown PD, Gondi V, Pugh S, et al. Hippocampal avoidance during whole-brain radiotherapy plus memantine for patients with brain metastases: phase III trial NRG oncology CC001. *J Clin Oncol*. 2020;38(10):1019-1029. doi:10.1200/JCO.19.02767
- Gondi V, Tolakanahalli R, Mehta MP, et al. Hippocampal-sparing whole-brain radiotherapy: a “how-to” technique using helical tomotherapy and linear accelerator-based intensity-modulated radiotherapy. *Int J Radiat Oncol Biol Phys*. 2010;78(4):1244-1252. doi:10.1016/j.ijrobp.2010.01.039
- Lee K, Lenards N, Holson J. Whole-brain hippocampal sparing radiation therapy: volume-modulated arc therapy vs intensity-modulated radiation therapy case study. *Med Dosim*. 2016;41(1):15-21. doi:10.1016/j.meddos.2015.06.003
- Sood S, Pokhrel D, McClinton C, et al. Volumetric-modulated arc therapy (VMAT) for whole brain radiotherapy: not only for hippocampal sparing, but also for reduction of dose to organs at risk. *Med Dosim*. 2017;42(4):375-383. doi:10.1016/j.meddos.2017.07.005
- Oh SA, Yea JW, Park JW, Park J. Use of a head-tilting baseplate during volumetric-modulated arc therapy (VMAT) to better protect organs at risk in hippocampal sparing whole brain radiotherapy (HS-WBRT). *PLoS One*. 2020;15(4):1-11. doi:10.1371/journal.pone.0232430
- Yuasa M, Kurosaki H. Noncoplanar radiation using tomotherapy: a phantom study. *Technol Cancer Res Treat*. 2020;19. doi:10.1177/1533033820945776
- Shen J, Bender E, Yaparalvi R, et al. An efficient volumetric arc therapy treatment planning approach for hippocampal-avoidance whole-brain radiation therapy (HA-WBRT). *Med Dosim*. 2015;40(3):205-209. doi:10.1016/j.meddos.2014.11.007
- Prokic V, Wiedenmann N, Fels F, Schmucker M, Nieder C, Grosu AL. Whole brain irradiation with hippocampal sparing and dose escalation on multiple brain metastases: a planning study on treatment concepts. *Int J Radiat Oncol Biol Phys*. 2013;85(1):264-270. doi:10.1016/j.ijrobp.2012.02.036
- Jiang A, Sun W, Zhao F, et al. Dosimetric evaluation of four whole brain radiation therapy approaches with hippocampus and inner ear avoidance and simultaneous integrated boost for limited brain metastases. *Radiat Oncol*. 2019;14(1):1-8. doi:10.1186/s13014-019-1255-7
- García-Mollá R, de Marco-Blancas N, Bonaque J, Videira L, López-Tarjuelo J, Perez-Calatayud J. Validation of a deformable image registration produced by a commercial treatment planning system in head and neck. *Phys Med*. 2015;31(3):219-223. doi:10.1016/j.ejmp.2015.01.007
- Gutiérrez AN, Westerly DC, Tomé WA, et al. Whole brain radiotherapy with hippocampal avoidance and simultaneously integrated brain metastases boost: a planning study. *Int J Radiat Oncol Biol Phys*. 2007;69(2):589-597. doi:10.1016/j.ijrobp.2007.05.038