

Contents lists available at [ScienceDirect](#)

## International Journal of Surgery Case Reports

journal homepage: [www.casereports.com](http://www.casereports.com)Laparoscopic management of a strangulated internal hernia underneath the left external iliac artery<sup>☆</sup>

Karl-Andreas Dumont\*, Jan Cyril Wexels

Department of Surgery, Klinik Bærum Hospital, Vestre Viken, Postboks 83 1309 Rud, Norway

## ARTICLE INFO

## Article history:

Received 13 March 2013  
 Received in revised form 26 July 2013  
 Accepted 31 July 2013  
 Available online 17 September 2013

## Keywords:

Hernia  
 Iliac artery  
 Intestinal obstruction  
 Lymphadenectomy

## ABSTRACT

**INTRODUCTION:** Internal herniation of a small bowel behind pelvic vessels is a rare complication seen after pelvic lymphadenectomy.

**PRESENTATION OF CASE:** A 56-year-old woman was operated due to a gynecological cancer. 4 years thereafter she presented with a 2 days history of abdominal pain and vomiting. Clinical and radiological findings indicated a small bowel obstruction. A loop of small bowel had herniated behind the left external iliac artery. Using laparoscopic technique the herniated bowel was reduced. Due to limited peritoneum around the area and skeletonized vessel, we decided not to do any repair of the hernia orifice. The postoperative recovery was uneventful, bowel activity returned to normal and she was discharged the next day.

Follow-up was done at 1 month and the latest at 10 months. She didn't experience pain or discomfort after the operation.

**DISCUSSION:** Due to limited peritoneum around the skeletonized vessel, we decided to leave the hernia orifice unrepaired. We found it hazardous to do any direct suture of the orifice or use a free peritoneal graft to repair the defect as the fibrosis and inflammatory process might have compromised the artery or the vein. A longer follow-up of the patient is needed to clearly conclude if this simple procedure has been sufficient. We agreed that if the patient would experience any sign of recurrence and need another operation we would close the defect at that time.

**CONCLUSION:** 4 years after pelvic lymphadenectomy a small bowel herniation behind an external iliac artery occurred. The patient was successfully treated with reduction of the small bowel using laparoscopic technique. A quick recovery with minimal discomfort and no sign of recurrence after 10 months made our approach an acceptable surgical option.

© 2013 The Authors. Published by Elsevier Ltd on behalf of Surgical Associates Ltd. All rights reserved.

## 1. Introduction

Para-aortic and pelvic lymphadenectomy is often performed in the treatment of ovarian or testicular cancer.<sup>1,2</sup> Internal herniation of a small bowel behind the external iliac artery after lymphadenectomy is a very rare complication to this procedure and to our knowledge only reported twice in the literature.<sup>3,4</sup>

In the first paper published in 1978<sup>3</sup> the author described how they managed their patient with laparotomy and resection of a perforated small bowel. The hernia orifice was closed by using a free peritoneal graft harvested from the under surface of the anterior abdominal wall. Thereby they covered the aorta and iliac

arteries and the defect. This patient had to undergo several surgical procedures to re-establish blood flow to the extremity because of thrombosis of the iliac artery. The second case<sup>4</sup> reported underwent laparotomy and small bowel resection. Peritoneum was then closed over the artery to prevent recurrence of the hernia. As there are few similar cases reported worldwide, there is no consensus or guidelines available. We performed a laparoscopic reduction of the herniated bowel. We did not close the orifice. Because of the skeletonized vessel we were afraid of compromising the vessel if we tried to close the defect. At follow-up after 10 months the patient is doing well without any symptoms.

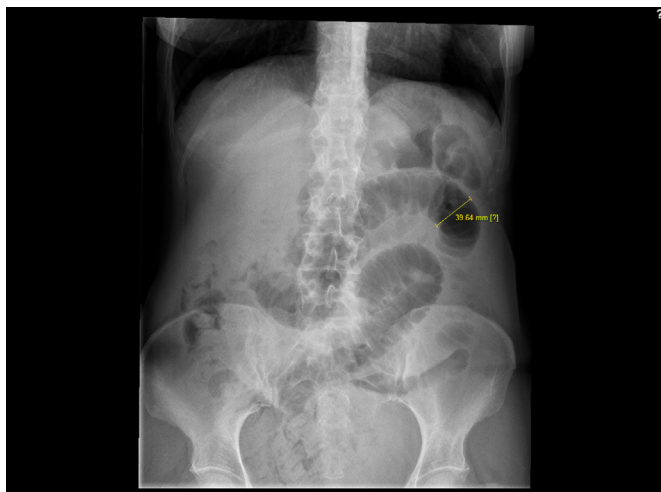
## 2. Presentation of case

A 56-year-old woman underwent in 2008 prophylactic bilateral laparoscopic salpingo-oophorectomy because of a mutation in BRCA1 gene. The histological result revealed a serous papillary adenocarcinoma in the right ovary and on its surface. Therefore a restaging operation was performed. She underwent laparotomy with total abdominal hysterectomy, omentectomy, appendectomy, with a radical retroperitoneal lymphadenectomy which involved

<sup>☆</sup> This is an open-access article distributed under the terms of the Creative Commons Attribution-NonCommercial-No Derivative Works License, which permits non-commercial use, distribution, and reproduction in any medium, provided the original author and source are credited.

\* Corresponding author. Present address: Department of Hepato-Pancreato-Biliary Surgery Rikshospitalet, Oslo University Hospital, Postboks 4950 Nydalen, 0424 Oslo, Norway. Tel.: +47 48297889.

E-mail addresses: [kardum@ous-hf.no](mailto:kardum@ous-hf.no), [karlsrufer@hotmail.com](mailto:karlsrufer@hotmail.com) (K.-A. Dumont), [jancyril.wexels@vestreviken.no](mailto:jancyril.wexels@vestreviken.no) (J.C. Wexels).



**Fig. 1.** Photograph of abdominal plain view showing obstructed small bowel loops.

“en bloc” dissection and removal of the para-aortic and iliac lymph nodes.

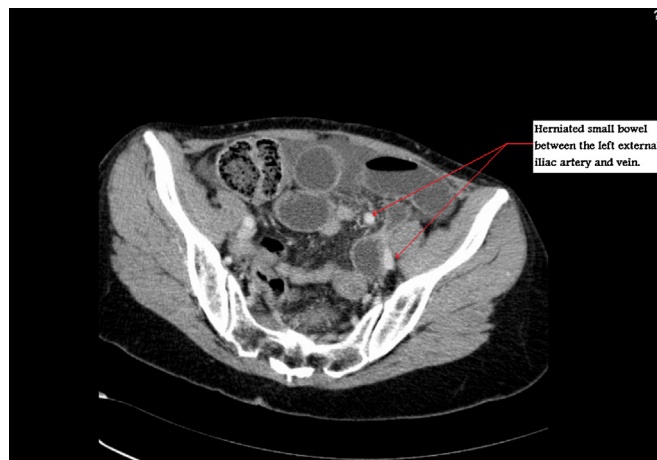
Peritonealization was not performed. The histology revealed adenocarcinoma and metastasis on the surface of the appendix. There was no metastasis in the biopsies taken from the rectum wall and the laparoscopy trocar ports as well as the 46 harvested lymph nodes. The postoperative stay was uneventful and she was discharged 6 days after surgery. She started with chemotherapy Carboplatin and Paclitaxel 2 months after the diagnosis. The patient did not receive any radiation therapy.

In 2012, 4 years later, she was admitted to hospital with a 2 days history of severe abdominal pain, vomiting and the inability to pass gas or stools for the last few days. She had never had similar symptoms before. The abdomen was distended, diffused tender and tympanitic, without guarding or rebound tenderness. Bowel sounds were high-pitched. Her groin examination was normal without any sign of herniation through the femoral or inguinal canals. We palpated pulsations at the groins and legs on both sides. Her rectal examination was normal without any sign of melena or hematochezia. Blood pressure 140/90 mmHg, pulse 71 beats/minute and a temperature of 37.9°C. CRP normal, WBC  $13 \times 10^{10}$  with a marked left shift. Blood gas was normal with a serum lactate of 1 mmol/L.

We initiated fluid substitution with a combination of Ringer Acetate and Sodium Chloride solutions. Admission abdominal radiographic findings were compatible with a small bowel obstruction (Fig. 1). A computerized tomography (CT) scan was performed. Our CT protocol for evaluating mechanical ileus is performed with i.v. contrast in the portovenous phase, and we do not give peroral contrast. Our patient received 90 ml of iomeprol 350 mg/ml i.v. and this was sufficient to see the vessels. The CT scan demonstrated transition zone both where the loop entered behind the external iliac vessel and where the intestine passed out behind the vessel as a closed loop. The small bowel was dilated both proximal to, as well as inside the closed loop (Figs. 2 and 3).

The patient received a prophylactic antibiotics composed of metronidazole 1.5 g and doxycycline 400 mg i.v. as a single dose. Exploratory laparoscopy was performed. The initial abdominal access was achieved using an optical trocar Visiport Excel®. We established pneumoperitoneum with a pressure of 12 mmHg and inserted two other working ports of 12 mm and one of 5 mm. The small bowel was dilated and congested with venous stasis but without any perforation. Some of the ascites fluid was collected to bacterial analysis.

We examined the non dilated bowel from the ileocecal junction, approximately 200 cm from the ileocecal junction the small

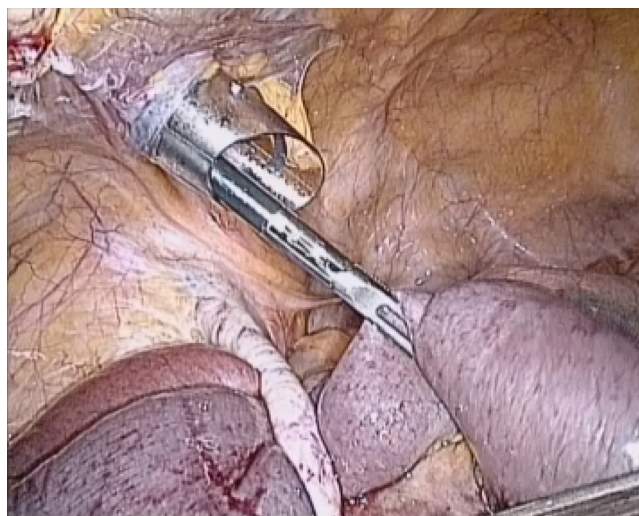


**Fig. 2.** Transverse plan of CT scan view of the herniated small bowel between external iliac artery (red arrow) and external iliac vein (red arrow). Notice the amount of ascites.

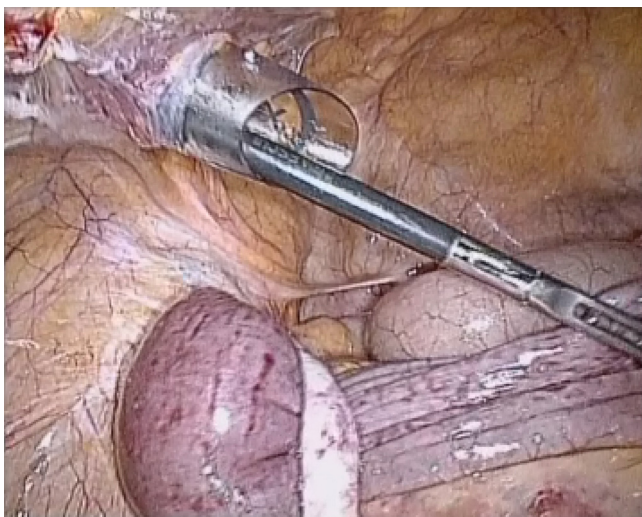
bowel made a closed loop underneath the left external iliac artery (Picture 1). The small bowel was strangulated by the external iliac vessel. By gentle manipulation we reduced the herniated small bowel (Picture 2) that soon recovered. The blue color and venous congestion were fading out and we noticed peristaltic movement of the previously herniated bowel we therefore did not perform any bowel resection. The defect underneath the artery was about 2–3 cm (Picture 3) in diameter. We found it risky to try to close the orifice and decided to leave it unrepaired. We noticed pulsation on the iliac vessel after the small bowel reduction and we evaluated the pulsation of the dorsalis pedis artery and the posterior tibial artery during the operation.

The abdomen was exsufflated and the fascia defects in the 12 mm ports were sutured and the skin closed with stapler. The patient was observed in the intensive care unit until the next morning, with focus on her leg pulse and color. Dalteparin 5000 IE was given subcutaneously 6 h after surgery and continued for the first 24 h after surgery.

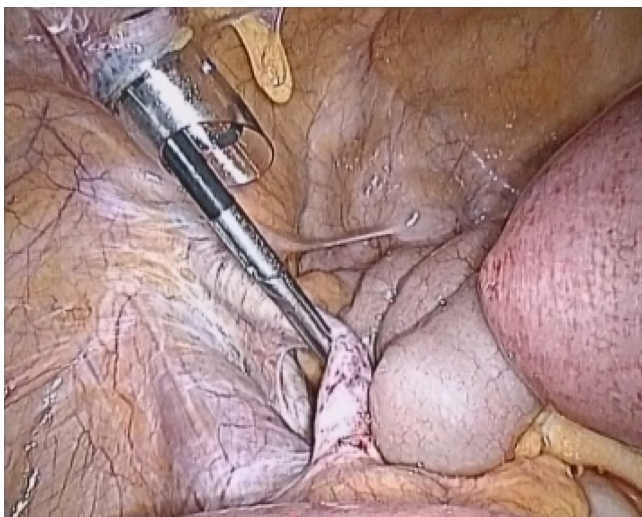
The postoperative course was uneventful and she was discharged from hospital the day following operation.



**Picture 1.** Laparoscopic picture showing small bowel incarcerated underneath the iliac artery (white structure on the picture).



**Picture 2.** Laparoscopic picture of the small bowel during laparoscopic reduction.



**Picture 3.** Laparoscopic picture, the small bowel has been reduced, the venous stasis is progressively disappearing (bowel loop on the right of the screen). The iliac vessels are skeletonized, one can appreciate the psoas muscle and the defect underneath the left external iliac vessel where the small bowel had herniated.

### 3. Discussion

Due to limited peritoneum in the area of the hernia defect and the skeletonized external iliac artery, we did not do any direct suture of the orifice as this might have compromised the artery and/or the vein. Due to previous omentectomy, no omentum was available for any repair. An alternative might have been to harvest a free peritoneum graft to cover the defect as described in the two other cases.<sup>3,4</sup> Another option was to use a mesh covered with an oxidized regenerated cellulose or expanded polytetrafluoroethylene (ePTFE) that minimize bowel adhesions. We decided to

leave the orifice unrepaired. We proposed that natural adhesions postoperative might reduce the chance of re-herniation.

A longer follow-up of the patient is needed to clearly conclude if this simple procedure has been sufficient. If the patient later experience any sign of recurrence and need another operation we will have to close the defect.

A challenge would have been if the bowel could not be reduced due to long standing obstruction. In such a case a bowel resection and/or a vascular surgical procedure might have been necessary. This would have considerably complicated the operation.

Following radical pelvic lymphadenectomy we find it important to be aware of this rare complication.

The small bowel in ileus might be fragile, gangrenous or necrotic and there is probably a higher risk of bowel perforation performing a laparoscopic approach.

We do not routinely use Verres needle in laparoscopy, we prefer to use Visiport as an optical trocar or an open Hasson approach that is another safe alternative to minimize the chance of bowel perforation on entrance into the abdominal cavity.

### 4. Conclusion

Strangulated internal hernia behind the iliac vessel is a rare entity only reported twice in the literature. Several options of treatment is discussed in previous papers.<sup>3,4</sup> To our knowledge this is the first case in the literature where laparoscopically reduction of the internal herniated bowel underneath the iliac vessel is performed. A quick recovery with no complications, short hospital stay and minimal discomfort postoperatively made our approach an acceptable surgical option for this patient.

### Conflicts of interest

The authors report that there are no conflicts of interest.

### Funding

None.

### Ethical approval statement

Written informed consent was obtained from the patient for publication of this case report and accompanying images. A copy of the written consent is available for review by the Editor-in-Chief of this journal on request.

### References

1. Ditto A, Martinelli F, Reato C, Kusamura S, Solima E, Fontanelli R, et al. Systematic para-aortic and pelvic lymphadenectomy in early stage epithelial ovarian cancer: a prospective study. *Ann Surg Oncol* 2012;**19**(November (12)):3849–55.
2. Chang SJ, Bristow RE, Ryu HS. Analysis of para-aortic lymphadenectomy up to the level of the renal vessels in apparent early-stage ovarian cancer. *J Gynecol Oncol* 2013;**24**(January (1)):29–36.
3. Guba AM, Lough F, Collins GJ, et al. Iatrogenic internal hernia involving the iliac artery. *Ann Surg* 1978;**188**(July):49–52.
4. Kim KM, Kim CH, Cho MK, Jeong YY, Kim YH, Choi HS, et al. A strangulated internal hernia behind the external iliac artery after a laparoscopic pelvic lymphadenectomy. *Surg Laparosc Endosc Percutan Tech* 2008;**18**(August (4)):417–9.

### Open Access

This article is published Open Access at [scimedirect.com](http://scimedirect.com). It is distributed under the [IJSCR Supplemental terms and conditions](#), which permits unrestricted non commercial use, distribution, and reproduction in any medium, provided the original authors and source are credited.