

# A Wave-Like Anastomosis, a New Technique of Anastomosis to Prevent Stricture after Oesophageal Atresia Repair

Mohamed Oulad Saïad

Department of General Pediatric Surgery, Mother and Child Unit, School of Medicine, Mohamed VI University Teaching Hospital, Cadi Ayyad University, Marrakesh, Morocco

## Abstract

**Background:** Anastomotic stricture still a frequent postoperative complication. Its development is multifactorial, nonetheless by improving some factors we can prevent the stricture. Anastomotic technique is among the factors that can be improved to prevent this complication. **Aims and Objectives:** Our aim is to report a new technique of anastomosis with a multiple plain suture, wave-like anastomosis and large low traction zone to prevent stricture after esophageal atresia repair. Furthermore this is a self-patient's anatomy dependant technique. **Materials and Methods:** A retrospective study reported forty nine esophageal atresia survivals without significant difference in weight and gap length. They were divided in two groups A and B with respectively eighteen and thirty one patients. The wave-like anastomosis technique is used in group A but in the group B an end to end anastomosis was used. **Results:** After a mean follow-up of 3 years no patient of the group A presented with anastomotic stricture and eight patients in the group B presented with stricture ( $p=0,046$ ) so there was a significant difference between the two groups. **Conclusion:** This is a technique providing a multiple plain anastomosis, increasing the lumen in the anastomotic site and helping to prevent anastomotic stricture.

**Keyword:** Anastomosis, atresia, oesophagus, stricture, technique

## INTRODUCTION

Oesophageal atresia surgery has benefitted from the development of surgery and intensive care. Nevertheless, anastomotic stricture is still the most frequent post-operative complication. The development of anastomotic stricture is multifactorial: the suture material, anastomotic technique, gastro-oesophageal reflux disease, anastomotic tension and post-operative anastomotic leak.<sup>[1]</sup> Some of those factors could be preventable. We report a technique of anastomosis allowing a long and multiple plain suture that results into a healing without stricture.

## MATERIALS AND METHODS

After institutional review board approval, a retrospective study of 49 oesophageal atresia type C survivors was conducted from February 2011 and March 2018; there were no significant differences in weight, oesophageal atresia subtype, evaluation according to the Waterston's prognostic classification system

and gap length. The same absorbable 5/0 polydioxanone suture material was used in all patients. All the patients received the same post-operative care in the same unit and received the same antacid medication. A routine oesophagram was done on the 7<sup>th</sup> day after surgery to rule out an anastomotic leak. The diagnosis of stricture was based on the clinical features that included dysphagia, regurgitation, cough, aspiration and recurrent respiratory infection. In symptomatic survivals, an oesophagram and an endoscopy were systematically performed. Depending on the anastomotic technique, we divided patients in two Groups A and B with, respectively, 18 (12 males and 6 females) and 31 (19 males and 12 females) patients. The wave-like anastomosis technique was used in the Group A, but in the Group B, an end-to-end anastomosis

**Address for correspondence:** Prof. Mohamed Oulad Saïad, Mother and Child Unit, School of Medicine, Mohamed VI University Teaching Hospital, Cadi Ayyad University, Marrakesh, Morocco.  
E-mail: mouladsaiad@gmail.com

Received: 19-08-2020 Revised: 27-09-2020 Accepted: 12-12-2020 Available Online: 30-07-2021

### Access this article online

Quick Response Code:



Website:  
www.afripaedurg.org

DOI:  
10.4103/ajps.AJPS\_123\_20

This is an open access journal, and articles are distributed under the terms of the Creative Commons Attribution-NonCommercial-ShareAlike 4.0 License, which allows others to remix, tweak, and build upon the work non-commercially, as long as appropriate credit is given and the new creations are licensed under the identical terms.

**For reprints contact:** WKHLRPMedknow\_reprints@wolterskluwer.com

**How to cite this article:** Saïad MO. A wave-like anastomosis, a new technique of anastomosis to prevent stricture after oesophageal atresia repair. Afr J Paediatr Surg 2021;18:179-81.

was used. Patients of the two groups were evaluated by using pre-operative test for the frequency of anastomotic stricture, leakage and recurrence of fistula. Data were statistically analysed the tests are considered significant if the null hypothesis is rejected ( $\alpha = 5\%$ ).

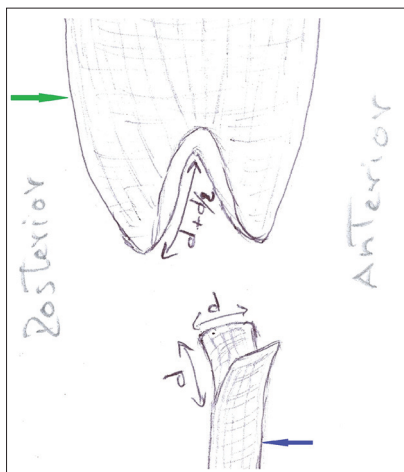
### Surgical technique

This operation could be performed through classical dorsolateral or modified posterior thoracotomy extra or transpleurally. After the closure of the tracheo-oesophageal fistula, two stay sutures in the lateral right and left sides of the lower end oesophagus are placed. The upper pouch was undermined and dissected, and two stay sutures were placed on its anterior and posterior walls. In this way, the line joining the upper pouch stay sutures was perpendicular to the line joining the lower distal end stay sutures. We calculated the diameter 'd' of the lower end which was only the distance between the two lower stay sutures. We performed, without any mobilisation, a longitudinal sagittal incision equal to the diameter 'd' on both the anterior and posterior walls of the

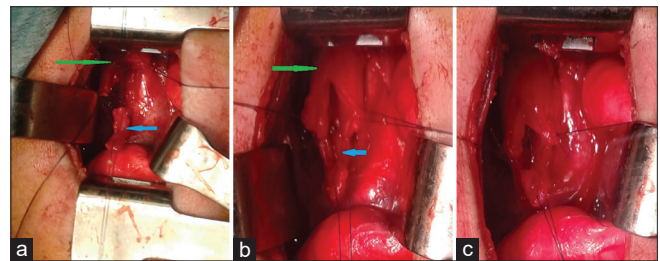
distal end. A transversal incision ( $= d + d/2$ ) was performed on the right and left walls to open the proximal pouch [Figure 1]. At the end, two separate flaps and two open V are created in each end of the oesophagus [Figure 2a]. First of all, the left flap from the lower end was laid into the left open inverted V of the upper pouch [Figure 2b], and then, we sutured the lower left flap to the left side of the anterior and posterior flaps of the upper pouch with care to take the mucosa in the sutures [Figure 2c]. The nasogastric tube is inserted trans-anastomotically by the anaesthesiologist under eye control. The right flap from the lower end is laid in right open V of the upper pouch [Figure 3a], and then, we suture the lower right flap to the right side of the anterior and posterior flaps of the upper pouch. A non-circular wide and wave-like anastomosis that increases the lumen is created with a total of generally 12 sutures [Figure 3b].

### RESULTS

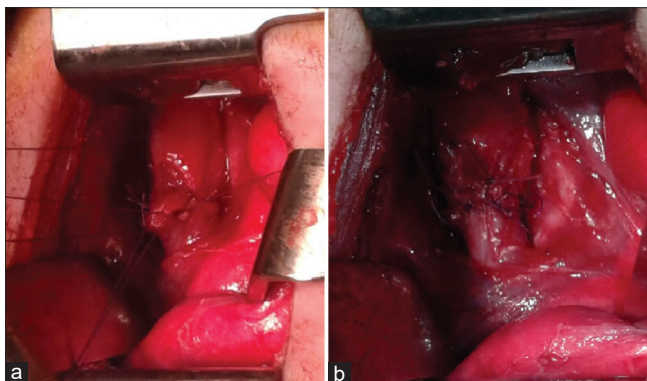
After a mean follow-up of 3 years in the Group A, two patients had leakages in the routine oesophagram, one patient had a recurrent tracheo-oesophageal fistula and no patient had clinical symptoms



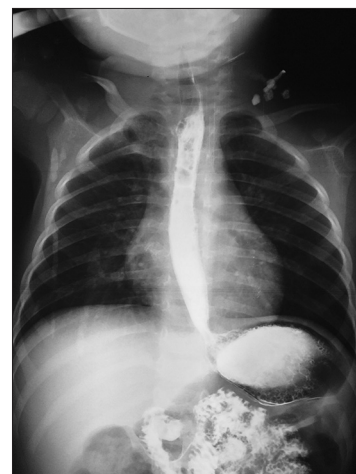**Figure 1:** Sagittal incision of the lower end oesophagus equal to the diameter 'd' of the lower end after dividing the tracheo-oesophageal fistula. Transversal incision on the upper pouch equal to 'd + d/2'



**Figure 2:** (a) Intra-operative view of the incisions, the plain of the incision on the upper pouch (green arrow) is perpendicular to the plain of the incision on the lower end of the oesophagus (blue arrow). (b) First step of anastomosis: Left flap from the lower end is laid into the left open V. (c) Second step of anastomosis: Suture of the left lower flap to the left sides of the anterior and posterior upper flaps



**Figure 3:** (a) Third step of anastomosis: After passing the nasogastric tube the right lower flap is laid into the right open V. (b) Last step of anastomosis: End of the wave-like anastomosis by suturing the right lower flap to the right side of the anterior and posterior upper flaps



**Figure 4:** Oesophagram showing the long-term evolution and healing of the wave-like anastomosis with a good oesophageal calibre in the anastomosis site

of stricture. Oesophagram performed after >1 year of follow-up showed a good calibre [Figure 4]. In the Group B, four patients had a leakage on the routine oesophagram, one patient presented with a recurrent fistula and eight patients presented with clinical, radiological and endoscopic signs of stricture between 1 and 6 months after oesophageal atresia repair. A balloon dilatation was performed with good outcome. For the stricture  $P = 0.046$  the null hypothesis is rejected making the test significant. For the leakage ( $P = 1$ ) and recurrent fistula ( $P = 1$ ) showing non-significant difference between the two groups

## DISCUSSION

Anastomotic stricture is the most common and challenging post-operative complication occurring in 18%–60% of survivals after oesophageal atresia repair.<sup>[2]</sup> Risk factors of anastomotic stricture can be divided into pre-operative risk factors encompassing the length of the gap and prematurity, intraoperative risk factors including anastomotic tension and the type of suture and post-operative risk factors with anastomotic leak and gastro-oesophageal reflux disease.<sup>[1]</sup> Beside other factors, the type of anastomosis is also involved in the development of stricture.<sup>[3]</sup> A circular anastomosis as in end-to-end anastomosis contracts by one third during healing, this contraction narrows the lumen and results in the stricture of anastomosis.<sup>[3]</sup> Different techniques of anastomosis have been used to prevent anastomotic strictures. Sulamaa *et al.* reported end-to-side anastomosis that results in a long anastomosis line to prevent stricture.<sup>[4]</sup> Even this long anastomotic line, which is limited to one plain, still gives rise to strictures.<sup>[5]</sup> Only a large anastomotic line unrestricted to one plain can help in preventing the risk of anastomotic stricture. Sharma and Wakhlu and Singh and Shun reported two techniques based on one flap raised from the upper pouch that provides a large lumen anastomosis; nevertheless, it may result in a tension in the anterior suture line.<sup>[3,6]</sup> Melek and Cobanoglu described a plus-shaped incision to open the upper pouch that gives a large anastomosis line with a zigzag anastomosis,<sup>[5]</sup> but we think that the flaps created may be too small, so the anastomosis was laid in 2 mm incision of the lower end may result in a small zigzag. The technique we reported is related to the diameter of the lower oesophageal end that helped us to calculate the incision length of the lower

end and upper pouch. This resulted in a large line anastomosis and more accentuated zigzag or wave-like anastomosis in different plains. This technique is dependent on peculiar anatomy of the pathology as it is based on the personal diameter of the lower end. There was no loss of tissue when opening the upper pouch that leads to length gain. We think that, in this technique, only the four sutures in open V are bearing most of the traction and represent points of traction when the gap is long preventing the other 8 sutures to bear lower traction, with a large low traction zone and consequent good healing. Further, the four flaps increase the diameter of the anastomotic site making it superior to the diameter ‘*d*’ of the lower end; this increases the lumen in the anastomotic site with a progressive transition from the larger upper pouch to lower end of the oesophagus.

This technique provides a multiple plane wide anastomosis with a large low traction zone for a good healing without risk of stricture; nonetheless, it should be submitted to a larger study cohort before final conclusions can be drawn.

## Financial support and sponsorship

Nil.

## Conflicts of interest

There are no conflicts of interest.

## REFERENCES

1. Tambucci R, Angelino G, De Angelis P, Torroni F, Caldaro T, Balassone V, *et al.* Anastomotic strictures after esophageal atresia repair: Incidence, investigation, and management, including treatment of refractory and recurrent strictures. *Front Pediatr* 2017;5:120.
2. Landisch RM, Foster S, Gregg D, Chelius T, Cassidy LD, Lerner D, *et al.* Utilizing stricture indices to predict dilation of strictures after esophageal atresia repair. *J Surg Res* 2017;216:172-8.
3. Sharma AK, Wakhlu A. Simple technique for proximal pouch mobilization and circular myotomy in cases of esophageal atresia with tracheoesophageal fistula. *J Pediatr Surg* 1994;29:1402-3.
4. Sulamaa M, Gripenberg I, Alvenainen EK. Prognosis and treatment of congenital atresia of the oesophagus. *Acta Chir Scand* 1951;102:141-57.
5. Melek M, Cobanoglu U. A new technique in primary repair of congenital esophageal atresia preventing anastomotic stricture formation and describing the opening condition of blind pouch: Plus (“+”) incision. *Gastroenterol Res Pract* 2011;2011:527323.
6. Singh SJ, Shun A. A new technique of anastomosis to avoid stricture formation in oesophageal atresia. *Pediatr Surg Int* 2001;17:575-7.