


## Case Report

# A case of estrogen-secreting adrenocortical carcinoma: Comprehensive immunohistochemical analysis of disorganized steroid genesis

Megumi Yokoyama,<sup>1</sup> Toshiki Kijima,<sup>1</sup>  Atsuko Takada-Owada,<sup>2</sup> Kazumasa Sakamoto,<sup>1</sup> Issei Suzuki,<sup>1</sup> Daisaku Nishihara,<sup>1</sup> Yasuhiro Nakamura,<sup>3</sup> Kazuyuki Ishida<sup>2</sup> and Takao Kamai<sup>1</sup>

Departments of <sup>1</sup>Urology and <sup>2</sup>Diagnostic Pathology, Dokkyo Medical University, Shimotsuga, Tochigi, and <sup>3</sup>Division of Pathology, Tohoku Medical and Pharmaceutical University, Sendai, Miyagi, Japan

## Abbreviations & Acronyms

ACC = adrenocortical carcinoma  
 CT = computed tomography  
 DHEA-S = dehydroepiandrosterone sulfate  
 DHEA-ST = dehydroepiandrosterone sulfotransferase  
 EST = estrone sulfotransferase  
 FDG-PET = fluorodeoxyglucose-positron emission tomography  
 HE = hematoxylin-eosin  
 HSD = hydroxysteroid dehydrogenase  
 P450arom = aromatase  
 P450c17 = 17 $\alpha$ -hydroxylase/17,20-lyase  
 P450c21 = steroid 21-hydroxylase  
 RT-PCR = reverse transcription-polymerase chain reaction  
 STS = steroid sulfatase

**Correspondence:** Toshiki Kijima M.D., Ph.D., Department of Urology, Dokkyo Medical University, 880 Kitakobayashi, Mibu, Shimotsuga, Tochigi, 321-0293, Japan. Email: tkijima@dokkyomed.ac.jp

**How to cite this article:** Yokoyama, M, Kijima T, Takada-Owada A, *et al.* A case of estrogen-secreting adrenocortical carcinoma: Comprehensive immunohistochemical analysis of disorganized steroid genesis. *IJU Case Rep.* 2021; 4: 318–321.

This is an open access article under the terms of the Creative Commons Attribution-NonCommercial-NoDerivs License, which permits use and distribution in any medium, provided the original work is properly cited, the use is non-commercial and no modifications or adaptations are made.

Received 3 April 2021; accepted 10 June 2021.  
 Online publication 28 June 2021

**Introduction:** Adrenocortical carcinoma rarely secretes estrogens, and little is known regarding the mechanism of intra-tumor estrogen production. We report an estrogen-secreting adrenocortical carcinoma in a postmenopausal woman, where comprehensive immunohistochemical analyses of the resected tumor revealed disorganized steroidogenesis.

**Case presentation:** A 68-year-old woman presented with postmenopausal vaginal bleeding and was found to have a left adrenal tumor. Serum estradiol and testosterone were elevated but they normalized after resection of the tumor, suggestive of adrenocortical carcinoma with disorganized steroidogenesis. Immunohistochemical analyses revealed that the tumor expressed aromatase which converts androgens into estrogens. Furthermore, the tumor lacked 17 $\beta$ HSD2, which converts estradiol to estrone, suggesting that estradiol accumulated as the final product of the tumor's steroidogenic pathway.

**Conclusion:** The capability of adrenocortical carcinoma to produce estrogen can be demonstrated by comprehensive immunohistochemical analyses of steroidogenic enzymes, such as those reported here.

**Key words:** adrenocortical carcinoma, aromatase, estrogen, immunohistochemistry, steroid genesis.

## Keynote message

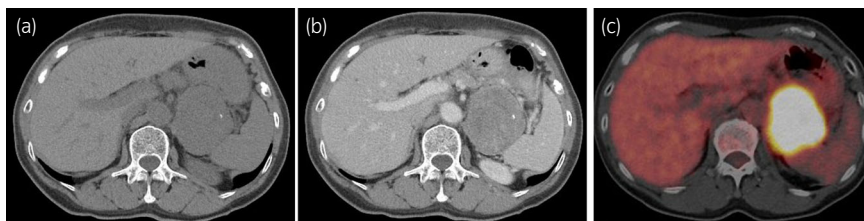Adrenocortical carcinoma rarely secretes estrogens; however, immunohistochemical analyses of steroidogenic enzymes can reveal the details of estrogen production within the tumor. Estrogen-secreting adrenocortical carcinoma should be considered in the presence of vaginal bleeding in a postmenopausal woman.

## Introduction

ACC is rare and highly malignant, with a poor prognosis. Approximately 60% of ACCs are hormone secreting, and the steroid profile typically exhibits a disorganized steroidogenesis pattern, further exacerbating the morbidity in ACCs.<sup>1</sup> ACCs most commonly secrete cortisol and androgens. ACCs secreting estrogens are rare, with an incidence of 1–2%,<sup>2</sup> and the source and mechanism of estrogen overproduction in ACCs remain unclear. Physiologically, the adrenal cortex has minimal capacity to produce estrogens, since they lack P450arom (CYP19A1), which converts androgens into estrogens. Previous studies have shown aromatase overexpression at the mRNA and protein levels in estrogen-secreting ACCs.<sup>3–6</sup> This may contribute to ectopic estrogen production in ACCs. However, performing detailed analyses of the steroidogenesis pathway by immunohistochemical analysis is difficult due to its low sensitivity and tumor heterogeneity.<sup>7,8</sup> We report the result of a comprehensive immunohistochemical analysis of disorganized steroidogenesis in estrogen-secreting ACC.

## Case presentation

A 68-year-old woman presented with a 3-month history of postmenopausal vaginal bleeding. On transvaginal ultrasound, the uterus was enlarged, but the left and right ovaries were normal. Hormonal study revealed elevated serum estradiol (95.9 pg/mL, normal range in postmenopausal women <5.0 pg/mL). The pelvic magnetic resonance imaging findings suggest endometrial cancer, but the endometrial cytology and biopsy revealed proliferating endometrial tissue without signs of malignancy. Computed tomography revealed a 7-cm left adrenal tumor (Fig. 1a,b). FDG-PET CT revealed avid FDG uptake in the adrenal tumor, but no metastatic lesion (Fig. 1c). The hormonal test was performed again (Table 1), and it showed elevated serum estradiol (147.7 pg/mL) and testosterone (3.58 ng/mL, normal range in postmenopausal women 0.1–0.6 ng/mL), suggestive of ACC with disorganized steroidogenesis. Based on the large tumor size and abnormal hormonal analysis results, we suspected tumor malignancy and performed left adrenalectomy. The postoperative course was uneventful. After surgery, her serum estradiol and testosterone normalized, and vaginal bleeding was alleviated. She has been well and disease-free, with adjuvant mitotane therapy, for 6 months. Histologically, the tumor was heterogeneously composed of large and small cell components with eosinophilic cytoplasm. The tumor exhibited high nuclear grade foci, mitosis, necrosis, and venous and capsular invasions. Seven of the 9 items in the Weiss Criteria were met, suggesting a malignancy. A comprehensive immunohistochemical analysis of disorganized steroidogenesis was performed (Fig. 2). All tumor cells tested positive for SF-1, suggesting an adrenocortical origin. The tumor expressed 3 $\beta$ HSD, P450c21, P450c17, DHEA-S, and 17 $\beta$ HSD5, suggesting that the tumor could produce androgens. Furthermore, the tumor expressed P450arom, which enables the conversion of androgens to estrogens. The tumor was negative for 17 $\beta$ HSD2, which converts estradiol to estrone. Based on this, estradiol was expected to accumulate as the final product of the tumor's steroidogenic pathway. The tumor cells were also positive for STS, which converts serum estrone sulfate into estrone, suggesting that the tumor could convert serum estrone sulfate into estradiol. Although 3 $\beta$ HSD was heterogeneously expressed in the tumor, a substantial proportion of tumor cells was negative. This explained why the tumor predominantly produced sex steroids, instead of cortisol and aldosterone.



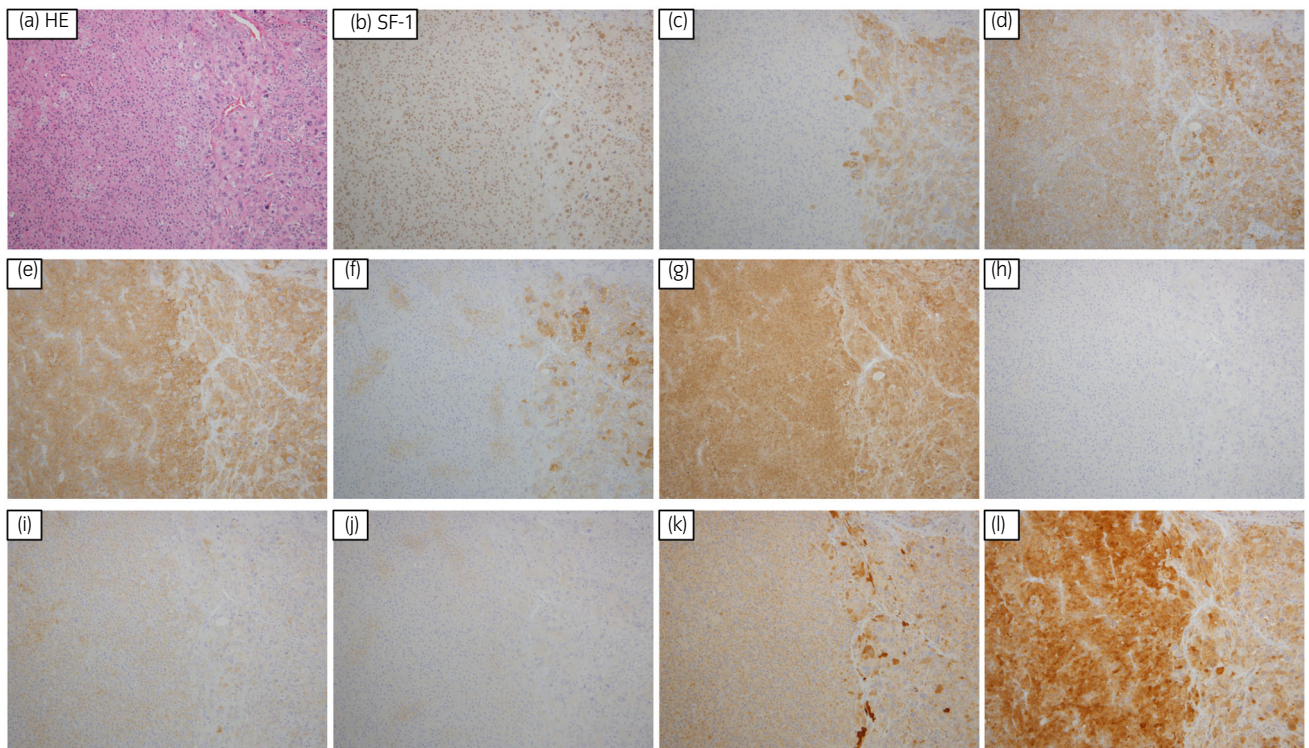
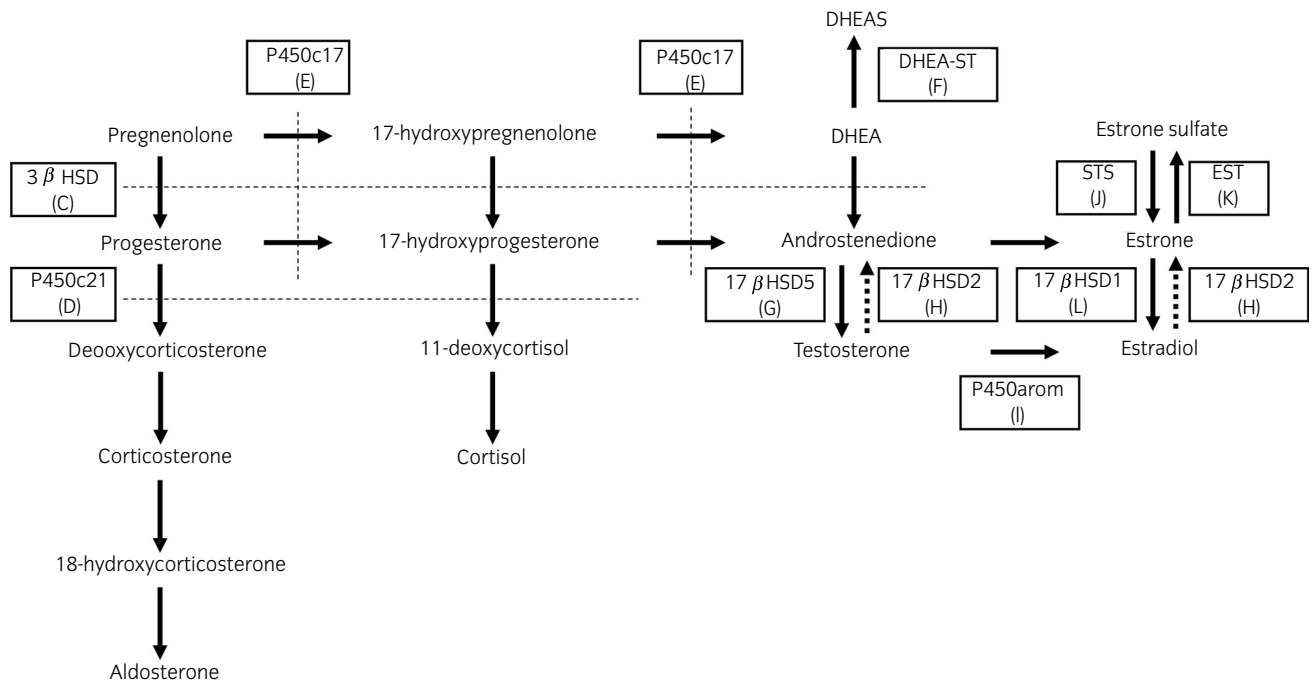
**Fig. 1** Computed tomography (CT) findings of the left adrenal tumor. (a) Plain CT; (b) Contrast-enhanced CT; (c) Fluorodeoxyglucose-positron emission tomography (FDG-PET) CT.

**Table 1** Hormonal status before and after adrenalectomy

|                       | Normal range in menopausal women | Before adrenalectomy | After adrenalectomy |
|-----------------------|----------------------------------|----------------------|---------------------|
| LH (mIU/mL)           | 5.72–64.31                       | 2.35                 | 32.01               |
| FSH (mIU/mL)          | <157.79                          | 6.37                 | 103.05              |
| Progesterone (ng/mL)  | 0.0–0.3                          | 0.16                 | 0.08                |
| Aldosterone (pg/mL)   | 38.9–307                         | 83.8                 | 107                 |
| Testosterone (ng/mL)  | 0.1–0.6                          | 3.58                 | 0.07                |
| Estradiol (pg/mL)     | < 5.0                            | 147.74               | 11.8                |
| Prolactin (ng/mL)     | 3.1–15.4                         | 15.57                | 10.02               |
| PRA (ng/mL/h)         | 0.2–3.9                          | 2                    | 3.6                 |
| Adrenaline (pg/mL)    | <100                             | 26                   | 31                  |
| Noradrenaline (pg/mL) | 100–450                          | 239                  | 465                 |
| Dopamine (pg/mL)      | <20                              | 9                    | 13                  |

## Discussion

We reported a case with estrogen-secreting ACC, where comprehensive immunohistochemical analyses revealed the details of disorganized steroidogenesis within the tumor. Adrenocortical adenomas have homogeneous expression of steroidogenic enzymes, while ACC cells show heterogeneous expression of these enzymes, which is referred to as disorganized steroidogenesis, resulting in the secretion of various intermediate metabolites.<sup>9</sup> Two possible mechanisms have been proposed for elevated serum estrogen in ACC patients. First, the conversion of serum androgens, which is produced by ACC cells, to estrogens by aromatase at the peripheral adipose tissues.<sup>10</sup> Second, the intra-tumor conversion of androgens to estrogens, since intra-tumor aromatase activity has been reported in ACC cases recently.<sup>3–7,11</sup> However, detecting aromatase activity within the tumor using immunohistochemistry is sometimes difficult due to the low sensitivity and tumor heterogeneity.<sup>7,8</sup> In this case, ACC cells were proven to be capable of not only androgen production, but also converting androgens into estrogens. To the best of our knowledge, this is the first case report of estrogen-secreting ACC where the intra-tumor estrogen production pathway was revealed using immunohistochemical analysis. Due to the low sensitivity of immunohistochemical analyses, there could be a discrepancy between immunohistochemical results and clinical symptoms. In such situations, the detection of transcripts associated with aromatase promoter by RT-PCR would be diagnostically helpful.<sup>12</sup> Hatano et al. reported a case of



**Fig. 2** Comprehensive immunohistochemical analysis revealing disorganized steroid genesis in adrenocortical carcinoma. (a) HE staining, (b) SF-1, (c) 3βHSD, (d) P450c21, (e) P450c17, (g) 17βHSD5, (h) 17βHSD2, (i) P450arom, (j) STS, (k) EST, and (l) 17βHSD1.

clinically estrogen-producing, but pathologically testosterone-producing, ACC where overexpression of the aromatase promoter was observed upon RT-PCR.<sup>7</sup> Similarly, immunohistochemical analysis revealed a relatively low intensity expression of P450arom by tumor cells in the current case. Therefore, we speculate that intensity on immunohistochemical analysis is not necessarily correlated with aromatase

activity, and that positive staining for P450arom, irrespective of intensity, is enough to suggest aromatase activity.

Adrenal precursor cells and bipotential gonadal precursor cells arise from a common ancestor. Previous studies have revealed the combined steroidogenic characters of fetal adrenal cells and Leydig cells in androgen-producing ACC.<sup>13</sup> ACCs may have acquired pluripotential steroidogenic



function via dedifferentiation of the adrenocortical cells toward their common adrenal-gonadal precursor.<sup>14</sup> This leads to the production of sex steroids in ACCs.

Disorganized steroidogenesis can be useful for assessing the presence of malignancy. At initial adrenal tumor diagnosis, feminization is considered almost pathognomonic of malignancy. Furthermore, feminizing ACCs tend to be larger and have worse prognosis compared with non-feminizing ACCs.<sup>2</sup> Therefore, in cases of suspected ACC, an extensive steroid hormone work-up, including glucocorticoid, mineralocorticoid, sex hormone, and precursor-steroid analysis, should be performed.

As more than half of ACC patients who undergo complete tumor resection develop local recurrence or metastases, adjuvant therapy is often provided. Mitotane has been the reference drug for metastatic ACC management and is increasingly used in adjuvant settings. Recent guidelines<sup>15</sup> recommend adjuvant mitotane for patients at high risk of recurrence (stage III-IV, incomplete resection, and/or high Ki-67 index or mitotic rates). In the current case, we provided adjuvant mitotane therapy because the tumor had a high mitotic rate.

Endometrial carcinoma is the most likely diagnosis in postmenopausal women with vaginal bleeding. Cytology and biopsy of the endometrial tissue must be performed. With findings of endometrial hyperplasia suggesting a high estrogenic activity, thorough hormonal examination and imaging studies must be performed to investigate the presence of estrogen-secreting ovarian tumors or ACCs. The capability of ACCs to produce estrogen can be demonstrated by comprehensive immunohistochemical analyses of steroidogenic enzymes, as performed in the current case.

## Conflict of interest

The authors declare no conflict of interest.

## Approval of the research protocol by an institutional reviewer board

Not applicable.

## Informed consent

Written informed consent was obtained from the patient for publication of this case report and accompanying images.

## Registry and the registration no. of the study/trial

Not applicable.

## References

- Allolio B, Fassnacht M. Clinical review: Adrenocortical carcinoma: clinical update. *J. Clin. Endocrinol. Metab.* 2006; **91**: 2027–37.
- Moreno S, Guillermo M, Decoux M, Dewailly D, Bresson R, Proye C. Feminizing adreno-cortical carcinomas in male adults. A dire prognosis. Three cases in a series of 801 adrenalectomies and review of the literature. *Ann. Endocrinol.* 2006; **67**: 32–8.
- Saito T, Tojo K, Furuta N, Ono K, Sasano H, Utsunomiya K. Feminizing adrenocortical carcinoma with selective suppression of follicle-stimulating hormone secretion and disorganized steroidogenesis: a case report and literature review. *Intern. Med.* 2011; **50**: 1419–24.
- Watanabe T, Yasuda T, Noda H. Estrogen secreting adrenal adenocarcinoma in an 18-month-old boy: aromatase activity, protein expression, mRNA and utilization of gonadal type promoter. *Endocr. J.* 2000; **47**: 723–30.
- Moreau F, Mitre H, Benhaim A *et al.* Aromatase expression in the normal human adult adrenal and in adrenocortical tumors: biochemical, immunohistochemical, and molecular studies. *Eur. J. Endocrinol.* 2009; **160**: 93–9.
- Nicol MR, Papacleovoulou G, Evans DB *et al.* Estrogen biosynthesis in human H295 adrenocortical carcinoma cells. *Mol. Cell Endocrinol.* 2009; **300**: 115–20.
- Hatano M, Takenaka Y, Inoue I *et al.* Feminizing adrenocortical carcinoma with distinct histopathological findings. *Intern. Med.* 2016; **55**: 3301–7.
- Sasano H, Suzuki T, Nagura T *et al.* Steroidogenesis in human adrenocortical carcinoma: biochemical activities, immunohistochemistry, and in situ hybridization of steroidogenic enzymes and histopathologic study in nine cases. *Hum. Pathol.* 1993; **24**: 397–404.
- Brutsaert EF, Sasano H, Unger P *et al.* Adrenal cortical carcinoma with late pulmonary metastases causing clinical Cushing's syndrome: case report with immunohistochemical analysis of steroidogenic enzyme production. *Endocr. Pract.* 2012; **18**: e138–e143.
- Zayed A, Stock JL, Liepman MK *et al.* Feminization as a result of both peripheral conversion of androgens and direct estrogen production from an adrenocortical carcinoma. *J. Endocrinol. Invest.* 1994; **17**: 275–8.
- Fukai N, Hirono Y, Yoshimoto T *et al.* A case of estrogen-secreting adrenocortical carcinoma with subclinical Cushing's syndrome. *Endocr. J.* 2006; **53**: 237–45.
- Advani A, Johnson SJ, Nicol MR *et al.* Adult-onset hypogonadotropic hypogonadism caused by aberrant expression of aromatase in an adrenocortical adenocarcinoma. *Endocr. J.* 2010; **57**: 651–6.
- Fujisawa Y, Sakaguchi K, Ono H *et al.* Combined steroidogenic characters of fetal adrenal and Leydig cells in childhood adrenocortical carcinoma. *J. Steroid Biochem. Mol. Biol.* 2016; **159**: 86–93.
- Hatano O, Takakusu A, Nomura M, Morohashi K. Identical origin of adrenal cortex and gonad revealed by expression profiles of Ad4BP/SF-1. *Genes Cells* 1996; **1**: 663–71.
- Fassnacht M, Assie G, Baudin E *et al.* Adrenocortical carcinomas and malignant pheochromocytomas: ESMO-EURACAN Clinical Practice Guidelines for diagnosis, treatment and follow-up. *Ann. Oncol.* 2020; **31**: 1476–90.