

# Innovation in the imaging of perianal fistula: a step towards personalised medicine

Kapil Sahnan, Samuel O. Adegbola, Philip J. Tozer, Uday Patel, Rajpandian Ilangovan, Janindra Warusavitarne, Omar D. Faiz, Ailsa L. Hart, Robin K. S. Phillips and Phillip F. C. Lung

Ther Adv Gastroenterol

2018, Vol. 11: 1–7

DOI: 10.1177/  
1756284818775060

© The Author(s), 2018.

Reprints and permissions:  
[http://www.sagepub.co.uk/  
journalsPermissions.nav](http://www.sagepub.co.uk/journalsPermissions.nav)

## Abstract

**Background:** Perianal fistula is a topic both hard to understand and to teach. The key to understanding the treatment options and the likely success is deciphering the exact morphology of the tract(s) and the amount of sphincter involved. Our aim was to explore alternative platforms better to understand complex perianal fistulas through three-dimensional (3D) imaging and reconstruction.

**Methods:** Digital imaging and communications in medicine images of spectral attenuated inversion recovery magnetic resonance imaging (MRI) sequences were imported onto validated open-source segmentation software. A specialist consultant gastrointestinal radiologist performed segmentation of the fistula, internal and external sphincter. Segmented files were exported as stereolithography files. Cura (Ultimaker Cura 3.0.4) was used to prepare the files for printing on an Ultimaker 3 Extended 3D printer. Animations were created in collaboration with Touch Surgery™.

**Results:** Three examples of 3D printed models demonstrating complex perianal fistula were created. The anatomical components are displayed in different colours: red: fistula tract; green: external anal sphincter and levator plate; blue: internal anal sphincter and rectum. One of the models was created to be split in half, to display the internal opening and allow complexity in the intersphincteric space to be better evaluated. An animation of MRI fistulography of a trans-sphincteric fistula tract with a cephalad extension in the intersphincteric space was also created.

**Conclusion:** MRI is the reference standard for assessment of perianal fistula, defining anatomy and guiding surgery. However, communication of findings between radiologist and surgeon remains challenging. Feasibility of 3D reconstructions of complex perianal fistula is realized, with the potential to improve surgical planning, communication with patients, and augment training.

**Keywords:** innovation, MRI, 3D printing

Received: 15 January 2018; revised manuscript accepted: 11 April 2018.

## Introduction

Crohn's perianal fistulas are frequently complex, with patients suffering from reduced quality of life.<sup>1</sup> Magnetic resonance imaging (MRI) is the gold standard<sup>2</sup> for fistula imaging, with scans informing clinicians about fistula complexity: the morphology of the tracts; presence of extensions/sepsis, and the relation to the anal sphincter.

Longitudinally, it is used to assess a patient's response to treatment. The disease process itself is frequently refractory, with high recurrence and reoperation rates.<sup>3–5</sup> A vicious cycle often ensues due to the combination of a recurrent inflammatory process and distortion of the anorectum from scar tissue following each operative procedure.

Correspondence to:

**Phillip FC Lung**  
Consultant  
Gastrointestinal  
Radiologist, St Mark's  
Hospital, Watford Road,  
Harrow, Middlesex HA1  
3UJ, UK  
[philliplung@nhs.net](mailto:philliplung@nhs.net)

**Kapil Sahnan**  
**Samuel O Adegbola**  
**Philip Tozer**  
**Janindra Warusavitarne**  
**Omar Faiz**  
**Prof Ailsa Hart**  
**Robin KS Phillips**  
Fistula Research Unit,  
St Mark's Hospital and  
Academic Institute,  
Harrow, UK  
Department of Surgery  
and Cancer, Imperial  
College, London, UK

**Uday Patel**  
**Rajpandian Ilangovan**  
Gastrointestinal Imaging,  
St Mark's Hospital and  
Academic Institute,  
Harrow, UK

**Phillip F. C. Lung**  
Fistula Research Unit,  
St Mark's Hospital and  
Academic Institute,  
Harrow, UK  
Department of Surgery  
and Cancer, Imperial  
College, London, UK  
Gastrointestinal Imaging,  
St Mark's Hospital and  
Academic Institute,  
Harrow, UK

Despite improvements in fistula imaging and increasing use of additional scan techniques and contrast, conceptualization of the fistula can be difficult. Understanding of complex fistula anatomy by surgeons is sometimes mediated through interactions with radiologists, either informally or through multidisciplinary meetings, but may still prove challenging. Also, not all surgeons review imaging with radiologists; it is not always possible in environments such as busy clinics or in theatre, where better methods than written reports are needed to convey satisfactory understanding for surgery. Explaining fistula anatomy and options for surgery to patients amplifies these challenges further, which impact their ability to make management decisions.

There has been an influx of novel techniques to treat perianal fistulas<sup>6</sup> of which video-assisted anal fistula treatment (VAAFT) is one. A recent meta-analysis found that mean operative time was  $42 \pm 14.2$  min, that the internal opening was identified in 85.7% of patients, and that recurrence occurred in 112 (14.2%) patients after a median follow up of 9 months.<sup>7</sup> However, this underestimated the complexity encountered in Crohn's fistulas, as only 13 of the 788 patients included in the meta-analysis had Crohn's disease, and these findings need to be interpreted with caution. It is the first of the novel procedures that combines a diagnostic phase with intervention and highlights the surgeon's desire for the operator to obtain a perioperative mechanism to understand tract morphology. The technique uses a rigid endoscope of fixed diameter, which makes visualization difficult in some cases and impossible in others, particularly in complex Crohn's fistula or curved tracts. Whilst the technique is not used worldwide, the authors of this paper have found the technique particularly useful in complex Crohn's perianal fistula.<sup>8</sup>

Three-dimensional (3D) reconstructions offer no new information to the two-dimensional 2D image but act to improve conceptualization, whereby a multitude of 2D pictures/slices, separated by a predetermined slice thickness, are 'stacked' upon each other to create a 3D representation.<sup>9</sup> The 3D imaging provides a more realistic representation of anatomy, based on cross-sectional data that has been shown to be a useful aid for patient education, clinical communication<sup>10</sup> and surgical planning.<sup>11</sup> The optimum medium of 3D reconstruction with reference to

improving communication and understanding may vary according to the target audience, which may be an expert (consultant surgeon), intermediate (trainee or medical student) or novice (lay public/patient). The St Mark's IBD patient panel, when shown previous 3D reconstructions by our institution,<sup>12,13</sup> suggested 3D printing as a viable alternative. All media require further evaluation not only for acceptability and efficacy, but also resource use (availability of the necessary technology, cost and time).

We postulate that a physical representation of the fistula will further improve patient and surgeon understanding (or at least facilitate acquisition of understanding), and also that a 'virtual VAAFT' or MRI fistulography may help surgeons approaching the fistula in theatre with a probe or VAAFT scope.

We have therefore developed these two further innovations for subsequent assessment. We describe the feasibility of creating 3D-printed fistula models and MRI fistulography.

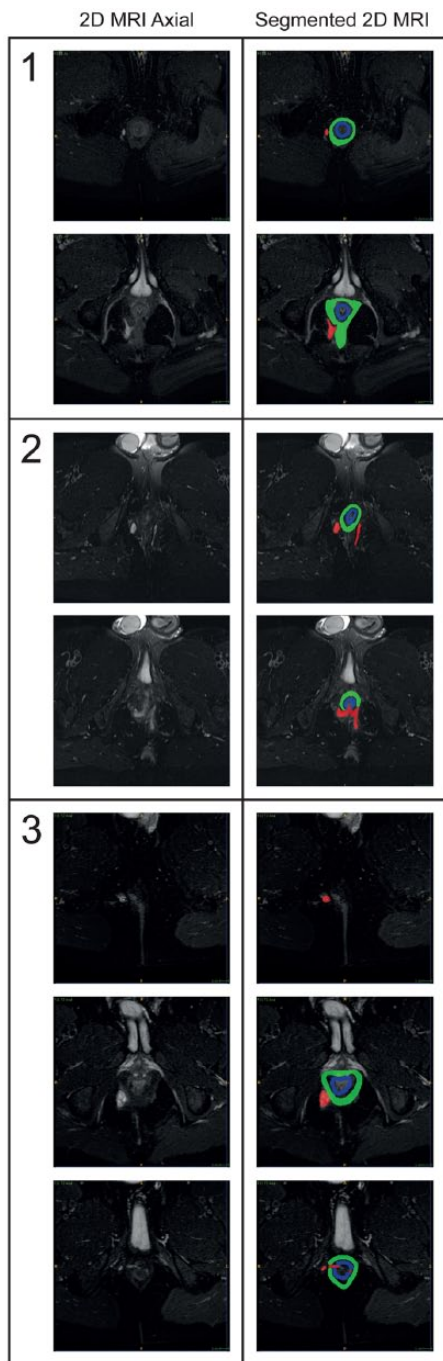
## Material and methods

### *Ethical approval*

After consultation with the local research and development (R and D) department (London North West NHS Trust), it was advised that approval by a National Health Service (NHS) research ethics committee or the R and D department was deemed unnecessary owing to the non-patient identifiable retrospective nature of this feasibility study. The study received departmental approval by the research lead of St Mark's Hospital, London, United Kingdom.

### *Magnetic resonance imaging technique*

Standard T2-weighted spectral attenuated inversion recovery MRI sequences were acquired in axial (Repetition time [TR] 8000; Echo Time [TE] 96; thickness 4 mm; gap 0.2 mm; Field-of-View [FOV] 240 mm; averages 4, flip angle 150, bandwidth 130Hz/Pixel [PX]) and coronal (TR 8860; TE 89; thickness 4 mm; gap 0.2 mm; FOV 250 mm; averages 4; flip angle 150, bandwidth 130Hz/PX) planes, with a sagittal T2-weighted BLADE sequence (TR 5400; TE 100; thickness 3 mm; gap 0.9 mm; FOV 290 mm; averages 1; flip angle 150, bandwidth 362Hz/PX; BLADE coverage 200%).



**Figure 1.** Two-dimensional axial scans with fistula complex segmented.

The various anatomical components are displayed in different colours (red: fistula tract; green: external anal sphincter (EAS) and levator plate; blue: internal anal sphincter (IAS) and rectum).

### Segmentation

Digital imaging and communications in medicine files of the MRI sequences were generated

from picture archiving and communication system and these were segmented and smoothed using validated open-source software.<sup>14,15</sup> A specialist consultant gastrointestinal radiologist manually segmented the following structures using axial sequences: fistula tract; internal sphincter; external sphincters/levator plate; and rectum.

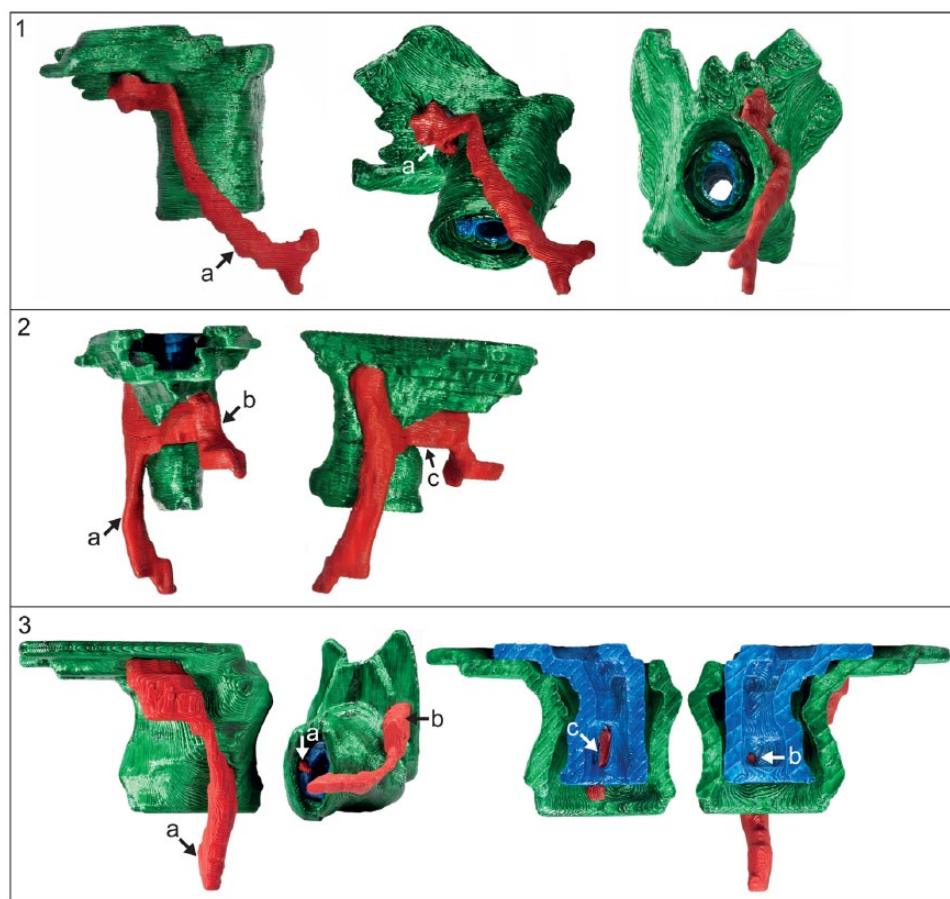
The segmented files were exported as stereolithography files. We used Cura (Ultimaker Cura 3.0.4, Ultimaker B.V., 4191 PN Geldermalsen, The Netherlands) to prepare the files for printing on an Ultimaker 3 Extended 3D printer. Animations were created in collaboration with Touch Surgery™.

## Results

### Three-dimensional printing

Segment scans and 2D axial MRI scans for three patients detailing the fistula complex are shown in Figure 1. The various anatomical components are displayed in different colours (red: fistula tract; green: external anal sphincter (EAS) and levator plate; blue: internal anal sphincter (IAS) and rectum). Segmentation of patient images took approximately 15 min per case. A further 10 min was required for smoothing and uploading the images to the 3D printer. Each of the models took approximately 60 min to make.

Figure 2 shows various orientations of the 3D models for the same patients: (1) A transsphincteric fistula (black arrow) with a small blind-ending cavity (white arrow) beneath the levator plate; (2) a transsphincteric fistula with the right tract (black arrow) passing through the ischioanal fossa and the left tract (double black arrow) being blind-ending, connected via a posterior horseshoe (triple black arrow); (3) these images show a right-sided transsphincteric fistula (black arrow) with a blind-ending cranial extension below the levator (double black arrow), and a short left-sided intersphincteric fistula (white arrow). Internal openings of the right transsphincteric fistula (double white arrow) and left intersphincteric fistula (triple white arrow) are shown on the internal views of the composite model. Of note, the final 3D model has been created so it can come apart to demonstrate the internal opening and complexity in the intersphincteric space.



**Figure 2.** Three-dimensional perianal anal fistula models. (1) Trans-sphincteric fistula with an infralevator extension; (2) trans-sphincteric fistula with a horseshoe; (3) complex trans-sphincteric and intersphincteric fistula.

### *Magnetic resonance fistulography*


An animation demonstrating a trans-sphincteric fistula with a cephalad extension in the intersphincteric space is shown in Figure 3 using the same colour code as Figure 1. In the animation clip, which is in the form of a ‘fly through’ akin to virtual colonoscopy, the viewer travels through the fistula tract and is oriented by annotations as they pass through specific sphincter structures.

### **Discussion**

Conventional 2D pelvic MRI is the imaging modality of choice to demonstrate fistula anatomy in anal fistula<sup>16</sup> and has been shown to reduce recurrence by up to 75%<sup>17</sup> when used to guide surgery.<sup>18</sup> The innovations described in this paper are derived from conventional MRI and do not provide any additional anatomical information or require additional sequences, but they do change the medium by which

this information is communicated. MRI fistulography and 3D printing represent further attempts to improve a surgeon’s understanding of information from the MRI, but could also have similar benefits in the explanation to patients and trainees.

Our MRI parameters are standard compared to other institutions,<sup>19,20</sup> allowing for ease of adoption of the technique to other centres. A slice thickness of 4 mm provides satisfactory contrast between different components of the anal canal and the fistula with good signal-to-noise ratio. Additionally, there are fewer slices through the anal canal, reducing time taken to segment the fistula and anal canal. With technology advancing rapidly, these innovations represent the first step to automated segmentation techniques that have been described in other specialties,<sup>21–23</sup> including abdominal MRI of Crohn’s patients,<sup>24</sup> and could become the standard of care for perianal fistulas.



**Figure 3.** Animation demonstrating a magnetic resonance fistulography, a ‘fly through’ of the fistula tract as it passes through the sphincter complex (the animation is available on the journal site as the online supplementary material).

For surgeons, a 3D model can potentially aid understanding of the complex relationship between sphincter anatomy and fistula, guiding surgical decisions and improving outcomes. Our initial experience was of ‘whole’ printed models, which allowed for an overall appreciation of the anatomy, but had similar benefits to 3D images. As our experience grew, we sought to deliver visualization of intersphincteric complexity and identification of key anatomical landmarks such as the internal opening, through the creation of composite fistula models that can be separated (as in the final panel of Figure 2) to highlight internal structures. The 3D-printed models represent a ‘concrete’ step toward personalized medicine.<sup>25</sup> Whilst the technique offers an intuitive benefit, clinical utility maybe difficult to ascertain. Any effect is likely to be harder to demonstrate amongst ‘experts’ but may have benefit to those surgeons with less experience and as such, we envisage the junior trainee may benefit the most.

In Crohn’s perianal fistula, the underlying disease process can be unforgiving, and sustained remission can only be achieved in 26–50%.<sup>26</sup> Two of the key objectives in reducing recurrence are to identify correctly and treat all secondary extensions and drain any collections/abscesses.<sup>27</sup> VAAFT is a recent innovation that aims to address both

objectives.<sup>28</sup> Criticisms of the technique are that the rigid scope limits manoeuvrability and as with any technique, it carries an associated new expense and a learning curve. MR fistulography would facilitate novices in the ‘diagnostic’ phase to identify/negotiate tracts with the potential to limit overall operative time, whilst providing a ‘road map’ for more challenging fistulas, aiding identification of secondary extensions which might otherwise be missed and lead to inevitable recurrence. And of course, the same benefit would apply to other reparative techniques performed with a clearer understanding of the tract anatomy.

The patient–clinician relationship centres around shared decision making, with the clinician offering options with their associated risks and benefits, and patients deciding which options are most appropriate to their own symptoms and goals. A variety of factors including the patient’s prior understanding and the clinician’s interpersonal skills, as well as the complexity of the decision and a balance of the patient’s ability to understand and the clinician’s ability to explain, govern the success of this decision-making process. Some of these factors are not modifiable but clinicians can improve their delivery of information, including using adjuncts. When the complexity is related to anatomical understanding, 3D models provide a theoretical advantage. An example of this benefit was demonstrated in a recent study on congenital heart defects, which quantified the benefit of 3D models in facilitating communication with patients.<sup>29</sup> The study also demonstrated patients’ enthusiasm for the technique, with over three quarters of the study participants asking to keep the models. Further work is needed to confirm this in patients with perianal Crohn’s fistula, particularly in facilitating informed consent.

Another potential benefit is in medical education. Due to the complexity of tracts and their relationship with the anal sphincter, perianal fistulas are an example of a topic that is not only hard to understand but also hard to teach. Such topics lend themselves to 3D reconstruction very well. Much of the key to understanding the treatment options, difficulties, and likely success of surgery is in deciphering the exact morphology of the tract(s) and the amount of sphincter involved. If the trainee does not understand the fistula, they cannot plan surgery, consent patients or understand how their consultant does so. We have previously demonstrated an international appetite

for 3D reconstructions at an international conference at which 85% of respondents expect 3D modelling to be useful for perianal fistula surgery and 88% would use 3D modelling if available.<sup>30</sup> The precise metric needed to demonstrate clinical utility is part of future work. We postulate that the metric will be stakeholder (surgeon: generalist *versus* specialist, trainee, patient) and time specific (pre-, peri-, postoperatively, such as in describing the nature of a case to a lay audience as part of a medico-legal proceeding).

The aim of this feasibility study was to prove the concept and develop experience in producing 3D imaging, 3D models and MRI fistulography.

There are several limitations of this proof-of-concept study. Firstly, expertise is required to create the 3D images, models and fistulography. The accuracy of the segmentation of the fistula and the sphincter complex is dependent on the radiologist, but the technique is generalizable and uses open-source software. The use of 3D printing is increasingly widespread, and institutions in which a need exists for such models are often affiliated with universities and can be granted access to 3D printers. An additional resource consideration is cost (printer and materials) and as such, one may choose to limit such techniques to complex or refractory cases. Future improvements in clinical applicability, in terms of raw materials to print with, speed of printing and reduced costs, are likely to make 3D printing more widespread.<sup>31</sup> Ultimately, the benefit of these techniques in patient understanding, training of junior surgeons and communication between radiologist and surgeon, needs to be demonstrated in further work, underway at our institution.

### Conclusion

MRI fistulography and 3D-printed models have been developed with specific functions in mind. We suggest that 3D-printed models will offer a medium to enhance the education of trainees and a useful adjunct for communication with patients. MRI fistulography is a concept that has been derived from the success of virtual colonoscopy and offers the operating surgeon a realistic road map to follow. Both of these innovative techniques offer intuitive advantages to surgeons, trainees and patients but the effect of these needs objective assessment.

### Acknowledgements

The authors would like to acknowledge the aid of TouchSurgery™. All authors have contributed to this manuscript.

### Funding

Kapil Sahnan is supported by a Royal College of Surgeons of England Research Crohn's and Colitis UK Scholarship and ForCrohn's charity grant. The other authors have no conflict of interests or financial ties to disclose.

### Conflict of interest statement

The authors declare that there is no conflict of interest.

### References

1. Mahadev S, Young JM, Selby W, *et al.* Quality of life in perianal Crohn's disease: what do patients consider important? *Dis Colon Rectum* 2011; 54: 579–585.
2. Hagggett PJ, Moore NR, Shearman JD, *et al.* Pelvic and perineal complications of Crohn's disease: assessment using magnetic resonance imaging. *Gut* 1995; 36: 407–410.
3. Ardizzone S and Porro GB. Perianal Crohn's disease: overview. *Dig Liver Dis* 2007; 39: 957–958.
4. Beaugerie L, Seksik P, Nion-Larmurier I, *et al.* Predictors of Crohn's disease. *Gastroenterology* 2006;130:650–656.
5. Hughes LE. Surgical pathology and management of anorectal Crohn's disease. *J R Soc Med* 1978; 71: 644–651.
6. Adegbola SO, Sahnan K, Pellino G, *et al.* Short-term efficacy and safety of three novel sphincter-sparing techniques for anal fistulae: a systematic review. *Tech Coloproctol* 2017; 21: 775–782.
7. Emile SH, Elfeki H, Shalaby M, *et al.* A Systematic review and meta-analysis of the efficacy and safety of video-assisted anal fistula treatment (VAAFT). *Surg Endosc* 2017; 32: 2084–2093.
8. Adegbola SO, Sahnan K, Strouhal R, *et al.* Video-assisted anal fistula treatment (VAAFT) in patients with Crohn's perianal fistula – a palliative approach. *Colorectal Dis* 2017; 19: 4–13. DOI:10.1111/codi.13850.
9. Garcia J, Yang Z, Mongrain R, *et al.* 3D printing materials and their use in medical education: a

- review of current technology and trends for the future. *BMJ Simul Technol Enhanc Learn* 2018; 4: 27–40.
10. John NW. The impact of Web3D technologies on medical education and training. *Comput Educ* 2007; 49: 19–31.
  11. Fadero PE and Shah M. Three dimensional (3D) modelling and surgical planning in trauma and orthopaedics. *Surgeon* 2014; 12: 328–333.
  12. Sahnan K, Pellino G, Adegbola SO, *et al.* Development of a model of three-dimensional imaging for the preoperative planning of TaTME. *Tech Coloproctol*. Epub ahead of print 29 November 2017. DOI: 10.1007/s10151-017-1724-7.
  13. Sahnan K, Adegbola SO, Tozer PJ, *et al.* Improving the Understanding of Perianal Crohn Fistula Through 3D Modeling. *Ann Surg*. Epub ahead of print 11 December 2017. DOI: 10.1097/SLA.0000000000002629.
  14. Yushkevich PA, Piven J, Hazlett HC, *et al.* User-guided 3D active contour segmentation of anatomical structures: significantly improved efficiency and reliability. *Neuroimage* 2006; 31: 1116–1128.
  15. Meshlab. MeshLab, <http://www.meshlab.net/> (accessed 17 October 2017).
  16. Buchanan GN, Halligan S, Bartram CI, *et al.* Clinical examination, endosonography, and MR imaging in preoperative assessment of fistula in ano: comparison with outcome-based reference standard. *Radiology* 2004; 233: 674–681.
  17. Buchanan G, Halligan S, Williams A, *et al.* Effect of MRI on clinical outcome of recurrent fistula-in-ano. *Lancet* 2002; 360: 1661–1662.
  18. Beets-Tan RG, Beets GL, Van der Hoop AG, *et al.* Preoperative MR imaging of anal fistulas: does it really help the surgeon? *Radiology* 2001; 218: 75–84.
  19. Tolan DJ. Magnetic resonance imaging for perianal fistula. *Semin Ultrasound CT MR* 2016; 37: 313–322.
  20. Samaan MA, Puylaert CAJ, Levesque BG, *et al.* The development of a magnetic resonance imaging index for fistulising Crohn's disease. *Aliment Pharmacol Ther*. Epub ahead of print 27 June 2017. DOI: 10.1111/apt.14190.
  21. Van Ginneken B. Fifty years of computer analysis in chest imaging: rule-based, machine learning, deep learning. *Radiol Phys Technol* 2017; 10: 23–32.
  22. Lee H, Tajmir S, Lee J, *et al.* Fully automated deep learning system for bone age assessment. *J Digit Imaging* 2017; 30: 427–441.
  23. Rincón M, Díaz-López E, Selnes P, *et al.* Improved automatic segmentation of white matter hyperintensities in MRI based on multilevel lesion features. *Neuroinformatics* 2017; 15: 231–245.
  24. Mahapatra D, Schuffler PJ, Tielbeek JA, *et al.* Automatic detection and segmentation of Crohn's disease tissues from abdominal MRI. *IEEE Trans Med Imaging* 2013; 32: 2332–2347.
  25. Goyanes A, Scarpa M, Kamlow M, *et al.* Patient acceptability of 3D printed medicines. *Int J Pharm* 2017; 530: 71–78.
  26. Gecse KB, Bemelman W, Kamm MA, *et al.* A global consensus on the classification, diagnosis and multidisciplinary treatment of perianal fistulising Crohn's disease. *Gut* 2014; 63:1381–1392.
  27. Sahnan K, Adegbola SO, Tozer PJ, *et al.* Perianal abscess. *BMJ* 2017; 356: j475.
  28. Meinero P. Video-assisted anal fistula treatment (VAAFT): a novel sphincter-saving procedure for treating complex anal fistulas. *Tech Coloproctol* 2011; 15: 417–422.
  29. Biglino G, Capelli C, Wray J, *et al.* 3D-manufactured patient-specific models of congenital heart defects for communication in clinical practice: feasibility and acceptability. *BMJ Open* 2015; 5: e007165.
  30. Sahnan K, Adegbola SO, Tozer PJ, *et al.* Experience of 3D modelling in perianal fistula disease and survey of international surgical interest. *J Crohn's Colitis* 2017; 11(Suppl. 1): S202.
  31. Yeong XL, Ko Teck Ee R, Ong CW, *et al.* The importance of 3D printing in vascular surgical simulation and training. *J Surg Simul* 2017; 4: 23–28.