

Subtrochanteric Femoral Insufficiency Fracture in Woman on Bisphosphonate Therapy for Glucocorticoid-Induced Osteoporosis

Lisabeth A. Bush, M.D., and Felix S. Chew, M.D.

Citation: Bush LA, Chew FS. Subtrochanteric femoral insufficiency fracture in woman on bisphosphonate therapy for glucocorticoid-induced osteoporosis. *Radiology Case Reports*. [Online] 2009;4:261.

Copyright: © 2009 The Authors. This is an open-access article distributed under the terms of the Creative Commons Attribution-NonCommercial-NoDerivs 2.5 License, which permits reproduction and distribution, provided the original work is properly cited. Commercial use and derivative works are not permitted.

Abbreviations: CT, computed tomography; MRI, magnetic resonance imaging; MDP, methylene disphosphonate; IV, intravenous; PTH, parathyroid hormone; SSBT, severely suppressed bone turnover

Lisabeth A. Bush, M.D. (Email: lisabeth.bush@gmail.com), and Felix S. Chew, M.D., are in the Department of Radiology University of Washington, Seattle, WA, United States of America.

The views expressed in this manuscript are those of the authors and do not reflect the official policy or position of the Department of the Army, Department of Defense, or the U.S. Government.

Published: January 1, 2009

DOI: 10.2484/rcr.v4i1.261

Abstract

We present the case of an 85-year-old woman who sustained a subtrochanteric femoral shaft insufficiency fracture after receiving bisphosphonate therapy for osteoporosis. After more than 6 years of taking risedronate sodium (Actonel) and daily supplemental calcium carbonate and vitamin D, the patient developed right anterior thigh pain that was worse with weight-bearing. A small, pyramidal ridge of cortical bone was demonstrated by radiographs and CT along the antero-lateral subtrochanteric region of the right femoral shaft. On MRI, there was focally increased T2 signal in the adjacent bone marrow. Radionuclide bone scan showed moderately-intense, focally-increased uptake. The lesion was recognized as a potential stress riser for fracture; however, before a prophylactic intramedullary rod could be placed, the patient suffered a low-energy insufficiency fracture through the lesion. In the setting of bisphosphonate therapy for osteoporosis, a painful pyramidal projection of cortical bone in the subtrochanteric femoral shaft should be recognized as an impending insufficiency fracture and treated expeditiously.

Introduction

We present the case of an insufficiency fracture of the proximal femoral shaft in an 85-year-old woman who was receiving bisphosphonate therapy to reduce the fracture risk secondary to severe osteoporosis which was likely multi-factorial in etiology with advanced age, postmenopausal state, and prolonged use of glucocorticoid medications all likely being contributory. This fracture is

identical in presentation and appearance to other cases of insufficiency fractures of the proximal femoral shaft described in patients who developed severe suppression of bone turnover with prolonged oral bisphosphonate therapy. Abnormal bone remodeling due to prolonged osteoclast suppression appears to lead to insufficiency fractures of the subtrochanteric femoral shaft. It is ironic that medications known to increase bone density by decreasing the activity of osteoclasts, could in certain patients, contribute to severe suppression of bone turnover characterized by inadequate remodeling and the formation of insufficiency fractures.

Case Report

An 85-year-old woman presented with limp and anterior right thigh pain. After more than 6 years of taking risedronate sodium (Actonel) at a dose of 35mg/week, as well as supplemental calcium carbonate and Vitamin D, the patient complained of 2-3 months of persistent anterior right thigh pain that was worse with weight bearing. This pain was different from previous episodes of pain related to spinal stenosis and polymyalgia rheumatica. Her past medical history was significant for osteoporosis with prior fractures of the pelvis, spine, and both ankles, polymyalgia rheumatica, and disc degeneration with spinal stenosis. She had taken oral corticosteroids for polymyalgia rheumatica for many years with a daily dose alternating between 7.5 and 10 mg of prednisone. On physical exam, her pain was non-radiating, and her gait was antalgic. Initially, an MRI was performed at an outside institution, and the patient was subsequently referred to our institution for further evaluation. The MRI report described focally increased T2 signal in the right lateral femur. At our institution, a CT was performed as well as radiographs, and a bone scan. Radiographic evaluation of the femur demonstrated a focal pyramidal-shaped projection of bone on the lateral cortex (Fig. 1). The bone scan performed following injection Tc99m methylene diphosphonate (MDP) (Fig. 2) revealed a moderately-intense focus of increased uptake at the subtrochanteric region of the right femur and a degenerative pattern of activity in the spine, shoulders, knees, and wrists without evidence of other lesions concerning for metastatic disease. CT demonstrated a focal beak of cortical thickening on the lateral cortex (Fig. 3), and 3-dimensional reformations showed the lesion to be a domed roughly-pyramidal ridge, similar to a volcano such as Mt. Rainier (Fig 4). Although no fracture line was evident, this lesion was recognized as potential riser for fracture and the patient was referred to orthopedics. The patient hesitated at their recommendation for biopsy and prophylactic placement of an intramedullary rod to prevent fracture completion.

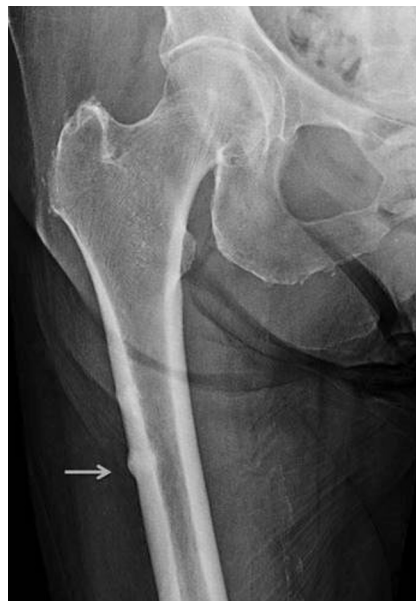

Figure 1. 85-year-old woman on bisphosphonate therapy. Radiographic evaluation of the femur demonstrated mild, diffuse cortical thickening and a focal, domed, conical, projection along the lateral cortex (arrow).

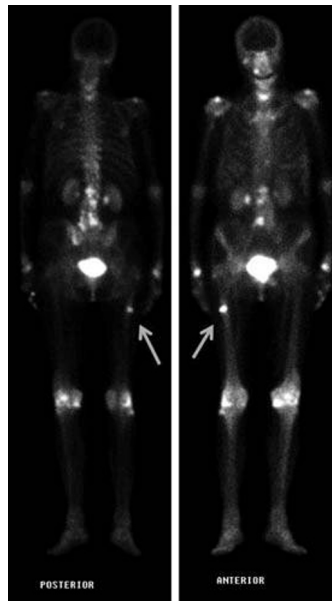


Figure 2. 85-year-old woman on bisphosphonate therapy. Tc99m MDP bone scan shows a focus of moderately intense uptake at the subtrochanteric region of the right femur (arrows) and a degenerative pattern of activity in the spine, shoulders, knees, and wrists, without evidence of metastatic disease.

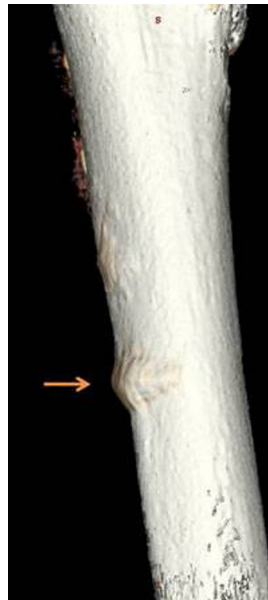

Figure 3. 85-year-old woman on bisphosphonate therapy. 3D surface rendered CT reformation demonstrates the cortical ridge at the antero-lateral aspect of the femur at the junction of the proximal and middle thirds (arrow).



Figure 4. The volcanic mountain peak, Mt. Rainier, as viewed from Puget Sound offshore Seattle, Washington. (Courtesy Mahesh Thapa, M.D., starvingphotographer.com.)

Nearly one month later, on her way to an appointment to discuss additional treatment options for this lesion, the patient stumbled on a curb. With this minimal trauma, the insufficiency fracture completed. Radiographs of the fracture showed a severely-angulated, simple, transverse, subtrochanteric femoral shaft fracture at the junction of the proximal and middle thirds (Fig 5). Following closed reduction, the fracture is seen to extend through the middle of the cortical ridge seen on the earlier radiograph (Fig. 6).

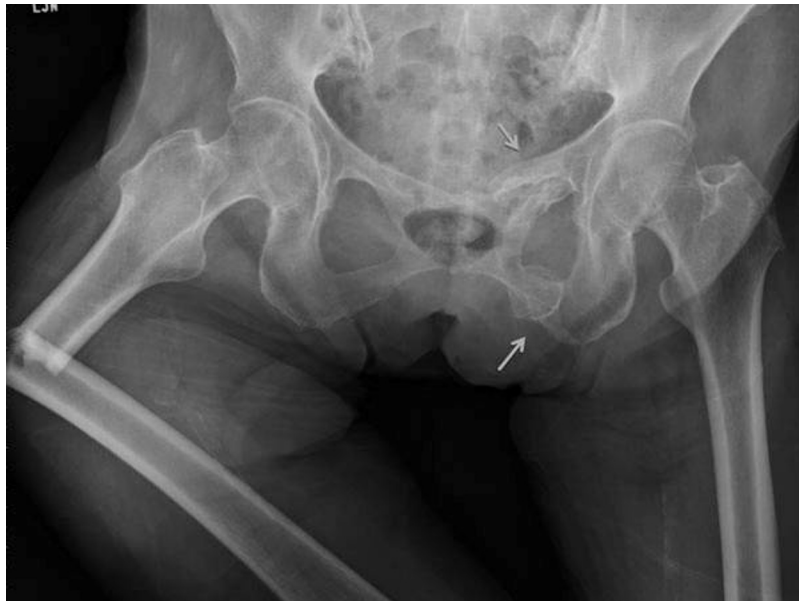

Figure 5. 85-year-old woman on bisphosphonate therapy. Post-fracture radiograph depicts a severely-angulated, simple, transverse, subtrochanteric femoral shaft fracture at the junction of the proximal and middle thirds that extends through the middle of the triangular cortical ridge seen on the earlier studies. Old, healed fractures of the superior and inferior rami of the left obturator ring are also evident (arrows).

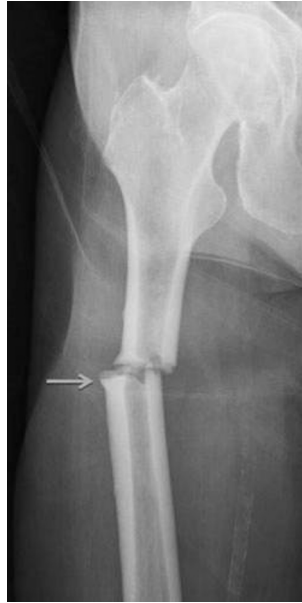

Figure 6. 85-year-old woman on bisphosphonate therapy. Proximal femoral shaft fracture following closed reduction of the marked angular deformity, the simple transverse fracture extends through the beak-shaped region of the insufficiency fracture (arrow). Mild diffuse cortical thickening is also present.

The patient underwent surgical reduction and internal fixation. A relatively long and thick reconstruction nail with two pins in the femoral neck was utilized due to the osteoporotic capaciousness of her intramedullary canal and to prevent formation of proximal femoral neck and distal femoral shaft stress risers which could lead to subsequent fractures. At the time of surgery, a curetted bone specimen was obtained by reaming for intramedullary rod placement. Histological examination of this specimen confirmed the absence of malignant disease.

Due to prolonged bisphosphonate usage and both chronic and ongoing glucocorticoid use, she was considered at risk for poor fracture healing, and her medications were adjusted to optimize healing. Medical necessity required that her steroid medication be continued; however, her bisphosphonate medication, risedronate sodium (Actonel), was discontinued. Her calcium and vitamin D supplementation were continued unchanged, and an anabolic agent, recombinant human parathyroid hormone, teriparatide (Forteo), was initiated at 20 micrograms daily by subcutaneous injection.

Follow up radiographs of the fracture site obtained ten (Fig. 7) and nineteen weeks (Fig. 8) after surgery demonstrated abundant fracture callus and were deemed consistent with appropriate interval fracture healing. The patient has recovered uneventfully.

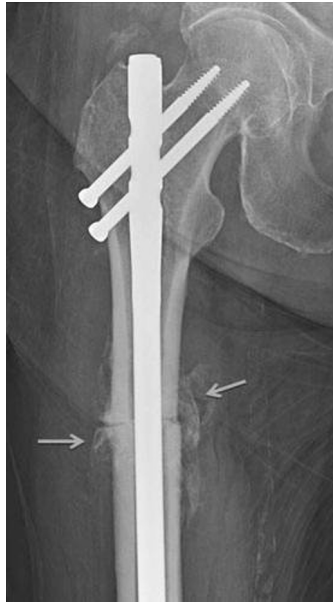


Figure 7. 85-year-old woman on bisphosphonate therapy. Subtrochanteric femur fracture 10 weeks post operative fixation with an 11mm x 40cm reconstruction rod with 75 and 85mm screws proximally and a 65 mm locking screw distally (not included in this image). Exuberant callus is present at the fracture site (arrows).

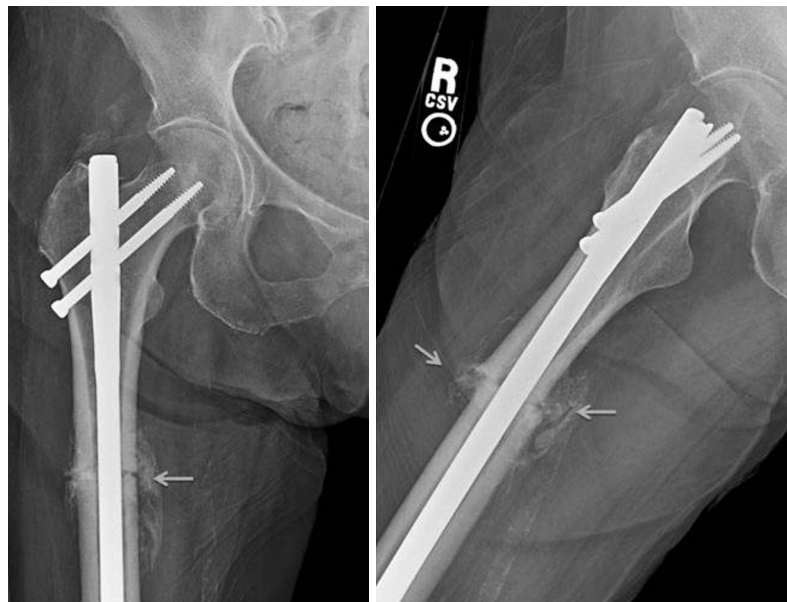

Figure 8. 85-year-old woman on bisphosphonate therapy. Subtrochanteric femur fracture 19 weeks post operative fixation. (A) AP and lateral (B) lateral views with exuberant callus at the fracture site (arrows) in the proximal femoral diaphysis, compatible with appropriate healing.

Discussion

The femoral shaft is the strongest portion of the most resilient bone in the body, and therefore, subtrochanteric shaft fracture is associated with violent force or underlying bony abnormality to include tumor, Paget disease, excessive exercise, hypophosphatemic osteomalacia, pycnodysostosis,

fluorosis, or severe osteoporosis. [1-9] Osteoporotic femoral fractures are associated with a higher degree of comminution [10].

In 2005, Odvina et al. identified a group of 9 patients who developed spontaneous non-spinal fractures while on long-term alendronate. These non-traumatic fractures involved skeletal areas rich in cortical bone such as the femoral shaft, pubic bone, and ischium, and were considered atypical for osteoporotic fractures [11]. Bone biopsies in all demonstrated severe suppression of bone turnover (SSBT). The patients also on estrogen or glucocorticoids presented with fractures after a shorter duration of bisphosphonate therapy. Post-fracture continuation of bisphosphonate therapy was also associated with delayed fracture healing [11].

In 2007, an apparent increase in the number of subtrochanteric femur fractures in women between the ages of 50 and 70, many of whom had received alendronate for 3 or more years prompted Goh et al. to further evaluate these fractures. In a series of 13 patients with low energy subtrochanteric fractures, patients on alendronate had a higher incidence of simple transverse or short oblique fractures (89%) as opposed to the patients with osteoporosis not receiving bisphosphonates (0%) [12]. Approximately 55-76% of the patients with bisphosphonate-related fractures had prodromal pain prior to fracture completion whereas none of the patients with fractures due solely to severe osteoporosis in the absence of long-term alendronate had prodromal pain [12, 13]. Their further retrospective review determined a radiographically-identifiable insufficiency fracture configuration characterized by focal, lateral cortical thickening of the subtrochanteric femur with subsequent development of a transverse fracture through the lesion [13]. Additionally, 53% had bilateral findings of stress reaction or fracture [13].

In 2008, Neviasser et al. evaluated 70 low energy fractures of the femoral shaft and identified that the simple transverse fracture pattern with unicortical beak was 98% specific for alendronate use and was more likely to be seen in patients with long term use; an average of 6.9 years of alendronate use in patients with this fracture type compared with 2.5 years in patients on alendronate but not displaying this fracture pattern [15].

In 2008, Visekruna et al. described severely suppressed bone turnover (SSBT) and atypical skeletal fragility with proximal femoral metadiaphyseal/subtrochanteric fractures in 3 patients on long term bisphosphonate therapy, all three of whom were receiving another medication (estrogen, glucocorticoid, or raloxifene) that likely further suppressed bone remodeling beyond the effect of the alendronate alone [16]. Given the prolonged residence time of bisphosphonate medications in bone, their non-metabolized nature, and their ability to cause irreversible osteoclast failure, Visekruna et al. raise concern that although beneficial in most patients, certain susceptible patients may experience atypical skeletal fragility related to oral bisphosphonates, particularly when administered with other anti-remodeling agents. They further suggested a potential role for teriparatide to facilitate fracture healing in this scenario of suppressed bone remodeling [16]. Recombinant human parathyroid hormone PTH (1-34); teriparatide (Forteo) can be systemically administered to increase bone as it promotes osteoblastogenesis and decreases osteoblast apoptosis [17-19].

After postmenopausal and senile osteoporosis, glucocorticoid-induced osteoporosis is the third most common etiology of osteoporosis [20]. Common expressions of glucocorticoid-induced osteoporosis include fractures of the spine and ribs and osteonecrosis of the femoral heads [20]. Glucocorticoid medications contribute to osteopenia by several mechanisms, including early osteoclast stimulation and chronic osteoblast suppression [19]. It seems reasonable that teriparatide, may be beneficial in cases of glucocorticoid-induced osteoporosis and has been demonstrated to increase bone density in these patients [18].

There is potential for insufficiency fractures in patients on long term, high dose, or IV bisphosphonates; particularly if there are other co-administered medications or factors that inhibit bone remodeling. In the setting of bisphosphonate therapy for osteoporosis, a painful pyramidal projection of cortical bone in the subtrochanteric femoral shaft should be recognized as an impending/incomplete insufficiency fracture and treated expeditiously to reduce the risk of fracture completion.

It is necessary to balance the important benefit of bisphosphonate therapy in osteoporotic against the potential risk of over-suppression and subsequent insufficiency fracture. Optimal protocols for the dosage and duration of bisphosphonate therapy and preferred clinical management of a patient with an impending or completed insufficiency fracture while on bisphosphonates or other anti-remodeling medications deserve additional consideration. Because bisphosphonates are not metabolized, have a long dwell time, and may adversely affect fracture healing in some patients for months or even years after discontinuation, additional steps in addition to bisphosphonate discontinuation may be needed to promote fracture healing [11, 21, 22, 23, 24, 25].

This case is a paradigm of a new pattern of fractures noted in patients on bisphosphonates. It demonstrates characteristic radiographic features which may help identify patients at risk for impending fractures and suggests a possible role for teriparatide in treatment. Our patient appears to represent a “textbook presentation” of insufficiency fracture related to prolonged bisphosphonate medication on a background of severe glucocorticoid-induced osteoporosis. She presented with prodromal pain, a volcano-shaped conical ridge at the lateral subtrochanteric femur, and a subsequent simple transverse fracture with low energy mechanism. These findings are not characteristic of an osteoporotic fracture (due to the prodromal pain and lack of comminution), nor is the subtrochanteric femur a standard site for glucocorticoid-induced complications which primarily involve fractures of the ribs and spine, and osteonecrosis of the femoral head.

This case further highlights a paucity of data addressing the clinical management of these lesions. It is unknown which patients will best benefit from prophylactic placement of an intramedullary rod to prevent fracture completion and in which cases a less-invasive pharmaceutical modality may achieve fracture healing. Given our current understanding of this syndrome of insufficiency fracture in the setting of severely suppressed bone turnover, the discontinuation of bisphosphonate medication, and use of teriparatide seem to be the best actions; however, in years to come, more information will certainly refine the understanding and management of these patients.

References

1. Resnick D, Goergen T, Niwayama G. Physical Injury: Concepts and Terminology. In: Resnick D (editor): *Diagnosis of Bone and Joint Disorders*, 3rd edition. Philadelphia, PA: Saunders; 1995, pp. 2561-692.
2. Bucholz RW, Brumback RJ. Fractures of the shaft of the femur In: *Rockwood and Green's Fractures in Adults* 4th edition. Philadelphia, PA:Lippincott-Raven;1996, pp1827-918.
3. Resnick D, Niwayama G. Osteoporosis. In: Resnick D (editor): *Diagnosis of Bone and Joint Disorders*, 3rd edition. Philadelphia, PA: Saunders; 1995, pp. 1783-853.
4. Resnick D, Niwayama G. Paget's Disease. In: Resnick D (editor): *Diagnosis of Bone and Joint Disorders*, 3rd edition. Philadelphia, PA: Saunders; 1995, pp. 1946-1948.

5. Butler JE, Brown SL, McConnell BG. Subtrochanteric stress fractures in runners. *Am J Sports Med* 1982;10(4):228-32. [[PubMed](#)]
6. Leinberry CF, McShane RB, Stewart Jr WG, Hume EL. A displaced subtrochanteric stress fracture in a young amenorrheic athlete. *Am J Sports Med* 1992; 20(4):485-7. [[PubMed](#)]
7. Esterberg J, Kassim RA, Redmon J, Coad J, Macari GS, Saleh KJ. Hip pain in a case of hypophosphatemic osteomalacia. *Am J Orthop*. 2003 Sep;32(9):455-8. [[PubMed](#)]
8. Roth VG. Pycnodysostosis presenting with bilateral subtrochanteric fractures: case report. *Clin Orthop Relat Res* 1976;(117):247-53 [[PubMed](#)]
9. Schnitzler CM, Wing JR, Gear KA, Robson HJ. Bone fragility of the peripheral skeleton during fluoride therapy for osteoporosis. *Clin Orthop Relat Res* 1990;(261):268-75 [[PubMed](#)]
10. Bergman GD, Winquist RA, Mayo KA, Hansen ST Jr. Subtrochanteric fracture of the femur. Fixation using the Zickel nail. *J Bone Joint Surg Am*. 1987 Sep;69(7):1032-40. [[PubMed](#)]
11. Odvina CV, Zerwekh JE, Rao DS, Maalouf N, Gottschalk FA, Pak CY. Severely suppressed bone turnover: a potential complication of alendronate therapy. *J Clin Endocrinol Metab*. 2005 Mar;90(3):1294-301. Epub 2004 Dec 14. [[PubMed](#)]
12. Goh SK, Yang KY, Koh JS, Wong MK, Chua SY, Chua DT, Howe TS. Subtrochanteric insufficiency fractures in patients on alendronate therapy: a caution. *J Bone Joint Surg Br*. 2007 Mar;89(3):349-53. [[PubMed](#)]
13. Kwek EB, Goh SK, Koh JS, Png MA, Howe TS. An emerging pattern of subtrochanteric stress fractures: a long-term complication of alendronate therapy? *Injury*. 2008 Feb;39(2):224-31. Epub 2008 Jan 28. [[PubMed](#)]
14. Kwek EB, Koh JS, Howe TS. More on atypical fractures of the femoral diaphysis. *N Engl J Med*. 2008 Jul 17;359(3):316-7; author reply 317-8. [[PubMed](#)]
15. Neviasser AS, Lane JM, Lenart BA, Edobor-Osula F, Lorich DG. Low-energy femoral shaft fractures associated with alendronate use. *J Orthop Trauma*. 2008 May-Jun;22(5):346-50. [[PubMed](#)]
16. Visekruna M, Wilson D, McKiernan FE. Severely suppressed bone turnover and atypical skeletal fragility. *J Clin Endocrinol Metab*. 2008 Aug;93(8):2948-52. Epub 2008 Jun 3. [[PubMed](#)]
17. Alkhiary YM, Gerstenfeld LC, Krall E, Westmore M, Sato M, Mitlak BH, Einhorn TA. Enhancement of experimental fracture-healing by systemic administration of recombinant human parathyroid hormone (PTH 1-34). *J Bone Joint Surg Am*. 2005 Apr;87(4):731-41. [[PubMed](#)]
18. Saag KG, Shane E, Boonen S, Marín F, Donley DW, Taylor KA, Dalsky GP, Marcus R. Teriparatide or alendronate in glucocorticoid-induced osteoporosis. *N Engl J Med*. 2007 Nov 15;357(20):2028-39. [[PubMed](#)]
19. Jia D, O'Brien CA, Stewart SA, Manolagas SC, Weinstein RS. Glucocorticoids act directly on osteoclasts to increase their life span and reduce bone density. *Endocrinology*. 2006 Dec;147

(12):5592-9. Epub 2006 Aug 24. [[PubMed](#)]

20. Weinstein RS, Jilka RL, Parfitt AM, Manolagas SC. Inhibition of osteoblastogenesis and promotion of apoptosis of osteoblasts and osteocytes by glucocorticoids. Potential mechanisms of their deleterious effects on bone. *J Clin Invest*. 1998 Jul 15;102(2):274-82. [[PubMed](#)]

21. Ott SM. Long-term safety of bisphosphonates. *J Clin Endocrinol Metab* 2005;90(3):1897-9. [[PubMed](#)]

22. Ott SM. Osteoporosis web site: <http://courses.washington.edu/bonephys> Accessed 20 August 2008.

23. Bagger YZ, Tanako LB, Alexandersen P, Ravn P, Christiansen C. Alendronate has a residual effect on bone mass in postmenopausal Danish women up to 7 years after treatment withdrawal. *Bone* 2003;33:301-7. [[PubMed](#)]

24. Demiralp B, Ilgan S, Ozgur Karacalioglu A, Cicek EI, Yildirim D, Erler K. Bilateral femoral insufficiency fractures treated with inflatable intramedullary nails: a case report. *Arch Orthop Trauma Surg*. 2007 Sep;127(7):597-601. Epub 2007 Jun 16. [[PubMed](#)]

25. Stock JL, Bell NH, Chesnut CH 3rd, Ensrud KE, Genant HK, Harris ST, McClung MR, Singer FR, et al. Increments in bone mineral density of the lumbar spine and hip and suppression of bone turnover are maintained after discontinuation of alendronate in postmenopausal women. *Am J Med*. 1997 Oct;103(4):291-7. [[PubMed](#)]

26. Burr DB, Forwood MR, Fyhrie DP, Martin RB, Schaffler MB, Turner CH. Bone microdamage and skeletal fragility in osteoporotic and stress fractures. *J Bone Miner Res*. 1997 Jan;12(1):6-15. [[PubMed](#)]

27. Suckel AA, Dietz K, Wuelker N, Helwig P. Evaluation of complications of three different types of proximal extra-articular femur fractures: differences in complications, age, sex and surviving rates. *Int Orthop*. 2007 Oct;31(5):689-95. Epub 2006 Oct 11. [[PubMed](#)]

28. Mashiba T, Hirano T, Turner CH, Forwood MR, Johnston CC, Burr DB. Suppressed bone turnover by bisphosphonates increases microdamage accumulation and reduces some biomechanical properties in dog rib. *J Bone Miner Res*. 2000 Apr;15(4):613-20. [[PubMed](#)]

29. Melton LJ 3rd, Thamer M, Ray NF, Chan JK, Chesnut CH 3rd, Einhorn TA, Johnston CC, Raisz LG, Silverman SL, Siris ES. Fractures attributable to osteoporosis: report from the National Osteoporosis Foundation. *J Bone Miner Res*. 1997 Jan;12(1):16-23. [[PubMed](#)]

30. Kanis JA, Oden A, Johnell O, Jonsson B, De Laet C, Dawson A. The burden of osteoporotic fractures: a method for setting intervention thresholds. *Osteoporos Int*. 2001;12(5):417-27. [[PubMed](#)]

31. Metcalfe D. The pathophysiology of osteoporotic hip fracture. *Mcgill J Med*. 2008 Jan;11(1):51-7. [[PubMed](#)]

32. Lenart BA, Lorich DG, Lane JM. Atypical fractures of the femoral diaphysis in postmenopausal

women taking alendronate. N Engl J Med. 2008 Mar 20;358(12):1304-6. [[PubMed](#)]

This work is licensed under a [Creative Commons Attribution-NonCommercial-NoDerivs 2.5 License](#).