

Unsuspected Skin Metastasis of Adenocarcinoma of the Prostate in a Patient on Goserelin (Zoladex)

Timothy Uzoma Mbaeri, Jideofor Chukwuma Orakwe, Ogochukwu I Ezejiofor¹

Department of Surgery,
Division of Urology,
Nnamdi Azikiwe University,
¹Department of Internal
Medicine, Nnamdi Azikiwe
University, Awka, Nigeria

ABSTRACT

Prostate cancer remains the most common noncutaneous cancer in men, especially in this era of prostate-specific antigen assay. Prostate cancer metastases have been known to commonly affect the lymphatics, bones, and lungs. Prostate cancer metastasis to the skin is very rare (<1%) and often signifies a terminal disease. Involvement of the skin has been thought to be through lymphatic spread by embolization or permeation, hematogenous spread, and implantation during surgery (port site in radical prostatectomy). We report a 74-year-old man on management for advanced prostate cancer with subcutaneous goserelin (Zoladex) but developed skin metastasis in the course of treatment. The skin metastasis in our patient, however, was initially localized to the site of the regions of subcutaneous goserelin injection that we imagined if there is a link between the two. We reviewed the literature and currently found no connection. Is there truly a link?

KEYWORDS: Goserelin, prostate cancer, skin metastasis

INTRODUCTION

Prostate cancer remains the most common noncutaneous cancer in men, especially in this era of routine screening for prostate-specific antigen (PSA). Prostate cancer has been known to metastasize commonly to the lymphatics, bone, and lungs, but metastasis to the skin is very rare and often signifies a terminal disease.^[1,2] The skin areas reported so far vary from head, face, neck, chest, and trunk to the knee, but it has been reported to frequently affect the genitalia and suprapubic region.^[2-4] Skin involvement has been suggested to signify terminal disease. Involvement of the skin has been thought to be through lymphatic spread by embolization or permeation, hematogenous spread, and implantation during surgery (port site in radical prostatectomy), etc.^[5,6]

Patients usually present late in our environment as alternative care is often the first port of call for many patients with presentation to surgeons when desired results are not obtained. In spite of this late presentation, skin metastasis is still not common in our practice, and thus we report an abnormal skin metastatic finding with the possibility of multiple interpretations.

The skin metastasis in our patient, however, was initially localized to the site of the regions of subcutaneous

goserelin injection that we imagined if there is a link between the two or a mere coincidence.

We report the case presentation of a prostate cancer patient who developed skin metastasis and we provide a review of literature.

CASE REPORT

A 74-year-old man, retired civil servant, presented through surgery outpatient clinic with 1-year history of bilateral scrotal and lower-limb swelling. The scrotal swelling was gradual in onset, painless, and progressively worsened with involvement and partial engulfment/burying of his penis. The bilateral lower-limb swelling was painless and not associated with breathlessness or orthopnea. There was no lower urinary tract symptom. There was no history of trauma, pelvic/groin surgery, and irradiation.

For the above complaints, he went to traditionalist who gave oral concoction and scrotal injection and made

Address for correspondence: Dr. Timothy Uzoma Mbaeri,
Department of Surgery, Division of Urology,
Nnamdi Azikiwe University, Nnewi Campus, Awka, Nigeria.
E-mail: uzomambaeri@yahoo.com

This is an open access journal, and articles are distributed under the terms of the Creative Commons Attribution-NonCommercial-ShareAlike 4.0 License, which allows others to remix, tweak, and build upon the work non-commercially, as long as appropriate credit is given and the new creations are licensed under the identical terms.

For reprints contact: reprints@medknow.com

How to cite this article: Mbaeri TU, Orakwe JC, Ezejiofor OI. Unsuspected skin metastasis of adenocarcinoma of the prostate in a patient on goserelin (Zoladex). Niger J Surg 2018;24:138-41.

Access this article online

Quick Response Code:



Website: www.nigerianjsurg.com

DOI: 10.4103/njs.NJS_15_17

cuts/incisions on the scrotum and lower extremities all to no avail. He then decided to present to our center.

On examination, he was an elderly man with no obvious distress, anicteric, afebrile, and pale, with bilateral symmetrical pitting leg edema and scarification marks all over the lower extremities.

His pulse rate was 88 beats/min, respiratory rate was 18 cycles/min, blood pressure was 100/80 mmHg, and temperature was 37°C. The chest was clinically clear.

Abdominal and rectal examination was unremarkable with prostate barely enlarged with benign features.

External genitalia showed edematous scrotum and penis. Scrotum measured 15 cm × 15 cm, was nontender and thickened with hyperkeratotic penoscrotal skin with the testes barely palpable.

An impression of genital lymphedema secondary to chronic cellulitis from multiple local incisions and herbal application was made. He was admitted into the male surgical ward, investigated, and resuscitated.

Requested laboratory and radiological investigations with results include full blood count (FBC): hematocrit: 24%, white blood cell: $6.6 \times 10^3/\text{ml}$, neutrophil: 36%, lymphocyte: 59%, monocyte: 04%, and eosinophil: 01%; platelet: $268 \times 10^3/\text{ml}$; erythrocyte sedimentation rate: 120 mm/h; serum PSA (total: 158.4 ng/ml; % free: 19.4); urinalysis: normal; skin snip and blood film for microfilaria were negative; retroviral screening was negative; S/E/U/Cr: Na: 141, K: 4.5, Cl: 100, HCO_3^- : 21, urea: 5.9, and creatinine: 200. Abdominopelvic USS showed enlarged irregular prostate with nodular changes and lobulated margins highly suggestive of cancer of prostate, bilateral hydronephrosis, and multiple bilateral superficial inguinal lymphadenopathy.

Three units of blood were transfused to optimize the patient with posttransfusion hemogram of 10.6 g/dl. He was commenced on oral antibiotics, haematinics and diuretics. His limbs were also elevated on a pillow.

He had transrectal prostate biopsy and inguinal lymph node biopsy, with histopathology revealing adenocarcinoma of prostate Gleason score 8 [see Figure 1 for tissue photomicrograph].

We counseled him on the options of medical or surgical androgen deprivation therapy (ADT).

He opted for medical ADT, and we commenced monthly subcutaneous Goserelin 3.6 mg. He was discharged to be seen monthly on follow-up and Goserelin injection. For financial reasons, he was irregular with his injections but received a total of four doses in 7 months. His leg and scrotal swelling disappeared, and we lost him to follow-up.

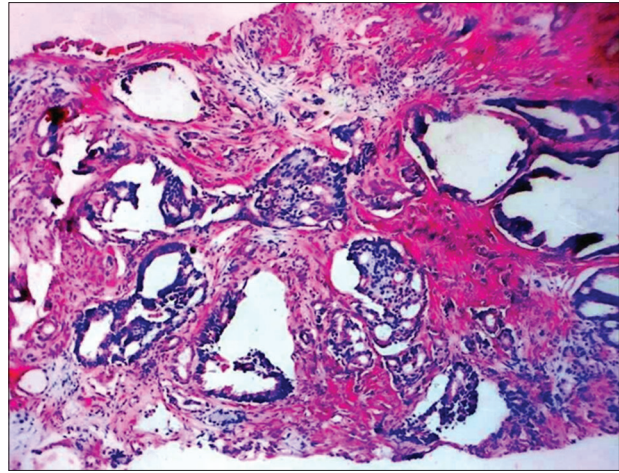


Figure 1: Prostate biopsy tissue photomicrograph

Seven months later (14 months from the first presentation), he presented again with recurrence of scrotal swelling but no leg swelling. We offered the option of orchidectomy which he consented to and had. After a visit 2 weeks later, we lost him yet again to follow-up.

He only presented 24 months later (38 months from the first presentation) with recurrence of penoscrotal swelling and a new onset of nodular cutaneous growths on the lower abdomen on both lumbar regions around the area of subcutaneous Goserelin injection. These nodules were painless and progressively involved the entire lower abdomen below the umbilicus [Figures 2 and 3].

An impression of Kaposi's sarcoma to rule out metastatic skin nodules was made. Skin biopsy showed the lesion to be metastatic adenocarcinoma of prostate [see Figures 4 and 5 for photomicrograph]. PSA done then was 122 ng/ml, and he was commenced on tablet stilbesterol, vasoprin and hematinics. He died about 18 months from the onset of the skin metastasis and 56 months from first presentation and diagnosis of prostate cancer.

DISCUSSION

Prostate cancer incidence has persistently increased, especially with the advent of PSA. However, early reports on data following the advice by the United States Preventive Services Task Force has shown some decline in incidence and diagnosis of early disease.^[7] In Nigeria, where there has never been a screening policy, the advice will likely not influence presentation.

Prostate cancer metastasis has been known to commonly affect the lymphatics, bones, and lungs.^[8] Metastasis to the skin is possible but very rare accounting for about 0.36%.^[1] Skin involvement has been suggested to signify

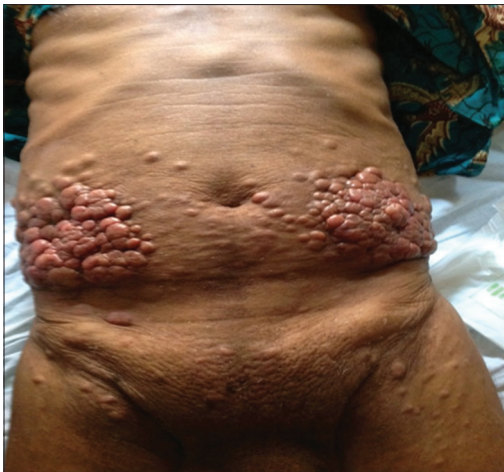

Figure 2: Initial presentation of skin lesion

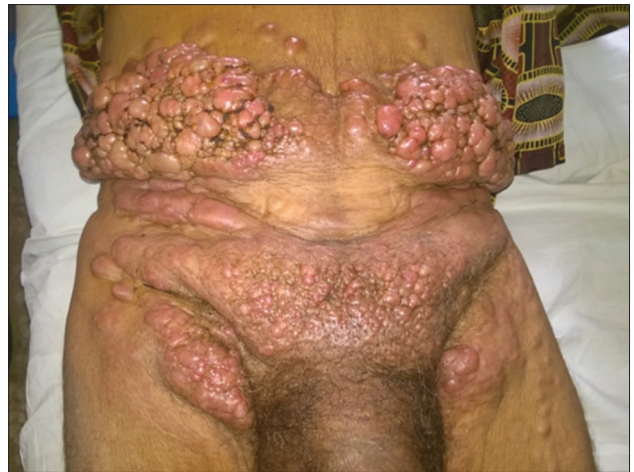

Figure 3: Eleven months after the initial presentation

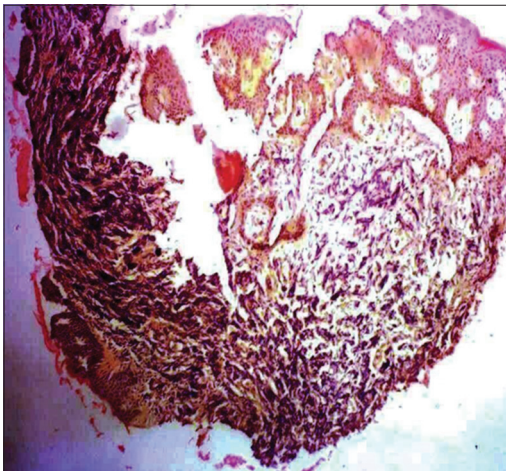


Figure 4: Skin biopsy tissue photomicrograph 1

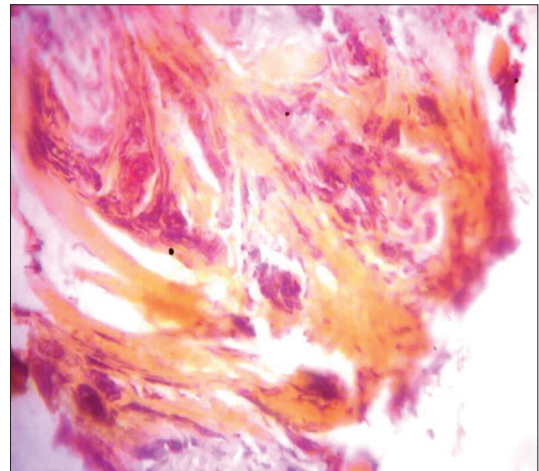


Figure 5: Skin biopsy tissue photomicrograph 2

terminal disease. Involvement of the skin has been thought to be through lymphatic spread by embolization or permeation, hematogenous spread, and implantation during surgery (port site in radical prostatectomy), etc.^[5,6]

The sites of skin involvement can be anywhere from the head, chest, nostril, groin, lower abdomen, port site in radical prostatectomy, and back, but the abdomen and groin area have been found to be the most common site of skin metastasis.^[2-4,6] Our patient presented with abdominal and groin skin lesions. Although it has been reported to often start from the inguinal area and lower abdomen, this pictorial presentation may be too site specific to be a mere coincidence [Figure 2].

The possible risk in this case could include the following: the presence of pedal and scrotal edema in our patient suggests pelvic lymph node involvement at presentation with possible retrograde flow of lymph and prostate cancer cells by embolization or permeation. That being the case, puncture of the skin to subcutaneous level during subcutaneous administration of Zoladex could

bring about implantation to the cutaneous level as has been reported extensively with bladder cancer and the case of port site implantation in radical prostatectomy for prostate cancer.^[6,9]

Although it is worrisome that similar event or reaction did not occur at the skin incision site for orchidectomy, the fact that the tumor burden had been reduced by medical ADT before the procedure was undertaken is a possible explanation.

It is not clear if massive scrotal and penile edema is a risk for skin metastasis or if goserelin injection contributed. Further studies we believe are needed to unravel this.

Declaration of patient consent

The authors certify that they have obtained all appropriate patient consent forms. In the form the patient(s) has/have given his/her/their consent for his/her/their images and other clinical information to be reported in the journal. The patients understand that their

names and initials will not be published and due efforts will be made to conceal their identity, but anonymity cannot be guaranteed.

Acknowledgments

We acknowledge Prof. Igwebuike Onyiora and Dr. Cornelius Ukah the pathologist for their support on the histology and provision of the photomicrogram.

Financial support and sponsorship

Nil.

Conflicts of interest

There are no conflicts of interest.

REFERENCES

- Mueller TJ, Wu H, Greenberg RE, Hudes G, Topham N, Lessin SR, *et al.* Cutaneous metastases from genitourinary malignancies. *Urology* 2004;63:1021-6.
- Reddy S, Bang RH, Contreras ME. Telangiectatic cutaneous metastasis from carcinoma of the prostate. *Br J Dermatol* 2007;156:598-600.
- Sharma R, Chandra M. Cutaneous metastases from carcinoma of the prostate: A case report. *Dermatol Online J* 2005;11:24.
- Rodríguez-Lojo R, Castiñeiras I, Rey-Sanjurjo JL, Fernández-Díaz ML. Distant cutaneous metastases of prostate cancer: A report of 2 cases. *Actas Dermosifiliogr* 2016;107:e52-6.
- Venable DD, Hastings D, Misra RP. Unusual metastatic patterns of prostate adenocarcinoma. *J Urol* 1983;130:980-5.
- Savage SJ, Wingo MS, Hooper HB, Smith MT, Keane TE. Pathologically confirmed port site metastasis after laparoscopic radical prostatectomy: Case report and literature review. *Urology* 2007;70:1222.e9-11.
- Fleshner K, Carlsson SV, Roobol MJ. The effect of the USPSTF PSA screening recommendation on prostate cancer incidence patterns in the USA. *Nat Rev Urol* 2017;14:26-37.
- Bubendorf L, Schöpfer A, Wagner U, Sauter G, Moch H, Willi N, *et al.* Metastatic patterns of prostate cancer: An autopsy study of 1,589 patients. *Hum Pathol* 2000;31:578-83.
- Andersen JR, Steven K. Implantation metastasis after laparoscopic biopsy of bladder cancer. *J Urol* 1995;153:1047-8.