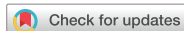

Original Article



A Promising Method for Tumor Localization during Total Laparoscopic Distal Gastrectomy: Preoperative Endoscopic Clipping based on Negative Biopsy and Selective Intraoperative Radiography Findings

Joo Weon Chung ¹, Kyung Won Seo ¹, Kyoungwon Jung ², Moo In Park ², Sung Eun Kim ², Seun Ja Park ², Sang Ho Lee ¹, Yeon Myung Shin ¹

¹Department of Surgery, Kosin University College of Medicine, Busan, Korea

²Division of Gastroenterology, Department of Internal Medicine, Kosin University College of Medicine, Busan, Korea



Received: Apr 19, 2017

Revised: Jun 2, 2017

Accepted: Jul 21, 2017

Correspondence to

Kyung Won Seo

Department of Surgery, Kosin University
College of Medicine, 262 Gamcheon-ro,
Seo-gu, Busan 49267, Korea.

Tel: +82-51-990-6462

Fax: +82-51-246-6093

E-mail: kwseo.surg@kosin.ac.kr

Copyright © 2017. Korean Gastric Cancer Association

This is an Open Access article distributed under the terms of the Creative Commons Attribution Non-Commercial License (<https://creativecommons.org/licenses/by-nc/4.0>) which permits unrestricted noncommercial use, distribution, and reproduction in any medium, provided the original work is properly cited.

ORCID iDs

Joo Weon Chung

<https://orcid.org/0000-0002-2314-5347>

Kyung Won Seo

<https://orcid.org/0000-0002-5771-3832>

Kyoungwon Jung

<https://orcid.org/0000-0002-5324-7803>

ABSTRACT



Purpose: Precise localization of tumors and creation of sufficient proximal resection margins are complicated processes during total laparoscopic distal gastrectomy (TLDG) for clinical T1/T2 gastric cancers. Various solutions to this problem have also yielded many disadvantages. In this study, we reviewed a preoperative endoscopic clipping method based on the results of negative biopsy and selective intraoperative radiography.

Materials and Methods: A retrospective review of 345 consecutive patients who underwent TLDG and preoperative endoscopic clipping for tumor localization was conducted. During preoperative endoscopy, the endoscopists performed negative biopsies just 1–2 cm selectively above the tumor's upper limit. After confirming the biopsy results, endoscopic metal clips were applied just proximal to the negative biopsy site the day before surgery. Selective intraoperative tumor localization using portable abdominal radiography was performed only when we could not ensure a precise resection line.

Results: Negative biopsy was performed in 244 patients. Larger tumor size ($P=0.008$) and more distally located tumors ($P=0.052$) were observed more frequently in the negative biopsy group than in the non-negative biopsy group. The non-negative biopsy group had significantly higher frequencies of differentiated tumor types than the negative biopsy group ($P=0.003$). Of the 244 patients who underwent negative biopsies, 6 had cancer cells in their biopsy specimens. We performed intraoperative radiography in 12 patients whose tumors had difficult-to-determine proximal margins. No tumors were found in the proximal resection margins of any patients.

Conclusions: Our tumor localization method is a promising and accurate method for securing a sufficient resection margin during TLDG.

Keywords: Stomach neoplasms; Laparoscopy; Gastrectomy; Tumor localization; Negative biopsy

Moo In Park <https://orcid.org/0000-0003-2071-6957>Sung Eun Kim <https://orcid.org/0000-0002-1835-4830>Seun Ja Park <https://orcid.org/0000-0003-3217-5115>Sang Ho Lee <https://orcid.org/0000-0002-8863-7625>Yeon Myung Shin <https://orcid.org/0000-0001-9083-3783>

Author Contributions

Conceptualization: S.K.W., P.S.J., P.M.I.; Data curation: C.J.W., S.K.W.; Formal analysis: C.J.W., S.K.W.; Investigation: C.J.W., S.K.W.; Writing - original draft: C.J.W., S.K.W., J.K.; Writing - review & editing: C.J.W., S.K.W., J.K.

Conflict of Interest

No potential conflict of interest relevant to this article was reported.

INTRODUCTION

Total laparoscopic distal gastrectomy (TLDG) is one of the treatments of choice for early gastric cancer (EGC) owing to several advantages, including decreased wound complications and feasibility for obese patients [1]. During this procedure, tumor localization followed by determination of a sufficient resection margin is a critical issue. To date, many surgeons have tried various methods, such as preoperative endoscopic clipping with intraoperative radiography [2], intraoperative endoscopy [3], and computed tomography (CT) gastroscopy [4]. However, these methods may require extraneous efforts because of their increased operation time, need for additional manpower, and possibility of a frozen section during surgery if the gross margin is suspicious. In this study, we reviewed a useful method of preoperative endoscopic negative biopsy and selective intraoperative tumor localization after preoperative endoscopic clipping.

MATERIALS AND METHODS

Patients

Between January 2014 and December 2016, 345 consecutive patients who underwent TLDG for clinical T1/T2 (cT1/T2) gastric cancer and preoperative endoscopic clipping for tumor localization were retrospectively reviewed. We performed laparoscopic gastrectomy for the patients with cT1-2N0M0 tumors. Preoperatively, all patients underwent endoscopy with biopsy and abdominal CT scan, basic blood testing, electrocardiogram, and chest radiography. Among them, 244 patients underwent selective negative biopsies to aid in determining the proximal resection line. This study was approved by the Institutional Review Board of Kosin University Gospel Hospital, and informed consent was obtained from all patients before surgery.

The patients underwent TLDG with intracorporeal anastomosis. Distal gastrectomy was performed on the basis of the tumor location, and D1+ or D2 lymphadenectomy was performed in accordance with the Japanese Gastric Cancer Treatment Guideline (4th English edition) [5]. Intracorporeal Billroth I delta-shaped anastomosis and Billroth II anastomosis using laparoscopic linear staplers were the preferred methods in most cases.

Preoperative localization procedure

All patients who were referred for surgery from the gastroenterology clinic underwent endoscopy with biopsy to confirm the status of the main lesion and to identify undetected lesions during primary endoscopy. At the same time, selected patients underwent negative biopsy to help the surgeons determine the proximal resection line. The patients who did not undergo negative biopsy were grouped into the non-negative biopsy group. Most of these patients had cancers located in the lower third of the stomach and well-differentiated dominant type compared with the patients in the negative biopsy group; therefore, the endoscopists were able to determine the negative proximal margin more easily (Table 1). The endoscopists performed additional biopsies 1–2 cm above the main lesion (Fig. 1A).

The day before surgery, 2 or 4 endoscopic metallic clips (EZ Clip, HX-610-135L; Olympus Medical Co., Tokyo, Japan) were applied just 1–2 cm proximal to the negative biopsy site based on the negative biopsy results (Fig. 1B). Thereafter, 2–3 mL of indocyanine green (ICG) dye (Indocyanine Green Injection; Dongindang Pharmaceutical Co., Siheung, Korea) was injected between the gastric muscle layer and the subserosa using a standard injection needle

Negative Biopsy in Tumor Localization for Total Laparoscopic Distal Gastrectomy

Table 1. Patient demographics

Variables	Neg. Bx (n=244)	Non-neg. Bx (n=101)	
Age (yr)	58.9±11.0	62.3±9.9	0.007
Sex			0.103
Male	137 (56.1)	67 (66.3)	
Female	107 (43.9)	34 (33.7)	
BMI	23.8±3.3	24.3±3.6	0.148
Operation time (min)	136.0±40.3	139.5±40.4	0.470
Tumor size (cm)	2.3±1.1	1.9±1.2	0.008
Proximal margin (cm)	5.5±2.8	6.8±3.2	0.000
Distal margin (cm)	6.2±2.9	5.3±3.3	0.015
Location			0.052
M	104 (42.6)	31 (30.7)	
L	140 (57.4)	70 (69.3)	
Gross type			0.095
EGC-I	3 (1.2)	5 (5.0)	
EGC-IIa	41 (16.8)	25 (24.8)	
EGC-IIb	26 (10.7)	10 (9.9)	
EGC-IIc	146 (59.8)	57 (56.4)	
EGC-III	13 (5.3)	2 (2.0)	
B-I	2 (0.8)	0 (0.0)	
B-II	6 (2.5)	0 (0.0)	
B-III	7 (2.9)	2 (2.0)	
pT			0.144
1	224 (91.7)	96 (95.0)	
2	11 (4.6)	5 (5.0)	
3	9 (3.7)	0 (0.0)	
pN			0.773
0	227 (93.0)	96 (95.0)	
1	11 (4.5)	4 (4.0)	
2	4 (1.6)	1 (1.0)	
3	2 (0.8)	0 (0.0)	
pTNM stage			0.373
Ia	206 (84.4)	92 (91.1)	
Ib	22 (9.0)	8 (7.9)	
IIa	8 (3.3)	0 (0.0)	
IIb	6 (2.5)	1 (1.0)	
IIIa	1 (0.4)	0 (0.0)	
IIIc	1 (0.4)	0 (0.0)	
WHO class			0.003
Papillary	2 (0.8)	0 (0.0)	
WD	41 (16.8)	35 (34.7)	
MD	76 (31.1)	30 (29.7)	
PD	29 (11.9)	13 (12.9)	
SRC	62 (25.4)	17 (16.8)	
Unknown	2 (0.8)	2 (2.0)	
Poorly cohesive type	32 (13.1)	4 (4.0)	
Reconstruction method			0.947
Billroth I	57 (23.4)	22 (21.8)	
Billroth II	178 (73.0)	75 (74.3)	
Roux-en-Y	9 (3.7)	4 (4.0)	

Data are shown as mean±standard deviation or number (%).

Neg. Bx = negative biopsy group; BMI = body mass index; M = middle third of the stomach; L = lower third of the stomach; EGC = early gastric cancer; B = Borrmann type; pT = primary tumor; pN = regional lymph nodes; pTNM = pathological tumor-node-metastasis; WHO = World Health Organization; WD = well-differentiated; MD = moderately differentiated; PD = poorly differentiated; SRC = signet-ring cell.

(Clear-Jet injector, 23 G, 4 mm [0.1 T]-2300; Finemedix Co., Ltd, Daegu, Korea) to improve the precision of identifying the lesion during surgery (**Fig. 1C**). In cases with positive tumor cells at the negative biopsy site, the endoscopist applied the clips more proximally above (>3 cm) the negative biopsy site.

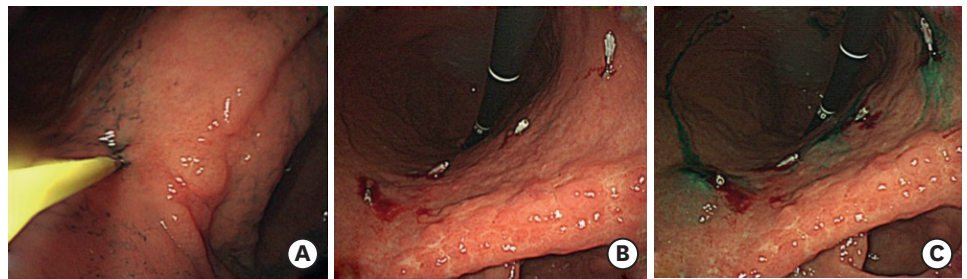


Fig. 1. Preoperative localization procedures. (A) Negative biopsy was performed 1–2 cm above the main lesion to aid in defining the proximal resection line. (B) Several metal clips were applied just proximal to the site of negative biopsy based on negative biopsy results. (C) ICG was injected to help precisely identify the lesion during surgery. ICG = indocyanine green.

Intraoperative localization procedure

After establishing the pneumoperitoneum, we applied a simple liver retraction to expose the hepatogastric ligament properly. Next, we determined the proximal resection line according to the information acquired from preoperative endoscopic clipping and ICG tattooing (**Fig. 2A**). When we could not confirm an exact proximal resection line from the abovementioned information, intraoperative portable abdominal radiographs were obtained to identify the endoscopic clips. In this situation, we applied metallic laparoscopic vessel clips along the greater and lesser curvatures of the external surface of the stomach and drew an artificial line (**Fig. 2B**). After obtaining portable abdominal radiographs, the proximal resection line was determined in accordance with the correlation between the metallic clips and artificial line (**Fig. 3**). When the metallic clips were located below the line connecting the 2 clip points, the stomach was resected at this line. When the clips were located above the line, the stomach was resected 3 cm proximally above the line. After resecting the stomach, we moved the resected specimen out of the body and confirmed the grossly negative margins by opening the specimen and consequently identifying the metallic clips. Frozen sectioning was not performed during the surgery if the gross margin seemed sufficient [5]. The distances from the lesion to the proximal and distal margins were measured during routine pathologic examination of the specimen.

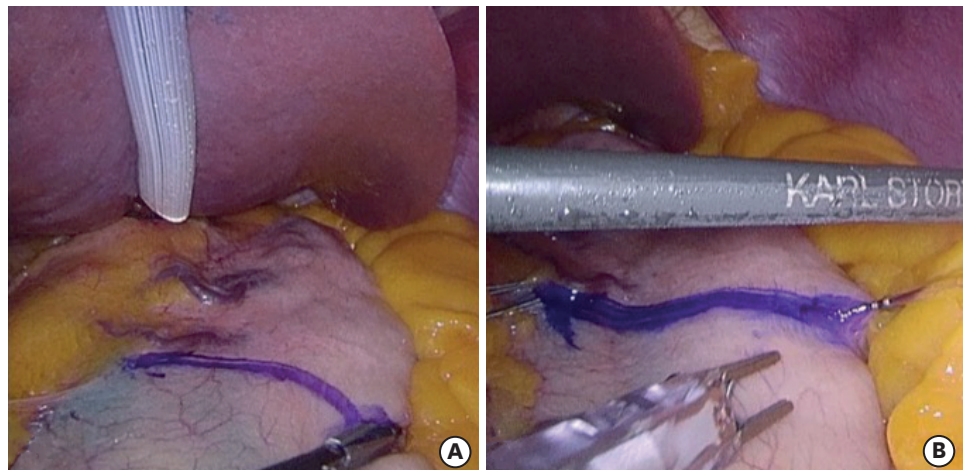


Fig. 2. Intraoperative localization procedures. (A) The proximal resection line according to the information acquired from preoperative endoscopic clipping and ICG tattooing. (B) Metallic laparoscopic vessel clips along the greater and lesser curvatures of the external surface of the stomach followed by drawing an artificial line. ICG = indocyanine green.

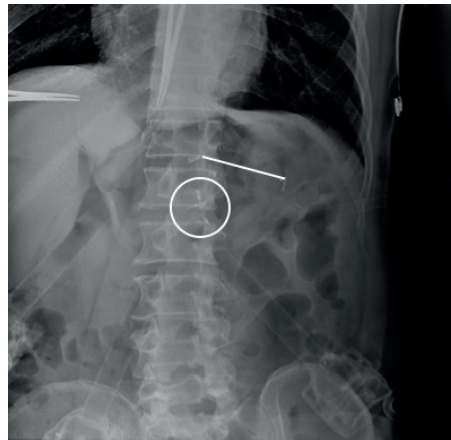


Fig. 3. Radiograph show the location of metallic clips and endoscopic clips.

We used the R version 3.3.2 for all statistical analyses (R Foundation for Statistical Computing, Vienna, Austria; <https://www.R-project.org/>). The χ^2 test for categorical variables and Student's t-test for independent continuous variables were used for comparisons between the 2 treatment groups, and $P < 0.05$ was considered statistically significant.

RESULTS

In all patients who underwent TLGD, the final pathologic results confirmed negative tumor cells at the resection margin. Negative biopsy was performed in 244 patients (Fig. 4).

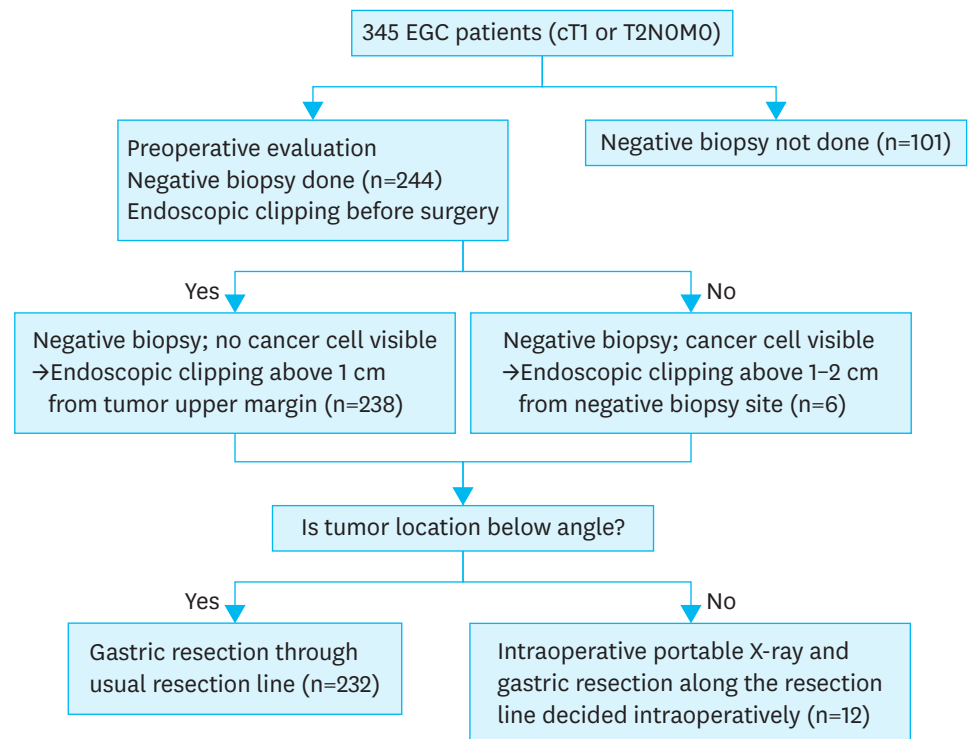


Fig. 4. Study profile with result.
EGC = early gastric cancer; cT1 = clinical T1.

Table 2. Comparison of the clinical features between the non-radiography and radiography subgroups in the negative biopsy group

Variables	Non-radiography (n=232)	Radiography (n=12)	P-value
Location			0.043
M	95 (40.9)	9 (75.0)	
L	137 (59.1)	3 (25.0)	
Tumor size (cm)	2.3±1.2	2.2±0.9	0.963
Proximal margin (cm)	5.5±2.8	4.9±3.1	0.454
Distal margin (cm)	6.1±2.8	8.6±3.8	0.003
Operation time (min)	135.6±40.2	144.2±43.3	0.473

Data are shown as mean±standard deviation or number (%).

M = middle third of the stomach; L = lower third of the stomach.

The patient demographics are summarized in **Table 1**. The 2 groups were not significantly different in the sex ratio (P=0.103), mean body mass index (BMI) (P=0.148), operation time (P=0.470), and gross tumor type (P=0.095). There were also no significant differences in the tumor, node, and metastasis (TNM) staging system (P=0.373) and the reconstruction method (P=0.947). However, tumor size was significantly larger (P=0.008), and the tumors were more distally located (P=0.052) in the negative biopsy group than in the non-negative biopsy group. Additionally, the mean length of the proximal resection margin was significantly shorter (P<0.001), and that of the distal resection margin was longer (P=0.015) in the negative biopsy group than in the non-negative biopsy group. Moreover, the non-negative biopsy group had significantly more differentiated tumor types than the negative biopsy group (P=0.003).

Of the 244 patients who underwent negative biopsies, 6 had cancer cells in their biopsy specimens. In all cases in which we performed preoperative marking without re-biopsy, clipping was performed at or 1–2 cm from the proximal margin of the negative biopsy site. To secure the negative resection margin, intraoperative frozen biopsy of the proximal margin was performed before anastomosis. Additionally, 6 cases were proximal margin-negative in the final biopsy.

Twelve of the negative biopsy patients had resection margins that were difficult to determine; thus, we performed intraoperative radiography. The comparison between the non-radiography and radiography subgroups is described in **Table 2**. There were no significant differences in tumor size (P=0.963), length of the proximal margin (P=0.454), and operation time (P=0.473) between the 2 subgroups. However, the non-radiography subgroup had more distally located tumors (P=0.043) and shorter length of the distal margin (P=0.003) than the radiography subgroup. The proximal margins of the patients were negative for lesions in the final biopsy.

DISCUSSION

In this study, we retrospectively evaluated a novel method to secure negative proximal margins safely and reduce extraneous surgical procedures, including frozen biopsy, intraoperative endoscopy, and CT gastroscopy. Our method aids in determining the proximal resection margin based on the results of negative biopsies obtained proximal to the lesion by carefully examining the lesion boundary during preoperative endoscopy and using selective intraoperative radiographs.

Since laparoscopically assisted distal gastrectomy has become the treatment of choice for EGC, many surgeons tried intracorporeal anastomosis instead of extracorporeal anastomosis because the benefits of the former included superior postoperative recovery, less pain, and shorter hospital stay [6]. However, because of the inability to confirm tumor location by

touching the serosal surface, a wide variety of methods were developed to secure the proximal margin for TLDG. These supplementary procedures included preoperative gastroscopy with dye injection [3], autologous blood tattooing [7], laparoscopic ultrasonography [8], intraoperative radiography [2], and even endoscopic clipping with CT gastroscopy [4]; however, they also had several disadvantages. Intraoperative endoscopy, ultrasonography, or endoscopic clipping with CT gastroscopy is costly and requires skilled labor during surgeries. Endoscopic dye injection spreads and eventually disappears over time after injection.

Herein, we performed clipping with dye injection on the day before surgery, and we did not perform intraoperative endoscopy. By doing so, it was easier to determine the exact resection line for most of the lower-third tumors. For the middle-third tumors, we avoided wasting time and effort by performing intraoperative radiography in cases where it was difficult to define the resection margin. This procedure can be performed confidently because of the introduction of an endoscopic clipping method based on the negative biopsy results. This allows surgeons to extract and open the specimen. Afterward, we were able to define an appropriate negative margin while minimizing the use of frozen sections during surgery.

Intraoperative tumor localization using portable abdominal radiography saves time and money, is accurate, and is applicable in any hospital setting compared with that using the methods listed above. However, one disadvantage of this method is that the surgeon determines the resection line, not based on the tumor itself, but on the endoscopic clips that are placed by the endoscopist. Thus, we emphasize that there is a need to be critical when determining the appropriate resection line to plan surgeries for patients whose preoperative tumor biopsies reveal histologic types of undifferentiated adenocarcinoma [2].

According to a retrospective study of 1,549 EGC cases after endoscopic resection, lateral margin positivity was significantly related to large lesions, undifferentiated histology types, and submucosal invasion [9]. In another study of endoscopic resection for undifferentiated EGC, lateral margin positivity was significantly higher in diffuse poorly differentiated adenocarcinomas and signet-ring cell carcinomas [10]. Therefore, it is not easy to determine the margin accurately on endoscopic examination in EGC cases with an undifferentiated histology, and clipping without negative biopsy may result in cancer development in the resection margin despite surgical treatment. This requires the surgeon to perform a negative biopsy when planning a surgery for a patient whose histologic type of undifferentiated adenocarcinoma was identified via preoperative tumor biopsy and to ensure that an appropriate resection line is selected carefully.

In this study, 6 of the 244 patients who underwent negative biopsy had malignant tumor cells. These tumors were undifferentiated, and when we retrospectively reviewed their endoscopy results, we confirmed that their margins were particularly difficult to define. Therefore, our method offers a valuable solution to previous disadvantages. Nevertheless, undifferentiated tumors are characterized by difficulty in defining the border; thus, caution is required when setting a resection line.

This study has some limitations. First, this study was an observational study; there were 101 patients who did not undergo negative biopsy. However, the tumors of these 101 patients were located more distally, involving a large proportion of differentiated tumor types. Thus, it can be assumed that the endoscopists would not have performed negative biopsies. Second, the number of patients who underwent intraoperative radiography was 12, which is relatively small, although the number of the middle-third tumors was 128. The reason is that it was

relatively easy to detect the clip on the serosal side during surgery because our endoscopist performed ICG tattooing simultaneously during preoperative endoscopic clipping. Furthermore, the proximal resection line in distal gastrectomy at our institution is based on a two-thirds resection whenever possible, regardless of the tumor location. Therefore, the need for an intraoperative radiograph for tumor localization was less than expected.

In conclusion, a preoperative endoscopic clipping method based on negative biopsy and selective intraoperative radiography findings for tumor localization is a promising and accurate method for securing a sufficient resection margin in TLDG for cT1/cT2 gastric cancer.

ACKNOWLEDGMENTS

The authors thank registered nurses Aeri Yang and Goeun Kim for their support in the data summarization of this study.

REFERENCES

1. Kim MG, Kim KC, Kim BS, Kim TH, Kim HS, Yook JH, et al. A totally laparoscopic distal gastrectomy can be an effective way of performing laparoscopic gastrectomy in obese patients (body mass index \geq 30). *World J Surg* 2011;35:1327-1332.
[PUBMED](#) | [CROSSREF](#)
2. Kim HI, Hyung WJ, Lee CR, Lim JS, An JY, Cheong JH, et al. Intraoperative portable abdominal radiograph for tumor localization: a simple and accurate method for laparoscopic gastrectomy. *Surg Endosc* 2011;25:958-963.
[PUBMED](#) | [CROSSREF](#)
3. Xuan Y, Hur H, Byun CS, Han SU, Cho YK. Efficacy of intraoperative gastroscopy for tumor localization in totally laparoscopic distal gastrectomy for cancer in the middle third of the stomach. *Surg Endosc* 2013;27:4364-4370.
[PUBMED](#) | [CROSSREF](#)
4. Jeong SH, Bae K, Ha CY, Lee YJ, Lee OJ, Jung WT, et al. Effectiveness of endoscopic clipping and computed tomography gastroscopy for the preoperative localization of gastric cancer. *J Korean Surg Soc* 2013;84:80-87.
[PUBMED](#) | [CROSSREF](#)
5. Japanese Gastric Cancer Association. Japanese gastric cancer treatment guidelines 2014 (ver. 4). *Gastric Cancer* 2017;20:1-19.
[CROSSREF](#)
6. Nishimura S, Oki E, Tsutsumi S, Tsuda Y, Sugiyama M, Nakashima Y, et al. Clinical significance of totally laparoscopic distal gastrectomy: a comparison of short-term outcomes relative to open and laparoscopic-assisted distal gastrectomy. *Surg Laparosc Endosc Percutan Tech* 2016;26:372-376.
[PUBMED](#) | [CROSSREF](#)
7. Jeong O, Cho SB, Joo YE, Ryu SY, Park YK. Novel technique for intraoperative tumor localization during totally laparoscopic distal gastrectomy: endoscopic autologous blood tattooing. *Surg Endosc* 2012;26:1778-1783.
[PUBMED](#) | [CROSSREF](#)
8. Hyung WJ, Lim JS, Cheong JH, Kim J, Choi SH, Song SY, et al. Intraoperative tumor localization using laparoscopic ultrasonography in laparoscopic-assisted gastrectomy. *Surg Endosc* 2005;19:1353-1357.
[PUBMED](#) | [CROSSREF](#)
9. Kakushima N, Ono H, Tanaka M, Takizawa K, Yamaguchi Y, Matsubayashi H. Factors related to lateral margin positivity for cancer in gastric specimens of endoscopic submucosal dissection. *Dig Endosc* 2011;23:227-232.
[PUBMED](#) | [CROSSREF](#)
10. Kim YH, Kim JH, Kim H, Kim H, Lee YC, Lee SK, et al. Is the recent WHO histological classification for gastric cancer helpful for application to endoscopic resection? *Gastric Cancer* 2016;19:869-875.
[PUBMED](#) | [CROSSREF](#)