

COVID-19 and risk of pulmonary fibrosis: the importance of planning ahead

Francesco Gentile¹, Alberto Aimò^{1,2}, Francesco Forfori³, Giosuè Catapano¹, Alberto Clemente¹, Filippo Cademartiri⁴, Michele Emdin^{1,2} and Alberto Giannoni^{1,2}

European Journal of Preventive Cardiology
2020, Vol. 27(13) 1442–1446
© The European Society of Cardiology 2020
Article reuse guidelines:
sagepub.com/journals-permissions
DOI: 10.1177/2047487320932695
journals.sagepub.com/home/cpr



Interstitial pneumonia represents the most common cause of hospitalization for coronavirus disease 2019 (COVID-19) and may be complicated by acute distress respiratory syndrome, refractory respiratory failure and death. On the other hand, whether survivors of COVID-19 pneumonia may be at risk of chronic sequelae is unknown. From observational studies, it is known that some SARS-CoV-1 survivors have developed fibrotic pulmonary remodelling, restrictive lung abnormalities, associated with impaired exercise tolerance and poor quality of life at follow-up. Based on the numerous similarities between SARS-CoV-2 and SARS-CoV-1 infections, we hypothesize that lung fibrosis may be also a possible long-term consequence of COVID-19 pneumonia. Assessing the long-term consequences of COVID-19 thus appears crucial. We therefore stress on the importance of: (a) setting up specific follow-up strategies in COVID-19 patients showing pulmonary involvement to assess the possible progression toward lung fibrosis; (b) treating patients at risk from the early phases with therapies preventing the development of future lung fibrosis.

As of 2 May 2020, over three million people worldwide have been diagnosed with COVID-19, with almost 230,000 deaths. Interstitial pneumonia is one of the most common features of COVID-19 and can be complicated by acute respiratory distress syndrome (ARDS), a condition associated with high mortality, especially in elderly with multiple comorbidities.¹ However, the degree of lung involvement may be highly variable among different patients, ranging from mildly symptomatic to rapidly lethal diseases (Figure 1). Nevertheless, the majority of patients with COVID-19 pneumonia survive the acute phase and it is currently unknown whether they could be at risk of developing long-term consequences on lung function.

Between November 2002 and August 2003, the SARS-CoV-1 outbreak resulted in over 8000 cases

and 900 deaths. SARS-CoV-1 infection mainly caused an atypical interstitial pneumonia, named SARS, frequently complicated by ARDS (in about one-third of patients).^{2,3} Some patients survived to the acute phase and were then followed up by a few studies, which have assessed the long-term pulmonary consequence of SARS. The most informative of these studies enrolled 97 survivors from SARS. At one-year follow-up, abnormalities on chest radiography were observed in 28% of patients, while pulmonary function testing (PFT) showed decreased forced vital capacity (FVC), total lung capacity (TLC) and diffusing capacity for carbon monoxide (DL_{CO}) <80% of predicted in 4%, 5% and 24% of patients, respectively. Notably, the extent of radiographical abnormalities correlated with the severity of functional impairment. Moreover, FVC and DL_{CO} were the only independent predictors of six-minute-walking-test performance, which was significantly lower in SARS survivors compared with age-matched healthy controls. Similarly, SARS survivors had worse overall quality of life, with patients admitted to intensive care units (32%) showing a greater impairment of PFT than those treated in medical wards.³ Among 55 patients with two-year follow-up data, FVC, TLC and DL_{CO} were decreased in 16%, 11% and 53% of patients, respectively, suggesting a persistent impairment of lung function.⁴ More recently, lung diffusion abnormalities were observed in about

¹Fondazione Toscana G. Monasterio, Pisa, Italy

²Institute of Life Sciences, Scuola Superiore Sant'Anna, Pisa, Italy

³Intensive Care Unit, Azienda Ospedaliero Universitaria Pisana, Pisa, Italy

⁴Cardiovascular Imaging Centre SDN IRCCS, Naples, Italy

Corresponding author:

Alberto Giannoni, Scuola Superiore Sant'Anna and Fondazione Toscana G. Monasterio, CNR-Regione Toscana, via Giuseppe Moruzzi 1, 56124, Pisa, Italy.

Email: alberto.giannoni@gmail.com

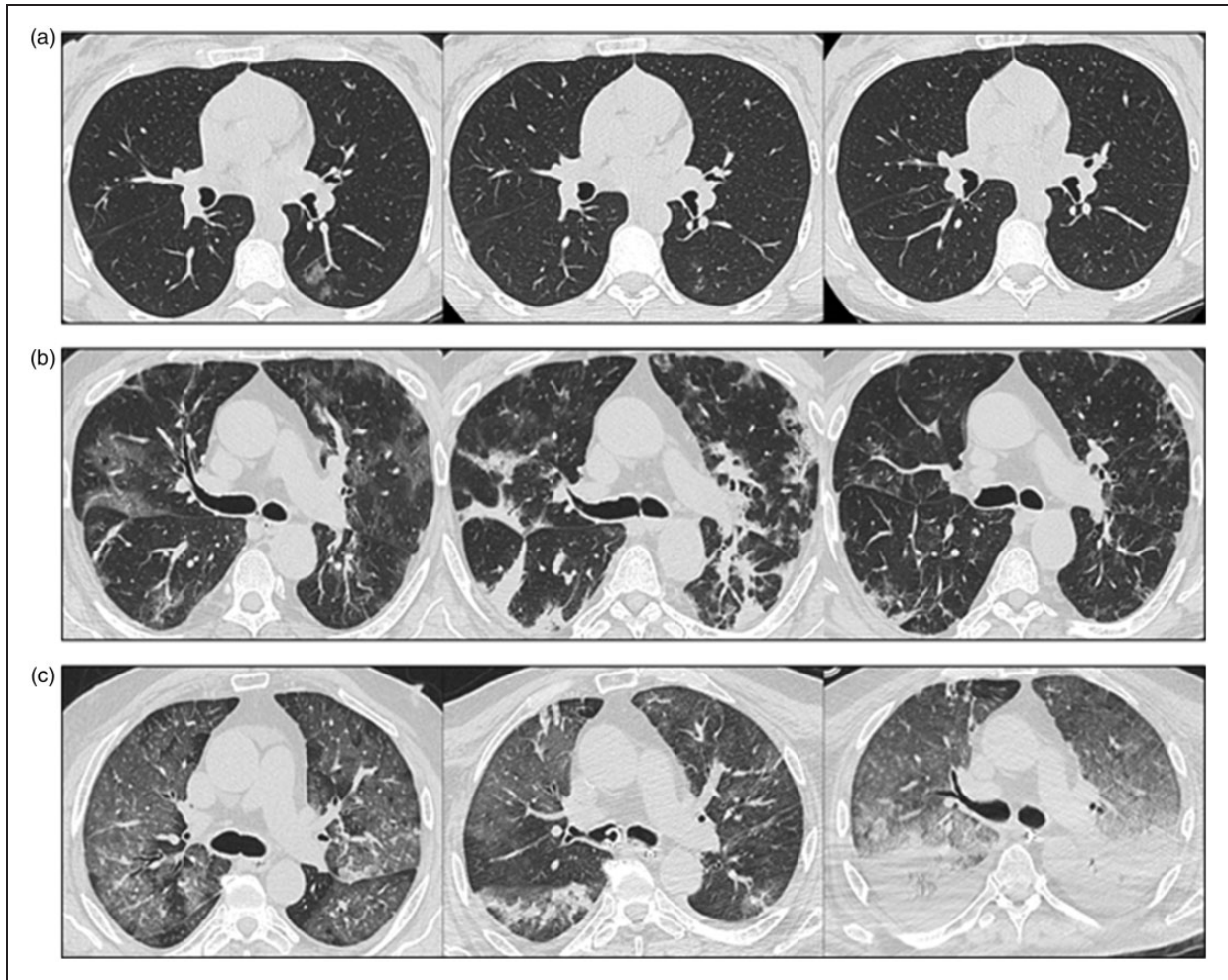


Figure 1. Serial high-resolution computed tomography (HRCT) images of three patients with a confirmed infection by SARS-CoV-2, showing different possible evolutions of lung involvement.

(a) Mild COVID-19 lung involvement in a 39-year-old woman, scarcely symptomatic and home-treated with hydroxychloroquine. HRCT at day 1 showed a small subpleural mono-lateral ground-glass opacity (GGO) at the superior segment of the left inferior lobe (1), which was significantly reduced at day 7 (2), and almost completely resolved after two weeks (3). (b) Severe COVID-19 pneumonia in a 67-year-old man, hospitalized and treated with tocilizumab and ventilatory support with favourable evolution. HRCT at day 1 showed multiple patchy bilateral subpleural and peripheral areas of GGO associated with limited interlobular septal thickening (1). At day 5, there was a significant progression of the disease with air-space consolidations (2). After three weeks, HRCT showed significant reduction of the extension and severity of the consolidations with residual GGO and peribronchovascular thickening (3). (c) Severe COVID-19 pneumonia in a 74-year-old man, hospitalized with poor outcome. HRCT at day 1 showed bilateral extensive GGO with diffuse distribution associated with reticulations in a 'crazy-paving pattern', particularly at the lower lobes (1). At day 9, there was a reduction of the GGO with progressive evolution in peripheral consolidations (2). Finally, HRCT at day 18 showed diffuse bilateral GGO and marked increase of the consolidative posterior distribution in a full-blown acute distress respiratory syndrome (3).

one-third of patients in a 15-year follow-up study on 71 SARS survivors.⁵ Long-term sequelae of SARS at computed tomography (CT) (e.g. air trapping, 'ground-glass' opacities, reticulations and traction bronchiectasis) were found in over one-half of a population of 40 patients during a follow-up lasting up to six months.⁶ Although the number of pulmonary segments involved was lower at the end of an 84-month follow-up, intralobular and interlobular septal thickening

overcame ground-glass opacities as predominant lesions, suggesting ongoing lung remodelling.⁷

Findings from both CT and PFT are similar to disorders characterized by pulmonary fibrosis, where thickened alveolar membranes and interstitial remodelling usually affect gas diffusion and decrease lung compliance. Accordingly, while biopsy samples showed lung oedema, desquamation of pneumocytes and formation of hyaline membranes during the early stages of

SARS, fibrin deposition and infiltration of inflammatory cells and fibroblasts were found some weeks later, possibly as early signs of lung fibrosis.²

During the acute phase of COVID-19 pneumonia, lung injury mainly derives from the inflammatory response to viral infection with possible bacterial superinfection. Endothelial dysfunction and microvascular damage by local thromboembolic events are other possible determinants of lung damage.¹ A histopathological progression similar to SARS has already been observed in COVID-19 pneumonia, with intra-alveolar and interstitial fibrin deposition and chronic inflammatory infiltrates, already a few weeks after the initial diagnosis.⁸ Although the possible mechanisms involved in long-term remodelling are uncertain, a wound repair response with predominance of pro-fibrotic pathways may be implicated, while mechanical stress associated with invasive ventilation may also contribute.⁹

Notably, coronavirus infection could directly promote lung fibrosis by at least two mechanisms. The nucleocapsid protein of SARS-CoV-1 is known to directly enhance transforming growth factor-beta (TGF- β) signalling, which is a powerful pro-fibrotic stimulus.¹⁰ Whether SARS-CoV-2 may share such a feature is unknown, albeit its nucleocapsid protein is over 90% similar to that of SARS-CoV-1.¹¹ Coronaviruses seem also to induce a downregulation of angiotensin-converting-enzyme-2, reducing angiotensin II (Ang II)

clearance in the lungs. Ang II could then upregulate TGF- β and connective tissue growth factor.¹²

The numerous similarities between COVID-19 and SARS make us imagine a comparable risk of progression toward lung fibrosis. Given the magnitude of the COVID-19 pandemic, it seems urgent to investigate whether survivors may be truly at risk of developing chronic pulmonary sequelae. Furthermore, as patients with established cardiovascular disease seem more at risk of COVID-19, the possible worsening of functional capacity in these patients should not be overlooked once recovered from the acute illness.¹³ Moreover, the consequence of lung remodelling may be more pronounced in patients with prior heart dysfunction, while symptoms like dyspnoea and fatigue may characterize both conditions. The set-up of dedicated outpatient ambulatories to follow-up COVID-19 survivors could then be helpful and a multidisciplinary approach, involving both pneumologists and cardiologists, may be valuable. On the other hand, the use of serial PFT and/or imaging tests in the early phase post-discharge, as well as in the mid and long term, may outline the actual pulmonary outcomes of COVID-19 survivors. Moreover, should the risk of long-term lung fibrosis be confirmed, the identification of risk factors and early markers of lung fibrosis would become crucial, favouring the implementation of preventive strategies in the subset at higher risk (Figure 2).

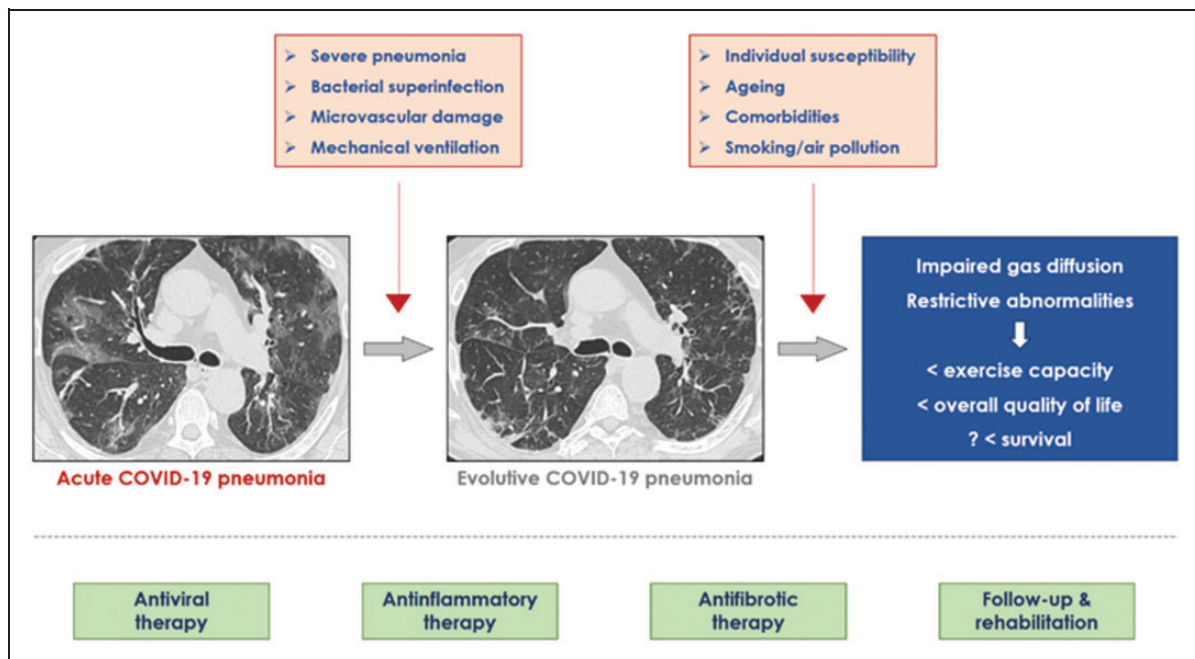


Figure 2. Possible progression of COVID-19 pneumonia to lung fibrosis, and preventive strategies.

The high-resolution computed tomography (HRCT) images in the first two panels show a case of severe COVID-19 pneumonia recovered after three weeks in a 67-year-old man. Although clinically stable and near to discharge, the persistent residual interstitial involvement at HRCT (second panel) could be an early sign of long-term fibrosis.

In this regard, three complementary strategies to reduce the likelihood of development of lung fibrosis may be proposed: (a) a more intense and prolonged inhibition of viral replication; (b) a long-standing inhibition of the inflammatory response; (c) the administration of anti-fibrotic drugs. To date, it is unknown whether an early and/or prolonged administration of antiviral agents may prevent lung remodelling, or whether some antiviral agents are of greater value than others. Although the use of anti-inflammatory drugs in the acute phase of COVID-19 is still debated, a prolonged administration of low-dose corticosteroids may prevent maladaptive lung remodelling in survivors of ARDS. Nevertheless, the benefit–risk ratio of these drugs should be carefully evaluated, especially in patients with previous comorbidities such as diabetes mellitus, hypertension and chronic heart failure.¹⁴ On the other hand, since Ang II may be a key player also in the development of lung fibrosis, the use of either angiotensin-converting-enzyme inhibitors or angiotensin-receptor blockers may protect patients from chronic consequences, although this point is still to be clarified.¹⁵ Other drugs, such as pirfenidone and nintedanib, currently approved for the treatment of idiopathic pulmonary fibrosis, deserve a special mention. Indeed, beyond their anti-fibrotic actions, they seem to have also anti-inflammatory effects, and thus their use is intriguing even in the acute phase of COVID-19 pneumonia.¹⁶ A multicentre, randomized, open clinical trial (ClinicalTrials.gov identifier: NCT04282902) is currently testing the effects of a four-week course of pirfenidone on CT findings and gas exchanges in patients with COVID-19. Nonetheless, further trials with longer follow-up durations are mandatory to clarify the efficacy of anti-fibrotic drugs in this setting.

Over the next months, the number of patients infected by SARS-CoV-2 surviving the acute phase with clinical and CT evidence of pulmonary involvement is expected to grow exponentially. Beyond the indisputable relevance of approaches targeting the acute phase, the long-term sequelae on lung function should not be overlooked. Indeed, some patients may be at risk of developing long-standing fibrotic remodelling, which may affect quality of life and survival. Therefore, clarifying the mid- and long-term consequences of COVID-19 pneumonia and defining the potential preventive and follow-up strategies may prove valuable in the future, but only if we think ahead to the next stage of the war against this insidious and treacherous virus.

Declaration of conflicting interests

The author(s) declared no potential conflicts of interest with respect to the research, authorship, and/or publication of this article.

Funding

The author(s) received no financial support for the research, authorship, and/or publication of this article.

References

- Phua J, Wang L, Ling L, et al. Intensive care management of coronavirus disease 2019 (COVID-19): Challenges and recommendations. *Lancet Respir Med*. Epub ahead of print 6 April 2020. DOI:10.1016/S2213-2600(20)30161-2.
- Cheung OY, Chan JWM, Ng CK, et al. The spectrum of pathological changes in severe acute respiratory syndrome (SARS). *Histopathology* 2004; 45: 119–124.
- Hui DS, Wong KT, Ko FW, et al. The 1-year impact of severe acute respiratory syndrome on pulmonary function, exercise capacity, and quality of life in a cohort of survivors. *Chest* 2005; 128: 2247–2261.
- Ngai JC, Ko FW, Ng SS, et al. The long-term impact of severe acute respiratory syndrome on pulmonary function, exercise capacity and health status. *Respirology* 2010; 15: 543–550.
- Zhang P, Li J, Liu H, et al. Long-term bone and lung consequences associated with hospital-acquired severe acute respiratory syndrome: A 15-year follow-up from a prospective cohort study. *Bone Res* 2020; 8: 8.
- Chang YC, Yu CJ, Chang SC, et al. Pulmonary sequelae in convalescent patients after severe acute respiratory syndrome: evaluation with thin-section CT. *Radiology* 2005; 236: 1067–1075.
- Wu X, Dong D and Ma D. Thin-section computed tomography manifestations during convalescence and long-term follow-up of patients with severe acute respiratory syndrome (SARS). *Med Sci. Monit* 2016; 22: 2793–2799.
- Zhang H, Zhou P, Wei Y, et al. Histothologic changes and SARS-CoV-2 immunostaining in the lung of a patient with COVID-19. *Ann Intern Med*. Epub ahead of print 12 March 2020. DOI:10.7326/M20-0533.
- Cabrera-Benitez NE, Laffey JG, Parotto M, et al. Mechanical ventilation-associated lung fibrosis in acute respiratory distress syndrome: A significant contributor to poor outcome. *Anesthesiology* 2014; 121: 189–198.
- Zhao X, Nicholls JM, Chen YG, et al. Severe acute respiratory syndrome-associated coronavirus nucleocapsid protein interacts with Smad3 and modulates transforming growth factor-beta signaling. *J Biol Chem* 2008; 283: 3272–3280.
- Tilocca B, Soggiu A, Sanguinetti M, et al. Comparative computational analysis of SARS-CoV-2 nucleocapsid protein epitopes in taxonomically related coronaviruses. *Microb Infect*. Epub ahead of print 14 April 2020. DOI:10.1016/j.micinf.2020.04.002.
- Zuo W, Zhao X and Chen YG. SARS coronavirus and lung fibrosis. In: Lal S (ed.) *Molecular biology of the SARS-coronavirus*. Berlin and Heidelberg: Springer, 2010, pp.247–258.

13. Barison A, Aimo A, Castiglione V, et al. Cardiovascular disease and COVID-19: les liaisons dangereuses. *Eur J Prev Cardiol* 2020; 27: 1017–1025.
14. Villar J, Confalonieri M, Pastores S, et al. Rationale for prolonged corticosteroid treatment in the acute respiratory distress syndrome caused by coronavirus disease 2019. *Crit Care Explor* 2020; 2: e0111.
15. Brojakowska A, Narula J, Shimony R, et al. Clinical implications of SARS-Cov2 interaction with renin angiotensin system. *J Am Coll Cardiol*. Epub ahead of print 15 April 2020. DOI: 10.1016/j.jacc.2020.04.028.
16. Collins BF and Raghu G. Antifibrotic therapy for fibrotic lung disease beyond idiopathic pulmonary fibrosis. *Eur Respir Rev* 2019; 28: 190022.