



Review Article

# Completion thyroidectomy: is timing important for transcervical and remote access approaches?

Juan Pablo Dueñas <sup>a,\*</sup>, Carlos Simón Duque <sup>b</sup>,  
Laura Cristancho <sup>c</sup>, Manuela Méndez <sup>d</sup>

<sup>a</sup> Hospital Pablo Tobón Uribe, Instituto de Cancerología IDC Las Américas, Clínica Universitaria Bolivariana, Clínica el Rosario Sede el Tesoro (CLID), Medellín, Colombia

<sup>b</sup> Universidad Militar Nueva Granada, Bogotá, DC, Colombia

<sup>c</sup> Universidad CES, Medellín, Colombia

<sup>d</sup> Hospital Pablo Tobón Uribe, Clínica Las Américas, Medellín, Colombia

Received 4 February 2020; accepted 27 February 2020

Available online 30 June 2020

## KEYWORDS

Completion thyroidectomy;  
Total thyroidectomy;  
Complications;  
Nerve monitoring

**Abstract** Completion thyroidectomy (CT) is employed after lobectomy when histopathological results mandates total removal of the gland as in case of well differentiated thyroid carcinoma (DTC). It is also employed as a second stage thyroid surgery when unfavorable events occur as in recurrent laryngeal nerve injury or when the surgeon finds out the case is beyond his/her expertise in an attempt to protect the contralateral side and allowing time for recovery or for an expert surgeon to help.

Copyright © 2020 Chinese Medical Association. Production and hosting by Elsevier B.V. on behalf of KeAi Communications Co., Ltd. This is an open access article under the CC BY-NC-ND license (<http://creativecommons.org/licenses/by-nc-nd/4.0/>).

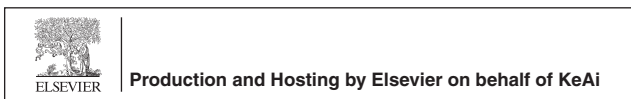## Introduction

Improvements in the diagnostic tools for thyroid diseases have contributed to change in surgical approach to different thyroid diseases. For instance, the newer ultrasound machines can detect thyroid nodules as small as 2 mm and further other characteristics such as echogenicity, margins, vascularity, microcalcifications, number of nodules and location, etc. Moreover, with utilization of Bethesda classification of fine needle aspiration cytology

\* Corresponding author.

E-mail address: [jpduenas@ciendocrina.com](mailto:jpduenas@ciendocrina.com) (J.P. Dueñas).

Peer review under responsibility of Chinese Medical Association.



(FNAC) as well as molecular testing and tumor markers, healthcare teams as well as patients are able to make an informed decision more than ever.<sup>1–3</sup>

Additionally, surgical technology has improved the conduction of thyroid procedures making them safer and faster without compromising patient's safety. It provides better surgical instruments to enhance dissection and tissue resection and at the same time sealing of vessels up to 5–7 ml reducing blood loss as well as ligation time. Nerve monitoring has allowed us to learn more about the physiology of the Recurrent Laryngeal Nerve (RLN) and to distinguish if a nerve is functional throughout thyroid surgery.

Remote-access thyroid surgery is employed to bypass the neck scar resulting from traditional thyroid surgery with transoral endoscopic thyroidectomy via the vestibular approach (TOETVA) being the most recent and the only scarless surgery.<sup>4–8</sup>

Most importantly, improvement in biological data collection and analysis (Bioinformatics) throughout the past years has provided the chance to revise and change management. Guidelines has been described and published around the world, including the American Thyroid Association (ATA), European Thyroid Association (ETA), and many others.

For instance, currently patients with a one to 4-cm thyroid nodule, positive for Papillary Thyroid Carcinoma (PTC) without any other suspicious lesion in the contralateral side or an abnormal pathology finding, are offered a hemithyroidectomy as a single and curative modality of treatment. Consequently, reducing the complication rates associated with total thyroidectomy as opposed to hemithyroidectomy as well as the need for exogenous thyroid replacement therapy or radioactive iodine treatment (RAI).<sup>9–11</sup>

As such, these new information and advances have surely allowed us today to offer the patient who is scheduled for a total thyroidectomy a safer and more reliable procedure, permitting surgeons to change a treatment plan intraoperatively in the event of an unexpected finding during the procedure that may alter the patient's wellbeing and reschedule the intervention to remove the entire thyroid gland once it is safe.

The term "Completion Thyroidectomy" fits clearly this description, of patients who need a second intervention due to their tumor findings or any other condition that was not taken into account when the patient had the initial thyroid surgery.<sup>12,13</sup>

The following article will discuss and explain the term "completion thyroidectomy" as a safe measure to complete in a later date the removal of the remaining thyroid gland tissue.

## Revision of present thyroid surgical procedures

Even though the objective of this article is to discuss completion thyroidectomy, it is important to describe the main surgical operations in thyroid surgery.

1. Lobectomy with or without the removal of the isthmus: which can eventually be combined with an ipsilateral paratracheal dissection. It is utilized to remove benign

lesion as well as malignant tumors with specific characteristics.

2. Total thyroidectomy: removing the entire thyroid gland which usually is chosen as a treatment modality for thyroid cancer, multinodular goiter, Grave's disease and even Hashimoto's thyroiditis. As known, has the most feared rate of complication of unilateral or bilateral recurrent nerve injury and hypoparathyroidism.
3. Near Total Thyroidectomy: removing all thyroid leaving a small amount of tissue in order to preserve at least one normal parathyroid gland and the recurrent laryngeal nerve, to avoid permanent hypoparathyroidism or vocal cord paralysis. It is mainly used on big multinodular goiter, Graves' disease and in some specific well differentiated thyroid cancer. The small amount of tissue left might not need a completion thyroidectomy in cases that well differentiated thyroid cancer is diagnosed, and might even allow for the administration of radioactive iodine.<sup>12</sup>
4. Subtotal thyroidectomy: leaves a bigger amount of thyroid tissue in some difficult multinodular goiters and Grave's disease. Completion thyroidectomy might be needed if WDTC is described, especially if RAI is considered.<sup>12</sup>

## Possible scenarios for a completion thyroidectomy

### Patient No 1

Regardless of all recent changes, increased knowledge, advances in technology, and pathology, etc. completion thyroidectomy has always been part of the options to treat patients with thyroid diseases.

The classical example in the past was the patient with a 2–3 cm thyroid nodule with a benign fine needle biopsy and progressive growth who underwent an uneventful hemithyroidectomy. Later however, the frozen was informed as goiter, but on a final and complete revision papillary carcinoma measuring 2 cm without any other description is informed by pathology. In the current context of offering a partial thyroidectomy for the management of a differentiated thyroid carcinoma between one and four centimeters, the final result of the pathology may evidence high risk factors of recurrence such as extra thyroid extension, aggressive variants, lymphovascular or neural invasion, positive margins or presence of multiple nodal micro-metastases or macrometastases; which make the patient a candidate for radioactive iodine treatment after a completion thyroidectomy.

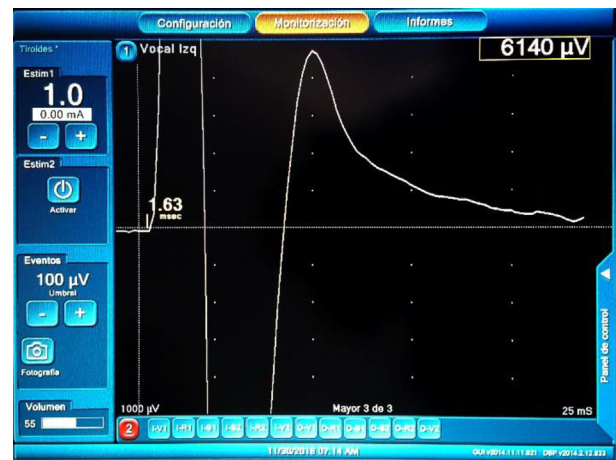
### Patient No 2

A 27-year-old male with a 2 cm × 1.2 cm, middle third aspect of his left thyroid lobe diagnosed with papillary carcinomas, was scheduled to have a total thyroidectomy with Neuromonitorization Nim 3 (Medtronic 3-0 Jacksonville, FL: USA). Once the left thyroid lobe was exposed, the

sternothyroid muscle was sacrificed in an en block procedure, as it appeared to be slightly infiltrated by the lesion. After the superior lobe was released and a normal Vagal (V1) nerve response was obtained, the inferior pedicle was approached, at this moment dark cystic lymphadenopathies measuring up to 5 mm were observed. One of these lymph-nodes was sent for frozen section analysis and was informed as consistent with metastatic papillary cancer. The left recurrent laryngeal nerve was found to be surrounded but not infiltrated by this metastatic node. As a first pre dissection maneuver, the nerve was stimulated with the provided probe its amplitude showed a surprising R1 6.140 microvolt ( $\mu\text{V}$ ) amplitude and a 1.63 ms latency. Next, the nerve was dissected upwards with careful, gentle and subtle manipulation to free it from the adenopathy, to find shortly that even though, there was not a true infiltration of the nerve by the tumor, it sure came in close contact with it. At this point new neurostimulation showed similar R1 results and the nerve was released from the tumor with the most delicate manipulation without damaging it. Later however, the amplitude dropped to the 3000  $\mu\text{V}$  and the latency started to increase as well. Even though the nerve was "completely intact" its amplitude continues dropping to 973  $\mu\text{V}$  and the latency increased to 1.88 ms without recovering after allowing a 25 minutes rest period. At this point, decision to end the procedure was made and the family was informed. A flexible exam of the larynx confirmed a left true vocal cord paralysis, the pathology reported a 2 cm classic papillary carcinoma with positive extra thyroidal extension and 3 out of 6 paratracheal nodes with metastatic disease. Two months later, once the left vocal cord was fully recovered the patient underwent a completion thyroidectomy, removing his right thyroid lobe and was given radioactive iodine (Figs. 1 and 2).

## Discussion

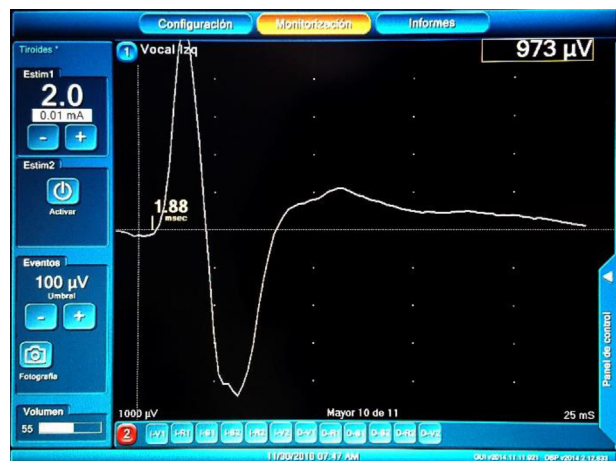
With no doubt, total thyroidectomy continues to be the treatment of choice for many benign or malignant thyroid conditions such a multinodular goiter, Grave's disease, thyroid cancer or the presence of high risk factors for recurrence in the final pathology. Furthermore, complication rate is lower when performed by a high-volume surgeon. Nevertheless, complications such as hematomas, recurrent laryngeal nerve injury, hypoparathyroidism can and still occur. In 2015 the American Thyroid Association (ATA) proposed lobectomy as an option for "low risk" patients with WDTC measuring between 1 and 4 cm. The low risk assessment however should be closely looked at by careful evaluation of imaging and pathological findings as well as family history of thyroid cancer. Though most of these patients are scheduled for a hemithyroidectomy, almost one third of them might eventually require a completion thyroidectomy. For example, during a scheduled lobectomy the surgeon finds gross invasion to the strap muscles, trachea, recurrent laryngeal nerve, etc. In which case the original plan discussed with the patient will need to be changed to a total thyroidectomy with mediastinal dissection. Even though, there is no a pre-determined time to perform a completion thyroidectomy, one can argue that



**Fig. 1** Patient with a 2 cm left thyroid papillary cancer left laryngeal recurrent nerve pre-dissection stimulation results. Nim 3 (Medtronic Nim 3. Jacksonville, FL. USA).

this unexpected finding will urge the surgeon to call the procedure immediately if patients conditions – nerve integrity and functionality are present.

For many years ago, patients were submitted to an eventful hemithyroidectomy, for what appeared to be a benign 2 cm thyroid nodule with visual identification of the recurrent laryngeal nerve with normal post-operative voice. Once the surgeon analyzed the pathology report, informing that not only the operated thyroid lobe harbored a 1.7 cm malignant lesion, but also it described gross extra thyroidal and extracapsular extension, lymphovascular invasion plus a high risk papillary thyroid cancer variety. After meeting with the patient and discussing such findings the need for a "completion thyroidectomy" should be considered in order to allow not only radioactive iodine treatment



**Fig. 2** Same patient's left laryngeal recurrent nerve post-dissection stimulation results, after the nerve was manipulated from the compromised lymphadenopathies in the left paratracheal groove and released from its close contact with the tumor. A dramatic reduction on the amplitude is observed as well as an increase in the latency. Nim 3 (Medtronic Nim 3. Jacksonville, FL. USA).

but also to favor follow up (Thyroglobulin, antithyroglobulin antibodies, ultrasound).

However, if the pathology report shows a 1.7 malignant – classical papillary carcinoma with no other worrisome features like the ones described before, probably this patient nowadays will not have to go back to surgery as his pathology will be revised without reporting any disturbance, a new ultrasound will not show contralateral disease and the patient will undergo periodic surveillance without needing radioactive iodine. With no doubt this description fits the first patient scenario.<sup>10,13–15</sup>

Most of the cases on which a surgeon can perform a CT applies basically to large multinodular goiters, Graves' disease, Hashimoto's thyroiditis and malignant conditions such as WDTC.

With respect to Medullary Thyroid Carcinoma (MTC), the term and or expression completion thyroidectomy (CT) may apply to those patients who undergo a hemithyroidectomy for a benign nodule or even a WDTC and the pathology finds a MTC which not only needs a completion thyroidectomy but also a mediastinal dissection. For advanced MTC with high volume tumors and neck metastasis, the urgent need to remove the disease, certainly in our opinion may not warrant a delayed second procedure in case of an unexpected event during surgery such as injury to the recurrent laryngeal nerve while performing the first side lobectomy in need to remove the entire gland in conjunction with mediastinal and bilateral neck metastasis due to high tumor volume. In this case, if the intervention is done under intra operative neuro-monitorization, delaying the procedure after observing a decrease of signal or even a complete loss of signal in the first recurrent laryngeal nerve, may (of course this should be consider by the acting surgeon at the moment analyzing all available information to come to a final decision) not be considered as it is clear that the patient will definitively need complementary treatment (Radiotherapy) to try to ensure control of the disease.<sup>16</sup>

It is not the purpose of this discussion to describe the technical aspects of thyroid gland surgery under nerve monitoring. Regardless, this relatively new technology allows the surgeon to confirm the integrity of the nerve and most importantly its function. That is, when is properly stimulated that nerve will render a satisfactory response not only for the recurrent nerve (R2) but also from the Vagus nerve (V2) showing no changes in the original numbers or a slight change allowing the surgeon to safely approach to the contralateral side. In the event that the other nerve is injured regardless of the reason,

the patient will not need a tracheostomy since one nerve at least is functional. On the other hand, if there are severe and drastic changes in the amplitude or latency or no signal at all when the surgeon stimulates the recurrent laryngeal nerve in the absence of a disturbing factor such as muscle relaxation given by anesthesia malfunction of the equipment by any means (loose or detached cables, lack of energy, etc.) and a positive signal in the contralateral vagus nerve as it has been described, a loss of signal is determined. Though not common, this situation may happen as described in our case. If such event happened during the removal of the affected side (the author's approach always first the lobe with the malignant lesion and in case of a Goiter, the side with the larger lobe) is wise to analyze the findings and determine the course of the procedure case based on the available information. Like patient No 2, most recurrent laryngeal nerves that were not severely injured and were treated gentle will recover within a three-month period allowing the surgeon to perform a completion thyroidectomy if indicated. In our personal experience (not published) this possible scenario of a loss of signal is discussed with the patient prior to surgery and with his/her family at the time this occurs during the intervention, we must affirm that all patients definitively were glad that the procedure was ended and rescheduled once the nerve is functional.<sup>5,17,18</sup>

Another advantage of this approach is even though a total thyroidectomy was scheduled and only a hemithyroidectomy was performed due to the loss of signal, the final pathology report might show that there is no urgent need or even might not need to complete the surgery as the tumor findings were less than what it was seen originally and a hemithyroidectomy was enough.

Despite some authors refer that by doing a CT, the surgeon might end up with a higher rate of complications due to the inflammation and fibrotic tissue present at the moment of the reintervention. Regardless, if the plan is to remove the contralateral side using the same scar incision the surgeon will definitively encounter at the beginning of the procedure some amount of fibroid and scar tissue, through the midline, but a great option to follow as we usually do in these cases, is a lateral approach, retracting the sternocleidomastoid muscle (ECM) and if needed a gentle retraction of the common carotid artery and internal jugular vein externally with and upward retraction of the strap muscles. If they are surrounded by scar tissue one option is to divide them until the thyroid lobe is visualized, and the end of the procedure they should be sutured back

**Table 1** Comparison of the complication rate between completion thyroidectomy vs. total thyroidectomy.

Author, year	Type of study	Number of patients	Results
Li et al, 2015	Meta-analysis	1208	No significant differences in: Temporary or permanent paralysis of the NLR, temporary or permanent hypocalcemia, haematoma or operative site infection.
Gulcelik et al, 2018	Prospective	287	Increased temporal hypocalcemia, unilateral temporal paralysis of the NLR and operative site infection in completion thyroidectomy

together. Once the surgeon finds a clear and clean thyroid bed the procedure can be finished.<sup>13,19,20</sup>

## Literature review

The meta-analysis of Li et al,<sup>19</sup> which included seven studies with a total of 1208 patients compared the rate of complications between completion thyroidectomy vs. total thyroidectomy, without finding significant differences in the presence of temporary or permanent recurrent laryngeal nerve paralysis, temporary or permanent hypokalemia, hematoma or operative site infection, and this result may be attributed to careful identification of the recurrent nerves and parathyroid glands.

Gulcelik et al<sup>21</sup> In a prospective study included 287 patients with completion thyroidectomy and 407 with total thyroidectomies. The rates of complications were compared resulting in significant differences in the rates of temporal hypocalcemia, unilateral temporary paralysis of the recurrent laryngeal nerve and infection of the operative site. However, no significant differences in permanent complications were detected. They concluded that completion thyroidectomy is just as safe as total thyroidectomy, showing no permanent complications, but completion thyroidectomies were performed as soon as the decision for reoperation was made, and there was not a specific timing for reoperations.

There is no consensus on the exact timing of completion thyroidectomy, this topic remains controversial. In a retrospective study Kisaoglu et al,<sup>15</sup> included 66 patients who required completion thyroidectomy as a treatment for differentiated thyroid cancer. The results were evaluated according to the interval of time between the first and the second surgery. The first group included patients who had surgery 10–90 days after the initial surgery, the other group, included all those patients who had surgery after 90 days; there were not significant differences between the two groups regarding postoperative complications.

Another retrospective study by Salem et al,<sup>22</sup> included 118 patients who were taken to completion thyroidectomy for differentiated thyroid cancer, who were divided into 3

groups according to the timing from the first surgery; one week to 3 months, 3 months–6 months and after 6 months from the initial surgery. The overall rates of transient and persistent postoperative hypocalcemia was 19.5% and 4.2%, respectively. The rates of persistent hypocalcemia was found in groups A and B but not in group C. Regarding transitory or persistent lesions of the recurrent laryngeal nerves, a significant increase was found in groups A and B, ranging from 3.1% to 9.3% and from 3.3% to 6.7% respectively ( $P < 0.005$ ) with respect to group C. The rates of persistent hypocalcemia were found in groups A and B, but not in group C. There were no significant differences in survival between the 3 groups; however, recurrence was higher in group A.

Bin et al,<sup>13</sup> conducted a systematic review and a meta-analysis of early completion thyroidectomy (from 7 to 90 days) vs. late (after 90 days), finding that late performance was associated with lower rates of postoperative complications, including transient hypocalcemia, persistent hypocalcemia, transient and permanent paralysis of the recurrent laryngeal nerve and transient hypoparathyroidism.

Recently, Sawant et al<sup>23</sup> Publish a study of consecutive patients with DTC identified from prospective records of South-East Scotland from 2009 to 2015. Of 361 patients diagnosed with DTC, 161 (45%) had CT. In total 22 patients (14%) suffered complications. Four patients (3%) developed postoperative hematoma. Two (1%) had an identified permanent nerve palsy on the completion side. 13 patients (8%) remained on calcium supplementation for more than 6 months postoperatively and three patients (2%) developed wound complications, demonstrating a high CT rate (45%) in patients operated for thyroid cancer with a significant complication rate.

To the date there is still not consensus regarding to the reasonable time to perform a safe completion thyroidectomy. In our opinion, the optimal time to complete the thyroidectomy could be three months, but this issue should be discussed with the patient and determined once all facts have been considered such as tumor volume, the necessity to administer radioactive iodine based on the pathology report, the surgeon findings during surgery, as well as the

**Table 2** Interval of time in the realization of the completion thyroidectomy and complications.

Author, year	Type of study	Number of patients	Time interval for completion thyroidectomy	Conclusión
Kisaoglu et al, 2014	Retrospective	66	Group 1: 10 to 90 days. Group 2: more than 90 days.	No significant differences in complications.
Salem et al, 2017	Retrospective	118	Group A: one week to 3 months. Group B: 3–6 months. Grupo C: more than 6 months.	Persistent hypoparathyroidism in groups A and B but not in group C. Higher transitory or persistent lesions of NLR in Groups A and B.
Bin et al, 2018	Systematic review and meta-analysis	957	Group 1: 7–90 days. Grupo 2: more than 90 days	Group 2 has lower rates of hypocalcemia, hypoparathyroidism and transient and permanent paralysis of the NLR.

status of the recurrent laryngeal nerve postoperatively and the time of the recovery from a previous loss of signal.<sup>2,10,11,13,17,18,21,24</sup>

In regards to remote access completion thyroidectomy, in particular Trans Oral Endoscopic Thyroid Vestibular Approach (TOETVA), there are only two published cases in the literature, to remove the entire thyroid after Hürthle cell carcinoma and a follicular carcinoma were found on a scheduled, uneventful lobectomy.<sup>25,26</sup>

Table 1 and Table 2 summarize the most important findings of the studies mentioned.

## Conclusion

A completion thyroidectomy is today an option that allow the surgeon to remove the remaining thyroid tissue later in order to ensure that entire gland is removed. In benign conditions there might be no rush for completion thyroidectomy. Nonetheless, for those with DTC in whom the administration of radioactive iodine is indicated, the timing of the procedure surely should be taken into account. Important factors to be considered are related to the functionality of the nerve, type of and extent of tumor or the presence of high risk factors for recurrence in the final pathology. The optimal time to complete the thyroidectomy could be three months in order to reduce complications.

## Consent

Consent was obtained from the patient in order to use the images of the Nim 3 Monitor (Medtronic Jacksonville, FL, USA) recorded during his intervention.

## Declaration of Competing Interest

JD Dueñas and CS Duque give nerve monitoring courses in head and neck surgery for surgeons in Latin-America, with the sponsorship of Medtronic. However, this article was not funded by this or any other company.

## References

1. Detweiler K, Eifenbein DM, Mayers D. Evaluation of thyroid nodules. *Surg Clin North Am.* 2019;99:571–586.
2. Cibas ES, Ali SZ. The 2017 Bethesda system for reporting thyroid cytopathology. *Thyroid.* 2017;27:1341–1346.
3. Seethala RR, Baloch ZW, Bartletta JA, et al. Noninvasive follicular thyroid neoplasm with papillary-like nuclear features: a review for pathologists. *Mod Pathol.* 2018;31:39–55.
4. Dionigi G, Wu CW, Kim HY, et al. Safety of energy based devices for hemostasis in thyroid surgery. *Gland Surg.* 2016;5:490–494.
5. Randolph GW, Dralle H, Abdullah H, et al. Electrophysiologic recurrent laryngeal nerve monitoring during thyroid and parathyroid surgery: international standards guideline statement. *Laryngoscope.* 2011;121(Suppl 1):S1–S16.
6. Anuwong A. Transoral endoscopic thyroidectomy vestibular approach: a series of the first 60 human cases. *World J Surg.* 2016;40:491–497.
7. Anuwong A, Sasanakietkul T, Jitpratoom P, et al. Transoral endoscopic thyroidectomy vestibular approach (TOETVA): indications, techniques and results. *Surg Endosc.* 2018;32:456–465.
8. Jongekkasit I, Jitpratoom P, Sasanakietkul T, Anuwong A. Transoral endoscopic thyroidectomy for thyroid cancer. *Endocrinol Metab Clin North Am.* 2019;48:165–180.
9. Vargas-Pinto S, Romero AMA. Lobectomy compared to total thyroidectomy for low-risk papillary thyroid cancer: a systematic review. *J Surg Res.* 2019;242:244–251.
10. Ullmann TM, Gray KD, Stefanova D, et al. The 2015 American thyroid association guidelines are associated with an increasing rate of hemithyroidectomy for thyroid cancer. *Surgery.* 2019;166:349–355.
11. Luster M, Aktolun C, Amendoeira I, et al. European perspective on 2015 American thyroid association management guidelines for adult patients with thyroid nodules and differentiated thyroid cancer: proceedings of an interactive international symposium. *Thyroid.* 2019;29:7–26.
12. Erbil Y, Barbaros U, Salmastioğlu A, Yanik BT, Bozboru A, Ozarmağan S. The advantage of near-total thyroidectomy to avoid postoperative hypoparathyroidism in benign multinodular goiter. *Langenbecks Arch Surg.* 2006;391:567–573.
13. Bin SR, Bin SM, Bin SN. Impact of completion thyroidectomy timing on post-operative complications: a systematic review and meta-analysis. *Gland Surg.* 2018;7:458–465.
14. Kim ES, Kim TY, Koh JM, et al. Completion thyroidectomy in patients with thyroid cancer who initially underwent unilateral operation. *Clin Endocrinol (Oxf).* 2004;61:145–148.
15. Kisaoglu A, Özoğul B, Akçay MN, et al. Completion thyroidectomy in differentiated thyroid cancer: when to perform. *Ulus Cerrahi Derg.* 2014;30:18–21.
16. Raffel A, Cupisti K, Krausch M, Wolf A, Schulte KM, Röher HD. Incidentally found medullary thyroid cancer: treatment rationale for small tumors. *World J Surg.* 2004;28:397–401.
17. Sitges-Serra A, Fontané J, Dueñas JP, et al. Prospective study on loss of signal on the first side during neuromonitoring of the recurrent laryngeal nerve in total thyroidectomy. *Br J Surg.* 2013;100:662–666.
18. Schneider R, Randolph GW, Dionigi G, et al. International neural monitoring study group guideline 2018 part I: staging bilateral thyroid surgery with monitoring loss of signal. *Laryngoscope.* 2018;128(Suppl 3):1S1–1S17.
19. Li YJ, Wang YZ, Yi ZB, Chen LL, Zhou XD. Comparison of completion thyroidectomy and primary total surgery for differentiated thyroid cancer: a meta-analysis. *Oncol Res Treat.* 2015;38:528–531.
20. Pironi D, Pontone S, Vendettuoli M, et al. Prevention of complications during reoperative thyroid surgery. *Clin Ter.* 2014;165:e285–e290.
21. Gulcelik MA, Dogan L, Akgul GG, Güven EH, Ersöz GN. Completion thyroidectomy: safer than thought. *Oncol Res Treat.* 2018;41:386–390.
22. Salem MA, Ahmed BM, Elshoieby MH. Optimum timing and complication of completion thyroidectomy for differentiated thyroid cancer. *J Cancer Ther.* 2017;8:518–526.
23. Sawant R, Hulse K, Sohrabi S, et al. The impact of completion thyroidectomy. *Eur J Surg Oncol.* 2019;45:1171–1174.
24. Glockzin G, Hornung M, Kienle K, et al. Completion thyroidectomy: effect of timing on clinical complications and oncologic outcome in patients with differentiated thyroid cancer. *World J Surg.* 2012;36:1168–1173.
25. Razavi CR, Tufano RP, Russell JO. Completion thyroidectomy via the transoral endoscopic vestibular approach. *Gland Surg.* 2018;7:77577–77579.
26. Park JO, Anuwong A, Kim MR, Sun DI, Kim MS. Transoral endoscopic thyroid surgery in a Korean population. *Surg Endosc.* 2019;33:2104–2113.