

Combined Viscodilation of Schlemm's Canal and Collector Channels and 360° Ab-Interno Trabeculotomy for Congenital Glaucoma Associated with Sturge–Weber Syndrome

This article was published in the following Dove Press journal:
International Medical Case Reports Journal

Lucia Porsia
Manlio Nicoletti

Maggiore Hospital, Bologna 40133, Italy

Purpose: This case report demonstrates the potential role of the OMNI surgical system in the surgical management of congenital glaucoma.

Patients and Methods: The case was a 4-month-old full-term, otherwise healthy female infant with cutaneous hemangiomas of both upper lids, corneal edema in the right eye (RE) and IOP > 30 mmHg. Sturge–Weber syndrome (SWS) was diagnosed. The RE was surgically treated with ab-interno circumferential viscodilation and trabeculotomy.

Results: Through 10 months of follow-up, intraocular pressure was adequately controlled without the need for adjunctive medical therapy.

Conclusion: Given its advantages over other angle surgery techniques, this procedure's role in treating glaucomas of childhood warrants further evaluation.

Keywords: Sturge–Weber, congenital glaucoma, OMNI surgical system, viscodilation, canal surgery, pediatric glaucoma

Introduction

Glaucoma in infants and children often requires surgical intervention for intraocular pressure (IOP) reduction and disease control. Angle-based procedures such as goniotomy and trabeculotomy are the most commonly performed procedures in children's eyes, with other more invasive procedures reserved for nonresponsive cases, thus avoiding in most affected children their attendant risks. In recent years, an array of minimally invasive glaucoma surgeries (MIGS) have been developed as safer, albeit often less effective, alternatives to trabeculectomy in adult eyes. Many of these MIGS procedures are angle-based procedures and reports are emerging of their clinical utility in managing childhood glaucoma. Reported herein is the case of an infant with Sturge–Weber Syndrome (SWS) and unilateral secondary open-angle glaucoma who underwent combined viscodilation of Schlemm's Canal (SC) and collector channels (CC) and 360° ab interno trabeculotomy. Through 10 months of follow-up, intraocular pressure was adequately controlled without the need for adjunctive medical therapy. Given its advantages over other angle surgery techniques, this procedure's role in treating glaucomas of childhood warrants further evaluation.

Correspondence: Lucia Porsia
Tel +39 3470638829
Email lucia.porsia@ausl.bologna.it

Written consent for publication of the photographs and case details included in this case report was obtained from the child's parents. Institutional approval was not required for this publication.

Case Description

A 4-month-old female was referred by her pediatrician for frequent tearing, photophobia, blepharospasm, and rubbing of the right eye (RE). She was a full-term, otherwise healthy infant. Her father was Italian and her mother Moroccan; her father was under observation as a unilateral glaucoma suspect. Examination in the office revealed cutaneous hemangiomas of both upper lids (more prominent RE, [Figure 1](#)), corneal edema in the RE and IOP > 30 mmHg in both eyes by rebound tonometry. Sturge-Weber syndrome (SWS) was diagnosed. Timolol and brinzolamide were prescribed both eyes. Ocular ultrasonography revealed no choroidal thickening, and neuroimaging was negative for intracranial involvement. At examination under anesthesia (EUA) 2 weeks later, IOP RE was 17 mmHg by Perkins tonometry, and IOP left eye (LE) was 9 mmHg. Horizontal corneal diameters (HCD) were 12.5 mm RE and 11.0 mm LE. Axial length (AL) was 21.33 mm RE and 19.29 mm LE by contact biometry. The RE manifested corneal edema and Haab striae; the left cornea was clear. Gonioscopy in both eyes revealed indistinct structural demarcation with high iris insertion and prominent iris processes.

The diagnosis of secondary open-angle glaucoma associated with SWS was made in the RE; the LE appeared free of glaucoma and the elevated IOP in the LE on initial presentation was presumed to be an artifact of in-office measurement. Two weeks later, at 5 months of age, the child underwent viscodilation of SC and CC and ab interno 360° trabeculotomy RE using the OMNI glaucoma treatment system (Sight Sciences, Inc., Menlo Park, CA). A temporal incision was created in the peripheral cornea. The pupil was constricted with an injection of acetylcholine chloride 20mg/2mL (Miovisin, Bausch & Lomb, Bridgewater, NJ)

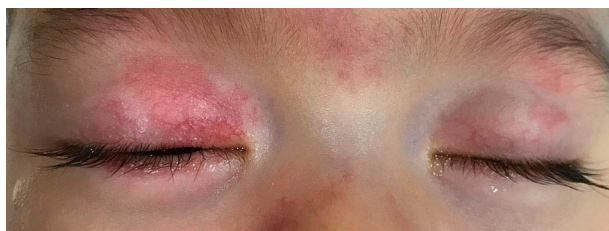

Figure 1 Flat hemangioma of the right upper eyelid.

through this incision. The device's handpiece was introduced into the anterior chamber (AC) (filled with sodium hyaluronate 1.4% [Healon GV, Johnson & Johnson, New Brunswick, NJ]) through the same incision and directed to the nasal angle. The handpiece features a sharp-tipped cannula within which lies an extensible microcatheter. The cannula tip pierced the trabecular meshwork (TM), and the microcatheter was advanced around 180° of SC (its blue color [[Figure 2](#)] permitted visualization through TM), then retracted as a fixed volume of sodium hyaluronate 1.4% (Healon GV) was dispensed to dilate the canal in a controlled fashion to perform the viscodilation procedure. The procedure was repeated through the same TM entry point along the second 180° of SC. The microcatheter was then reinserted sequentially into each 180° of SC and withdrawn in such a way that the entire circumference of the TM was unroofed via a cheese-wiring technique similar to that of suture trabeculotomy.¹ The sodium hyaluronate was then partially removed from the AC and the corneal incision was closed with vicryl sutures to prevent flattening of the AC due to high postero-anterior push typical of vitreous in the infant eye. A small hyphema—an expected part of the procedure and common to most angle-based surgeries—resolved without treatment. Postoperatively, all IOP-lowering medications were discontinued in both eyes. The child's mother reported reduction of corneal edema and photophobia RE.

At follow-up EUA 2 months later (age 7 months), unmedicated IOP by Perkins tonometry were 15 and 11 mmHg in RE and LE, respectively. HCD and AL increased appropriately for age-related eye growth; HCD increased 1 mm bilaterally, while AL was increased in the RE less than in the LE, being 21.93 and 19.98 mm, respectively. Corneal edema RE had resolved leaving only Haab striae. At follow-up EUA 5 months later (age 12 months), unmedicated IOP by Perkins tonometry were 8 and 9 mmHg in RE and LE, respectively.

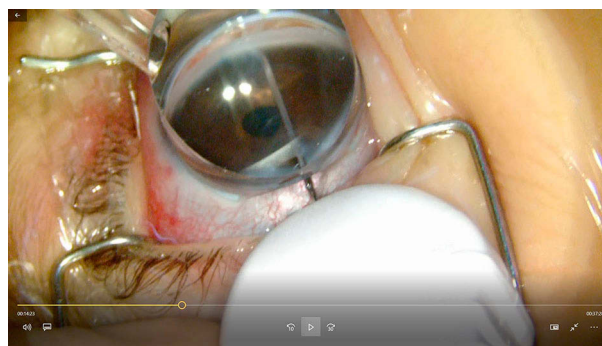


Figure 2 Blue color of OMNI microcatheter is visible behind the trabecular meshwork.

HCDs were unchanged, and ALs were 22.08 mm RE and 20.56 mm LE; the increase in AL LE is indicative of age-related ocular growth, while the RE increased less, an indicator of successful surgery.^{2,3} At last follow-up 10 months after surgery, IOP by rebound tonometry was 18 RE and 17 LE on no medications.

Conclusions

Sturge–Weber Syndrome has several ocular manifestations, including ocular surface and retinal/choroidal vascular anomalies as well as glaucoma.⁴ The glaucoma may manifest in infancy, as in the present case, or later in life. Manifestation in infancy is thought to be due to outflow obstruction similar to primary congenital glaucoma and is generally treated with an angle-based procedure like goniotomy. Later onset is thought to be related in part to elevated episcleral venous pressure arising from vascular malformations that impede outflow.⁴ These glaucomas respond less well to medical therapy than other forms of congenital glaucoma.^{5,6} Bleb-based surgeries are associated with high rates of complications that include expulsive choroidal hemorrhage, bleeding, and prolonged hypotony.⁶

The advent of MIGS has rekindled interest in angle-based surgery in adults with glaucoma.⁷ MIGS procedures are typically minimally traumatic to ocular tissues, have a favorable safety profile, and offer rapid recovery,⁸ all of which are desirable in both adult and pediatric eyes with glaucoma. While MIGS have been developed primarily for adult patients, the similarities between some MIGS procedures and traditional pediatric glaucoma procedures has led some surgeons to utilize MIGS procedures in children with glaucoma.⁹ Significant for this case of SWS is that many MIGS procedures lower IOP without the formation of a bleb, offering the potential for greater safety compared to bleb-based procedures.

This case demonstrates the potential role of the OMNI system in the surgical management of congenital glaucoma. This approach has several advantages over more traditional glaucoma surgical procedures. Goniotomy cuts TM for only 120° in a single session and requires sufficient gonioscopic and surgical skills in congenital glaucoma to recognize the right site for a lengthy circumlinear incision and the right depth of incision without damaging the outer wall of SC, while ab interno trabeculotomy using the OMNI microcatheter can extend the TM opening for 360° and obviates the need for a lengthy freehand incision and judgement regarding incision site and depth and thus

may be easier for surgeons who do not frequently perform glaucoma surgery on children.

Compared to GATT,¹⁰ the combined OMNI technique may be easier for many surgeons to perform: following correct positioning of the device tip, the instrument's semirigid microcatheter typically feeds easily into and through SC. The blue-colored microcatheter can be visualized throughout its passage preventing misdirection. Viscodilation of the CC system, particularly in older children, addresses any post-trabecular outflow obstruction¹¹ further enhancing aqueous egress through the previously underutilized trabecular outflow system and subsequent IOP reduction.

Also, since most children with glaucoma have normal life expectancies and may need several operations to control IOP, in contrast to ab externo trabeculotomy, the ab interno approach spares the conjunctiva and sclera for future surgery if needed. Other case reports of ab interno MIGS procedures include implantation of the gel stent implant in 4 children ranging in age from 4 months to 14 years for congenital glaucoma or steroid-induced ocular hypertension,^{12,13} as well as several reports of excisional^{14,15} and incisional¹⁶ goniotomy in children.

In conclusion, combined viscodilation of SC and CC and 360° ab interno trabeculotomy for congenital glaucoma can produce low IOP without the need for medications. Further investigation is warranted to clarify the potential role of this safe and effective procedure in this and other forms of childhood glaucoma.

Acknowledgments

Sight Sciences, Inc. provided funding for medical writing and publication costs. Medical writing services were provided by Tony Realini, MD, MPH, Hypotony Holdings, LLC, who created the draft manuscript.

Disclosure

The authors declare that there is no conflict of interest.

References

1. Giangiacomo A, Beck A. Pediatric glaucoma: review of recent literature. *Curr Opin Ophthalmol*. 2017;28(2):199–203. doi:10.1097/ICU.0000000000000349
2. Law SK, Bui D, Caprioli J. Serial axial length measurements in congenital glaucoma. *Am J Ophthalmol*. 2001;132(6):926–928. doi:10.1016/S0002-9394(01)01183-7
3. Kiefer G, Schwenn O, Grehn F. Correlation of postoperative axial length growth and intraocular pressure in congenital glaucoma—a retrospective study in trabeculotomy and goniotomy. *Graefes Arch Clin Exp Ophthalmol*. 2001;239(12):893–899. doi:10.1007/s00417-001-0377-3

4. Mandal AK, Netland PA. *The Pediatric Glaucomas*. Philadelphia: Elsevier; 2006.
5. Sullivan JT, Clarke MP, Morin JD. The ocular manifestations of the Sturge-Weber syndrome. *J Pediatr Ophthalmol Strabismus*. 1992;29:349–356.
6. Mantelli F, Bruscolini A, La Cava M, Abdolrahimzadeh S, Lambiase A. Ocular manifestations of Sturge-Weber syndrome: pathogenesis, diagnosis, and management. *Clin Ophthalmol*. 2016;10:871–878. doi:10.2147/OPTH.S101963
7. Richter GM, Coleman AL. Minimally invasive glaucoma surgery: current status and future prospects. *Clin Ophthalmol*. 2016;10:189–206. doi:10.2147/OPTH.S80490
8. Saheb H, Ahmed II. Micro-invasive glaucoma surgery: current perspectives and future directions. *Curr Opin Ophthalmol*. 2012;23(2):96–104. doi:10.1097/ICU.0b013e32834ff1e7
9. Khouri AS, Wong SH. Ab interno trabeculectomy with a dual blade: surgical technique for childhood glaucoma. *J Glaucoma*. 2017;26(8):749–751.
10. Grover DS, Smith O, Fellman RL, et al. Gonioscopy assisted transluminal trabeculectomy: an ab interno circumferential trabeculectomy for the treatment of primary congenital glaucoma and juvenile open angle glaucoma. *Br J Ophthalmol*. 2015;99(8):1092–1096. doi:10.1136/bjophthalmol-2014-306269
11. Moses RA. The conventional outflow resistances. *Am J Ophthalmol*. 1981;92(6):804–810. doi:10.1016/S0002-9394(14)75634-X
12. Smith OU, Grover DS, Emanuel ME, Godfrey DG, Fellman RL. XEN gel stent in pediatric glaucoma. *J Glaucoma*. 2020;29(4):e19–e22. doi:10.1097/IJG.0000000000001453
13. Sousa DC, Leak I, Pinto LA. Steroid-induced protracted severe ocular hypertension in a 14-year-old girl. *BMJ Case Rep*. 2018;2018:bcr2018225244. doi:10.1136/bcr-2018-225244
14. Khouri AS, Zhu Y, Sadek H. Ab interno trabeculectomy with the dual blade in juvenile open-angle glaucoma. *Eur J Ophthalmol*. 2019;4:1120672119892440.
15. Khouri AS, Wong SH. Ab interno trabeculectomy with a dual blade: surgical technique for childhood glaucoma. *J Glaucoma*. 2017;26(8):749–751.
16. Arora S, Maeda M, Francis B, et al. Efficacy and safety of Ab interno trabeculectomy in juvenile open-angle glaucoma. *Can J Ophthalmol*. 2018;53(5):482–486. doi:10.1016/j.jcjo.2017.12.013

International Medical Case Reports Journal

Dovepress

Publish your work in this journal

The International Medical Case Reports Journal is an international, peer-reviewed open-access journal publishing original case reports from all medical specialties. Previously unpublished medical posters are also accepted relating to any area of clinical or preclinical science. Submissions should not normally exceed 2,000 words or 4

published pages including figures, diagrams and references. The manuscript management system is completely online and includes a very quick and fair peer-review system, which is all easy to use. Visit <http://www.dovepress.com/testimonials.php> to read real quotes from published authors.

Submit your manuscript here: <https://www.dovepress.com/international-medical-case-reports-journal-journal>