





CKJ REVIEW

Point-of-care ultrasound training in nephrology: a position statement by the International Alliance for POCUS in Nephrology

Abhilash Koratala¹, Eduardo R. Argañiz ^{2,3}, Gregorio Romero-González^{4,5,6}, Nathaniel Reisinger⁷, Siddiq Anwar^{8,9}, William Beaubien-Souligny ¹⁰, Bhavna Bhasin-Chhabra¹¹, Hugo Diniz¹², Marco Vaca Gallardo¹³, Fredzzia Graterol Torres^{14,5}, Faeq Husain-Syed ¹⁵, Jennifer Hanko¹⁶, Aala Jaber¹⁷, Amir Kazory¹⁸, Rupesh Raina^{19,20}, Claudio Ronco²¹, Octavio J. Salgado²², Sidharth Kumar Sethi ²³, Vanessa Villavicencio-Cerón²⁴, Manjusha Yadla²⁵ and Marcus Gomes Bastos^{26,27}

¹Division of Nephrology, Medical College of Wisconsin, Milwaukee, WI, USA, ²Departamento de Nefrología y Metabolismo Mineral, Instituto Nacional de Ciencias Médicas y Nutrición Salvador Zubirán, Mexico City, Mexico, ³Tecnológico de Monterrey, Escuela de Medicina y Ciencias de la Salud, Mexico City, Mexico, ⁴Nephrology Department, Germans Trias i Pujol University Hospital, Barcelona, Spain, ⁵REMAR-IGTP Group (Kidney-Affecting Diseases Research Group), Germans Trias i Pujol Research Institute, Barcelona, Spain, ⁶International Renal Research Institute of Vicenza, Vicenza, Italy, ⁷Renal Electrolyte and Hypertension Division, University of Pennsylvania, Philadelphia, PA, USA, ⁸Division of Medicine, Sheikh Shakhboub Medical City and School of Medicine Khalifa University, Abu Dhabi, United Arab Emirates, ⁹ADIA Lab, Abu Dhabi, United Arab Emirates, ¹⁰Division of Nephrology, Centre Hospitalier de l'Université de Montréal, Montreal, Quebec, Canada, ¹¹Division of Nephrology and Hypertension, Mayo Clinic Arizona, Scottsdale, AZ, USA, ¹²Nephrology Department, Centro Hospitalar Universitário de São João, Porto, Portugal, ¹³Nephrology Department, Hospital General Universitario Gregorio Marañón Madrid, Spain, ¹⁴Extracorporeal Therapies Unit, Germans Trias i Pujol University Hospital, Badalona, Spain, ¹⁵Department of Internal Medicine II, Division of Nephrology, University Hospital Giessen and Marburg, Justus-Liebig-University Giessen, Giessen, Germany, ¹⁶Belfast City Hospital, Belfast Health and Social Care Trust, Belfast, UK, ¹⁷Renal Section, Boston University Medical Center, Boston, MA, USA, ¹⁸Division of Nephrology, Hypertension and Renal Transplantation, University of Florida, Gainesville, FL, USA, ¹⁹Department of Nephrology, Akron Nephrology Associates/Cleveland Clinic Akron General Medical Center, Akron, OH, USA, ²⁰Department of Nephrology, Akron Children's Hospital, Akron, OH, USA, ²¹International Renal Research Institute and IRRIV Foundation for Research in Nephrology, Dialysis and Transplantation, San Bortolo Hospital, Vicenza, Italy,

Received: 16.7.2024; Editorial decision: 9.8.2024

© The Author(s) 2024. Published by Oxford University Press on behalf of the ERA. This is an Open Access article distributed under the terms of the Creative Commons Attribution-NonCommercial License (<https://creativecommons.org/licenses/by-nc/4.0/>), which permits non-commercial re-use, distribution, and reproduction in any medium, provided the original work is properly cited. For commercial re-use, please contact journals.permissions@oup.com

²²Department of Nephrology, School of Medicine, Universidad Católica de Cuenca, Avenida Las Américas y Humbolt, Cuenca, Ecuador, ²³Pediatric Nephrology, Kidney Institute, Medanta, The Medicity, Gurgaon, Haryana, India, ²⁴Department of Nephrology of the IEES Hospital, Portomed (Integral Center of Specialties), Portoviejo, Ecuador, ²⁵Department of Nephrology, Gandhi Medical College, Gandhi Hospitals, Hyderabad, Telangana, India, ²⁶Faculdade de Ciências Médicas e da Saúde de Juiz de Fora, Juiz de Fora, MG, Brazil and ²⁷Faculdade Ubaense Ozanam Coelho, Ubá, MG, Brazil

Correspondence to: Abhilash Koratala; Email: akoratala@mcw.edu

ABSTRACT

Point-of-care ultrasonography (POCUS) has rapidly evolved from a niche technology to an indispensable tool across medical specialties, including nephrology. This evolution is driven by advancements in technology and the visionary efforts of clinicians in emergency medicine and beyond. Recognizing its potential, medical schools are increasingly integrating POCUS into training curricula, emphasizing its role in enhancing diagnostic accuracy and patient care. Despite these advancements, barriers such as limited faculty expertise and 'lack of' standardized guidelines hinder widespread adoption and regulation. The International Alliance for POCUS in Nephrology (IAPN), through this position statement, aims to guide nephrologists in harnessing the diagnostic power of POCUS responsibly and effectively. By outlining core competencies, recommending training modalities and advocating for robust quality assurance measures, we envision a future where POCUS enhances nephrology practice globally, ensuring optimal patient outcomes through informed, evidence-based decision-making. International collaboration and education are essential to overcome current challenges and realize the full potential of POCUS in nephrology and beyond.

Keywords: competency, Doppler, nephrology, POCUS, training, ultrasound

BACKGROUND

Point-of-care ultrasonography (POCUS) refers to ultrasound examination performed at the patient's bedside by clinicians to answer focused clinical questions to guide management [1, 2]. Owing to technological advances leading to miniaturization of the equipment and the dedication of visionary physicians, notably those in emergency medicine, POCUS has transformed into an essential element of the physical examination over the past several years. Now it is being integrated into various medical and surgical specialties and is becoming a part of both medical school and graduate medical education curricula [3–6]. Once limited to procedural guidance, POCUS in nephrology has expanded to encompass diverse diagnostic applications, enhancing nephrologists' accuracy in evaluating complex fluid and haemodynamic disorders [7–12]. Professional nephrology organizations are increasingly recognizing POCUS as a vital clinical skill. For example, the recent American Society of Nephrology's task force report emphasized the need for POCUS training by stating, 'Nephrology fellowship training programs must offer higher-level training in nephrology-focused Point-of-Care Ultrasound, such as the assessment of kidney structure, volume status, and dialysis access' [13]. Despite growing enthusiasm, barriers such as the limited availability of POCUS-trained faculty and equipment in teaching institutions, the lack of awareness of the scope of practice and the lack of formal guidelines impede widespread adoption and regulation [14–16]. The International Alliance for POCUS in Nephrology (IAPN), consisting of nephrologists from around the world, strives to advance POCUS training and encourage its adoption within the field. This position statement aims to guide nephrologists interested in utilizing and teaching POCUS, offering recommendations on training and competency standards focusing on diagnostic applications. Procedural applications in nephrology vary significantly by

practice setting and are beyond the scope of this document. The authors, who are practicing nephrologists from diverse geographic locations, possess expertise in multi-organ POCUS and hold credentials for POCUS at their respective institutions.

SCOPE OF PRACTICE

The scope of POCUS is primarily determined by two factors: the competence of the physician and the pertinence of a particular sonographic application to the physician's specialization. There is minimal contention regarding the significance of kidney and urinary bladder ultrasound for nephrologists, given their expectation to incorporate information about structural abnormalities into clinical decision-making. A considerable amount of a nephrologist's time on a consultation service is dedicated to handling patients with intricate fluid and electrolyte disorders. Therefore, the objective evaluation of volume status using POCUS is crucial in nephrology practice, extending beyond the care of patients on maintenance dialysis. As elucidated in previous publications, the integration of multi-organ POCUS, encompassing focused cardiac ultrasound, lung ultrasound and Doppler assessment of systemic veins, significantly aids in assessing a patient's haemodynamic status (a more accurate term for 'volume status') in various clinical scenarios [11, 17–28]. Furthermore, POCUS assists in cannulation and facilitates the assessment of acute abnormalities of arteriovenous access in the dialysis unit [29, 30]. Fig. 1 depicts the commonly used sonographic applications in nephrology practice, illustrating the focused clinical questions being addressed.

As a new and evolving field, research on the applications of POCUS specific to nephrology is still in its early stages. A detailed discussion of studies in this area is beyond the scope

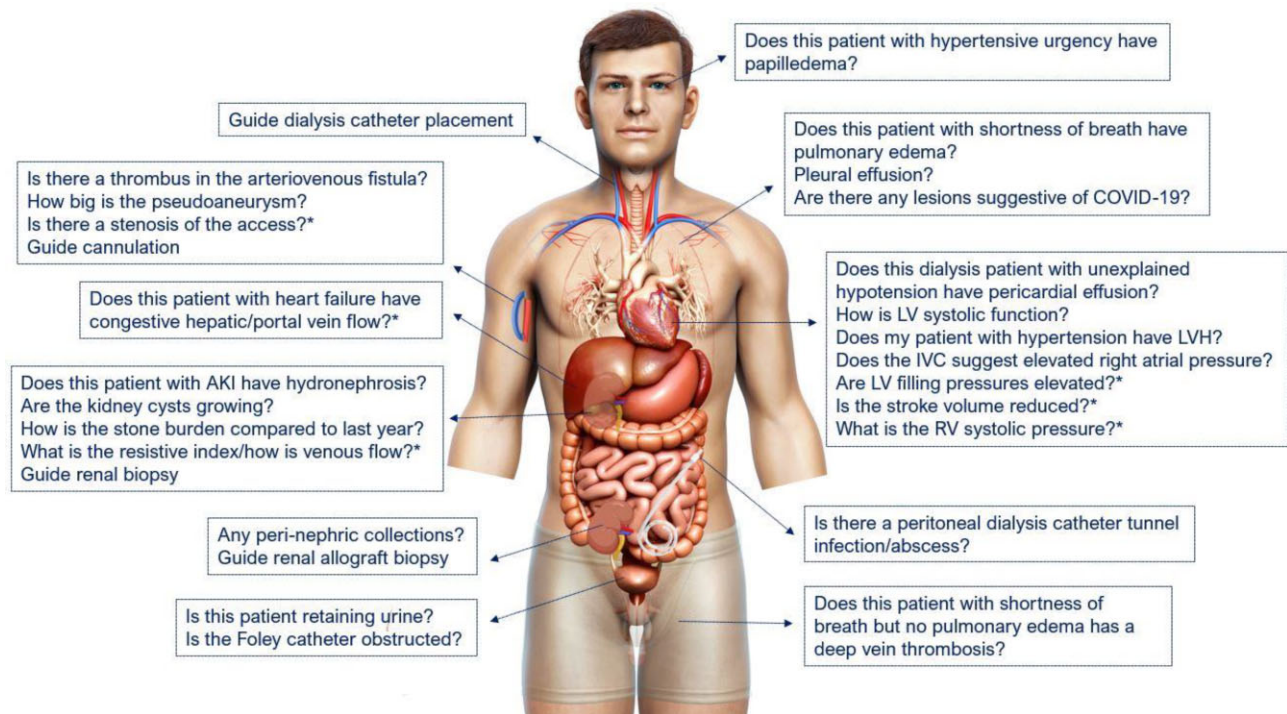


Figure 1: Scope of nephrology-related POCUS: organ-specific focused questions that can be answered by bedside ultrasonography. Those marked with an asterisk (*) indicate advanced sonographic applications requiring a higher operator skill level/additional training. The list of questions is not exhaustive [8]. Figure reused from reference 8 with permission.

of this article and is comprehensively covered in other articles [17–28], which dissect the current literature. Here are a few noteworthy ones that have recently garnered interest. In the LUST study (NCT02310061), end-stage kidney disease (ESKD) patients with high cardiovascular risk were randomized to dry weight titration based on lung ultrasound compared with the standard of care. Although the primary outcome of death, myocardial infarction or de novo decompensated heart failure was not different, a post hoc analysis based on previous heart failure literature showed less recurrence of decompensated heart failure in the POCUS group [31]. Dry weight reduction based on lung ultrasound also led to improved blood pressure control with fewer intradialytic hypotension events [32]. Other POCUS applications such as inferior vena cava and venous Doppler for the assessment of systemic venous congestion have been studied in patients with cardiorenal syndrome and a recent randomized clinical trial showed POCUS-guided therapy significantly improved the odds of achieving decongestion {odds ratio [OR] 2.6 [95% confidence interval (CI) 1.9–3.0], $P = .01$ } [33]. Furthermore, observational studies suggest that personalized treatment based on POCUS could be a valuable tool for tailoring care in patients with cirrhosis and acute kidney injury [34]. Given the increasing recognition of cardiac dysfunction and venous congestion in these patients, this highlights the need for randomized trials to objectively assess haemodynamics in this population.

It is reasonable to assume that the effective use of POCUS and the conduct of clinical research largely depend on proper training and competency of the operator. Quality research cannot be expected if investigators are not proficient in the technical aspects, accurate interpretation of POCUS findings and understanding its limitations. Additionally, with the increasing exposure of medical students and internal medicine residents to fundamental POCUS skills, akin to a physical exami-

nation, there is an anticipation for them to acquire specialty-specific advanced sonographic expertise, such as a comprehensive haemodynamic assessment using Doppler techniques during fellowship training. Nevertheless, it is important to emphasize that the intent of POCUS is not to substitute for consultative ultrasound examinations conducted by radiology or cardiology departments. These studies typically involve a comprehensive evaluation of an anatomical area, contrasting with the focused clinical question-guided assessment in POCUS. For instance, while a nephrologist performing POCUS is anticipated to identify mitral regurgitation as a potential cause for pulmonary oedema, evaluating the structural details required for surgery or performing transoesophageal echocardiography to search for vegetation are considered beyond their scope.

POCUS TRAINING AND CORE SKILLS

POCUS training should underscore three fundamental aspects: image acquisition, interpretation and the effective clinical integration of findings (Fig. 2). Commencing with a clear indication, proficient image acquisition ensures the quality and accuracy of diagnostic information. This involves mastering sonographic anatomy, understanding ergonomics for optimal scanning, selecting the appropriate transducer, optimizing images and following protocols for image storage and disinfection of the equipment. Subsequently, image interpretation demands expertise and attention to detail. Clinicians must determine the adequacy of the images, ensure correct orientation, adopt a systematic approach to interpreting normal and abnormal structures using standard terminology and identify artifacts that can either enhance or compromise diagnostic accuracy depending on the clinical context.

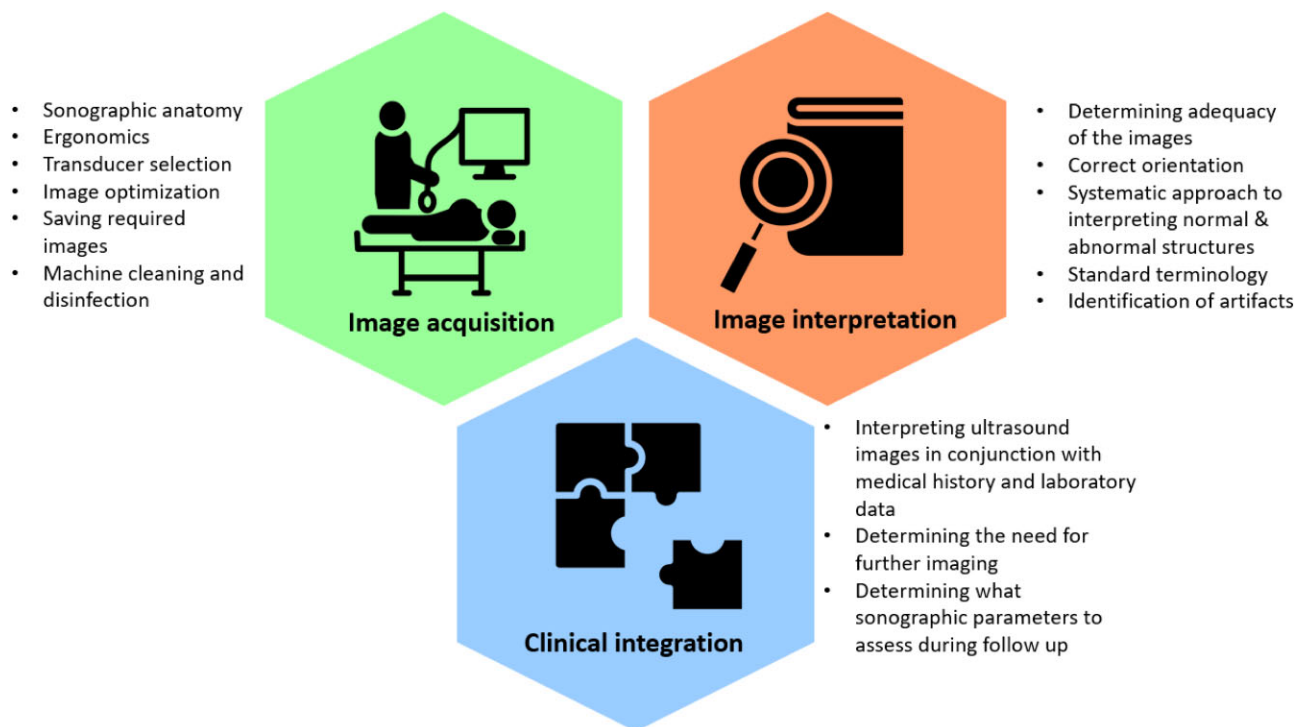


Figure 2: The three fundamental aspects of POCUS: image acquisition, interpretation and clinical integration.

Finally, the seamless integration of POCUS into clinical workflows enhances patient care by providing real-time insights. This entails interpreting ultrasound images in conjunction with medical history and laboratory data, determining the need for consultative imaging based on initial findings and deciding which sonographic parameters to assess during follow-up evaluations.

Herein, we will outline the core skills and competencies required for image acquisition and interpretation, categorizing diagnostic sonographic applications into basic and advanced. Basic applications are limited to grayscale and colour Doppler, while advanced applications involve ultrasound studies requiring spectral and tissue Doppler.

Basic POCUS applications

Sonographic application	Objectives and core competencies
Ultrasound physics and settings	<ul style="list-style-type: none"> • Select the appropriate transducer for each ultrasound study. • Adjust gain, depth, and focal zone to optimize image quality. • Explain ultrasound wave properties, differentiate grayscale appearances of different structures and identify common artifacts. • Familiarize with standard terminology, including relative echogenicity and transducer movements (slide, sweep, fan, rock, rotate, compress) [35].
Renal ultrasound	<ul style="list-style-type: none"> • Obtain long and short axis views of both right and left kidneys. • Optimize imaging to capture maximum kidney length in long axis, minimizing rib shadows. • Measure renal length and cortical/parenchymal thickness and evaluate cortical echogenicity. • Identify the structural components of a normal kidney. • Identify key abnormalities such as hydronephrosis, hydroureter, cysts, stones and renal outline distortions (mass).

Renal allograft and urinary bladder ultrasound	<ul style="list-style-type: none">• Recognize anatomical differences in renal allografts compared with native kidneys, including prominent collecting systems and proximity to the urinary bladder.• Obtain long and short axis views of the renal allograft.• Identify pathologies such as perinephric collections and hydronephrosis and evaluate vascular anastomosis using colour Doppler.• Obtain long and short axis views of the urinary bladder, calculate bladder volume, assess urinary retention, detect Foley catheter malposition, differentiate pelvic ascites from urine and identify prostatomegaly.
Lung ultrasound	<ul style="list-style-type: none">• Understand the rationale for multiple scanning systems and zones, correlating techniques.• Describe the physics behind artifact generation (A- and B-lines) and recognize the sonographic characteristics of cardiogenic and pneumogenic B-lines.• Identify pleural effusion, thoracic spine sign, qualitatively estimate the size and differentiate complex collections.• Distinguish dynamic from static air bronchograms, recognize mirror image artifacts and identify subpleural consolidations.• Recognize pleural sliding and its absence to suspect or diagnose pneumothorax.
Internal jugular vein ultrasound	<ul style="list-style-type: none">• Obtain long and short axis views of the internal jugular vein, locate collapse point and estimate central venous pressure.• Use right atrial depth from focused cardiac ultrasound where feasible, avoid assuming a standard 5-cm depth.• Ensure appropriate bed angle and avoid excessive transducer pressure and head turning.• Utilize alternative methods for central venous pressure estimation where appropriate, using jugular venous ultrasound, such as changes in cross-sectional area or diameter with Valsalva manoeuvre and respiration.
Focused cardiac ultrasound	<ul style="list-style-type: none">• Acquire basic cardiac views (parasternal long and short axis, apical 4 and 5 chamber, subxiphoid 4 chamber, inferior vena cava).• Correlate normal anatomical structures with sonographic images.• Explain M-mode indications and limitations in cardiac ultrasound.• Systematically interpret images to identify pericardial effusion and associated chamber collapse, estimate left ventricular ejection fraction, assess right ventricular systolic function, qualitatively assess variations in chamber size and identify gross valvular abnormalities using colour Doppler.• Estimate right atrial pressure using inferior vena cava long and short axis views.• Recognize if the views are inadequate, thereby hindering accurate interpretation.
Ultrasound of the dialysis access	<ul style="list-style-type: none">• Correlate vascular access anatomy (arteriovenous fistula/graft) with sonographic images (long and short axis views).• Identify pathologies such as pseudoaneurysm, fluid collections, thrombosis and grayscale and colour Doppler stigmata suggestive of stenosis.• Assist in cannulating a new or challenging access.• Describe abdominal wall anatomy, recognize normal peritoneal catheter and cuff sonographic appearances, suspect or diagnose tunnel infection and pericatheter fluid/abscess.
Others	<ul style="list-style-type: none">• Perform a 3-point compression ultrasound scan for deep vein thrombosis detection.• Identify common incidental findings like ascites and gallstones.• Recognize papilledema sonographic appearance.

Advanced POCUS applications

Sonographic application	Objectives and core competencies
Doppler physics and settings	<ul style="list-style-type: none"> • Explain principles of colour, power and spectral Doppler. • Adjust Doppler scale, gain, sweep speed, sample volume size and wall filter based on vascular bed and required measurements. • Apply angle correction as needed when measuring absolute velocities.
Venous excess ultrasound (VExUS)	<ul style="list-style-type: none"> • Hepatic vein: Describe the origin and terminology for individual waveforms (S, V, D, A) and changes with elevated right atrial pressure. Recognize limitations including effects of cardiac arrhythmias, valvular abnormalities and liver disease on the waveform, as well as the absence of simultaneous electrocardiogram. • Portal vein: Identify its typical appearance and changes with increased right atrial pressure. Recognize limitations such as the impact of portal hypertension and distinguish between cardiac and respiratory pulsatility. Understand that healthy athletic individuals may exhibit pulsatile waveforms at baseline. • Renal parenchymal vessel waveform: Identify its normal appearance and changes with rising right atrial pressure. Recognize challenges in image acquisition and troubleshoot appropriately. Obtain renal arterial resistive index where applicable. • Correlate VExUS findings with other sonographic observations, especially those from cardiac ultrasound. • Become acquainted with extended VExUS (eVExUS), which involves Doppler assessment of other systemic veins such as the internal jugular vein, femoral vein and superior vena cava when primary veins are inaccessible or unreliable.
Focused Doppler echocardiography	<ul style="list-style-type: none"> • Identify appropriate cardiac views and accurately place sample volume or Doppler cursor for desired Doppler parameters. • Recognize when the underlying cardiac view is inadequate for Doppler ultrasound. • Obtain optimal tracings and perform precise measurements of left ventricular outflow tract velocity time integral (LVOT VTI), cardiac output and right ventricular outflow tract velocity time integral (RVOT VTI) and conduct qualitative waveform assessment. • Measure pulmonary artery systolic pressure (PASP), perform mitral inflow Doppler (E:A ratio, E-wave deceleration time), measure mitral annular e' velocity, and tricuspid annular S' velocity using tissue Doppler. • Recognize sonographic stigmata of pre- and post-capillary pulmonary hypertension. • Acknowledge the limitations of each of these Doppler parameters where they may not be reliable. • Optimize Doppler alignment with alternate cardiac views where indicated (e.g. apical 3-chamber view for LVOT VTI, parasternal right ventricular inflow view for PASP, subxiphoid RVOT Doppler).
Arteriovenous access	<ul style="list-style-type: none"> • Evaluate flow in the access, usually within the feeding artery. • Use beam steering and angle correction features effectively to ensure accurate velocity recordings.

Others

Evaluation of renal artery stenosis (beyond identification of a parvus tardus waveform or gross differences in resistive index), detailed vascular mapping prior to arteriovenous access placement, comprehensive evaluation of stenosis in arteriovenous access using spectral Doppler and employing contrast-enhanced ultrasound are considered beyond the scope of POCUS. These procedures require significant time and expertise and the sonographic parameters have limited immediate utility for patient management to justify clinician-performed bedside ultrasound. Nevertheless, some institutions with robust ultrasound programs, particularly in outpatient settings, may choose to include these techniques in the training of nephrology trainees.

METHODS OF INSTRUCTION

Educational modalities for POCUS differ in their advantages and disadvantages, as well as in their focus, whether it be in image acquisition, interpretation or clinical integration [36]. In-person scanning of patients provides real-time feedback and true pathology exposure but is faculty-intensive, does not scale well with learner numbers and relies on unpredictable pathology availability. Scanning standardized patients provides real-time feedback and predictable scheduling, but the drawback is limited or no exposure to actual pathology. It is beneficial for 'bootcamp'-style intensive learning sessions early in residency or fellowship training. High-fidelity simulation mannequins offer immediate feedback, support self-directed learning and enhance understanding of sonographic anatomy, particularly for complex applications like cardiac ultrasound [37, 38]. Some models offer a wide range of pathology options but are expensive and may be cost-prohibitive for smaller institutions. Live lectures can accommodate moderate learner numbers but require expert instructors and do not develop mechanical skills. Recorded lectures and textbooks can reach larger audiences, are always accessible and offer high-quality content, which is especially beneficial for learners without local POCUS-trained faculty. However, they do not adapt to the needs of individual learners and require self-motivation since there is not a set time to watch the lectures, unlike live sessions. One study found that medical students who attended live teleconference lectures scored higher on weekly quizzes and practice exams compared with those who watched recorded lectures [39].

Social media platforms like X (formerly known as Twitter) provide a valuable space for POCUS learning and dissemination, allowing educators from diverse disciplines worldwide to share bite-sized information and engage in real-time dialogue. While beneficial for training one's eyes to various sonographic pathologies, the content on these platforms can be disorganized and lacks customization for individual learners. Relying solely on social media may result in missing essential knowledge while focusing disproportionately on rare or 'eye-catching' pathologies. X has also been utilized as a research tool to gather insights from learners and educators, shaping POCUS training in nephrology [40, 41]. Similarly, educational blogs (e.g. NephroPOCUS.com) offer nephrology-specific POCUS education through short posts and videos. However, like social media, these blogs have the limitation of not being organized like a textbook, and the material is not formally peer reviewed, although comments can serve as a form of feedback. Educators sharing POCUS cases and images on social media should exercise the utmost caution

to avoid disclosing any potentially identifiable patient information. In situations involving ambiguity, such as rare diseases or unique medical histories, obtaining informed patient consent is essential.

We suggest utilizing various modalities based on where a learner is in their training, adapting to local workflows and the size of the training program.

ULTRASOUND EQUIPMENT

The availability of ultrasound equipment is a crucial factor influencing the quality of POCUS education. Interest in affordable handheld devices is increasing because traditional cart-based machines are relatively expensive. Nephrology training programs must consider various factors beyond cost when acquiring ultrasound equipment. Typically, low-cost handheld devices offer lower image resolution, which may not impact applications such as lung ultrasound or internal jugular vein ultrasound, but can notably compromise the quality of cardiac imaging. Novice POCUS users might struggle to appreciate sonographic anatomy with such devices. Some of these devices may lack features such as full-range spectral Doppler, which is crucial for haemodynamic assessment. A study evaluating four commonly used handheld ultrasound devices in the USA found that none possessed all the desired attributes according to expert POCUS users [42]. Additionally, the size of the ultrasound monitor is also important. Larger screens (as opposed to tablet or cell phone-based displays) allow better appreciation of images or pathology at the bedside, especially with multiple learners. However, portability is important for equipment used in outpatient dialysis units and off-site clinics. We recommend that nephrology departments invest in both cart-based and handheld devices to provide an optimal training experience.

Consideration should be given to utilizing devices integrated with novel artificial intelligence (AI) techniques to assist in image acquisition, which can be particularly helpful in scenarios with limited availability of trained faculty or colleagues. Furthermore, automatic real-time measuring tools have demonstrated the ability to make accurate measurements quickly and easily, significantly enhancing examination reliability while saving the operator considerable time and effort. For instance, tools like auto-VTI measurement, left ventricular ejection fraction estimation and inferior vena cava diameter measurement have shown good correlation with expert readings [43]. Additionally, automated B-line counting on lung ultrasound and auto-calculation of the E:e' ratio for evaluating diastolic dysfunction show promise [44]. The use of AI-assisted ultrasound in chronic kidney disease and quantitative hydronephrosis diagnosis also holds significant potential [45]. Although still in the early stages of development, further advancement and standardization of this technology could greatly enhance the ubiquity of POCUS in nephrology. On the flipside, overreliance on AI-generated data when the underlying greyscale or Doppler images are suboptimal (e.g. tilted cardiac images) can lead to incorrect interpretations.

POCUS scans may be billable based on local healthcare regulations and systems, which can help offset equipment costs over time. Collaborative cost-sharing initiatives with departments like critical care and emergency medicine that also utilize POCUS may be beneficial where possible. In addition, creating a user-centred POCUS documentation workflow system for examination ordering, documentation, selective archiving and billing could streamline the process of revenue generation [46].

We do not endorse specific brands of ultrasound machines. Institutional information technology departments typically assist in selecting brands based on local image archiving requirements and preferences.

POCUS WORKSHOPS

Given the limited number of POCUS-trained nephrologists, well-organized nephrology-oriented POCUS workshops/courses at regional, national and international levels play a significant role in advancing the field until we accumulate a critical mass of trained nephrologists at the institutional level. Here are our recommended guidelines for organizing a POCUS workshop:

- Clearly define the goals and objectives, specifying which sonographic applications will be taught.
- Ensure that faculty meet minimum competency criteria according to local standards. While multidisciplinary faculty can be valuable, it is crucial they understand the common-use cases of POCUS in nephrology. Although the fundamentals of sonographic skills are consistent across specialties, clinical integration varies, necessitating tailored content for nephrology audiences.
- Focus didactics on principles of image acquisition, sonographic anatomy, interpretation of normal and abnormal images and case-based clinical integration pearls. In-person lectures are preferred where feasible, but online versions may be favoured in some settings depending on the intended audience and the specific centre's experience.
- Maintain lecture adherence to allocated topics within the timetable and local continuing medical education requirements.
- For the hands-on component, we recommend a learner:instructor ratio of 2:1 or 3:1, with a maximum of 4:1 assuming a rotation span of 30 minutes, aligning with current expert guidance [47, 48]. We recognize the impact of financial limitations and geographic differences in this regard, however, particularly for paid courses, organizers should strive to provide attendees with a fair return on their investment by ensuring they receive adequate hands-on experience.
- Use a checklist of tasks to ensure consistent learning of the sonographic technique and recognition of structures at each scan station.
- Include diverse volunteers or models for scanning practice, encompassing males, females and different body types. Where feasible, models with known abnormalities can also be included. Have a system in place to address any incidental abnormal findings discovered during the workshop.
- Use both cart-based and handheld ultrasound devices where possible, to allow learners to compare the image quality and ergonomics.
- Workshop duration should align with the number of sonographic applications taught; we prefer 1- to 2-day formats, especially for learners new to POCUS.
- Hold workshops alongside major professional society scientific meetings where applicable to minimize travel and accommodation expenses for participants, especially physicians in training.
- Consider conducting a post-test as a formative assessment at the conclusion of the course and collecting feedback from the participants.
- Provide a 'certificate of completion' detailing didactic and hands-on hours at the end of the workshop. Avoid certify-

ing 'competency' unless the course is specifically designed to do so as part of a certification program.

- The primary goal of these workshops is to instil confidence in participants so they can begin practicing scanning at their respective institutions. There are limited data on multi-organ POCUS courses in nephrology, but the existing findings are promising, indicating improvements in participants' knowledge and confidence in acquiring images [16, 49, 50]. These publications also serve as a model for designing workshop structures tailored to local needs and addressing the barriers to POCUS implementation.

COMPETENCY ASSESSMENT AND CERTIFICATION

Although workshops can boost confidence and serve as an initial step, achieving competency requires structured, longitudinal practice. Without ongoing, consistent practice following a short training program, retention of ultrasound skills is often suboptimal [51]. Studies have consistently shown that confident learners may not necessarily be competent, particularly without continued supervised practice [52, 53]. The literature on longitudinal curricula in nephrology is scarce but does exist, providing a framework for other programs [54]. However, the effectiveness of these curricula in terms of competency has not been formally examined, which represents the next logical step for the nephrology research community.

'Competence' in medicine is multifaceted and involves the consistent and thoughtful application of knowledge, technical skills, clinical reasoning, emotions, values and reflection in everyday practice to benefit both individuals and the community [55]. 'Competency' is a measurable component of competence, representing particular abilities or patterns of knowledge required to execute specific functions within a job. We endorse the components of competency for POCUS as defined by the American College of Emergency Physicians (ACEP):

Clinicians must recognize the indications and contraindications for the POCUS exam.

Clinicians must be able to acquire adequate images, which requires an understanding of basic ultrasound physics and the skills to operate the ultrasound system correctly while performing exam protocols on patients with varying conditions and body types.

Clinicians need to interpret the images by distinguishing normal anatomy, common variants and a range of pathologies from obvious to subtle.

Clinicians must be able to integrate POCUS exam findings into patient care plans and management. Effective integration involves understanding the accuracy of each exam, proper documentation, quality assurance and POCUS reimbursement [56].

There are various tools for assessing competency in POCUS, including self-assessment of knowledge and skills, multiple-choice questions for objective knowledge assessment, clinical vignettes to simulate scenarios, Objective Structured Clinical Examinations (OSCEs) for testing technical proficiency, real-time assessments during patient scans and longitudinal evaluations with periodic reviews [57]. It is important to recognize that no assessment method is perfect because each must balance reproducibility and standardization while being practically relevant. Tools that are easily standardized, such as multiple-choice questions, cannot test hands-on skills, while methods involving real patients face challenges in standardization. In longitu-

dinal training, a combination of these methods can be utilized based on the trainee's stage of development. Previous publications have outlined image review scales and OSCE formats specific to nephrology [54].

Traditional numerical benchmarks for procedural training in medical education offer a straightforward approach to documenting the completion of a prespecified number of exams required of trainees for certification. However, learning curves can differ significantly among trainees and across different applications and performing a certain number of scans cannot guarantee competency. Nevertheless, we recognize the importance of establishing benchmarks to streamline the process of granting POCUS privileges to practicing physicians, contingent upon the presence of a local quality assurance system. As emergency medicine has long integrated POCUS into its practice, we draw upon current benchmarks from emergency medicine literature and guidelines. According to the ACEP, it is recommended that trainees complete 25–50 quality-reviewed exams in a specific application, with an overall benchmark of 150–300 total emergency ultrasound exams [56]. Adaptations of these benchmarks for nephrology have been proposed, distinguishing between basic and advanced sonographic applications. We support the certification requirements outlined by Romero-González *et al.* [58], acknowledging that these may require refinement as more nephrology-specific competency data become available. In brief, basic POCUS certification, covering greyscale and colour Doppler, requires a minimum of 6 hours of didactics, coupled with at least 30 minutes of hands-on instruction per sonographic application (e.g. 30 minutes allocated for kidney, 30 for lung, 30 for basic cardiac views, etc.) per learner under direct supervision. Documentation of a minimum of 25 adequate studies per application is necessary, with adequacy determined by POCUS experts certified by a professional certifying authority or authorized to perform POCUS at the trainee's institution. It is important to understand that depending on prior scanning experience, obtaining adequate images, particularly cardiac, often requires more time than the minimum instruction time mentioned above. This recommendation is only intended to serve as a rough guideline to streamline documentation for hospital credentialing, as it is challenging to accurately document the informal supervision by institutional experts required to obtain the necessary 25 adequate scans compared with dedicated ultrasound courses. For advanced applications that include spectral Doppler, an additional minimum of 6 hours of didactics and at least 60 minutes of hands-on instruction per sonographic application per learner under direct expert supervision are required. A minimum of 50 adequately documented scans per sonographic application is necessary for certification in advanced POCUS.

Where possible, we recommend establishing institutional guidelines for local certification and ongoing quality assurance in collaboration with multidisciplinary experts. Multidisciplinary teamwork is essential for advancing POCUS in nephrology. By engaging with specialists from various fields, nephrologists can leverage the diverse perspectives and experience these professionals provide. For example, critical care and emergency medicine specialists often have significant experience with POCUS in acute settings, offering valuable insights into rapid diagnosis and management. Radiologists can contribute their expertise in imaging interpretation and quality control, ensuring high standards are maintained. This collaborative approach supports the development of local credentialing and quality assurance pathways, with expert committees periodically reviewing studies performed by newly credentialed

physicians to ensure proper documentation and regulatory compliance. Published models are available for creating these pathways at the institutional level, serving as a guide for others [59].

External certifications necessitate fees from applicants but serve as a viable option in the absence of an institutional pathway. We advocate for certifications that include standardized testing (e.g. the National Board of Echocardiography Special Competence in Critical Care Echocardiography exam in the USA or its equivalent in other countries) over those granted by commercial entities with minimal scrutiny.

We also emphasize the importance of image archiving. This practice enables timely feedback for trainees, facilitates billing and allows the seeking of expert opinions when necessary. With the ability to retrieve images from patient charts, the need for multiple specialists to perform repeat exams for the same clinical question is eliminated. Moreover, it aids in quality assurance, which is crucial for sustaining and advancing a POCUS program. It is essential to securely store images within the medical infrastructure following local protocols and ensure they are not shared, reproduced or used outside secure systems without proper de-identification, which includes redacting the patient's name, date of birth and other identifiers such as medical record number [60, 61].

CONCLUSIONS

Despite significant strides, diagnostic POCUS in nephrology still faces challenges, including limited faculty expertise and the absence of clear training guidelines. Moreover, access to POCUS varies significantly across regions and countries, influenced by healthcare infrastructure, training opportunities and economic resources. In high-income countries, POCUS adoption is more attainable, supported by established training programs led by multispecialty experts and institutional backing. Conversely, in low- and middle-income countries, access to POCUS is often limited by the availability of equipment and trained professionals. These global and regional disparities underscore the need for tailored approaches to training and integrating POCUS into routine nephrology practice. Moving forward, collaboration among nephrology professional societies is essential to establish universal standards for POCUS training and quality assurance, as well as to address geographic disparities in access to POCUS. Future research should focus on longitudinal competency assessment and testing the efficacy of various curricular structures, including telemedicine-based approaches such as remote lectures and supervision of scanning techniques and assistance with interpretation, which may help mitigate expertise-related disparities to some extent. With POCUS now recognized as a superior diagnostic tool, the next step is to study its impact on practical clinical outcomes in nephrology-specific scenarios such as end-stage kidney disease, cardiorenal syndromes, hepatorenal dysfunction and sepsis-induced kidney injury. This includes its potential to prevent hospital readmissions, reduce patient discomfort through early diagnosis and treatment, avoid unnecessary imaging or procedures and enhance the overall quality of care. While doing so, it is important to avoid overemphasizing isolated POCUS modalities, such as focusing solely on inferior vena cava or lung ultrasound, and instead consider the continuity of the haemodynamic circuit. Additionally, POCUS should not be viewed as a miraculous solution that directly improves mortality. Mortality benefit can only be achieved when the diagnostic tool is paired with an effective treatment that

can influence the outcome. Therefore, expectations must be realistic and focused on helping patients rather than dismissing improved diagnostic methods due to the absence of a direct mortality benefit. By fostering interdisciplinary partnerships and embracing technological advancements, nephrology can harness POCUS's full potential to enhance patient care.

FUNDING

None declared.

AUTHORS' CONTRIBUTIONS

A.Ko., E.R.A., G.R.-G., N.R., M.G.B. - core writing committee, conceived the outline and drafted the initial version. Rest of the authors reviewed and revised the manuscript for critical intellectual content and actively participated in shaping up the final document.

DATA AVAILABILITY STATEMENT

No new data were generated or analysed in support of this research.

CONFLICT OF INTEREST STATEMENT

S.A. is supported by ECHONous with a research grant in kind. The remainder of the authors declare no conflicts of interest.

REFERENCES

- Díaz-Gómez JL, Mayo PH, Koenig SJ. Point-of-care ultrasonography. *N Engl J Med* 2021;385:1593–602. <https://doi.org/10.1056/NEJMra1916062>
- Koratala A, Kazory A. An introduction to point-of-care ultrasound: Laennec to Lichtenstein. *Adv Chronic Kidney Dis* 2021;28:193–9. <https://doi.org/10.1053/j.ackd.2021.07.002>
- Soni NJ, Schnobrich D, Mathews BK et al. Point-of-care ultrasound for hospitalists: a position statement of the Society of Hospital Medicine. *J Hosp Med* 2019;14:E1–6. <https://doi.org/10.12788/jhm.3079>
- Davis JJ, Wessner CE, Potts J et al. Ultrasonography in undergraduate medical education: a systematic review. *J Ultrasound Med* 2018;37:2667–79. <https://doi.org/10.1002/jum.14628>
- Ma IWY, Steinmetz P, Weerdenburg K et al. The Canadian Medical Student Ultrasound Curriculum: a statement from the Canadian Ultrasound Consensus for Undergraduate Medical Education Group. *J Ultrasound Med* 2020;39:1279–87. <https://doi.org/10.1002/jum.15218>
- LoPresti CM, Schnobrich D, Novak W et al. Current point of care ultrasound use and training among internal medicine residency programs from the 2020 APDIM Program Director's survey. *Am J Med* 2022;135:397–404. <https://doi.org/10.1016/j.amjmed.2021.11.002>
- Romero-González G, Manrique J, Slon-Roblero, MF et al. PoCUS in nephrology: a new tool to improve our diagnostic skills. *Clin Kidney J* 2022;16:218–29. <https://doi.org/10.1093/ckj/sfac203>
- Koratala A, Reisinger N. POCUS for nephrologists: basic principles and a general approach. *Kidney360* 2021;2:1660–8. <https://doi.org/10.34067/KID.0002482021>
- Reisinger NC, Koratala A. Incorporating training in POCUS in nephrology fellowship curriculum. *Clin J Am Soc Nephrol* 2022;17:1442–5. <https://doi.org/10.2215/CJN.09580822>
- Bastos MG, Vieira AL, Nascimento MMD et al. Point-of-care ultrasonography in nephrology: a cross-sectional national survey among Brazilian nephrologists. *J Bras Nefrol* 2021;43:68–73. <https://doi.org/10.1590/2175-8239-jbn-2020-0023>
- Karakala N, Córdoba D, Chandrashekar K et al. Point-of-care ultrasound in acute care nephrology. *Adv Chronic Kidney Dis* 2021;28:83–90. <https://doi.org/10.1053/j.ackd.2021.06.003>
- Sethi SK, Raina R, Koratala A et al. Point-of-care ultrasound in pediatric nephrology. *Pediatr Nephrol* 2023;38:1733–51. <https://doi.org/10.1007/s00467-022-05729-5>
- Rosenberg ME, Anderson S, Farouk SS et al. Reimagining nephrology fellowship education to meet the future needs of nephrology: a report of the American Society of Nephrology Task Force on the Future of Nephrology. *Clin J Am Soc Nephrol* 2023;18:816–25. <https://doi.org/10.2215/CJN.000000000000133>
- Cook DL, Patel S, Nee R et al. Point-of-care ultrasound use in nephrology: a survey of nephrology program directors, fellows, and fellowship graduates. *Kidney Med* 2023;5:100601. <https://doi.org/10.1016/j.xkme.2023.100601>
- Moore CA, Ross DW, Pivert KA et al. Point-of-care ultrasound training during nephrology fellowship: a national survey of fellows and program directors. *Clin J Am Soc Nephrol* 2022;17:1487–94. <https://doi.org/10.2215/CJN.01850222>
- Koratala A, Reisinger N. Insights and observations from a multi-organ nephrology point-of-care ultrasound course. *Clin Nephrol* 2024;101:46–8. <https://doi.org/10.5414/CN111230>
- Argaiz ER, Romero-Gonzalez G, Rola P et al. Bedside ultrasound in the management of cardiorenal syndromes: an updated review. *Cardiorenal Med* 2023;13:372–84. <https://doi.org/10.1159/000534976>
- Batool A, Chaudhry S, Koratala A. Transcending boundaries: unleashing the potential of multi-organ point-of-care ultrasound in acute kidney injury. *World J Nephrol* 2023;12:93–103. <https://doi.org/10.5527/wjn.v12.i4.93>
- Turk M, Robertson T, Koratala A. Point-of-care ultrasound in diagnosis and management of congestive nephropathy. *World J Crit Care Med* 2023;12:53–62. <https://doi.org/10.5492/wjccm.v12.i2.53>
- Bhasin-Chhabra B, Koratala A. Point of care ultrasonography in onco-nephrology: a stride toward better physical examination. *World J Nephrol* 2023;12:29–39. <https://doi.org/10.5527/wjn.v12.i2.29>
- Argaiz ER, Koratala A, Reisinger N. Comprehensive assessment of fluid status by point-of-care ultrasonography. *Kidney360* 2021;2:1326–38. <https://doi.org/10.34067/KID.0006482020>
- Reisinger N, Koratala A. Current opinion in quantitative lung ultrasound for the nephrologist. *Curr Opin Nephrol Hypertens* 2023;32:509–14. <https://doi.org/10.1097/MNH.0000000000000919>
- Romero-González G, Manrique J, Castaño-Bilbao I et al. PoCUS: congestion and ultrasound two challenges for nephrology in the next decade. *Nefrología (Engl Ed)* 2022;42:501–5. <https://doi.org/10.1016/j.nefro.2021.09.008>
- Koratala A. Utilizing point-of-care ultrasound in the cardiorenal clinic to enhance patient care. *J Bras Nefrol* 2021;43:135–6. <https://doi.org/10.1590/2175-8239-jbn-2020-00234>

25. Bhasin-Chhabra B, Veitla V, Weinberg S et al. Demystifying hyponatremia: a clinical guide to evaluation and management. *Nutr Clin Pract* 2022;37:1023–32. <https://doi.org/10.1002/ncp.10907>
26. Koratala A, Reisinger N. Venous excess Doppler ultrasound for the nephrologist: pearls and pitfalls. *Kidney Med* 2022;4:100482. <https://doi.org/10.1016/j.xkme.2022.100482>
27. Argaiz ER. VExUS nexus: bedside assessment of venous congestion. *Adv Chronic Kidney Dis* 2021;28:252–61. <https://doi.org/10.1053/j.ackd.2021.03.004>
28. Di Nicolò P, Tavazzi G, Nannoni L et al. Inferior vena cava ultrasonography for volume status evaluation: an intriguing promise never fulfilled. *J Clin Med* 2023;12:2217. <https://doi.org/10.3390/jcm12062217>
29. Koratala A, Teodorescu V, Niyyar VD. The nephrologist as an ultrasonographer. *Adv Chronic Kidney Dis* 2020;27:243–52. <https://doi.org/10.1053/j.ackd.2020.03.005>
30. Dua Niyyar V, Buch K, Rawls F et al. Effectiveness of ultrasound-guided cannulation of AVF on infiltration rates: a single center quality improvement study. *J Vasc Access* 2023;24:322–8.
31. Zoccali C, Torino C, Mallamaci F et al. A randomized multicenter trial on a lung ultrasound-guided treatment strategy in patients on chronic hemodialysis with high cardiovascular risk. *Kidney Int* 2021;100:1325–33. <https://doi.org/10.1016/j.kint.2021.07.024>
32. Loutradis C, Sarafidis PA, Ekart R et al. The effect of dry-weight reduction guided by lung ultrasound on ambulatory blood pressure in hemodialysis patients: a randomized controlled trial. *Kidney Int* 2019;95:1505–13. <https://doi.org/10.1016/j.kint.2019.02.018>
33. Islas-Rodríguez JP, Miranda-Aquino T, Romero-González G et al. Effect on kidney function recovery guiding decongestion with VExUS in patients with cardiorenal syndrome 1: a randomized control trial. *Cardiorenal Med* 2024;14:1–11. <https://doi.org/10.1159/000535641>
34. Velez JCQ, Petkovich B, Karakala N et al. Point-of-care echocardiography unveils misclassification of acute kidney injury as hepatorenal syndrome. *Am J Nephrol* 2019;50:204–11. <https://doi.org/10.1159/000501299>
35. Bahner DP, Blickendorf JM, Bockbrader M et al. Language of transducer manipulation: codifying terms for effective teaching. *J Ultrasound Med* 2016;35:183–8. <https://doi.org/10.7863/ultra.15.02036>
36. Panebianco N, Baston C. Training, competency, and interdisciplinary collaboration in point-of-care ultrasound. *Semin Ultrasound CT MR* 2024;45:91–7. <https://doi.org/10.1053/j.sult.2023.12.010>
37. Koratala A. Simulation in POCUS education: how I do it. <https://nephropocus.com/2024/05/05/simulation-in-pocus-education-how-i-do-it/> (16 June 2024, date last accessed).
38. Koratala A, Paudel HR, Regner KR. Nephrologist-led simulation-based focused cardiac ultrasound workshop for medical students: insights and implications. *Am J Med Open* 2023;10:100051. <https://doi.org/10.1016/j.ajmo.2023.100051>
39. Huerta CT, Saberi RA, Thorson CM et al. Effects of recorded versus live teleconference didactic lectures on medical student performance in the surgery clerkship. *J Surg Educ* 2023;80:228–34. <https://doi.org/10.1016/j.jsurg.2022.09.017>
40. Vasudev K, Kazory A, Ronco C et al. Point of care ultrasound training in nephrology: Twitter poll as a modern tool for development of an effective curriculum. *Blood Purif* 2023;52:516–21. <https://doi.org/10.1159/000529263>
41. Koratala A, Bhattacharya D, Kazory A. Harnessing Twitter polls for multi-specialty collaboration in standardizing point-of-care ultrasonography in nephrology. *Clin Nephrol* 2020;94:50–2. <https://doi.org/10.5414/CN109946>
42. Nathanson R, Le MT, Proud KC et al. Development of a point-of-care ultrasound track for internal medicine residents. *J Gen Intern Med* 2022;37:2308–13. <https://doi.org/10.1007/s11606-022-07505-5>
43. Wang H, Uraco AM, Hughes J. Artificial intelligence application on point-of-care ultrasound. *J Cardiothorac Vasc Anesth* 2021;35:3451–2. <https://doi.org/10.1053/j.jvca.2021.02.064>
44. Gohar E, Herling A, Mazuz M et al. Artificial intelligence (AI) versus POCUS expert: a validation study of three automatic AI-based, real-time, hemodynamic echocardiographic assessment tools. *J Clin Med* 2023;12:1352. <https://doi.org/10.3390/jcm12041352>
45. Liang X, Du M, Chen Z. Artificial intelligence-aided ultrasound in renal diseases: a systematic review. *Quant Imaging Med Surg* 2023;13:3988–4001. <https://doi.org/10.21037/qims-22-1428>
46. Thompson B, Schoenfeld E, Westafer L et al. Implementation of an automated, user-centered point-of-care ultrasound workflow improves documentation and billing. *Acad Emerg Med* 2023;30:180–6. <https://doi.org/10.1111/acem.14654>
47. Dietrich CF, Hoffmann B, Abramowicz J et al. Medical student ultrasound education: a WFUMB position paper, part I. *Ultrasound Med Biol* 2019;45:271–81. <https://doi.org/10.1016/j.ultrasmedbio.2018.09.017>
48. Society of Hospital Medicine. POCUS certificate of completion. <https://www.hospitalmedicine.org/archive/pocus-certificate-of-completion/> (16 June 2024, date last accessed).
49. Nunes AA, Pazeli Júnior JM, Rodrigues AT et al. Development of skills to utilize point-of-care ultrasonography in nephrology practice. *J Bras Nefrol* 2016;38:209–14. <https://doi.org/10.5935/0101-2800.20160030>
50. Koratala A, Soni NJ, Mehta R et al. Effectiveness of a brief point of care ultrasound course at a national nephrology conference. *POCUS J* 2024;9:71–4. <https://doi.org/10.24908/pocus.v9i1.16858>
51. Hempel D, Stenger T, Campo dell' Orto M et al. Analysis of trainees' memory after classroom presentations of didactical ultrasound courses. *Crit Ultrasound J* 2014;6:10. <https://doi.org/10.1186/2036-7902-6-10>
52. Kumar A, Weng Y, Wang L et al. Portable ultrasound device usage and learning outcomes among internal medicine trainees: a parallel-group randomized trial. *J Hosp Med* 2020;15:e1–6. <https://doi.org/10.12788/jhm.3351>
53. Elliott BP, Berglund A, Markert R et al. Confidence and utilization are poorly associated with point-of-care ultrasound competency among internal medicine trainees. *Mil Med* 2023;188(Suppl 6):316–21. <https://doi.org/10.1093/milmed/usad127>
54. Koratala A, Olaoye OA, Bhasin-Chhabra B et al. A blueprint for an integrated point-of-care ultrasound curriculum for nephrology trainees. *Kidney360* 2021;2:1669–76. <https://doi.org/10.34067/KID.0005082021>
55. Epstein RM, Hundert EM. Defining and assessing professional competence. *JAMA* 2002;287:226–35. <https://doi.org/10.1001/jama.287.2.226>
56. Ultrasound guidelines: emergency, point-of-care and clinical ultrasound guidelines in medicine. *Ann Emerg Med* 2017;69:e27–54. <https://doi.org/10.1016/j.annemergmed.2016.08.457>

57. Kumar A, Kugler J, Jensen T. Evaluation of trainee competency with point-of-care ultrasonography (POCUS): a conceptual framework and review of existing assessments. *J Gen Intern Med* 2019;**34**:1025–31. <https://doi.org/10.1007/s11606-019-04945-4>
58. Romero-González G, Argaiz ER, Koratala A et al. Towards standardization of POCUS training in nephrology: the time is NOW. *Nefrología (Engl Ed)* 2024;**44**:5–9. <https://doi.org/10.1016/j.nefro.2024.02.005>
59. Mathews BK, Zwank M. Hospital medicine point of care ultrasound credentialing: an example protocol. *J Hosp Med* 2017;**12**:767–72. <https://doi.org/10.12788/jhm.2809>
60. Koratala A, Reisinger N. Point-of-care ultrasound training in nephrology: a leap forward, not merely a check mark. *Kidney Med* 2023;**6**:100752. <https://doi.org/10.1016/j.xkme.2023.100752>
61. Oto B, Baeten R, Chen L et al. Best practices for point of care ultrasound: an interdisciplinary expert consensus. *POCUS J* 2024;**9**:95–108. <https://doi.org/10.24908/pocus.v9i1.17240>